

Distribution of mandibular trabeculae bone volume fraction in relation to different MOP intervals for accelerating orthodontic tooth movement: *A randomized controlled trial*

Ng Heng Kiang Teh^a; Saritha Sivarajan^b; Muhammad Khan Asif^c; Norliza Ibrahim^d; Mang Chek Wey^e

ABSTRACT

Objectives: To investigate the effect of micro-osteoperforation (MOP) on the horizontal and vertical distribution of mandibular trabeculae bone volume fraction in relation to different MOP intervals during canine retraction.

Materials and Methods: This single-center, single-blinded, prospective randomized split-mouth clinical trial included 30 healthy participants aged 18 years and older, randomized into three groups of different MOP intervals (4, 8, and 12-weekly). Cone beam computed tomography images were taken to assess the bone volume fraction (bone volume over total volume or BV/TV).

Results: BV/TV was significantly reduced (mean difference: 9.79%, standard deviation [SD]: 11.89%; 95% confidence interval [CI]: 4.77, 14.81%; $P < .01$) and canine retraction increased (mean difference: -1.25 mm/4 mo, SD: 0.79 mm; 95% CI: -1.59, -0.92 mm; $P < .01$) with MOP, compared to control sites. MOP significantly changed the vertical and horizontal patterns of trabeculae bone with lower values nearer to intervention sites. Only the 4-weekly MOP interval group showed significant decrease in BV/TV (mean difference: 14.73%, SD: 12.88%; 95% CI: 3.96, 25.50%; $P = .01$) despite significant increase in canine retraction rate for all interval groups. With the use of MOP, BV/TV was found to be inversely correlated to the rate of canine retraction ($r = -0.425$; $P = .04$).

Conclusions: Mandibular trabecular alveolar bone volume fraction was reduced and rate of orthodontic tooth movement increased with MOP, especially in the 4-weekly interval. However, this effect was limited to the immediate interdental region of MOP. (*Angle Orthod.* 2020;90:774–782.)

KEY WORDS: Accelerated tooth movement; Micro-osteoperforation; Bone volume fraction; BV/TV

INTRODUCTION

Tooth movement rate is affected by alveolar bone remodelling.^{1–3} Altering this biology, such as with micro-osteoperforation (MOP) can induce a regional accele-

ratory phenomenon (RAP), which is the basis for accelerated orthodontics.^{4–9} The increased rates of bone remodeling and catabolic activities with RAP can be observed as trabecular alveolar bone volume

^a Orthodontic Resident, Department of Pediatric Dentistry and Orthodontics, Faculty of Dentistry, University Malaya, Kuala Lumpur, Malaysia.

^b Orthodontic Lecturer, Department of Pediatric Dentistry and Orthodontics, Faculty of Dentistry, University Malaya, Kuala Lumpur, Malaysia.

^c Lecturer, Department of Oral and Maxillofacial Clinical Sciences, Faculty of Dentistry University Malaya, Kuala Lumpur, Malaysia.

^d Associate Professor, Department of Oral and Maxillofacial Clinical Sciences, Faculty of Dentistry University Malaya, Kuala Lumpur, Malaysia.

^e Associate Professor, Department of Pediatric Dentistry and Orthodontics, Faculty of Dentistry, University Malaya, Kuala Lumpur, Malaysia.

Corresponding author: Dr Mang Chek Wey, Associate Professor, Department of Pediatric Dentistry and Orthodontics, Faculty of Dentistry, University Malaya, Kuala Lumpur 50603, Malaysia (e-mail: weymc@um.edu.my)

Accepted: June 2020. Submitted: March 2020.

Published Online: September 9, 2020

© 2020 by The EH Angle Education and Research Foundation, Inc.

fraction (bone volume over total volume or BV/TV) reduction,^{4,10} measurable via cone beam computed tomography (CBCT).¹¹

There are no randomized clinical trials investigating the MOP-related mandibular trabecular pattern changes over distance. Understanding the spread of MOP effects and their related interval would better enable its clinical use. The purpose of this randomized controlled CBCT study of orthodontic patients was to investigate the horizontal and vertical distribution of mandibular trabeculae pattern from different intervals of MOP. This study was limited to the mandible, where tooth movement is slower and bone density greater, compared to the maxilla.^{12,13} The null hypothesis was that there would be no difference in the mandibular trabeculae pattern between MOP-assisted orthodontic tooth movement, compared to conventional treatment.

The main aim was to investigate the area of mandibular BV/TV changes, caused by MOP in relation to the rate of orthodontic tooth movement. The objectives were:

1. To compare the effect of MOP-assisted orthodontic tooth movement on the horizontal pattern of mandibular trabeculae between MOP-assisted (intervention) and contralateral non-MOP (control) sides.
2. To compare the effect of MOP-assisted tooth movement on the vertical pattern of mandibular trabeculae between MOP-assisted and control sides.
3. To compare the distribution of mandibular trabeculae pattern in relation to different MOP-assisted intervals.

MATERIALS AND METHODS

Trial Design

This was a single-center, single-blinded, prospective, randomized split-mouth clinical trial conducted at University of Malaya. Ethical approval for this study was obtained from the Ethics Committee of the Faculty of Dentistry of University of Malaya (DF CD1608/0059(P)), and its registration was ClinicalTrials.gov no.NCT03924726.

Participants, Setting, and Eligibility Criteria

Inclusion criteria were: 18 years and above; either Class I, < unit Class II, or < unit Class III molar relationships; extraction of mandibular first premolars; mini-implant anchorage; and good oral hygiene. Exclusion criteria included: systemic disease requiring long-term antibiotic, phenytoin, cyclosporin, anti-inflammatory drugs, bisphosphonates, systemic cortico-

steroids, or calcium channel blockers; medication related to bone remodeling (glucocorticoids, aromatase inhibitors, proton pump inhibitors, immunosuppressants, selective serotonin inhibitors, and anti-epileptic drugs); vertical skeletal discrepancies; inadequate oral hygiene for more than two visits; active periodontal disease; and smoking.

Interventions

The lower dentition was fitted with preadjusted MBT edgewise brackets (3M Unitek, Monrovia, California, 0.022×0.028-in. slot). Prior to extractions, mini-implants (Orlus, Ortholution, 1.6×6 mm) were placed mesial to first molars for anchorage purposes. Canines were retracted on a 0.018×0.025-in. stainless steel arch wire using power chain (3M Unitek, Monrovia, California, Alastik) at 140-200 g (measured with Correx Force Tension gauge, Haag-Streit Diagnostics, Koeniz, Switzerland). Three vertical MOPs, 2-mm apart, were performed under local anesthesia on the intervention side, equidistant from the canine and second premolar to 3-mm depth using a similar mini-implant, according to three different time intervals (4, 8, and 12 weeks).

CBCT (Kodak 9000c 3D model, Carestream Health Dental Imaging/Practiceworks, Atlanta, GA, USA) was taken for MOP and non-MOP sides only once at 12 weeks after starting canine retraction. The selected scanning parameters used were 70kV, 10mA, 10.80 seconds, field of view of 5×5 cm with a resolution of 76 μm³. This was to assess the trabecular alveolar bone volume fraction (BV/TV). The rate of orthodontic tooth movement was assessed from canine retraction rate measured every 4 weeks with digital calipers accurate to 0.01 mm.

Sample Size Calculation

At the start of this study, no previous in vivo studies were available for determining the significant BV/TV related to orthodontic tooth movement to establish the sample size. Therefore, an animal study⁴ was used. To be able to observe an effect size of 0.7%, $\alpha \leq 0.05$ significance level, and to have an 80% power to detect significant differences among three study groups, a sample size of 24 patients was estimated and 30 participants were recruited to account for 30% dropout.

Randomization

Thirty participants were randomly allocated into three equal groups using a simple random pattern generated online (Random.org); group 1 with MOP interval of 4 weeks; group 2, eight weeks; and group 3, twelve weeks. Every group had its own contralateral

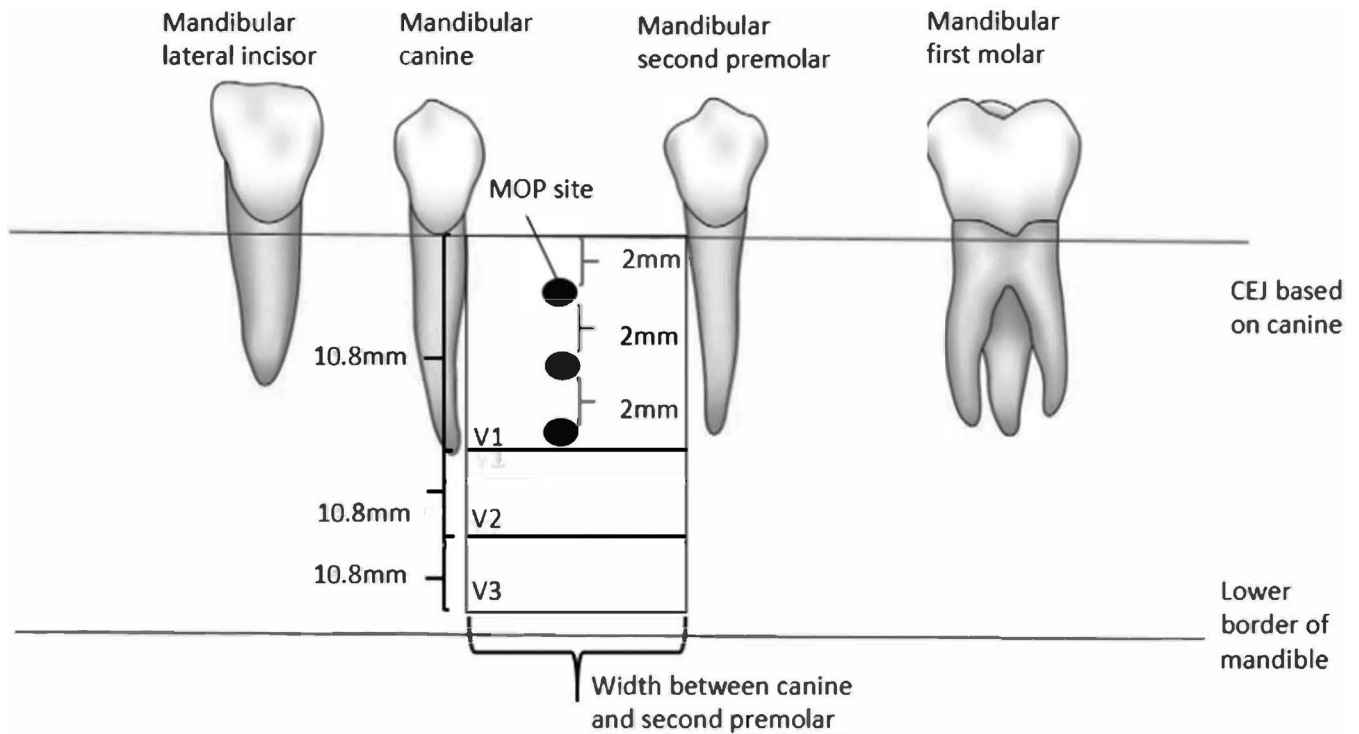


Figure 1. Schematic diagram for vertical sections.

split-mouth control. The sequence was then concealed in sealed individual envelopes with a unique identification number and revealed upon enrollment of patients into the trial. Simple randomization for the intervention and control sides was done separately via drawing of lots by the patients.

Data Collection

ImageJ software (Version 1.50.i) was used to convert the DICOM (Digital Imaging and Communications in Medicine) CBCT image data files into BMP (Bitmap) files for subsequent analysis with CT Analyser software (version 1.11.0.0, copyright Skyscan, Kontich, Belgium). Each mandibular quadrant was divided into three vertical and horizontal sections. The buccal and lingual cortical plate were set as the buccolingual limit for horizontal and vertical sections. The vertical sections extended vertically from the cemento-enamel junction (CEJ) of the canine to the slice at a distance of 32.4 mm or less, apical to the top border on the axial view of the CBCT image, and horizontally from the distal cortical plates of the canine root to the mesial cortical plates of the second premolar root (Figure 1). The 10.8-mm vertical sections labelled V1 and V2 at the top and middle respectively, and the apical third section labelled V3 (maximum: 10.8 mm or less), were analyzed for bone volume fraction, in 142 slices for each section.

The horizontal ROI extended from the distal root surface of the mandibular lateral incisor to the mesial

root of the first molar (Figure 2). The horizontal region of interest (ROI) was divided into three unequal sections: H1 from the distal cortical plate of the lateral incisor to the mesial plate of the canine, H2 from the distal cortical plate of the canine to the mesial of the second premolar, and H3 from the distal plate of the second premolar to the mesial of the first molar plate.

In CT analyzer, a polygonal tool was used to plot the top (Figure 3) and bottom border slices of each ROI. Dynamic interpolation from the software was then applied and each individual slice was manually checked for best fit to obtain an adaptive ROI. The ROI was then binarized using the threshold values based on the cortical bone on the control side and used to calculate the BV/TV.

Outcomes

The main objective was to investigate the area of BV/TV changes influenced by micro-osteoperforations (MOPs) in relation to the rate of orthodontic tooth movement.

Error of the Method

Intra-observer and inter-observer calibration for one examiner (TNHK) were conducted after 1 month's training. Five random samples were analyzed and repeated 2 weeks later for intra-observer reliability, then compared against another experienced research-

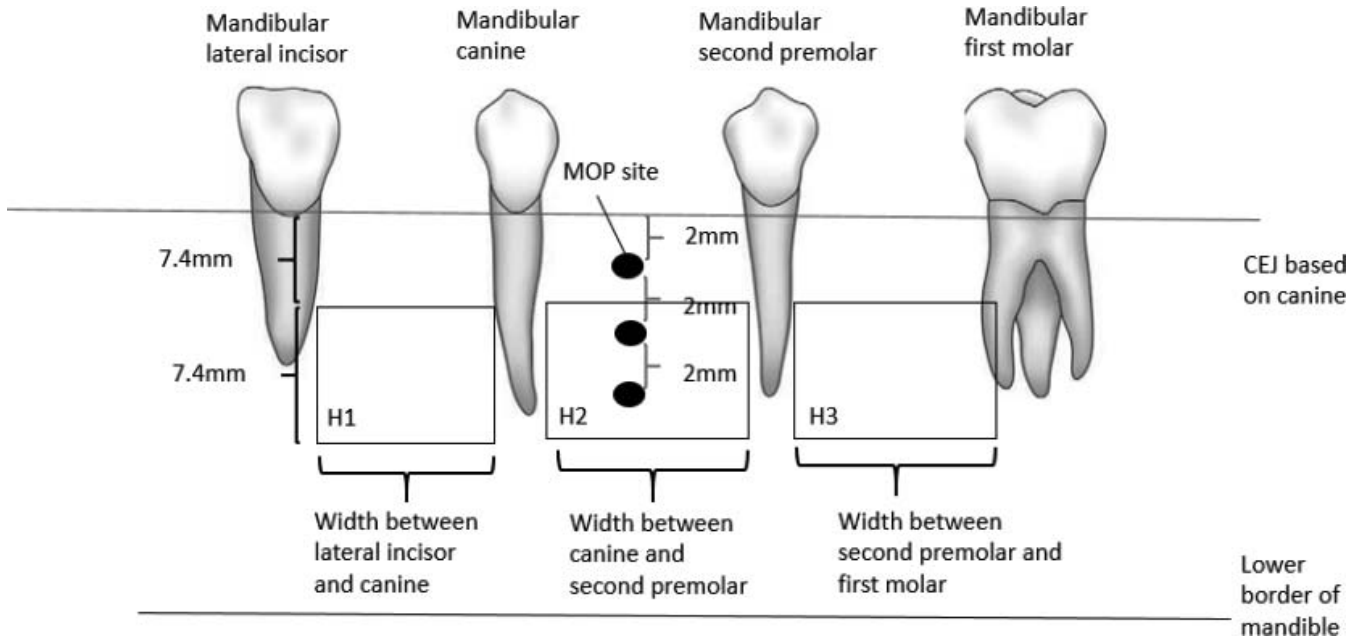


Figure 2. Schematic diagram for horizontal sections.

er (M) for interobserver reliability. Intraclass correlation coefficient (ICC) estimates and their 95% confidence intervals (CI) were calculated using SPSS statistical package version 22 based on a mean rating ($k = 2$), absolute-agreement, two-way mixed-effects model. Both intra-rater (0.96) and inter-rater (0.90) ICC scores indicated excellent and good reliability, respectively.

Blinding

The CBCT files were labeled randomly by a research assistant for blinding of data during analysis by another examiner.

Statistical Analysis

Reliability testing was done by ICC analysis on five random samples. The normality spread of data was tested with Shapiro-Wilk test. Parametric paired *t*-test and analysis of variance (ANOVA) tests (IBM SPSS version 22) were used for statistical analysis with significance level set at $P < .05$.

RESULTS

Thirty subjects were recruited, randomized and distributed into three groups of 10 subjects based on the MOP intervals of 4, 8, and 12 weeks. At the end of the trial, the CBCT data of only 24 participants were collected (Figure 4).

The subjects' age ranged from 19 to 27 years old (group 1 = 23.4 ± 1.8 , group 2 = 24.0 ± 2.6 , group 3 = 23.3 ± 2.8 years), with no significant age difference among groups ($P = .846$ calculated from ANOVA).

To minimize radiation, a CBCT was taken only once at 12 weeks after starting canine retraction. Baseline measurement for the intervention side was deemed almost similar to the measurement at the control side, as they were from contralateral sides of the same mandible.

Comparison of Bone Volume Fraction

Paired *t*-test analysis of all pooled intervention groups showed significantly decreased BV/TV at V1 and H2 sections (Table 1). Canine movement was

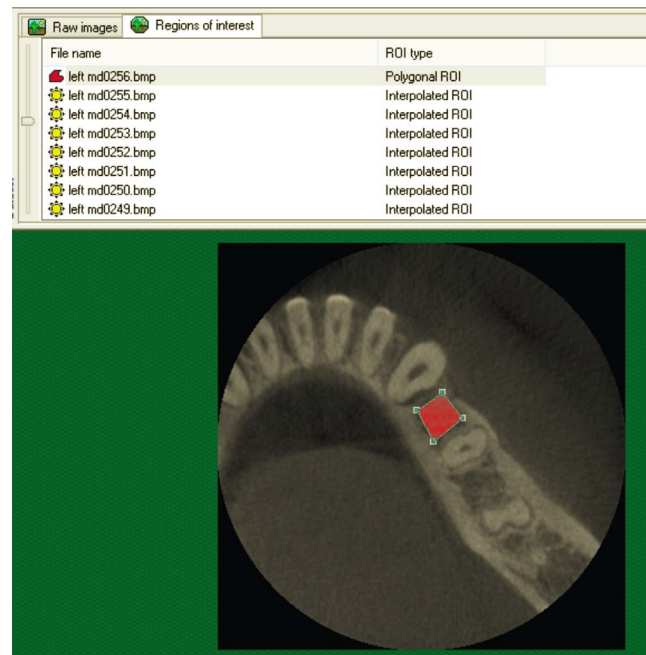


Figure 3. Top layer selection for the region of interest of V1.

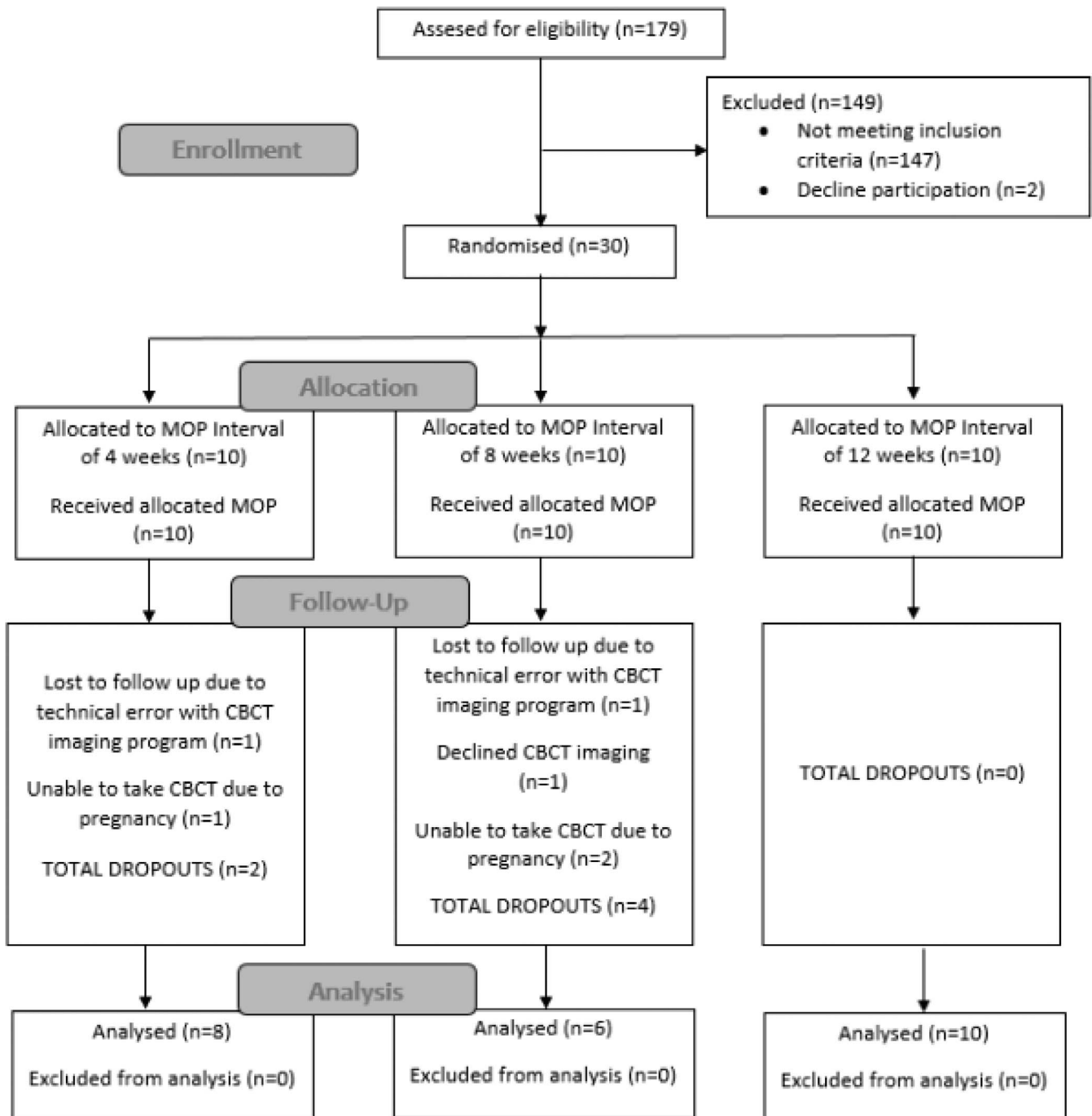


Figure 4. Consort diagram of patient recruitment.

significantly faster by 1.25 mm/4 mo (0.31 mm/mo) than the control side.

BV/TV distributions were similar among the vertical levels ($P = .95$) of the control side (Table 2, Figure 5), however horizontally, there was a significant increase toward the posterior ($P < .01$) (Figure 6). BV/TV of the intervention side increased significantly in the apical direction ($P = .03$), from V1 to V3. As on the control side, BV/TV increased toward the molar ($P < .01$).

Different MOP interval groups were then compared against the control group by comparing the difference in their mean values according to different vertical and horizontal sections. Significant differences in the mean BV/TV were found only for V1 and H2 sections at 4-weekly intervals, and H2 at 12-weekly intervals (Table 3).

Comparison of horizontal and vertical distribution on the intervention side for all intervention intervals using ANOVA post-hoc Tukey test were statistically signifi-

Table 1. Paired Sample Test Comparison of BV/TV and Canine Movement Rates Between Control and Intervention Sides^a

	Paired Difference Between Control and Intervention			P Value (2-tailed)
	Mean (SD)	95% Confidence Interval of the Difference		
		Lower	Upper	
BV/TV/ %				
V1	9.79 (11.89)	4.77	14.81	<.01*
V2	5.20 (13.19)	-0.37	10.77	.07
V3	-1.59 (10.47)	-6.01	2.83	.47
H1	7.53 (25.34)	-3.17	18.23	.16
H2	10.03 (13.41)	4.36	15.69	<.01*
H3	0.08 (12.06)	-5.01	5.17	.97
Canine movement rate/(mm/4 mo)	-1.25 (0.79)	-1.59	-0.92	<.01*

^a BV/TV indicates bone volume over total volume; SD, standard deviation.
* P < .05 is significant.

cant only for the 4-weekly MOP interval (group 1), where the horizontal distribution of BV/TV increased toward the posterior for the intervention side (P = .01), whereas the vertical distribution on the intervention side increased toward the apical (P = .01) (Table 4). BV/TV at V1 section was statistically significant for all the pooled MOP intervals (Table 1) and for the 4-weekly interval only (Table 3). However, canine retraction was significantly increased for all three intervention intervals.

DISCUSSION

Main Findings in the Context of Existing Evidence

Demographics. Due to unpredicted dropouts, group 2 (8-weekly MOP), with only six instead of the minimum eight participants, was underpowered to detect the BV/TV at 80% power. To reduce bias, the data analyses were based around differences in mean of the control compared to the intervention sides.

Radiographic Measurements. Micro-CT images with spatial resolution of 15 to 20 μm³ is the gold standard for assessing bone trabeculae patterns, in contrast to the CBCT resolution of 76 μm × 76 μm × 76 μm voxel size that was used in this study.¹⁴ However, in view of the high radiation dose and the strong correlation between both measurement methods,¹¹ the bone

microstructure was measured with CBCT in this study. However, further comparison in varying the reconstruction parameters is suggested.

Influence of MOP on Bone Volumetric Fraction

In this study, MOP significantly reduced the BV/TV and increased the rate of orthodontic tooth movement, in agreement with three animal studies.^{4,8,15} Unlike other micro-CT studies on human cadavers,^{16,17} the BV/TV results decreased toward the occlusal and the anterior. This could have been due to the BV/TV reduction in alveolar bone undergoing active orthodontic treatment,^{18,19} where in this study, the larger reduction of BV/TV in the anterior could have been due to the actively moving anterior teeth compared to the posterior, where the molars were anchored by the miniscrew.

Due to BV/TV reduction presenting only at the H2 section, it was hypothesized that MOP would not affect the whole horizontal section of that quadrant, much less cross over to the contralateral side. In the vertical dimension, MOP induced a BV/TV reduction in the apical-coronal direction, in contrast to Fanuscu and Chang,¹⁶ in which the BV/TV decreased in the coronal direction. This pattern of reduction during active orthodontic treatment was similar to that of the horizontal dimension, as most orthodontic movements occurred near the crestal bone (V1) as opposed to the lower border of the mandible (V3). Unlike the control side, the difference in the BV/TV among the vertical sections was statistically significant.

BV/TV reduced significantly only at the 10.8-mm vertical section, immediately below the canine CEJ and the horizontal interdental section between canine and second premolar where the MOP was performed. Although BV/TV decreased slightly in the regions adjacent to the MOP area, it was statistically insignificant. This was similar to the findings of an animal study,⁵ where it was reported that the regional acceleratory phenomenon (RAP) caused a significant

Table 2. Distribution of BV/TV Across Alveolar Bone^a

Mean (SD) / %	Control (n = 24)	P Value (ANOVA)	Intervention (n = 24)	P Value (ANOVA)
V1	63.97 (7.63)		54.18 (14.70)	
V2	63.24 (12.14)	.95	58.04 (13.48)	.03*
V3	62.98 (13.01)		64.57 (10.87)	
H1	49.27 (23.75)		41.74 (28.33)	
H2	61.65 (8.79)	<.01*	51.62 (15.25)	<.01*
H3	67.54 (15.03)		67.46 (15.83)	

^a ANOVA indicates analysis of variance; BV/TV, bone volume over total volume.
* P < .05 is significant.

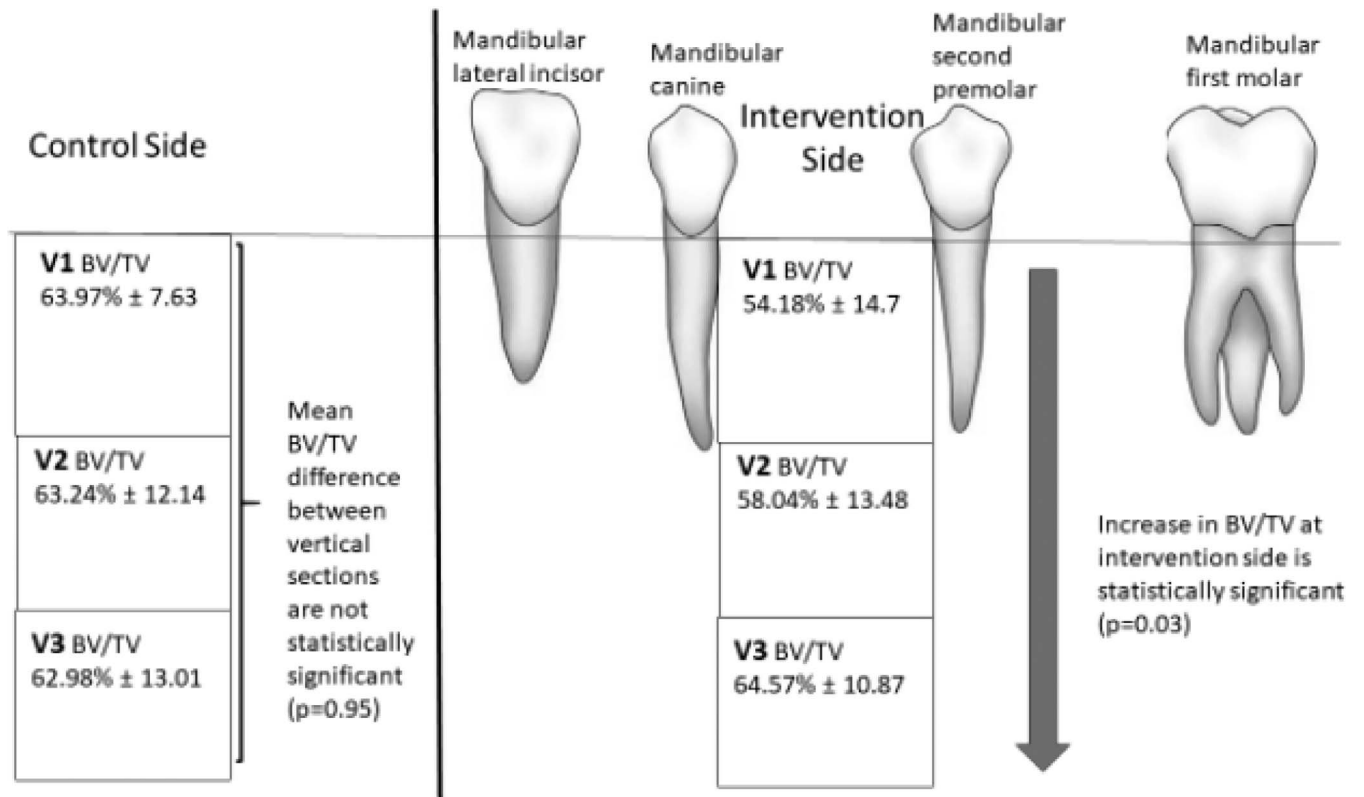


Figure 5. Schematic diagram of vertical distribution in bone volumetric density for control and intervention sides.

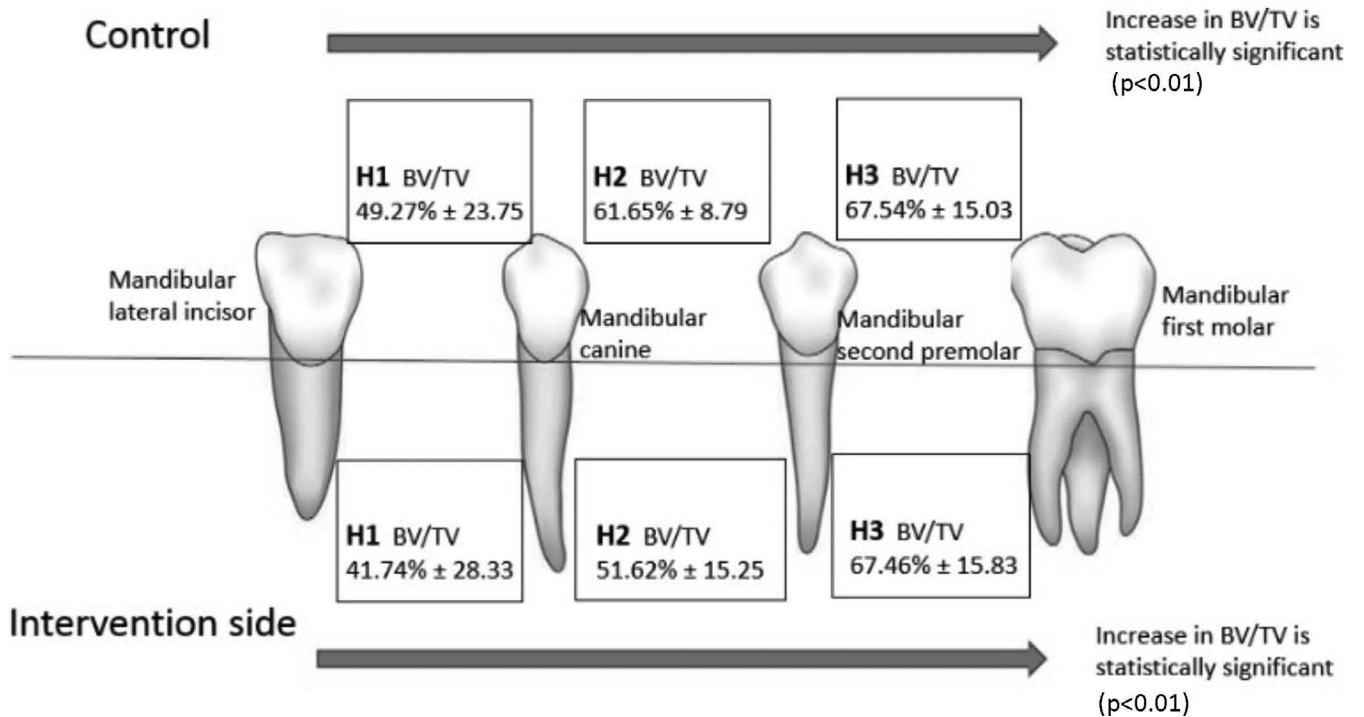


Figure 6. Schematic diagram of horizontal distribution in bone volumetric density for control and intervention sides.

Table 3. Paired Sample Test Comparing BV/TV and Rate of Canine Movement Between Each Different MOP Interval and Its Control Side^a

BV/TV / %	Paired Difference Between Control and Intervention Sides					
	4-weekly MOP (n = 8)		8-weekly MOP (n = 6)		12-weekly MOP (n = 10)	
	Mean (SD)	P Value	Mean (SD)	P Value	Mean (SD)	P Value
V1	14.73 (12.88)	.01*	7.01 (9.73)	.14	7.51 (12.12)	.08
V2	5.95 (18.22)	.39	7.51 (8.71)	.08	3.22 (11.67)	.41
V3	.50 (13.41)	.92	-1.03 (9.70)	.81	-3.59 (8.92)	.24
H1	3.82 (26.99)	.70	8.02 (21.55)	.40	10.20 (28.21)	.28
H2	15.08 (17.86)	.04*	6.19 (12.69)	.29	8.28 (9.29)	.02*
H3	-.06 (16.38)	.99	-1.31 (6.67)	.65	1.03 (11.66)	.79
Canine movement rate / (mm / 4 mo)	-1.49 (0.78)	<.01*	-1.12 (.60)	.01*	-1.14 (.93)	<.01*

^a BV/TV indicates bone volume over total volume; MOP, micro-osteoperforation; SD, standard deviation.

* $P < .05$ is significant; negative value denotes that intervention is larger than control.

decrease in the bone fraction values around the second molar area, which was not actively under orthodontic force. Similarly, Teixeira et al.⁸ found that the BV/TV reduction effect of MOP did not cross over to the contralateral side. Although MOP can significantly reduce the BV/TV of alveolar bone, this effect was localized to a small area around the MOP. To increase the rate of orthodontic tooth movement of multiple teeth, MOPs need to be placed at multiple sites of shorter distances. The use of MOP can therefore be specifically targeted at specific teeth while not affecting other teeth such as the anchor teeth.

Influence of Micro-osteoperforation Intervals on Bone Volumetric Fraction

The BV/TV trend at the 4-weekly interval was similar to the pooled intervals, where BV/TV at V1 and H2 reduced by almost 15%, while the rest showed insignificant reduction. The horizontal and vertical BV/TV similarly decreased coronally and anteriorly. There was no difference for the 8- and 12- weekly MOP

intervals. Only H2 showed reduction on the intervention side for the 12-weekly interval.

RAP occurs a few hours after noxious stimulation with the initiation of the inflammatory process, then it achieves peak effect at 1-2 months and lasts for about 4 months.^{7,20} It had been recommended for orthodontic tooth movement to commence not later than 2 weeks after the acceleration intervention so as to fully use the RAP effect, which lasts about 4-6 months.^{21,22} The peak of RAP effect coincided with the 4-weekly MOP interval of subjects in group 1, resulting in significant BV/TV reduction. However, this was less pronounced with the 8- and 12-weekly intervals probably due to the RAP effect not being at peak values.

Despite the BV/TV difference being only significant for the 4-weekly MOP interval between control and intervention sides of V1, the canine retraction rate was significantly increased for all three intervals by almost 0.3 mm per month. The fastest retraction rate was with the 4-weekly MOP, 1.49 mm/4 wk more than the control. The RAP induced by MOP is thought to decrease BV/TV and increase alveolar bone turnover which, in turn, accelerates orthodontic tooth move-

Table 4. Comparison of BV/TV Distribution Across Intervention and Control Sides According to MOP Intervals^a

Section	4-weekly MOP		8-weekly MOP		12-weekly MOP	
	Mean (SD) / %	P Value	Mean (SD) / %	P Value	Mean (SD) / %	P Value
Intervention						
V1	44.42 (15.47)		59.66 (11.69)		58.70 (12.77)	
V2	59.13 (14.09)	.01*	55.10 (15.59)	.70	58.94 (12.93)	.53
V3	67.38 (11.24)		61.71 (13.96)		64.04 (9.08)	
H1	34.44 (18.30)		40.84 (28.61)		48.12 (35.25)	
H2	43.25 (18.84)	.01*	55.51 (10.29)	.06	56.00 (12.86)	.21
H3	65.43 (18.26)		71.70 (19.06)		66.54 (12.76)	
Control						
V1	59.15 (5.28)		66.67 (9.21)		66.22 (7.00)	
V2	65.07 (10.49)	.26	62.61 (15.43)	.68	62.16 (12.42)	.52
V3	67.88 (13.95)		60.68 (9.92)		60.45 (13.95)	
H1	38.27 (22.65)		48.86 (22.72)		58.31 (23.60)	
H2	58.33 (7.09)	.02*	61.71 (11.57)	.12	64.27 (8.17)	.45
H3	65.37 (18.89)		70.38 (14.29)		67.57 (13.29)	

^a BV/TV indicates bone volume over total volume; MOP, micro-osteoperforation; SD, standard deviation.

* P value for F test between means is significant at $< .05$, analyzed by analysis of variance.

ment.^{20,23} This could imply that the peak effect of RAP is needed to cause a significant reduction of BV/TV. However, significantly increased rates of orthodontic tooth movement can be achieved as long as the RAP effect is present, even at non-peak levels.

Limitations of the Study

Clinical measurement of canine retraction may be less accurate than using dental study casts or three-dimensional superimposition and this study only investigated BV/TV changes over 12 weeks. However, this prospective randomized split-mouth exploratory investigation of bone density related to MOP does add to the biological understanding and should form the basis of further longer-term prospective research.

CONCLUSIONS

- Mandibular trabecular alveolar bone volume fraction was reduced and rate of orthodontic tooth movement was increased with MOP, especially in the 4-weekly interval. However, this effect was limited to the immediate interdental region of MOP.

ACKNOWLEDGMENTS

This study was funded by the Malaysia Ministry of Higher Education Fundamental Research Grant Scheme (Grant no.FP018-2017A).

REFERENCES

1. Burstone CJ. The biomechanics of tooth movement. *Vistas in Orthodontics*. Lea & Feabiger: Philadelphia. 1962:197–213.
2. Krishnan V, Davidovitch Z. Cellular, molecular, and tissue-level reactions to orthodontic force. *Am J Orthod Dentofacial Orthop*. 2006;129(4):469.e461–432. doi:10.1016/j.ajodo.2005.10.007.
3. Krishnan V, Davidovitch Z. On a path to unfolding the biological mechanisms of orthodontic tooth movement. *J Dent Res*, 2009;88(7):597–608. doi:10.1177/0022034509338914.
4. Tsai CY, Yang TK, Hsieh HY, Yang LY. Comparison of the effects of micro-osteoperforation and corticision on the rate of orthodontic tooth movement in rats. *Angle Orthod*. 2016; 86(4):558–564. doi:10.2319/052015-343.1.
5. Verna C, Zaffe D, Siciliani G. Histomorphometric study of bone reactions during orthodontic tooth movement in rats. *Bone*. 1999;24(4):371–379.
6. Verna C. Regional acceleratory phenomenon. *Front Oral Biol*. 2016;18:28–35. doi:10.1159/000351897.
7. Wilcko WM, Wilcko T, Bouquot JE, Ferguson DJ. Rapid orthodontics with alveolar reshaping: two case reports of decrowding. *Int J Periodontics Restorative Dent*. 2001;21(1): 9–19.
8. Teixeira CC, Khoo E, Tran J, et al. Cytokine expression and accelerated tooth movement. *J Dent Res*. 2010;89(10): 1135–1141. doi:10.1177/0022034510373764.
9. Sivarajan S, Doss JG, Papageorgiou SN, Cobourne MT, Wey MC. Mini-implant supported canine retraction with micro-osteoperforation: a split-mouth exploratory randomized clinical trial. *Angle Orthod*. 2019;89:183–189. doi:10.2319/011518-47.1.
10. Baloul SS, Gerstenfeld LC, Morgan EF, Carvalho RS, Van Dyke TE, Kantarci A. Mechanism of action and morphologic changes in the alveolar bone in response to selective alveolar decortication-facilitated tooth movement. *Am J Orthod Dentofacial Orthop*. 2011;139(4 Suppl):S83–101. doi:10.1016/j.ajodo.2010.09.026.
11. Ibrahim N, Parsa A, Hassan B, van der Stelt P, Aartman IH, Wismeijer D. Accuracy of trabecular bone microstructural measurement at planned dental implant sites using cone-beam CT datasets. *Clin Oral Implants Res*. 2014;25(8):941–945. doi:10.1111/clr.12163.
12. Park HS, Lee YJ, Jeong SH, Kwon TG. Density of the alveolar and basal bones of the maxilla and the mandible. *Am J Orthod Dentofacial Orthop*. 2008;133:30–37.
13. Giannopoulou C, Dudic A, Pandis N, Kiliaridis S. Slow and fast orthodontic tooth movement: an experimental study on humans. *Eur J Orthod*. 2016;38:404–408.
14. Jiang Y, Zhao DL, White, Genant HK. Micro CT and Micro MR imaging of 3D architecture of animal skeleton. *J Musculoskel Neuron Interact*. 2000;1:45–51.
15. Cheung T, Park J, Lee D, et al. Ability of mini-implant facilitated micro-osteoperforations to accelerate tooth movement in rats. *Am J Orthod Dentofacial Orthop*. 2016;150(6): 958–967. doi:10.1016/j.ajodo.2016.04.030.
16. Fanuscu MI, Chang TL. Three-dimensional morphometric analysis of human cadaver bone: microstructural data from maxilla and mandible. *Clin Oral Implants Res*. 2004;15(2): 213–218.
17. Kim JE, Shin JM, Oh SO, et al. The three-dimensional microstructure of trabecular bone: Analysis of site-specific variation in the human jaw bone. *Imaging Sci Dent*. 2013; 43(4):227–233. doi:10.5624/isd.2013.43.4.227.
18. da Silva Campos MJ, de Albuquerque EG, Pinto BCH, et al. The role of orthodontic tooth movement in bone and root mineral density: a study of patients submitted and not submitted to orthodontic treatment. *Int Med J Exp Clin Res*. 2012;18(12):CR752–CR757. doi:10.12659/MSM.883604.
19. Yu JH, Huang HL, Liu CF, et al. Does orthodontic treatment affect the alveolar bone density? *Medicine*, 2016;95(10): e3080. doi:10.1097/MD.0000000000003080.
20. Schilling T, Muller M, Minne HW, Ziegler R. Influence of inflammation-mediated osteopenia on the regional acceleratory phenomenon and the systemic acceleratory phenomenon during healing of a bone defect in the rat. *Calcif Tissue Int*. 1998;63(2):160–166.
21. Murphy KG, Wilcko MT, Wilcko WM, Ferguson DJ. Periodontal accelerated osteogenic orthodontics: a description of the surgical technique. *J Oral Maxillofac Surg*. 2009; 67(10):2160–2166. doi:10.1016/j.joms.2009.04.124.
22. Amit G, Jps K, Pankaj B, Suchinder S, Parul B. Periodontally accelerated osteogenic orthodontics (PAOO) - a review. *J Clin Experimental Dent*. 2012;4(5):e292–e296. doi:10.4317/jced.50822.
23. Goldie RS, King GJ. Root resorption and tooth movement in orthodontically treated, calcium- deficient, and lactating rats. *Am J Orthod*, 1984;85(5):424–430.