

**Comparison of skeletal maxillary transverse deficiency treated by microimplant-assisted rapid palatal expansion and tooth-borne expansion during the post-pubertal growth spurt stage:
A prospective cone beam computed tomography study**

Haichao Jia^a; Li Zhuang^b; Nan Zhang^b; Yuanyuan Bian^c; Song Li^d

ABSTRACT

Objective: To investigate the efficacy of microimplant-assisted rapid palatal expansion (MARPE) to treat skeletal maxillary discrepancies during the post-pubertal growth spurt stage.

Materials and Methods: Sixty patients with skeletal maxillary transverse deficiency during the post-pubertal growth spurt stage were randomly divided into MARPE and Hyrax groups. Thirty patients (mean age: 15.1 ± 1.6 years) were treated using the four-point MARPE appliance; 30 patients (mean age, 14.8 ± 1.5 years) were treated using the Hyrax expander. Cone beam computed tomography scans and dental casts were obtained before and after expansion. The data were analyzed using paired *t*-tests and independent *t*-tests.

Results: The success rates of midpalatal suture separation were 100% and 86.7% for MARPE and Hyrax groups, respectively. Palatal expansion and skeletal to dental ratio at the first molar level were greater in the MARPE group (3.82 mm and 61.4%, respectively) than in the Hyrax group (2.20 mm and 32.3%, respectively) ($P < .01$). Reductions in buccal alveolar bone height and buccal tipping of the first molars were less in the MARPE group than in the Hyrax group ($P < .01$).

Conclusions: MARPE enabled more predictable and greater skeletal expansion, as well as less buccal tipping and alveolar height loss on anchorage teeth. Thus, MARPE is a better alternative for patients with skeletal maxillary deficiency during the post-pubertal growth spurt stage. (*Angle Orthod.* 2021;91:36–45.)

KEY WORDS: Maxillary transverse deficiency; Microimplant-assisted rapid palatal expansion; Tooth-borne expansion; Post-pubertal growth spurt stage

INTRODUCTION

Rapid palatal expansion (RPE) with tooth-borne expanders has been used to treat patients with maxillary transverse deficiency.^{1,2} Many studies have shown that skeletal changes contribute to approximately one-third of the overall dental expansion after pubertal growth.^{3,4} Side effects are more common as skeletal expansion decreases, including bone dehiscence or fenestration, gingival recession, root resorption, posterior teeth buccal tipping, and relapse.^{5,6} Bishara and Staley¹ also reported that the optimal age for tooth-borne maxillary expansion is prior to 13–15 years of age, and the results are neither predictable nor stable in older patients.

Due to variation among individuals, skeletal age is a more accurate measure of skeletal maturity than chronological age.⁷ Revelo and Fishman evaluated the relationship between ossification of the midpalatal

^a Clinical Professor, Department of Orthodontics, Beijing Stomatological Hospital and School of Stomatology, Capital Medical University, Beijing, China.

^b Associate Clinical Professor, Department of Orthodontics, Beijing Stomatological Hospital and School of Stomatology, Capital Medical University, Beijing, China.

^c Postgraduate Student, Department of Orthodontics, Beijing Stomatological Hospital and School of Stomatology, Capital Medical University, Beijing, China.

^d Professor, Department of Orthodontics, Beijing Stomatological Hospital and School of Stomatology, Capital Medical University, Beijing, China.

Corresponding author: Dr Haichao Jia, Department of Orthodontics, Beijing Stomatological Hospital and School of Stomatology, Capital Medical University, 11 Xila Hutong, Dongcheng District, Beijing 100006, China (e-mail: haichaojia@hotmail.com)

Accepted: August 2020. Submitted: April 2020.

Published Online: November 4, 2020

© 2021 by The EH Angle Education and Research Foundation, Inc.

Table 1. Sex, Age, and Type of Malocclusion Among Patients in This Study

	MARPE	Hyrax	<i>P</i>
Number (n)	30	30	
Sex			.417
Male (n)	9	12	
Female (n)	21	18	
Age at start of treatment (years)			
Mean \pm SD	15.1 \pm 1.6	14.8 \pm 1.5	.453
Range	12.6–18.1	12.3–17.6	
Age distribution			.795
<15 years (n)	16	17	
\geq 15 years (n)	14	13	
Posterior occlusion			.391
Bilateral crossbite	14	9	
Unilateral crossbite	7	8	
Constriction without crossbite	9	13	

suture and skeletal maturity indicator (SMI) on hand-wrist radiography, in which the rate of interdigitation increased markedly in the midpalatal suture after SMI 8, and suggested that maxillary expansion should be completed before SMI 9.⁸ Therefore, maxillary expansion during the post-pubertal growth spurt stage (SMI 8–11) causes a particular concern.

To increase skeletal expansion and reduce the side effects of tooth-borne RPE, various types of bone-borne RPE have been developed.^{9–14} These appliances may produce different results based on their design and active protocol. A four-point microimplant-assisted rapid palatal expansion appliance (MARPE) has been used to treat skeletal maxillary transverse deficiency.^{10,15–19}

Two retrospective studies^{12,16} and one prospective study¹⁴ revealed that a 4-point bone-borne expander produced greater skeletal expansion than a tooth-borne expander in adolescents. In the study of Lin et al. in late adolescence, the older mean age (18.1 years) indicated that most patients had completed their growth.¹² The younger mean age (13.8 years) in the two other studies indicated that many patients were treated before the post-pubertal growth spurt stage.^{14,16} Few studies regarding bone-borne RPE have been performed during the post-pubertal growth spurt stage.

The aim of the present study was to investigate differences between MARPE and tooth-borne expansion to treat maxillary transverse deficiency during the post-pubertal growth spurt stage and determine whether MARPE is a better alternative.

MATERIALS AND METHODS

This was a prospective randomized control clinical trial. Approval for this trial was obtained from the Ethical Committee of Beijing Stomatological Hospital, Capital Medical University (approval no. CMUSH-IRB-KJ-PJ-2018-21). Sixty consecutive patients were recruited from the Department of Orthodontics, Beijing Stomatological Hospital, Capital Medical University from July 2015 to February 2019. The inclusion criteria were as follows: (1) skeletal maxillary transverse deficiency;²⁰ (2) >5 mm of maxillary dental expansion required; (3) negative buccal corridor; and (4) during the post-pubertal growth spurt stage (SMI 8–11).^{7,8} Exclusion criteria were craniofacial congenital anomalies, such as cleft lip and palate. All patients and their

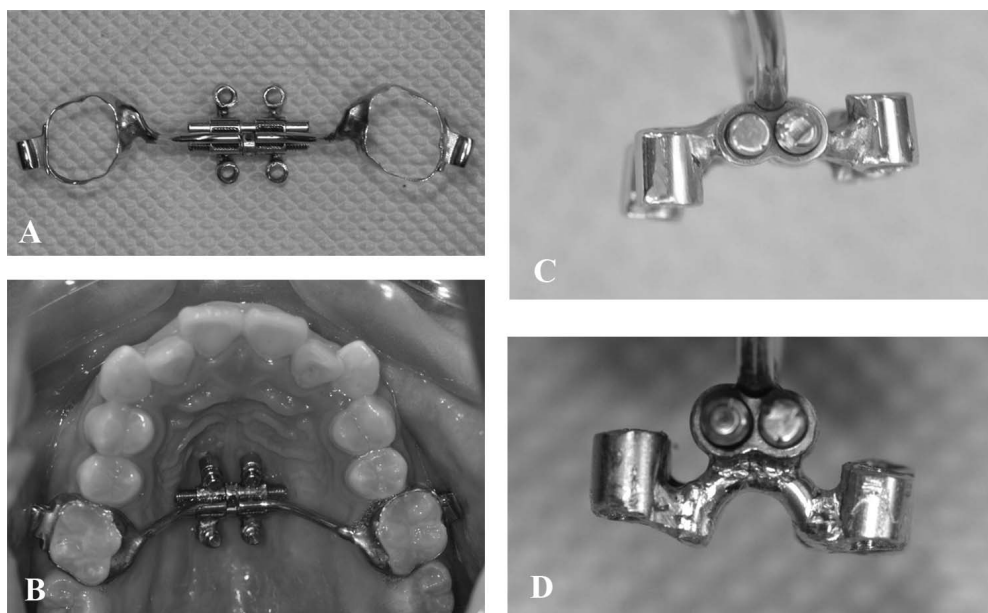


Figure 1. MARPE appliance. (A) photograph of MARPE appliance. (B) MARPE installation. (C) Direct connection of jackscrew and tube. (D) Indirect connection.

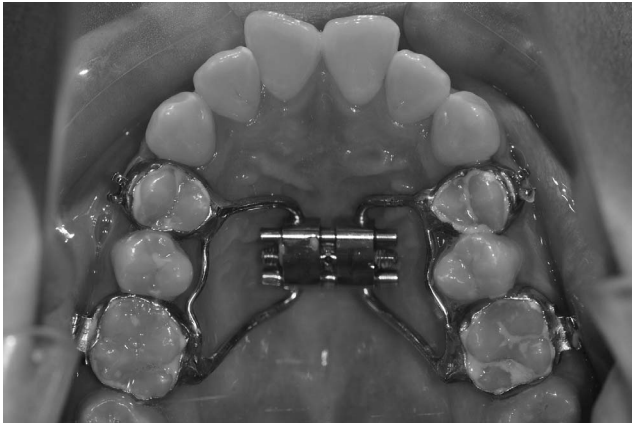


Figure 2. Hyrax expander.

parents provided informed consent to participate in this study.

Random numbers were generated using a standard approach with a computer program. The intervention information was enclosed in a sealed opaque envelope. Sixty patients were randomized in a 1:1 ratio to either the MARPE ($n = 30$) or Hyrax group ($n = 30$) for the trial. Patients and orthodontists were not blinded to the expander condition. Baseline demographic characteristics were matched in both groups (Table 1).

All appliances were fabricated by the same technician in the orthodontic lab. For the MARPE group, the MARPE appliance was composed of a jackscrew, four tubes, and two bands on the upper first molars (Figure 1A,B). The jackscrew (length: 12 mm; anatomic expander type: "s;" Forestadent, Pforzheim, Germany) was used for all patients. Four custom stainless-steel tubes (internal diameter: 2.0 mm; external diameter: 3.0 mm; length: 3.0 mm) were laser-soldered directly or indirectly to the body of the jackscrew. The direct connection type was used for patients with a broad palate (Figure 1C) and the indirect connection type for patients with severe narrow and deep palatal vault

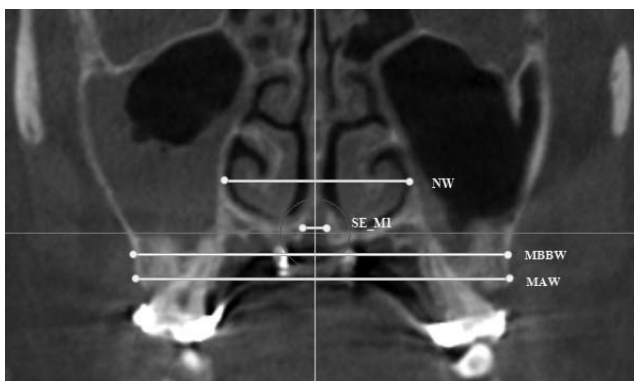


Figure 3. Transverse measurement of the maxillary first molar. NW indicates nasal width; SE_M1, suture expansion at first molar; MBBW, maxillary basal bone width; MAW, maxillary alveolar width.

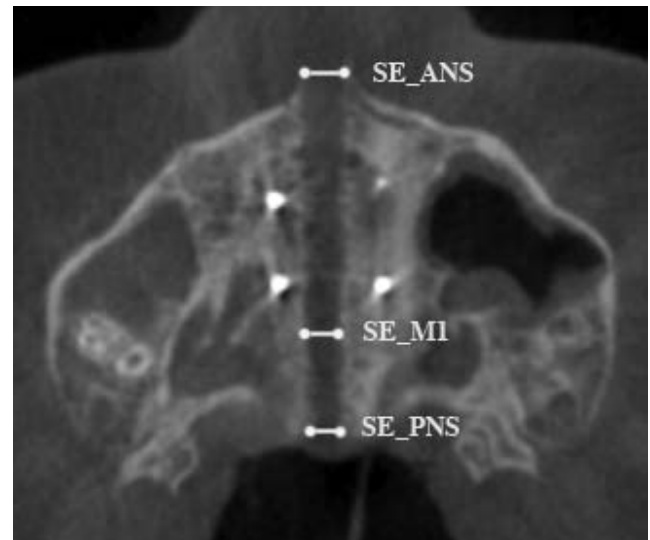


Figure 4. Measurement of midpalatal suture. SE_ANS indicates suture expansion at ANS; SE_PNS, suture expansion at PNS; SE_M1, suture expansion at maxillary first molar.

(Figure 1D). The jackscrew was located between the maxillary second premolars and first molars. The distance between the tube center and palatal suture was 3 mm. After the appliance was bonded to the first molars using glass ionomer cement, four miniscrews (diameter: 1.7 mm; length: 12.0 mm; self-drilled type: ORLUS, Ortholution, Seoul, Korea) were inserted into the tubes and passed through palatal cortical bone under local infiltration anesthesia.

In the Hyrax group, the Hyrax expander was used with a jackscrew (anatomic expander type; Forestadent). There were four bands on the first premolars and first molars (Figure 2).

Both expander screws were activated at a rate of two-quarter turns (180° , 0.5 mm) per day after the appliance had been installed. If a diastema did not appear within 8 days of expansion, the activation was changed to one-quarter turn every 3 days to minimize tissue damage. Four patients were treated with this modified treatment protocol in the Hyrax group. Activation was discontinued when the lingual cusps of the upper first molars contacted the buccal cusps of the lower first molars. The sample was removed from the trial if one or more microimplants became loose. All patients completed active expansion and then the screw was fixed with a ligature wire as a passive retainer. The patients underwent orthodontic treatment with a fixed appliance after 3 months of retention.

Cone beam computed tomography (CBCT) scans and dental casts were obtained before expansion (T1) and 1 week after active expansion (T2). All CBCT scans were obtained with the KaVo 3D eXam device (Imaging Sciences International LLC, Hatfield, PA,

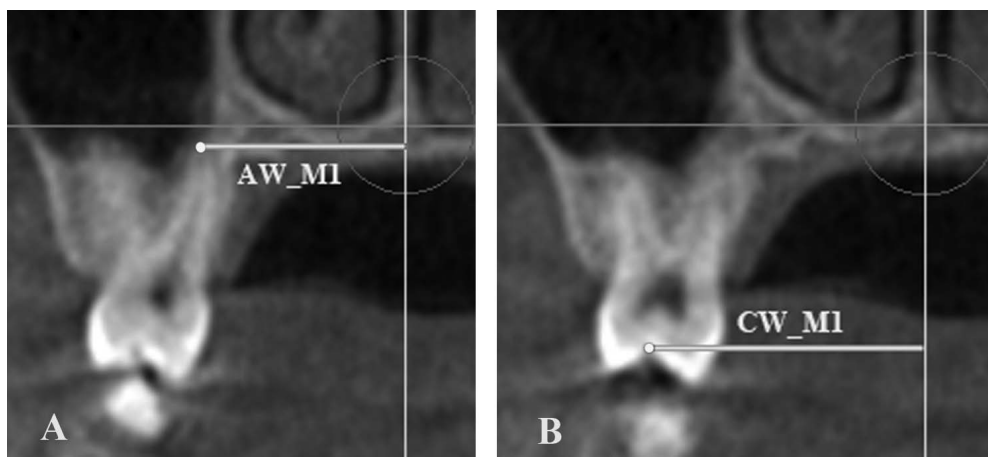


Figure 5. Dental measurement of maxillary first molar. (A) AW_M1 indicates apical width of root of maxillary first molar. (B) CW_M1, crown width of maxillary first molar.

USA). Exposure was performed at 18.54 mA and 120 kV for 8.9 s with a voxel size of 0.3 mm.

Head orientation: All CBCT images were oriented and analyzed using Invivo 5 software (Anatomage, San Jose, CA, USA). The axial plane was defined as the plane that passed through ANS and PNS points and was parallel to the line formed by the right and left orbitale points. The midsagittal plane was defined as the plane perpendicular to the axial plane passing through nasion and basion points. The frontal plane was the plane perpendicular to the axial and midsagittal planes.

Evaluation was performed mainly on two coronal slices and one axial slice. (1) The maxillary first molar coronal plane was produced from the center of the apical regions of the palatal roots of the maxillary first molars (Figure 3). (2) The maxillary first premolar coronal plane was produced from the center of the apical regions of the maxillary first premolars. (3) For

the palatal axial slice, the image was adjusted until the entire suture could be observed (Figure 4). Measurements on CBCT and dental casts are shown in Figures 3 to 8 and described in Table 2.^{21,22} The primary outcome was the ratio of skeletal to dental expansion at the maxillary first molar level (SE_M1/ICW_M1).

Statistical Analysis

Sample size calculation: in a study regarding RPE with tooth-borne expanders, the maxillary width and anchored maxillary first molar width increased by 2.8 mm and 8.9 mm in the late treated group, respectively;⁴ the ratio of skeletal to dental expansion was 31.5%. Calculation of sample size was based on the ability to detect a clinically relevant difference if there was an absolute increase of 15% in the ratio of skeletal to dental expansion between groups (31.5% vs 46.5%; standard deviation: 20%; two-tailed: $\alpha = 0.05$; 80%

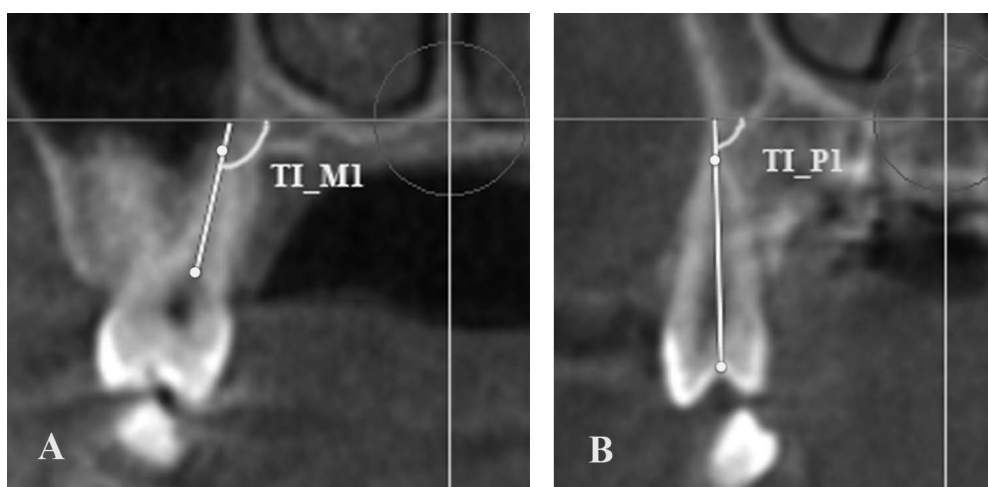


Figure 6. Measurement of tooth inclination. (A) TI_M1, Inclination of maxillary first molar. (B) TI_P1, Inclination of upper first premolar. R and L represent right and left, respectively.

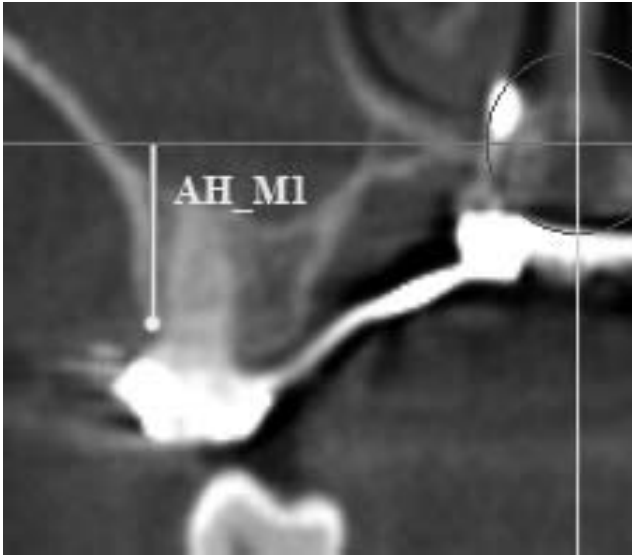


Figure 7. Measurement of alveolar height of maxillary first molar. AH_M1 indicate alveolar height of maxillary first molar; R and L represent right and left, respectively.

power). A minimum sample size of 28 in each group was required; 30 participants per group were included to account for dropouts.

Statistical analyses were performed with SAS software (version 9.2, SAS Inc., Cary, NC, USA). Paired *t*-tests were used to evaluate treatment chang-

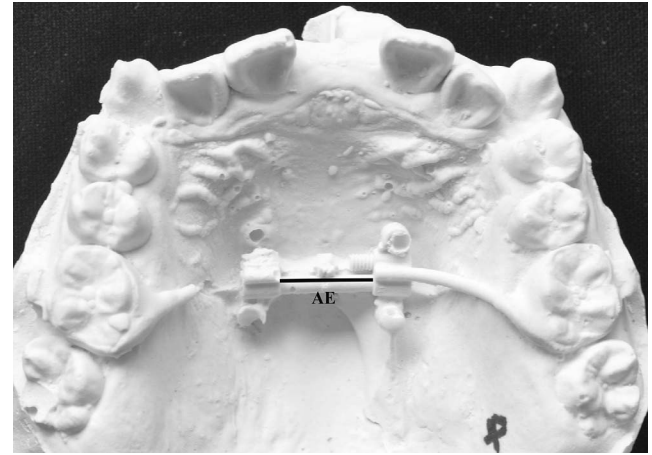


Figure 8. Measurement of appliance expansion.

es. Differences between groups were compared using independent *t*-tests. $P < .05$ was considered to indicate statistical significance.

RESULTS

Skeletal, alveolar, and dental characteristics were similar between the two groups before treatment (Table 3) ($P > .05$). Success of the maxillary expansion was defined as the presence of palatal suture opening on CBCT radiographs after expansion. Four patients (two boys, 15.8 and 17.0 years; and two girls, 16.3 and 17.0

Table 2. Measurements for Transverse Evaluation

Parameter	Definition	
Baseline	Line passing through lowest point at inferior inner contour of the nasal cavity on same side, parallel to axial plane.	
Skeletal		
NW	Nasal width	Distance between right and left inner lateral limits of nasal cavity, parallel to baseline.
MBBW	Maxillary basal bone width	Distance between right and left maxillary basal bone curve points, parallel to baseline; used to determine minimum width of maxilla.
SE	Suture expansion of midpalatal suture	Distance between right and left medial limits of maxillary palatal processes. If edges of midpalatal suture were obscure, they were obtained on palatal axial planes.
SE_ANS	Suture expansion at ANS	Transverse width between anterior nasal spine points of each maxillary half.
SE_PNS	Suture expansion at PNS	Transverse width between posterior nasal spine points of each maxillary half.
Alveolar		
MAW	Maxillary alveolar width	Distance between right and left most coronal points on maxillary alveolar processes, parallel to baseline.
AH	Alveolar height	Distance from most inferior alveolar point at mesiobuccal root of maxillary first molars or at root of first premolars to baseline.
Dental		
IAW	Inter-Apex Width	Apical width of root is distance from right or left root apex point to midsagittal plane (apices of palatine roots of maxillary first molars or apices of roots of maxillary first premolars). Inter-apex width is total of right and left apical widths of root.
ICW	Inter-Crown Width	Crown width of tooth represents distance from right or left central fossa point to midsagittal plane. Inter-crown width is total of right and left crown widths.
TI_M1	Tooth inclination of first molars	Angle formed by line passing through center of palatal orifice from chamber and apex of palatine root of maxillary first molar and baseline.
TI_P1	Tooth inclination of first premolars	Angle formed by line passing through central pit and apex of palatine root of maxillary first premolar and baseline.
Appliance		
AE	Appliance expansion	Total appliance expansion obtained by measuring screw width on dental casts using a caliper.

Table 3. Comparison of Maxillary Transverse Dimensions Before Treatment Between MARPE and Hyrax Groups

	MARPE		Hyrax		<i>t</i>	<i>P</i>
	Mean	SD	Mean	SD		
Skeletal						
NW_M1 (mm)	30.17	2.46	29.34	2.53	1.28	.205
MBBW_M1 (mm)	62.53	4.02	62.92	3.45	-0.40	.687
NW_P1 (mm)	26.37	3.00	25.66	2.55	0.99	.327
MBBW_P1 (mm)	40.69	3.85	40.03	4.47	0.62	.539
Alveolar						
MAW_M1 (mm)	61.66	4.44	60.57	4.22	0.97	.335
AH_M1R (mm)	14.41	2.57	15.24	2.60	-1.25	.216
AH_M1L (mm)	13.94	2.31	14.91	2.49	-1.57	.123
MAW_P1 (mm)	47.52	2.98	46.96	3.17	0.70	.485
AH_P1R (mm)	17.16	3.08	16.41	2.91	0.96	.340
AH_P1L (mm)	16.51	3.10	16.62	2.54	-0.15	.883
Dental						
IAW_M1 (mm)	33.81	2.92	33.07	2.98	0.97	.337
ICW_M1 (mm)	46.87	3.83	45.81	3.51	1.13	.265
TI_M1R (°)	109.76	6.49	109.75	6.93	0.01	.995
TI_M1L (°)	111.23	7.81	108.65	5.21	1.50	.138
IAW_P1 (mm)	34.13	2.74	34.94	3.66	-0.96	.339
ICW_P1 (mm)	35.45	2.72	34.50	2.41	1.42	.160
TI_P1R (°)	92.12	5.50	91.38	6.76	0.46	.647
TI_P1L (°)	91.82	6.56	89.13	6.43	1.60	.114

* $P < .05$.

years, respectively) exhibited failed suture separation in the Hyrax group. The success rate of midpalatal suture opening was higher in the MARPE group (100%) than in the Hyrax group (86.7%) (Table 4) ($P < .05$). The midpalatal suture width was defined as zero before treatment. After active expansion, there were significant increases for all variables involving maxillary width at the skeletal, alveolar, and dental levels in the MARPE (Table 5) and Hyrax (Table 6) groups ($P < .05$).

When both groups were compared, a similar screw expansion produced similar dental expansion of the maxillary permanent first molars. In contrast, the MARPE group showed greater increases of skeletal maxillary width compared to the Hyrax group (Table 7). The ratios of skeletal to screw expansion and of skeletal to dental expansion were nearly twofold greater in the MARPE group than in the Hyrax group (Table 8). No significant differences were observed in the ratios of NW_M1/SE_M1 and NW_P1/SE_P1 between MARPE and Hyrax groups ($P > .05$), which indicated that the rotation center of the zygomatico-maxillary complex was located at the same position (Table 8).

DISCUSSION

Melsen's histological study showed that the suture became interdigitated at 16 years of age for girls and 18 years of age for boys.²³ Another histological study showed that orthopedic force is theoretically effective

Table 4. Distributions of Success and Failure of Palatal Suture Opening

	MARPE	Hyrax	<i>P</i>
Number (n)	30	30	
Range of screw expansion (mm)	5.0-9.1	5.2-9.8	
Midpalatal suture opening			.038*
Success (n)	30	26	
Failure (n)	0	4	
Success rate (%)	100	86.7	

* $P < .05$.

for maxillary expansion in patients up to the age of 20 years who exhibit an obliteration index <0.5 . Suture obliteration exhibits significant variation among individuals.²⁴ The success rate of the midpalatal suture opening was higher in the MARPE group than in the Hyrax group. This agreed with Bishara and Staley's results¹ and previous basic scientific studies.^{23,24} Thus, tooth anchorage may be insufficient to split the earlier interdigitated midpalatal suture during the post-pubertal growth spurt stage.

Transverse changes in the midpalatal suture (2.20 mm) and skeletal to dental ratio (32.3%) at the first molar level in patients treated with the Hyrax were similar to those of previous studies.^{3,4} The ratio of skeletal to dental expansion was approximately twofold higher in the MARPE group (61.4%) than in the Hyrax group (32.2%). This finding was similar to the results of other MARPE studies with patients of the same age and use of the same type of appliance.^{15,16} Similar skeletal to dental expansion ratios were observed in Celenk-Koca et al.'s study, using a bone-borne expander without bands on maxillary molars.¹⁴ The results demonstrated that microimplants in the palate were the main anchorage for splitting the midpalatal suture during the post-pubertal growth spurt period. The amount of suture expansion was greater in the current study (SE_M1: 3.82 mm) than in a previous study.¹⁵ This may have been related to the expander design and maxillary constriction severity. The modified MARPE in the current study was suitable for most patients with severe narrow palatal vaults.

The palatal suture opening was wider in the anterior area and diminished posteriorly, such that the ratio was 51.7% in the Hyrax group. This result was consistent with the findings reported previously.²¹ The ratio of posterior to anterior palatal suture opening in the MARPE group (72.5%) was similar to that reported by Oh et al.¹⁶ However, this result differed from the findings of two previous studies regarding MARPE in which the midpalatal suture was separated in a parallel manner.^{15,18} This discrepancy can be explained by the position of the expander. The center of resistance of the maxilla is located between the first and second

Table 5. Comparison of Maxillary Dimensions Before (T1) and After (T2) Treatment in the MARPE Group (n = 30)

Variable	T1		T2		d		t	P
	Mean	SD	Mean	SD	Mean	SD		
Skeletal								
NW_M1 (mm)	30.17	2.46	32.93	2.42	2.77	0.77	19.56	<.001**
MBBW_M1 (mm)	62.53	4.02	66.40	4.25	3.88	1.17	17.90	<.001**
SE_M1 (mm)	0	0	3.82	0.80	3.82	0.80	25.62	<.001**
NW_P1 (mm)	26.37	3.00	29.42	2.79	3.37	0.87	21.29	<.001**
MBBW_P1 (mm)	40.69	3.85	45.23	4.13	4.53	1.24	20.05	<.001**
SE_P1 (mm)	0	0	4.17	0.96	4.17	0.96	22.10	<.001**
SE_ANS (mm)	0	0	4.39	0.98	4.39	0.98	24.52	<.001**
SE_PNS (mm)	0	0	3.13	0.59	3.13	0.59	29.10	<.001**
Alveolar								
MAW_M1 (mm)	61.66	4.44	65.65	4.06	3.99	1.04	20.94	<.001**
AH_M1R (mm)	14.41	2.57	13.99	2.40	-0.41	0.95	-2.37	.025*
AH_M1L (mm)	13.94	2.31	13.16	2.53	-0.79	0.98	-4.40	<.001**
MAW_P1 (mm)	47.52	2.98	52.27	2.69	4.75	1.21	21.22	<.001**
AH_P1R (mm)	17.16	3.08	16.66	2.94	-0.49	0.89	-2.92	.007**
AH_P1L (mm)	16.51	3.10	16.10	2.96	-0.40	0.92	-2.30	.030*
Dental								
IAW_M1 (mm)	33.81	2.92	37.54	3.19	3.73	1.06	19.33	<.001**
ICW_M1 (mm)	46.87	3.83	53.22	3.71	6.36	1.30	26.72	<.001**
TI_M1R (°)	109.76	6.49	113.58	6.98	3.82	4.07	5.14	<.001**
TI_M1L (°)	111.23	7.81	113.95	8.22	2.72	3.44	4.34	<.001**
IAW_P1 (mm)	34.13	2.74	38.88	2.53	4.75	1.51	17.30	<.001**
ICW_P1 (mm)	35.45	2.72	40.40	2.58	4.95	1.21	22.37	<.001**
TI_P1R (°)	92.12	5.50	92.75	4.90	0.63	2.94	1.18	.248
TI_P1L (°)	91.82	6.56	92.41	5.96	0.59	3.23	1.00	.325

* $P < .05$, ** $P < .01$.**Table 6.** Comparison of Maxillary Dimensions Before (T1) and After (T2) Treatment in the Hyrax Group (n = 30)

Variable	T1		T2		d		t	P
	Mean	SD	Mean	SD	Mean	SD		
Skeletal								
NW_M1 (mm)	29.34	2.53	30.95	2.91	1.61	1.12	7.87	<.001**
MBBW_M1 (mm)	62.92	3.45	64.95	3.82	2.03	1.61	6.90	<.001**
SE_M1 (mm)	0	0	2.20	1.09	2.20	1.09	11.13	<.001**
NW_P1 (mm)	25.66	2.55	27.70	2.67	2.03	1.21	9.22	<.001**
MBBW_P1 (mm)	40.03	4.47	42.39	4.56	2.37	1.81	7.16	<.001**
SE_P1 (mm)	0	0	2.79	1.45	2.79	1.45	10.53	<.001**
SE_ANS (mm)	0	0	3.12	1.60	3.12	1.60	10.72	<.001**
SE_PNS (mm)	0	0	1.57	0.78	1.57	0.78	10.97	<.001**
Alveolar								
MAW_M1 (mm)	60.57	4.22	63.45	4.16	2.88	1.74	9.05	<.001**
AH_M1R (mm)	15.24	2.60	13.69	3.00	-1.56	2.44	-3.49	.002**
AH_M1L (mm)	14.91	2.49	12.97	2.99	-1.95	2.56	-4.17	<.001**
MAW_P1 (mm)	46.96	3.17	50.22	3.46	3.26	1.38	12.91	<.001**
AH_P1R (mm)	16.41	2.91	14.95	3.42	-1.46	1.99	-3.95	.001**
AH_P1L (mm)	16.62	2.54	15.04	2.69	-1.58	2.25	-3.79	.001**
Dental								
IAW_M1 (mm)	33.07	2.98	35.05	2.99	1.98	1.57	6.93	<.001**
ICW_M1 (mm)	45.81	3.51	52.82	3.35	7.02	1.52	25.30	<.001**
TI_M1R (°)	109.75	6.93	116.46	6.37	6.71	4.88	7.53	<.001**
TI_M1L (°)	108.65	5.21	114.53	6.15	5.88	5.44	5.92	<.001**
IAW_P1 (mm)	34.94	3.66	38.38	3.76	3.44	1.59	11.86	<.001**
ICW_P1 (mm)	34.50	2.41	41.58	2.97	7.08	1.80	21.58	<.001**
TI_P1R (°)	91.38	6.76	97.25	7.35	5.86	3.78	8.50	<.001**
TI_P1L (°)	89.13	6.43	95.30	7.98	6.17	3.98	8.49	<.001**

* $P < .05$, ** $P < .01$.

Table 7. Comparison of Immediate Maxillary Changes Between MARPE and Hyrax Groups

	MARPE		Hyrax		<i>t</i>	<i>P</i>
	Mean	SD	Mean	SD		
Skeletal						
NW_M1 (mm)	2.77	0.77	1.61	1.12	4.68	<.001**
MBBW_M1 (mm)	3.88	1.17	2.03	1.61	5.04	<.001**
SE_M1 (mm)	3.82	0.80	2.20	0.19	6.67	<.001**
NW_P1 (mm)	3.37	0.87	2.03	1.21	4.93	<.001**
MBBW_P1 (mm)	4.53	1.24	2.37	1.81	5.26	<.001**
SE_P1 (mm)	4.17	0.96	2.79	1.45	3.95	<.001**
SE_ANS (mm)	4.39	0.98	3.12	1.60	3.71	.001**
SE_PNS (mm)	3.13	0.59	1.57	0.78	8.74	<.001**
Alveolar						
MAW_M1 (mm)	3.99	1.04	2.88	1.74	3.01	<.001**
AH_M1R (mm)	-0.41	0.95	-1.56	2.44	2.39	.022*
AH_M1L (mm)	-0.79	0.98	-1.95	2.56	2.33	.024*
MAW_P1 (mm)	4.75	1.21	3.26	1.38	4.40	<.001**
AH_P1R (mm)	-0.49	0.89	-1.46	1.99	2.36	.022*
AH_P1L (mm)	-0.40	0.92	-1.58	2.25	2.61	.013*
Dental						
IAW_M1 (mm)	3.73	1.06	1.98	1.57	5.07	<.001**
ICW_M1 (mm)	6.36	1.30	7.02	1.52	-1.84	.071
TI_M1R (°)	3.82	4.07	6.71	4.88	-2.49	.016*
TI_M1L (°)	2.72	3.44	5.88	5.44	-2.69	.010*
IAW_P1 (mm)	4.75	1.51	3.44	1.59	3.26	.002**
ICW_P1 (mm)	4.95	1.21	7.08	1.80	-5.38	<.001**
TI_P1R (°)	0.63	2.94	5.86	3.78	-5.98	<.001**
TI_P1L (°)	0.59	3.23	6.17	3.98	-5.96	<.001**
Appliance						
AE (mm)	6.33	1.04	6.98	1.66	-1.78	.081

* $P < .05$, ** $P < .01$.

molars in the sagittal plane.²⁵ The positions of the jackscrew and microimplants in the current study were between the second premolars and first molars to avoid the transverse palatal suture. In contrast, the jackscrews in Zong et al.¹⁵ and Song et al.¹⁸ were located between the maxillary first molars and closer to the center of resistance. A more parallel midpalatal suture opening may be achieved by posterior placement of the expander.^{15,18} The MARPE appliance separated the suture in a more parallel manner, compared to the Hyrax expander, which can also be explained by the more posterior position of jackscrew in the MARPE group than in the Hyrax group. Figure 9 shows a pair of twin sisters (17.6 years of age) who were treated with different expansion modalities. The younger sister was treated with MARPE and the older sister with Hyrax. The midpalatal suture showed different types of openings after active treatment with the same amount of jackscrew expansion.

Changes in inclination of anchored teeth are often produced by a fan-shaped movement of the two maxillary halves, as well as tipping movement in the alveolar bone. In the current study, the amount of buccal tipping of the first molars in the MARPE group (2.72° – 3.82°) was approximately half of the amount in

Table 8. Analysis of Immediate Maxillary Transverse Changes Between MARPE and Hyrax Groups

	MARPE		Hyrax		<i>t</i>	<i>P</i>
	Mean	SD	Mean	SD		
SE_M1/AE	0.610	0.13	0.338	0.15	7.44	<.001**
SE_M1/ICW_M1	0.614	0.13	0.323	0.15	8.13	<.001**
NW_M1/SE_M1	0.718	0.157	0.721	0.305	-0.03	.974
SE_P1/AE	0.665	0.134	0.430	0.210	4.96	<.001**
SE_P1/ICW_P1	0.865	0.169	0.395	0.195	9.44	<.001**
NW_P1/SE_P1	0.766	0.177	0.737	0.237	0.49	.628
PNS/ANS	0.725	0.11	0.517	0.11	7.18	<.001**

* $P < .05$, ** $P < .01$.

the Hyrax group. The change in buccal tipping of the first molar in the MARPE group was similar to the results of MSE in studies by Cantarella et al.¹⁷ and Moon et al.¹⁹ Buccal tipping in first molars was mainly caused by the gap between the microimplant and the tube on the jackscrew, as well as the movement of implants in the bone. No implant deformation was observed after active expansion in the study. Compared with the inclination of the maxillary first premolars without bonds in the MARPE group (caused by V-shaped movement of the maxillary halves), the absolute tipping of first molars in the alveolar bone was negligible.

The reductions in alveolar bone height on the mesiobuccal roots of the first molars were less in the MARPE group (0.41 mm, right side and 0.71 mm, left side) than in the Hyrax group in the current and previous studies.^{5,26} However, Moon et al.¹⁹ reported that the reductions in alveolar bone were greater in the anchorage first molars (1.15 mm and 1.51 mm on the right and left sides, respectively). This difference may have been caused by the measurement method, in that alveolar bone height loss was defined as the distance between alveolar bone and the cemento-enamel junction of the tooth.¹⁹ Extrusion of banded teeth during active expansion increased the value.

CONCLUSIONS

- The MARPE was more predictable and resulted in greater skeletal expansion, compared to the Hyrax expander.
- The skeletal to dental and skeletal to screw ratios were approximately twofold higher in the MARPE group than in the Hyrax group.
- Buccal tipping and buccal alveolar height loss on anchorage teeth were reduced in the MARPE group compared to the Hyrax group.
- These results indicate that MARPE could be a better alternative for patients with skeletal maxillary deficiency during the post-pubertal growth spurt stage.

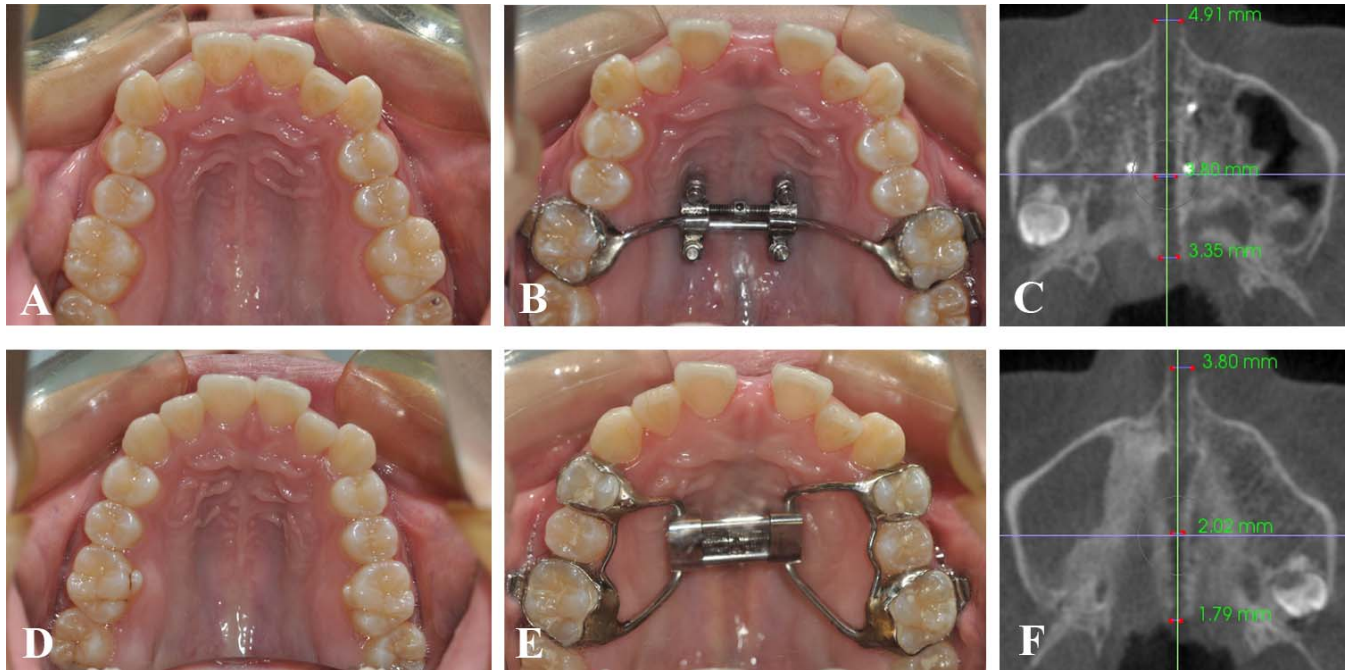


Figure 9. Twin sisters treated with MARPE and Hyrax appliances. (A, B, and C) Younger sister treated with MARPE. (D, E, and F) Older sister treated with Hyrax appliance.

ACKNOWLEDGMENTS

Supported by Scientific Research Common Program of Beijing Municipal Commission of Education (KM201610025022) and Beijing Municipal Science & Technology Commission (Z161100000516202).

REFERENCES

- Bishara SE, Staley RN. Maxillary expansion: clinical implications. *Am J Orthod Dentofacial Orthop.* 1987;91:3–14.
- Bazargani F, Feldmann I, Bondemark L. Three-dimensional analysis of effects of rapid maxillary expansion on facial sutures and bones. *Angle Orthod.* 2013;83:1074–1082.
- Wertz R, Dreskin M. Midpalatal suture opening: a normative study. *Am J Orthod.* 1977;71:367–381.
- Baccetti T, Franchi L, Cameron CG, McNamara JA Jr. Treatment timing for rapid maxillary expansion. *Angle Orthod.* 2001;71:343–350.
- Garib DG, Henriques JF, Janson G, de Freitas MR, Fernandes AY. Periodontal effects of rapid maxillary expansion with tooth-tissue-borne and tooth-borne expanders: a computed tomography evaluation. *Am J Orthod Dentofacial Orthop.* 2006;129:749–758.
- Lione R, Franchi L, Cozza P. Does rapid maxillary expansion induce adverse effects in growing subjects? *Angle Orthod.* 2013;83:172–182.
- Fishman LS. Radiographic evaluation of skeletal maturation. A clinically oriented method based on hand-wrist films. *Angle Orthod.* 1982;52:88–112.
- Revelo B, Fishman LS. Maturation evaluation of ossification of the midpalatal suture. *Am J Orthod Dentofacial Orthop.* 1994;105:288–292.
- Lee KJ, Park YC, Park JY, Hwang WS. Miniscrew-assisted nonsurgical palatal expansion before orthognathic surgery for a patient with severe mandibular prognathism. *Am J Orthod Dentofacial Orthop.* 2010;137:830–839.
- Carlson C, Sung J, McComb RW, Machado AW, Moon W. Microimplant-assisted rapid palatal expansion appliance to orthopedically correct transverse maxillary deficiency in an adult. *Am J Orthod Dentofacial Orthop.* 2016;149:716–728.
- Wilmes B, Nienkemper M, Drescher D. Application and effectiveness of a mini-implant- and tooth-borne rapid palatal expansion device: the hybrid hyrax. *World J Orthod.* 2010; 11:323–330.
- Lin L, Ahn HW, Kim SJ, Moon SC, Kim SH, Nelson G. Tooth-borne vs. bone-borne rapid maxillary expanders in late adolescence. *Angle Orthod.* 2015;85:253–262.
- Lagravère MO, Carey J, Heo G, Toogood RW, Major PW. Transverse, vertical, and anteroposterior changes from bone-anchored maxillary expansion vs. traditional rapid maxillary expansion: a randomized clinical trial. *Am J Orthod Dentofacial Orthop.* 2010;137:304.e1–12.
- Celenk-Koca T, Erdinc AE, Hazar S, Harris L, English JD, Akyalcin S. Evaluation of miniscrew-supported rapid maxillary expansion in adolescents: a prospective randomized clinical trial. *Angle Orthod.* 2018;88:702–709.
- Zong C, Tang B, Hua F, He H, Ngan P. Skeletal and dentoalveolar changes in the transverse dimension using microimplant-assisted rapid palatal expansion (MARPE) appliances. *Semin Orthod.* 2019;25:46–59.
- Oh H, Park J, Lagravère-Vich MO. Comparison of traditional RPE with two types of micro-implant assisted RPE: CBCT study. *Semin Orthod.* 2019;25:60–68.
- Cantarella D, Dominguez-Mompell R, Moschik C, et al. Midfacial changes in the coronal plane induced by microimplant-supported skeletal expander, studied with cone-beam

- computed tomography images. *Am J Orthod Dentofacial Orthop.* 2018;154:337–345.
18. Song KT, Park JH, Moon W, Chae JM, Kang KH. Three-dimensional changes of the zygomaticomaxillary complex after mini-implant assisted rapid maxillary expansion. *Am J Orthod Dentofacial Orthop.* 2019;156:653–662.
 19. Moon HW, Kim MJ, Ahn HW, et al. Molar inclination and surrounding alveolar bone change relative to the design of bone-borne maxillary expanders: a CBCT study. *Angle Orthod.* 2020;90:13–22.
 20. Howe RP, McNamara JA Jr, O'Connor KA. An examination of dental crowding and its relationship to tooth size and arch dimension. *Am J Orthod.* 1983;83:363–373.
 21. Weissheimer A, de Menezes LM, Mezomo M, Dias DM, de Lima EM, Rizzato SM. Immediate effects of rapid maxillary expansion with Haas-type and hyrax-type expanders: a randomized clinical trial. *Am J Orthod Dentofacial Orthop.* 2011;140:366–376.
 22. Christie KF, Boucher N, Chung CH. Effects of bonded rapid palatal expansion on the transverse dimensions of the maxilla: a cone-beam computed tomography study. *Am J Orthod Dentofacial Orthop.* 2010;137:S79–85.
 23. Melsen B. Palatal growth studied on human autopsy material. A histologic microradiographic study. *Am J Orthod.* 1975;68:42–54.
 24. Persson M, Thilander B. Palatal suture closure in man from 15 to 35 years of age. *Am J Orthod.* 1977;72:42–52.
 25. Braun S, Bottrel JA, Lee KG, Lunazzi JJ, Legan HL. The biomechanics of rapid maxillary sutural expansion. *Am J Orthod Dentofacial Orthop.* 2000;118:257–261.
 26. Lemos Rinaldi MR, Azeredo F, Martinelli de Lima E, Deon Rizzato SM, Sameshima G, Macedo de Menezes L. Cone-beam computed tomography evaluation of bone plate and root length after maxillary expansion using tooth-borne and tooth-tissue-borne banded expanders. *Am J Orthod Dentofacial Orthop.* 2018;154:504–516.