

## Evaluation of factors related to the success of miniscrew-assisted rapid palatal expansion

Cibele B. Oliveira<sup>a</sup>; Priscila Ayub<sup>b</sup>; Fernanda Angelieri<sup>c</sup>; Wilson H. Murata<sup>d</sup>; Selly S. Suzuki<sup>e</sup>; Dirceu B. Ravelli<sup>f</sup>; Ary Santos-Pinto<sup>f</sup>

### ABSTRACT

**Objectives:** To evaluate whether the success of miniscrew-assisted rapid palatal expansion (MARPE), performed in patients with advanced bone maturation is related to factors such as midpalatal suture (MPS) maturation, age, sex, or bicortical mini-implant anchorage.

**Materials and Methods:** Twenty-eight cone beam computed tomography (CBCT) scans of adults and post-pubertal adolescents treated by MARPE were included in the sample. CBCT images before (T0) and after expansion (T1) were used to evaluate the skeletal changes and the success or failure of MARPE. Axial images of MPS were extracted from T0 and classified into one of the five maturation stages. The correlation between MARPE success and the factors of age, sex, MPS maturation, and bicortical mini-implant anchorage was investigated.

**Results:** Only the age showed a statistically significant negative correlation with MARPE success and all the skeletal measures. There was an 83.3% success rate among individuals aged 15 to 19 years, 81.8% from 20 to 29 years, and 20% from 30 to 37 years. MPS maturation showed a negative correlation with the expansion effect. Subjects with stages B or C of MPS maturation showed a 100% success rate, followed by stage D (62.5%) and stage E (58.3%).

**Conclusions:** As age increased, there was a decrease in MARPE success and the skeletal effects of maxillary expansion. Sex and bicortical mini-implant anchorage were not shown to be relevant factors. There was no correlation between MPS maturation and MARPE success; however, it was observed that all cases of MARPE failure were classified as stage D or E of MPS maturation. (*Angle Orthod.* 2021;91:187–194.)

**KEY WORDS:** Midpalatal suture maturation; Palatal expansion; Maxilla

### INTRODUCTION

The non-surgical palatal expansion technique supported by miniscrews (MARPE) emerged as a prom-

ising alternative to increase orthopedic changes and avoid undesirable effects in late adolescence and adulthood.<sup>1</sup> Recently, clinical studies have shown better results using MARPE expanders compared to tooth-borne expanders, even in skeletally mature patients.<sup>2–4</sup>

A retrospective clinical study<sup>4</sup> observed a high success rate of 86.96% and 0.07 mm of post-treatment relapse at the intermaxillary width measurement. These results supported MARPE as a clinically acceptable and stable modality of treatment for young adults exhibiting transverse maxillary deficiency. However, the authors also pointed out that maxillary orthopedic expansion may not occur, and this has been attributed to the degree of suture synostosis.<sup>4</sup> A few studies suggested that it might be due to an increase of interdigtation occurring in the midpalatal and circum-maxillary sutures in late adolescence, becoming more rigid as age progresses, mainly around 30 years of age.<sup>4,5</sup>

<sup>a</sup> Private Practice, Paraíba, Brazil.

<sup>b</sup> Private Practice, Mato Grosso do Sul, Brazil.

<sup>c</sup> Private Practice, São Paulo, Brazil.

<sup>d</sup> Private Practice, São Paulo, Brazil.

<sup>e</sup> Adjunct Professor, Department of Orthodontics, São Leopoldo Mandic School and Dental Institute, Campinas, São Paulo, Brazil.

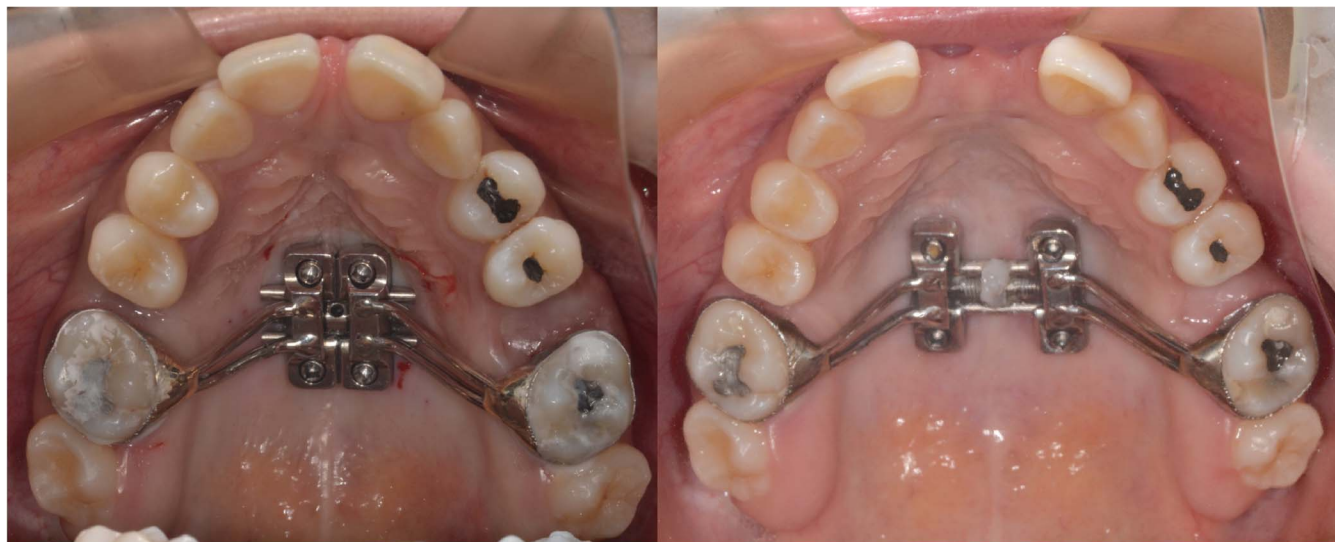<sup>f</sup> Adjunct Professor, Area of Orthodontics, Department of Pediatric Dentistry, São Paulo State University (UNESP), School of Dentistry, Araraquara, Brazil.

Corresponding author: Dra. Cibele Braga de Oliveira, Department of Pediatric Dentistry, São Paulo State University, Av. Humaitá 1680, Araraquara, São Paulo 14801-385, Brazil (e-mail: cibeledonto@yahoo.com.br)

Accepted: October 2020. Submitted: May 2020.

Published Online: December 22, 2020

© 2021 by The EH Angle Education and Research Foundation, Inc.



**Figure 1.** MARPE design with four miniscrews (two anterior: 1.8-mm diameter, transmucosal of 4 mm and 7 mm of thread length and two posterior: 1.8-mm in diameter, transmucosal of 4 mm and 5 mm of thread length).

Persson and Thilander<sup>5</sup> and Angelieri et al.<sup>6</sup> reported that the degree of consolidation in the midpalatal suture exhibits great individual variability and it may not be correlated with chronological age only. Therefore, Angelieri et al.<sup>6</sup> developed a classification of suture maturation based on cone-beam computed tomography (CBCT) images, determining stages from A to E to define the degree of consolidation of the midpalatal suture.

The high degree of suture consolidation in adults undergoing MARPE may result in a large magnitude of force experienced by mini-implants that support the expander. With the intention of increasing MARPE success, it was suggested that bicortical mini-implant anchorage rather than monocortical anchorage may be warranted, justified by the improvement in mini-implant stability.<sup>7</sup>

Factors related to a prediction of MARPE success are in need of further clarification. Therefore, the present study aimed to evaluate whether MARPE success in mature patients was related to factors such as midpalatal suture (MPS) maturation, age, sex, and bicortical mini-implant anchorage.

## MATERIALS AND METHODS

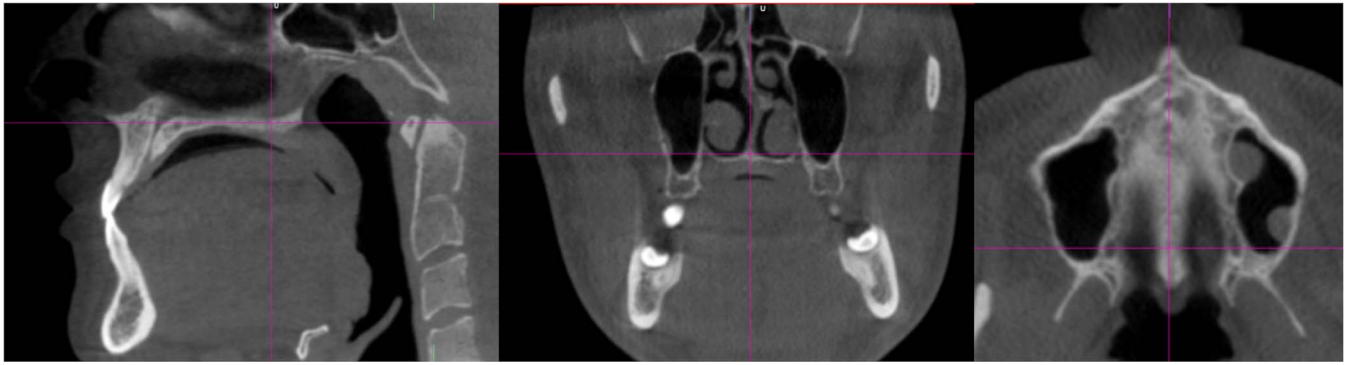
This retrospective study was approved by the ethics committee of the São Paulo State University, School of Dentistry, Araraquara, Brazil. Twenty-eight patients were included who were between 15 and 37 years of age (10 men and 18 women), with transverse maxillary deficiency, that were treated by MARPE in two clinical centers: Dental and Research Dentistry Center CO-ESP (João Pessoa, Paraíba, Brazil) and São Paulo State University (Araraquara, São Paulo, Brazil).

Sample size analysis performed for a group of 28 individuals with an alpha of 0.05 resulted in 96.9% of power for two-tailed *t*-test and effect size of 0.8 and 79.9% for correlation test and effect size of 0.5 (G\*Power version 3.0.10, University of Kiel, Germany). The inclusion criteria were: patients with records of CBCT before (T0) and after MARPE expansion (T1), post-pubertal adolescents (at least CS4 of the cervical vertebrae maturation method), and adults exhibiting unilateral or bilateral posterior crossbite. Individuals who had undergone previous orthodontic treatment or who were showing severe facial deformities and syndromes were excluded.

The MARPE appliance consisted of an expander device supported by four orthodontic miniscrews (Peclab, Belo Horizonte, Minas Gerais, Brazil) (Figure 1). The activation protocol was 2/4 turns immediately after mini-implant placement and 2/4 turn daily (varying from 14 to 18 days) until full transverse correction was achieved. To retain the expansion achieved, the appliance was kept in place without further activation for 4 months.

CBCT scans were taken using the i-CAT Next Generation (Imaging Sciences International, Hatfield, PA) with 13 × 16-cm field of view, 0.25-mm voxel size, 36 mAs and 120 kVp exposure conditions. The data were exported in the digital image and communication in medicine (DICOM) format and analyzed using NemoStudio software (NEMOTEC, Madrid, Spain).

T0 images were used to determine the MPS maturational stages of the patients, according to Angelieri et al.<sup>6</sup> (Figure 2).



**Figure 2.** Orientation planes for axial transverse slice standardization for MPS maturation analysis.

The T0 and T1 images were oriented as shown in Figure 2 to perform the skeletal transverse measurements (Table 1) in both anterior (AP) and posterior regions of the palate (PP) to quantify palatal expansion (Figure 3A,B). In the axial cross-section passing through the infraorbital foramina, a measurement was made to quantify expansion on midface (Figure 3C,D). Maxillary changes were obtained by calculating the difference between the linear measurements (T1-T0).

To assess bicortical mini-implant anchorage in the palate and the nasal cavity floor, the sagittal and coronal cross-sections at T1 were adjusted to pass through the long axis of each mini-implant. For each individual, the number of mini-implants with bicortical anchorage was observed to evaluate a relationship to MARPE performance regarding the opening of the midpalatal suture.

MARPE success was considered to be when a MPS split was observed at T1 and significant posterior expansion greater than 1 mm was achieved (group O). Failure of the treatment was defined when no MPS split was seen (group F). Cases of skeletal transverse expansion at the posterior palate (PP) equal or less than 1.0 mm were considered as a limited result (group L) and, therefore, were not considered successful cases. Patients were divided into 3 age groups from 15 to 19 years, 20 to 29 years, and 30 to 37 years old; by sex (male or female); according to MPS maturational stages; and by whether there was bicortical anchorage of 4, 2, or no mini-implants (yes, half, or no, respectively).

**Table 1.** Skeletal Transverse Measures

Measure	Definition
Anterior palate (AP)	Distance between the most external lateral walls of the incisive foramen
Posterior palate (PP)	Distance between the most external point of side walls of greater palatine foramina
Midface (MIF)	Distance between the most external point of side walls of infraorbital foramina.

To enable sample blinding, examiner ASP encoded the CT scans, examiner CBO was responsible for the skeletal measurements, and examiner FA classified sutural maturation. For method error, 28 blinded images (T0) were re-analyzed by the same examiner 15 days later. The Kappa test was used to evaluate MPS maturation consistency and intraclass correlation coefficient (ICC), complemented by a paired t-test, was used to evaluate the quantitative method reliability.

Data distribution was checked with the Kolmogorov-Smirnov and Shapiro-Wilk tests. Mean, standard deviation, minimum, and maximum values were calculated for the quantitative variables with normal distributions.

Associations between MARPE success, skeletal measures (MIF, PP, AP) and the intervening factors (sex, age, MPS maturation, and bicortical mini-implant anchorage) were evaluated using the Pearson correlation test. For this analysis, MPS maturation was recoded as sequential ordinal numbers (A to E were recoded as 1 to 5).

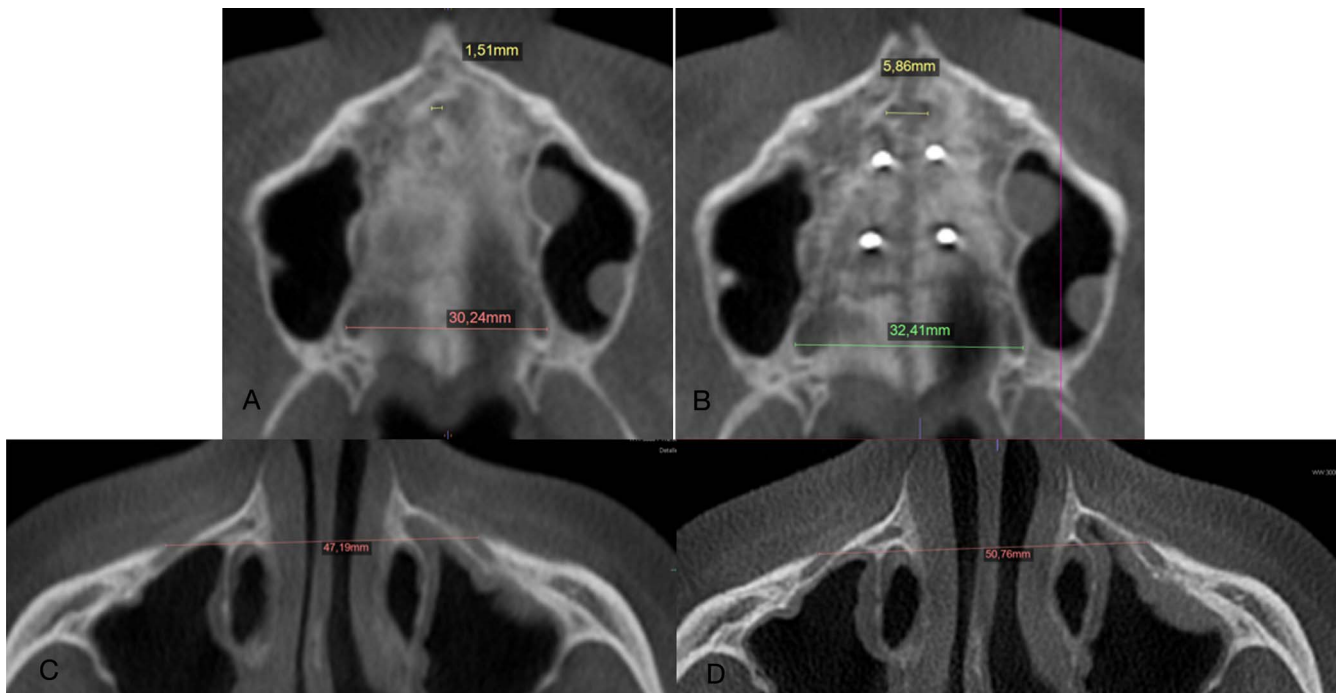
Analysis of variance (ANOVA) was used to detect skeletal change differences among the opening, limited opening, and opening failure groups. Tukey post hoc test was used to identify differences between groups. The level of statistical significance for all tests was  $P < .05$ . SPSS version 16.0 for Windows (release 16.01, Nov. 2007; SPSS Inc., Chicago, IL, USA).

**RESULTS**

The Kappa test result showed substantial agreement for MPS classification method according to Landis and Koch<sup>8</sup> (0.742 with a confidence interval ranging from 0.546 to 0.938 and weighted Kappa = 0.843). ICC showed excellent intra-examiner reproducibility for linear measurements (ICC: 0.92; maximum mean variation was 0.14 mm).

According to the Pearson’s correlation test, chronological age was a good predictor of MARPE success showing a negative correlation, meaning that greater





**Figure 3.** Axial slice passing through palatine process center before and after expansion (AP reference points in yellow and PP in green and red). Axial slice passing through infraorbital foramina before and after expansion (MIF indicates measurement between infraorbital foramens).

ages were associated with decreased chances of MARPE success and a lower amount of MPS opening and skeletal expansion (Table 2). The overall sample showed a 71.4% success rate. The success rate decreased with increased age (Table 3).

MPS maturation was negatively correlated with the amount of MPS opening when it was considered as 3 groups (O, L, and F groups), but not with MARPE success (group O) or with the skeletal measures (Table 2). For all individuals in the B and C stages of maturation, MPS opening was achieved, representing 100% success. The success rate decreased as MPS maturation increased (Table 3).

There were no differences in success between males and females, and sex was not correlated to any of the other measured variables (Table 2). Male and female patients showed success rates of 80.0% and 66.1%, respectively. Despite the mean age for

males being younger, the difference in ages between male and female participants was not statistically significant (Table 4).

Bicortical mini-implant anchorage had no correlation with MARPE success or any of the skeletal measures (Table 2). The highest success rate for suture opening was in cases without bicortical anchorage of the four mini-implants (80%) (Table 3). The cases with four and two bicortical mini-implants had success rates of 70.5% and 66.6%, respectively (Table 3). The individuals were older (mean age: 23.3; SD: 7.5) in the four bicortical mini-implant group than the two bicortical mini-implant group (mean age: 22.5; SD: 6.4) and the group without bicortical anchorage (Mean age: 22.6; SD: 6.8).

Table 5 shows that both the F and L groups showed minimal changes in skeletal measurements due to expansion with a mean value ranging from 0.1 to 0.2

**Table 2.** Correlation Between MARPE Success, Skeletal Measurements, MPS Opening Results, and Intervening Factors (n = 28)<sup>a,b</sup>

Variable	MPS Opening	Success	MIF	PP	AP
Age	-0.45*	-0.49**	-0.41*	-0.39*	-0.38*
Sex	0.01 ns	-0.14 ns	0.08 ns	0.11 ns	0.09 ns
MPS maturation	-0.40*	-0.37 ns	-0.24 ns	-0.35 ns	-0.26 ns
MPS opening		0.92**	0.69**	0.77**	0.71**
Mini-implant bicortical anchorage	-0.16 ns	-0.06 ns	-0.13 ns	-0.22 ns	-0.25 ns
Success	0.92**		0.70**	0.76**	0.70**

<sup>a</sup> AP indicates anterior region of the palate; MARPE, miniscrew-assisted rapid palatal expansion; MIF, measurement between infraorbital foramens; MPS, midpalatal suture; ns, nonsignificant; PP, posterior regions of the palate.

<sup>b</sup> Pearson correlation (r); \* Significant correlation  $P < .05$  (bilateral). \*\* Significant correlation  $P < .01$  (bilateral). Not significant correlation  $P > .05$  (bilateral).

**Table 3.** Descriptive Statistics of Categorical Independent Variables

Midpalatal Suture (MPS) Opening		Opening		Limited	Failure	Success Rate %
Variables	n	>1 mm, Group O (n)	≤ 1 mm, Group L (n)	Opening, Group F (n)	opening, Group F (n)	
<b>Sex</b>						
Male	10	8	0	2		80.0
Female	18	12	5	1		66.7
<b>MPS maturational stages</b>						
B	3	3	0	0		100
C	5	5	0	0		100
D	8	5	3	0		62.5
E	12	7	2	3		58.3
<b>Age</b>						
15 to 19	12	10	2	0		83.3
20 to 29	11	9	0	2		81.8
30 to 39	5	1	3	1		20.0
<b>Mini-implant bicortical anchorage</b>						
Yes	17	12	2	3		70.5
Half	6	4	2	0		66.6
No	5	4	1	0		80.0
Total	28	20	5	3		71.4

mm for the F group and from 0.8 to 1.2 mm for the L group. On the contrary, a greater increase in all skeletal transverse measurements was found in the O group ( $P < .05$ ) compared to the L and F groups. The successful cases were mostly found in younger patients compared to the failure cases.

The mean skeletal expansion in successful cases (group O) was similar for age groups 15 to 19 years and 20 to 29 years, but it was lower for the age group, 30 to 39 years (Table 6). Comparing the skeletal effects in the successful cases according to the maturation stage of MPS, it was observed that there was a similar amount of expansion in the midface (MIF) as in the anterior and posterior portion of the palate (AP and PP measurements) (Table 7).

**DISCUSSION**

MARPE can be a clinically viable and stable treatment modality for adults with transverse maxillary deficiency, showing a success rate of 86.9% for individuals between 18 and 28 years old.<sup>4</sup> The success rate in the current study was 71.4%, which was lower than that reported in a previous study.<sup>4</sup> This difference may be explained by the fact that, in the current study, success was considered as achieved only in cases exhibiting significant MPS opening and skeletal effects (group O); those showing a limited result were considered another distinct group (group L). Out of the 28 patients treated in this study, there were three failure cases showing non-opening of the MPS and no changes in skeletal measurements and five cases that exhibited limited suture opening with minor maxillary expansion.

**Table 4.** Sample Characteristics, Descriptive Statistics and Comparative Student's *t*-Test for Sex<sup>a</sup>

Sex	N	Mean (age)	SD	<i>t</i> -Test, <i>P</i>
Male	10	21.7	4.7	.400 <sup>ns</sup>
Female	18	23.7	7.7	

<sup>a</sup> ns indicates not significant;  $P > .05$ .

In the present study, there was a decrease in the MARPE success rate as the patient's chronological age increased, as shown by the correlation test. Although the average age of successful cases (20.9 years old) was statistically lower than for the failure cases (28.0 years old), age should not be considered as the only prognostic factor for MARPE success since it was possible to achieve MPS separation in older individuals. Persson and Thilander,<sup>5</sup> in a histological study, observed that, in most of the evaluated subjects, an increase in the MPS ossification was found with advancing age, mainly around 30 years old. However, great individual variability was observed in the level of MPS consolidation, suggesting that a suitable prediction of MARPE success cannot be determined by chronological age alone.

The results of the current study showed no statistically significant correlation between sex and success of MARPE therapy, agreeing with Choi et al.<sup>4</sup> Also, Cantarella et al.<sup>9</sup> showed no correlation between sex and the magnitude of expansion or the rate of separation of the pterygopalatine suture achieved by a maxillary skeletal expansion (MSE) device. Large interindividual variations in MPS consolidation could be the reason why there was no correlation between sex and MARPE success.

Upon evaluating MPS maturation as a predictor for MARPE success, conflicting results were found with no overall correlation. This was confirmed by observing that cases of MARPE success (group O) were present in individuals at all MPS maturational stages (Table 3). Despite that, a negative correlation was found between MPS maturation when all three degrees of the effects of MPS opening (Group O = opening > 1 mm, group L = limited opening < 1 mm, and group F = failure opening) were considered. This showed that the degree of MPS maturation may have influenced the MARPE expansion results, meaning that lower MPS maturation was associated with a higher likelihood of greater opening > 1 mm. Cases of limited expansion (group L) occurred in individuals with MPS maturational stages D or E, whereas failures (group F) appeared only in subjects exhibiting stage E (Table 3). These findings would be expected since stage D indicated a MPS consolidation only in the palatine bone. Doctors should be aware that the least skeletal effects resulting from maxillary expansion would be expected in those

**Table 5.** Maxillary Skeletal Changes and Age According to the Results of Midpalatal Suture (MPS) Opening<sup>a,b</sup>

Expansion Effect	Group O MPS Opening >1 mm					Group L MPS Limited Opening ≤1mm					Group F Failure Opening					ANOVA P
	N	Mean	SD	Min	Max	N	Mean	SD	Min	Max	N	Mean	SD	Min	Max	
Age	20	20.9 <b>A</b>	5.3	15	34	5	28.6 <b>AB</b>	8.8	17	37	3	28.0 <b>B</b>	2.9	24	31	<b>.023</b>
Expansion (mm)																
MIF	20	2.7 <b>B</b>	1.1	1.1	5.3	5	0.8 <b>A</b>	0.3	0.4	1.4	3	0.2 <b>A</b>	0.3	-0.1	0.7	<b>0</b>
PP	20	2.5 <b>C</b>	0.8	1.4	4.3	5	0.9 <b>B</b>	0.2	0.5	1.0	3	0.1 <b>A</b>	0.1	0.0	0.2	<b>0</b>
AP	20	3.4 <b>C</b>	1.3	1.9	6.1	5	1.2 <b>B</b>	0.3	0.9	1.7	3	0.1 <b>A</b>	0.1	-0.1	0.3	<b>0</b>

<sup>a</sup> The level of significance adopted for the rejection of the hypotheses examined was P < .05. Tukey post hoc test = capital letters across lines.  
<sup>b</sup> AP indicates anterior region of the palate; MIF, measurement between infraorbital foramens; PP, posterior regions of the palate.

patients with the largest areas of MPS consolidation. However, it should also be considered that sample size for the failure (n = 3) and limited opening (n = 5) groups were low. For all subjects in the B and C MPS maturational stages, MPS opening with expansion > 1 mm was achieved. These findings were in agreement with those of Shin et al.<sup>10</sup> who showed significant negative correlations between the MPS opening ratio and MPS maturation for young adults (from 18 to 36 years of age) treated by MARPE.

On the other hand, of the 20 successful cases, seven of them were at stage E and five at stage D of MPS maturation (Table 3). Particular characteristics that may have favored success were the partial consolidation of the MPS or the younger age observed in some of these patients. A study<sup>11</sup> of the midpalatal suture that evaluated 28 human palate specimens with micro-CT from individuals aged 14 to 71 showed a mean obliteration index that was generally low. This result supported the histological study of Persson and Thilander<sup>5</sup> that rarely found any marked degree of closure until 30 years of age. Additionally, Persson and Thilander<sup>5</sup> speculated that conventional RPE may disrupt the MPS with a melding index below 5%. Possibly, the force produced by MARPE was able to overcome a small consolidation area of the MPS in the maxillary or palatine bones mainly in younger patients, resulting in successful expansion in MPS maturation groups classified as being in the D or E stages. In addition, other related factors should be investigated to better explain these successful cases.

When a continuous biological process is approximated by assigning ordinal values such as MPS

maturational stages, it may be common to find some patients in intermediate stages such as D-E stages (MPS consolidation may have only started in maxillary bone) showing contradictory outcomes. This was noted while evaluating reproducibility of identifying MPS maturation (weighted Kappa = 0.843) where there was 82.1% agreement between the first and second evaluations. Additionally, Suzuki et al.<sup>12</sup> indicated that there were limitations of CBCT to identify small bridges of closure of the MPS, especially considering the calibration and resolution of modern imaging thresholds.

Additionally, no correlation was found between the magnitude of skeletal expansion observed and the stage of MPS maturation (Table 2). As shown in Table 7, the successful cases with different MPS maturation from C to E, showed the same amount of skeletal expansion when measured in the midface, anterior, and posterior palate. These results demonstrated that maxillary expansion of the same magnitude would occur regardless of the MPS maturational stage as long as the MARPE was able to overcome MPS resistance. This seems potentially to be a great clinical advantage of MARPE compared to conventional rapid maxillary expansion.

The ability to overcome heavy forces during expansion is also linked to the stability of the mini-implants used. Lee et al.<sup>7</sup> claimed that bicortical mini-implant anchorage improved expansion, explained by an increase in mini-implant stability and decreased mini-implant deformation and fracture. However, the present study found no correlation between bicortical mini-implant anchorage and MARPE success. Probably,

**Table 6.** Skeletal Changes in Successful Cases (Group O: MPS Opening > 1 mm) According to Age<sup>a</sup>

Age	15-19					20-29					30-39				
	N	Mean	SD	Min	Max	N	Mean	SD	Min	Max	N	Mean	SD	Min	Max
Expansion (mm)															
MIF	10	2.8	1.0	1.7	4.9	9	2.8	1.4	1.1	5.3	1	1.8	-	-	-
PP	10	2.5	0.7	1.5	4.0	9	2.8	1.1	1.4	4.4	1	2.0	-	-	-
AP	10	3.3	1.2	1.9	5.6	9	3.8	1.7	1.9	6.2	1	2.6	-	-	-

<sup>a</sup> AP indicates anterior region of the palate; MIF, measurement between infraorbital foramens; MPS, midpalatal suture; PP, posterior regions of the palate.

**Table 7.** Skeletal Changes in Successful Cases (Group O: MPS Opening > 1 mm) According to Midpalatal Suture (MPS) Maturation<sup>a</sup>

MPS Maturation Stage	B					C					D					E				
	N	Mean	SD	Min	Max	N	Mean	SD	Min	Max	N	Mean	SD	Min	Max	N	Mean	SD	Min	Max
Age	3	24.0	8.7	18.0	34.0	5	19.2	4.9	15.0	25.0	5	20.0	4.7	15.0	26.0	7	21.4	5.6	15.0	28.0
Expansion (mm)																				
MIF	3	2.7	0.7	1.8	3.2	5	2.7	1.4	1.5	4.9	5	2.8	0.7	2.0	3.6	7	2.8	1.5	1.1	5.3
PP	3	2.6	0.5	2.0	3.1	5	2.8	1.3	1.6	4.4	5	2.4	0.4	1.9	3.0	7	2.5	1.0	1.4	4.2
AP	3	3.3	0.7	2.6	3.9	5	3.6	2.1	1.9	6.1	5	3.2	0.9	2.2	4.0	7	3.6	1.7	1.9	6.2

<sup>a</sup> AP indicates anterior region of the palate; MIF, measurement between infraorbital foramens; PP, posterior regions of the palate.

other factors may have influenced the difference in the results of this clinical study when compared to the laboratory study performed using finite element simulation.<sup>7</sup> Therefore, it would be important to assess in future studies whether the amount of bone anchorage thickness<sup>8</sup> or density would be a factor responsible for ensuring the stability of mini-implants and success of the MARPE technique.

The influence of the skeletal pattern and skull morphology,<sup>13</sup> as well as the pterygopalatine suture and the circum-maxillary sutures as regions of resistance to the orthopedic forces transmitted by maxillary skeletal expanders, have all been noted as factors that may affect the results of MARPE. Although the vertical skeletal pattern and anteroposterior skeletal classification did not show statistically significant correlations in the study by Shin et al.,<sup>10</sup> it was suggested that those variables should be examined further in a future study with a larger sample size.

Based on the current results, it should be expected that there will be individual variability in the results of MARPE and that chronological age may not be the only factor influencing the prognosis of this therapeutic procedure. Although MPS maturation was not significantly correlated to MARPE success, more studies with a larger sample in each group will be necessary to understand what factors may be related to expansion failures. To predict the expected outcome of MARPE expansion more reliably, it is important to study other factors that may be associated with the success or failure of the MPS opening in MARPE therapy.

One of the limitations of the current study was its retrospective design, in which a convenience sample was used and a small number of patients was allocated to each group. For this reason, generalizations to other populations should be made with caution.

## CONCLUSIONS

- Chronological age was negatively correlated to MARPE success. MARPE showed high predictability of success in younger patients, with lower rates of success in patients older than 30 years.
- Sex and bicortical mini-implant anchorage were not correlated to MARPE success.

- The pattern of opening of the MPS (opening > 1 mm, limited opening ≤ 1 mm and failure opening) showed a negative correlation with MPS maturation.
- There was no correlation between MPS maturation and MARPE success. However, it was observed that the unfavorable cases were restricted to individuals in stage D or E of MPS maturation.

## REFERENCES

1. Moon SH, Park SH, Lim WH, Chun YS. Palatal bone density in adult subjects: implications for mini-implant placement. *Angle Orthod.* 2010;80:137–144.
2. Lin L, Ahn HW, Kim SJ, Moon SC, Kim SH, Nelson G. Tooth-borne vs bone-borne rapid maxillary expanders in late adolescence. *Angle Orthod.* 2015;85:253–262.
3. Lee KJ, Park YC, Park JY, Hwang WS. Miniscrew-assisted nonsurgical palatal expansion before orthognathic surgery for a patient with severe mandibular prognathism. *Am J Orthod Dentofacial Orthop.* 2010;137:830–839.
4. Choi SH, Shi KK, Cha JY, Park YC, Lee KJ. Nonsurgical miniscrew-assisted rapid maxillary expansion results in acceptable stability in young adults. *Angle Orthod.* 2016; 86:713–720.
5. Persson M, Thilander B. Palatal suture closure in man from 15 to 35 years of age. *Am J Orthod.* 1977;12:42–52.
6. Angelieri F, Cevidanes LHS, Franchi L, Gonçalves JR, Benavides E, McNamara JA. Midpalatal suture maturation: Classification method for individual assessment before rapid maxillary expansion. *Am J Orthod Dentofacial Orthop.* 2013; 144:759–769.
7. Lee RJ, Moon W, Hong C. Effects of monocortical and bicortical mini-implant anchorage on bone-borne palatal expansion using finite element analysis. *Am J Orthod Dentofacial Orthop.* 2017;151:887–897.
8. Landis JR, Koch GG. The measurement of observer agreement for categorical data. *Biometrics.* 1977;33:159–174.
9. Cantarella D, Dominguez-Mompell R, Mallya SM, et al. Changes in the midpalatal and pterygopalatine sutures induced by micro-implant-supported skeletal expander, analyzed with a novel 3D method based on CBCT imaging. *Prog Orthod.* 2017;18:34.
10. Shin H, Hwang CJ, Lee KJ, Choi YJ, Han SS, Yu HS. Predictors of midpalatal suture expansion by miniscrew-assisted rapid palatal expansion in young adults: a preliminary study. *Korean J Orthod.* 2019;49:360–371.
11. Korbmayer H, Schilling A, Püschel K, Amling M, Kahl-Nieke B. Age-dependent three-dimensional microcomputed to-

- mography analysis of the human midpalatal suture. *J Orofac Orthop.* 2007;68:364–376.
12. Suzuki H, Moon W, Previdente LH, Suzuki SS, Garcez AS, Consolaro A. Miniscrew-assisted rapid palatal expander (MARPE): the quest for pure orthopedic movement. *Dental Press J Orthod.* 2016;21:17–23.
  13. Cantarella D, Dominguez-Mompell R, Mallya SM, et al. Midfacial changes in the coronal plane induced by microimplant-supported skeletal expander, studied with cone-beam computed tomography images. *Am J Orthod Dentofacial Orthop.* 2018;154:337–345.