



Case Report

Incarcerated 5-mm Port Site Hernia: A Systematic Literature Review and Case Report

Elzerie de Jager, Gordon Wing, Yik-Hong Ho

Mater Hospital Townsville, Townsville, Queensland, Australia

Background: Port site hernias are a recognized complication of laparoscopic surgery and carry a high risk of strangulation because of the small size of the defect involved. Most hernias occur in trocar sites that are larger than 10 mm. This has resulted in the accepted practice that fascial defects larger than 10 mm are closed, incorporating the peritoneum and fascia, whereas defects less than 10 mm are not closed.

Results: We report a port site hernia at a 5-mm port site in a 90-year-old woman after ventral rectoplexy. A systematic review of literature found 27 cases of 5-mm port site herniation: 10 cases in general surgery and 17 cases in gynecological surgery.

Conclusion: The possibility of herniation through 5-mm port sites should be known to avoid a delay in recognition, diagnosis, and treatment.

Key words: Laparoscopic surgery – Port site hernias – Surgical complications

The incidence of trocar site hernias ranges from 0.65% to 2.8%.¹ The rates are related to trocar size.² A meta-analysis of port site hernias in gastrointestinal surgery found that 18 hernias occurred in 1780 port sites larger than 10 mm, whereas no hernias occurred at the 4444 ports sites smaller than 10 mm.³ It is widely accepted that it is not necessary to close fascial defects in adults in port sites <10 mm.⁴ We present a case report of a 5-mm trocar site hernia.

Case Report

A 90-year-old woman underwent ventral rectoplexy after a 2-week history of full-thickness rectal

prolapse. A 10–12 Hassan umbilical port was inserted, followed by three 5-mm ports in the right upper quadrant, left flank, and suprapubic regions. There was extensive adhesiolysis (secondary to previous midline exploratory laparotomy for appendicitis and laparoscopic-assisted vaginal hysterectomy). The total operative time was 120 minutes. The 10- to 12-mm port site fascia was closed using 1-0 Vicryl with a Karta Thompson laparoscopic suture passer, and the anterior rectus sheath was closed with interrupted 1-0 Maxon sutures. The 5-mm incisions were not closed at the fascial level. All sites were closed using INSORB 3-0 monocryl subcuticular sutures. The patient's recovery was unremarkable.

Corresponding author: Elzerie de Jager, MBBS (Hons 1), The James Cook University Clinical School, The Townsville Hospital, Townsville, Queensland 4814, Australia.

Tel.: +61747813423; E-mail: elzerie.dejager@my.jcu.edu.au

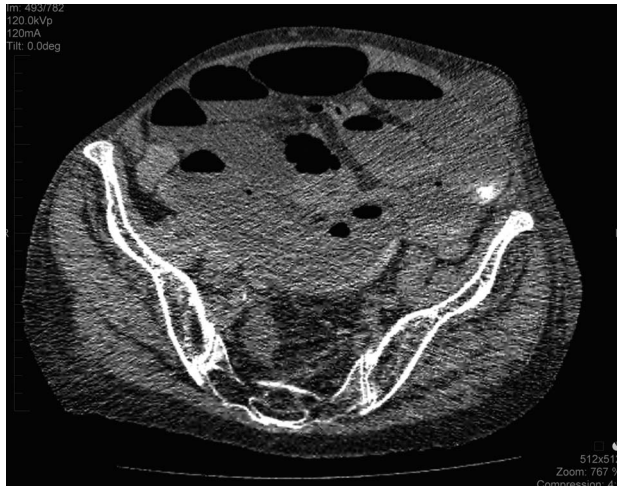


Fig. 1 Axial computer topography images of the patient on postoperative day 5. A hernia can be visualized in the left iliac fossa at her left flank laparoscopic port site.

As an inpatient, at postoperative day 5, the patient reported abdominal pain and vomiting and had not opened her bowels in the preceding 24 hours. On examination, she was afebrile, with a distended abdomen and a tender palpable mass at her left flank port site. A computed tomography scan was performed, which suggested a small bowel obstruction from an incarcerated hernia in the left iliac fossa (Figs. 1 and 2). An emergency laparotomy identified the hernia, and the defect was enlarged transversely. The erythematous, not edematous, bowel was reduced, and the hernial orifice closed with 1-0 interrupted mattress sutures Polydioxanone (PDS), mass closure of abdominal wall, and subcuticular INSORB 3-0 monocryl sutures. The patient was admitted to the intensive care unit postoperatively for 3 days and then discharged to the ward for postsurgical optimization before her return to independent living.

Literature Review

A literature search was conducted in Ovid and Cochrane databases using the following search strategy: ((Port site hernia) OR (Laparoscopic port hernia) OR (trocar site hernia)) AND ((5-mm) OR (5mm) OR (five mm)). The date last searched was 29 May 2016. Reference lists of relevant studies were searched by hand to identify additional publications. Studies were excluded if they were not written in English or did not specify port size. Studies

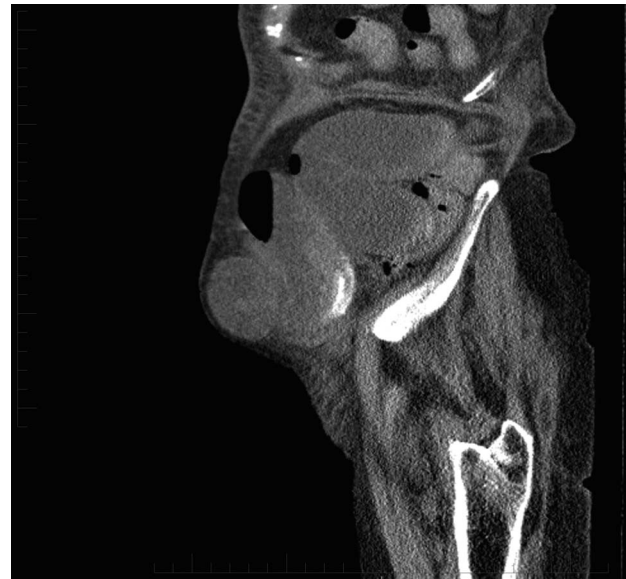

Fig. 2 Sagittal computer topography images of the patient on postoperative day 5. A hernia can be visualized in the left iliac fossa at her left flank laparoscopic port site.

included reported laparoscopic port site hernias in an adult population.

Data were extracted on the surgical specialty, type of operation, port size and type where available, port site, patient characteristics (age, body mass index), time from surgery to hernia presentation, presence of organ evisceration in hernia, management of the hernia, and any comments on the case.

Databases and reference lists searched yielded 358 articles, and the full text of 105 studies were examined. Based on the inclusion and exclusion criteria, 20 studies were included (Tables 1–3). One study was a retrospective review, 1 was a prospective cohort study, and the remaining 18 were case reports.

There were 27 cases of 5-mm trocar site hernias. There were 10 cases in general surgery: 9 case reports and 1 case in a prospective cohort trial. There were 17 cases in gynecological surgery: 12 case reports and 5 cases in a retrospective cohort trial.

Discussion and Conclusion

Surgical factors contributing to the development of hernias include the number of trocars, trocar size, location, trocar type, manipulation, the duration of procedure, drain positioning through the port sites,

Table 1 General surgery case reports

Study	Operation (laparoscopic)	Port size (mm)	Age (yr)/BMI (kg/m ²)	Site	Delay after laparoscopy (days)	Evisceration	Management	Comments
Abdel-Halim <i>et al</i> ⁷	Appendectomy	5	44	Left iliac fossa port	6	SI	Laparoscopic reduction and repair of incision	Previous drain site
Coda <i>et al</i> ⁸	Cholecystectomy	5	62/>30	Right lateral trochanter	2 years	Omentum	Laparoscopic reduction and repair of incision	COPD, incidental finding while reducing hernia as 10-mm port site
Dulskas <i>et al</i> ⁵	Cholecystectomy	5	63/36	Right subcostal margin		SI	Midline laparotomy	
Fleming and Winter ⁹	Right hemicolectomy	5	63/>30	Right iliac fossa	21	SI (Richter's hernia)	Laparotomy	Cecal carcinoma
Matter <i>et al</i> ¹⁰	Cholecystectomy	5		Right upper quadrant	10	Richter hernia		Reinsertion of cannula may widen initial fascial defect
Mehmet ¹¹	Cholecystectomy	5	58	Right upper quadrant	5	Meckels diverticulum (Littre's hernia)	Laparotomy	
Plaus ¹²	Cholecystectomy and pelvic laparotomy	5	46	Suprapubic		Omentum	Repair under local and sedation	
Ravichandran <i>et al</i> ¹³	Appendectomy	5	58/36	Lateral	1 year	Omentum and LI	Midline laparotomy	
Reardon <i>et al</i> ⁴	Paraesophageal hernia repair	5			2	SI obstruction		

BMI, body mass index; SI, small intestine; LI, large intestine; L, left; R, right; BSO, bilateral salpingo-oophorectomy.

Table 2 Gynecological surgery case reports

Study	Operation (laparoscopic)	Port size (mm)/type	Age (yr)/BMI (kg/m ²)	Site	Delay after laparoscopy (days)	Evisceration	Management	Comments
Bergemann <i>et al</i> ¹⁴	Tubal ligation	3	32	Umbilicus	2	Omentum		Preexisting umbilical herniation
Eltabbakh ¹⁵	Hysterectomy, BSO, lymphadenectomy	5	54		7	SI	Exploratory laparotomy	Prolonged operation
Huang <i>et al</i> ¹⁶	BSO, lymph node biopsy	5/nonbladed trocars	63	Right lower quadrant	1	SI	Laparoscopic reduction and repair of incision	
Khurshid <i>et al</i> ¹⁷	Tubal ligation (15 min)	5	36/33.1	Lateral	0	LI	Laparoscopic reduction and repair of incision	Corrected in surgery
Kanis <i>et al</i> ¹⁸	Laparoscopic BSO (100 min)	5/nonbladed balloon trocars	70/22	Right lower quadrant	1	SI	Laparoscopic reduction and repair of incision	
	Laparoscopic radical hysterectomy, BSO, lymph node dissection, adhesion lysis	5/nonbladed balloon trocars	84/20	Left lower quadrant	5	SI	Laparotomy	Incidental omental tissue found when examining right-sided 5-mm port, repaired in theater
Moreaux <i>et al</i> ¹⁹	Laparoscopic hysterectomy, BSO, pelvic lymphadenectomy (240 min)	5	63/26	Lateral	6	SI	Laparoscopy; segmental bowel resection and primary anastomosis	Previous drain site
	Laparoscopic hysterectomy, BSO, pelvic lymphadenectomy (120 min)	5	74/20	Right lower abdomen	6	SI	Laparotomy	Previous drain site
Plaus ¹²	Pelvic laparoscopy	5	27	Suprapubic		Omentum	Repair under local anaesthesia with sedation	
Sayaneh and Abdel-Rahman ²⁰	Ovarian cystectomy	5	43/26	Lateral	2	SI	Laparoscopic reduction and repair of incision	No risk factors, short uncomplicated procedure
Thapar <i>et al</i> ²¹	Laparoscopic ovarian cystectomy	5	38/23	Right lower quadrant	2	SI	Laparoscopic reduction and repair of incision	Previous drain at site
Toub ²²	Radical hysterectomy	5		Left lower quadrant		Omentum		Began chemotherapy day 3
Yamamoto <i>et al</i> ²	Hysterectomy	5	43	Right lateral abdominal wall		SI	Laparoscopic reduction and repair of incision	Extensive trocar manipulation

Table 3 Original studies

Study	Specialty	Sample size	Port size (mm)	Operation	Duration (min)	Site	Patient age (yr)/BMI (kg/m ²)	Evisceration	Management
Nassar <i>et al</i> ²³	Prospective trials general surgery	870, 16 umbilical hernias (1.8%), 1 at a 5-mm port	5	Laparoscopic cholecystectomies	Mean 86 mins	Lower lateral			
Nezhat <i>et al</i> ⁶	O&G retrospective review	5300 patients, 10 hernias, 5 in ports 5 mm	5	Adenolysis and presacral neurectomy Total hysterectomy	140 230	L lower quadrant	36/21.5	Omentum	Laparoscopic reduction and repair of incision
				Total hysterectomy	260	L lower quadrant	52/40.5	SI	Laparoscopic reduction and repair of incision
				Total hysterectomy and BSO	160	L lower quadrant	43/42.1	SI	Laparoscopic reduction and repair of incision
				Total hysterectomy	164	L lower quadrant	50/28.2	Omentum	Laparoscopic reduction and repair of incision
							48/20.2	SI	Laparoscopic reduction and repair of incision

entry, and closure techniques.^{2,5} Additionally, patient factors contributing to an increased rate of trocar site herniation's may include preexisting fascial defects, obesity, and surgical site infections.⁵

Extensive manipulation of trocar sites may widen the port site incision fascia and peritoneum beyond the initial length. Stretching may occur secondary to specimen removal, multiple reinsertions of the sheath, increased force and torque on the fascia, and prolonged operative time. The retrospective review by Nezhat *et al*⁶ noted that each of the 5 surgeries resulting in trocar site hernias were associated with surgical difficulties. For example, extensive adhesions, as seen in our case, required extensive manipulation from the trocar sites.

Laparoscopic port site herniation is a preventable cause of morbidity that requires a second, often emergent (or unplanned), surgical procedure to repair. All fascial defects larger than or equal to 10 mm should be closed at the fascial level. Smaller defects may require closure in certain circumstances to prevent subsequent herniation; in particular, where port sites have been subjected to additional unanticipated mechanical stress throughout the procedure. After laparoscopic procedures, patients reporting postoperative incisional swelling or gastrointestinal obstructive symptoms should be expediently evaluated for possible bowel herniation, regardless of port size used to avoid delays in diagnosis and treatment.

Observational case report ethics approval from an ethics committee or institutional review board was not required.

References

1. Tonouchi H, Ohmori Y, Kobayashi M, Kusunoki M. Trocar site hernia. *Arch Surg* 2004;**139**(11):1248–1256
2. Yamamoto M, Minikel L, Zaritsky E. Laparoscopic 5-mm trocar site herniation and literature review. *JLS* 2011;**15**(1): 122–126
3. Owens M, Barry M, Janjua AZ, Winter DC. A systematic review of laparoscopic port site hernias in gastrointestinal surgery. *Surgeon* 2011;**9**(4):218–224
4. Reardon PR, Preciado A, Scarborough T, Matthews B, Marti JL. Hernia at 5-mm laparoscopic port site presenting as early postoperative small bowel obstruction. *J Laparoendosc Adv Surg Tech A* 1999;**9**(6):523–525
5. Dulskas A, Lunevicius R, Stanaitis J. A case report of incisional hernia through a 5 mm lateral port site following laparoscopic cholecystectomy. *J Minim Access Surg* 2011;**7**(3):187–189
6. Nezhat C, Nezhat F, Seidman DS, Nezhat C. Incisional hernias after operative laparoscopy. *J Laparoendosc Adv Surg Tech A* 1997;**7**(2):111–115

7. Abdel-Halim MRE, Higgs SM, Niayesh MH. Early port site hernia causing small bowel obstruction after laparoscopic appendectomy. *Grand Rounds* 2007;7:64–66
8. Coda A, Bossotti M, Ferri F, Mattio R, Ramellini G, Poma A *et al.* Incisional hernia and fascial defect following laparoscopic surgery. *Surg Laparosc Endosc Percutan Tech* 2000;10(1):34–38
9. Fleming F, Winter D. Images in surgery. Richter's hernia at a 5-mm laparoscopic port site. *Surgery* 2009;146(3):523
10. Matter I, Nash E, Abrahamson J, Eldar S. Incisional hernia via a lateral 5 mm trocar port following laparoscopic cholecystectomy. *Isr J Med Sci* 1996;32(9):790–791
11. Mehmet EY. Meckel's diverticulum as a leading point of early onset-type hernia through a 5-mm trocar site incision. *Surg Pract* 2014;18(3):149–151
12. Plaus WJ. Laparoscopic trocar site hernias. *J Laparoendosc Surg* 1993;3(6):567–570
13. Ravichandran K, Velan MS, Karthik M, Ajmal IT, Venkatesan KP. A case report of incisional hernia through a 5mm suprapubic port site following laparoscopic appendectomy. *J Evol Med Dental Sci* 2014;3(73):15448–15642
14. Bergemann JL, Hibbert ML, Harkins G, Narvaez J, Asato A. Omental herniation through a 3-mm umbilical trocar site: unmasking a hidden umbilical hernia. *J Laparoendosc Adv Surg Tech A* 2001;11(3):171–173
15. Eltabbakh GH. Small bowel obstruction secondary to herniation through a 5-mm laparoscopic trocar site following laparoscopic lymphadenectomy. *Eur J Gynaecol Oncol* 1999;20(4):275–276
16. Huang M, Musa F, Castillo C, Holcomb K. Postoperative bowel herniation in a 5-mm nonbladed trocar site. *JSLs* 2010;14(2):289–291
17. Khurshid N, Chung M, Horrigan T, Manahan K, Geisler JP. 5-millimeter trocar-site bowel herniation following laparoscopic surgery. *JSLs* 2012;16(2):306–310
18. Kanis MJ, Momeni M, Zakashansky K, Chuang L, Hayes MP. Five-millimeter balloon trocar site herniation: report of two cases and review of literature. *J Minim Invasive Gynecol* 2013;20(5):723–726
19. Moreaux G, Estrade-Huchon S, Bader G, Guyot B, Heitz D, Fauconnier A *et al.* Five-millimeter trocar site small bowel eviscerations after gynecologic laparoscopic surgery. *J Minim Invasive Gynecol* 2009;16(5):643–645
20. Sayasneh ANA, Abdel-Rahman H. A case report of incisional hernia through a 5-mm lateral port site following laparoscopic right ovarian cystectomy. *Gynecol Surg* 2011;8:227–230
21. Ankur Thapar BK, Pyper R, Woods W. 5 mm port site hernia causing small bowel obstruction. *Gynecol Surg* 2010;7:71–73
22. Toub DB, Campion MJ. Omental herniation through a 5-mm laparoscopic cannula site. *J Am Assoc Gynecologic Laparoscopists* 1994;1(4):413–414
23. Nassar AH, Ashkar KA, Rashed AA, Abdumoneum MG. Laparoscopic cholecystectomy and the umbilicus. *Br J Surg* 1997;84(5):630–633