



## Case Report

# Strangulated Lesser Omentum Hiatus Hernia: A Rare Case Report and a Literature Review

Wei Wang<sup>1</sup>, Haifeng Wang<sup>1</sup>, Feng Tao<sup>1</sup>, Kaixing Ai<sup>2</sup>

<sup>1</sup>*Department of Gastrointestinal Surgery, Shaoxing People's Hospital, Shaoxing Hospital of Zhejiang University, Zhejiang, China*

<sup>2</sup>*Department of General Surgery, Tongji Hospital, Tongji University School of Medicine, Shanghai, China*

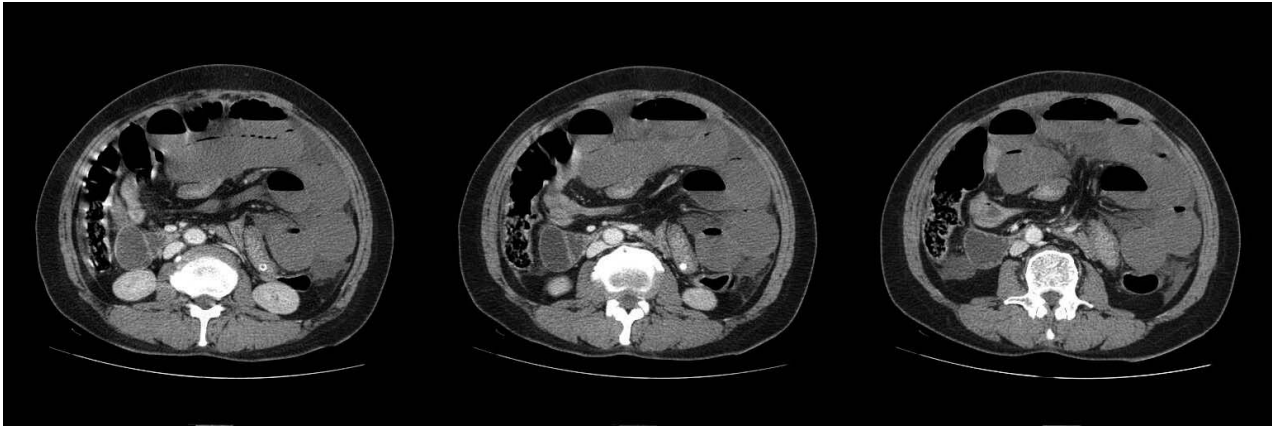
Intestinal obstruction caused by primary intraperitoneal hernia is infrequent and difficult to diagnose. Incorrect diagnosis and delayed surgical treatment will lead to serious consequences. We report a rare case of a 62-year-old Chinese woman with strangulated lesser omentum hiatus hernia. Contrast-enhanced abdominal computed tomography (CT) scan is recommended for early revelation of direct and indirect signs. We propose three diagnostic points of primary intraperitoneal hernia: (1) “Three-no” pathography: with no history of abdominal operation, abdominal trauma, or abdominal infection. (2) The disease begins with mechanical intestinal obstruction, then turns easily into strangulated intestinal obstruction. (3) It excludes intestinal wall lesions and intestinal blockage. We also summarize the surgical procedure in four steps. We hope this case can provide a reference for the diagnosis and treatment of similar situations.

*Key words:* Lesser omentum hiatus hernia – Primary intraperitoneal hernias – Intestinal obstruction – Computed tomography – Surgery

Secondary intraperitoneal hernias are more common than primary intraperitoneal hernias. The former are associated with the formation of abnormal gaps after abdominal operation, trauma, or infection. The latter are associated with abnormal gaps caused by abnormal rotation and fixation of midgut.<sup>1</sup> Paraduodenal hernias (53%), pericecal hernias (13%), Winslow hernias (8%), mesenteric

hernias (8%), and sigmoid hernias (6%) are relatively common,<sup>2</sup> whereas the lesser omentum hiatus hernias are rare. Intestines are the most common contents in intraperitoneal hernias. Early diagnosis of intraperitoneal hernias is difficult, especially for patients with no history of abdominal operation, trauma, or infection. Abdominal pain and distension is one of the main symptoms, which is often

Corresponding author: Wei Wang, Department of Gastrointestinal Surgery, Shaoxing People's Hospital, Shaoxing Hospital of Zhejiang University, No. 568 Zhongxing North Road, Shaoxing 312000, China.  
Tel.: +86 13989502616; E-mail: wwsjd@163.com



**Fig. 1** Contrast-enhanced abdominal CT scan of strangulated lesser omentum hiatus hernia. Direct signs of intraperitoneal hernias: the local approach of thin small intestine, mesentery, and blood vessel. Indirect signs of intraperitoneal hernias: passive shift of surrounding organs caused by dilated intestine.

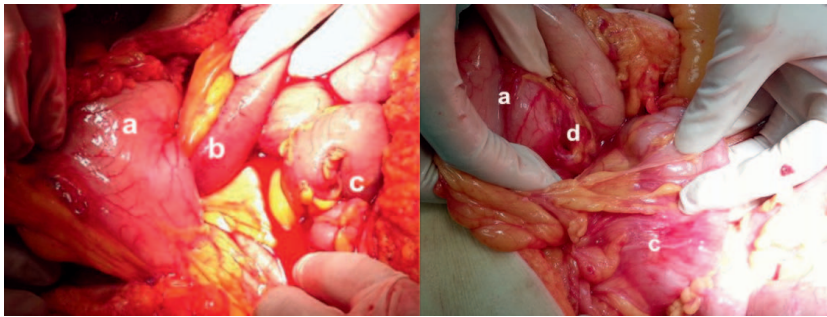
recurrent with the change of position. If a patient who has had previous abdominal surgery has the performance of strangulated intestinal obstruction, it is relatively easy to diagnose intraperitoneal hernias.<sup>1</sup> Incorrect diagnosis and delayed surgical treatment will lead to serious consequences.

Here, we report a rare case of strangulated lesser omentum hiatus hernia. Contrast-enhanced abdominal computed tomography (CT) scan is recommended for early revelation of direct and indirect signs. We also propose three diagnostic points and summarize the surgical procedure, which may be helpful for reducing the occurrence rate of intestinal necrosis and even more serious complications.

### Case Report

A 62-year-old woman was admitted because of severe abdominal pain and distention lasting for 1 day. She had no previous history of abdominal operation, trauma, or infection. Before admission, this patient suddenly felt abdominal pain when lying down after a meal, accompanied by abdominal distention, nausea, and vomiting. She received a diagnosis of intestinal obstruction in the local hospital after an abdominal CT scan. The symptoms were not relieved after management with spasmolysis, odynolysis, and anti-inflammatory drugs. For further diagnosis and treatment, she was then transferred to our hospital. Her pulse was 130 bpm, and blood pressure was 85/43 mmHg. The heart and lungs were normal. The whole abdomen was bulging and stiff. Tenderness and rebound tenderness around the abdomen were found. No

peristalsis was palpable. The gurgling sound disappeared. Shifting dullness was positive. We withdrew light, bloody, noncondensable liquid by abdominal paracentesis. Laboratory and radiology findings: blood routine showed a red blood cell count of  $2.5 \times 10^{12}/L$ , hemoglobin 81 g/L, and leukocyte count  $11.6 \times 10^9/L$ . Biochemical investigation showed serum creatinine 336.5  $\mu\text{mol}/L$ , blood urea nitrogen 15.26 mmol/L, and plasma D-dimer 5.63  $\mu\text{g}/\text{mL}$ . Ascites mucin qualitative test was ++++. Contrast-enhanced CT revealed the centralization of narrow small intestine, mesentery, and blood vessel in the rear of the lesser curvature of stomach. There were gas-fluid levels in the extensive intestine of the upper abdomen (Fig. 1). After adequate preparation, the patient underwent exploratory laparotomy. During operation, 2000 mL of light, bloody, noncondensable liquid was withdrawn from the peritoneal cavity. There was a geneogenous hiatus ( $2 \times 2$  cm) in the hepatogastric ligament. An approximately 200-cm-long intestine adjacent to the Treitz ligament first leapt over the transverse colon, then penetrated this hiatus into the subhepatic space between the liver and the lesser curvature of stomach. The strangulated intestine and mesentery were completely ischemic necrotic. There was a lot of chyme in the aperistaltic, dark, and extensive bowel, with only a 300-cm-long normal intestine remaining. Further exploration revealed geneogenous hypogenetic mesocolon, gastrocolic ligament, and greater omentum. Because of the geneogenous hypogenetic mesocolon, the transverse colon was close to the pancreas (Figs. 2 and 3). The intraoperative diagnosis was strangulated lesser omentum



**Fig. 2** Intraoperative pictures of strangulated lesser omentum hiatus hernia. (a) Stomach. (b) Incarcerated intestine. (c) Transverse colon. (d) Lesser omentum hiatus.

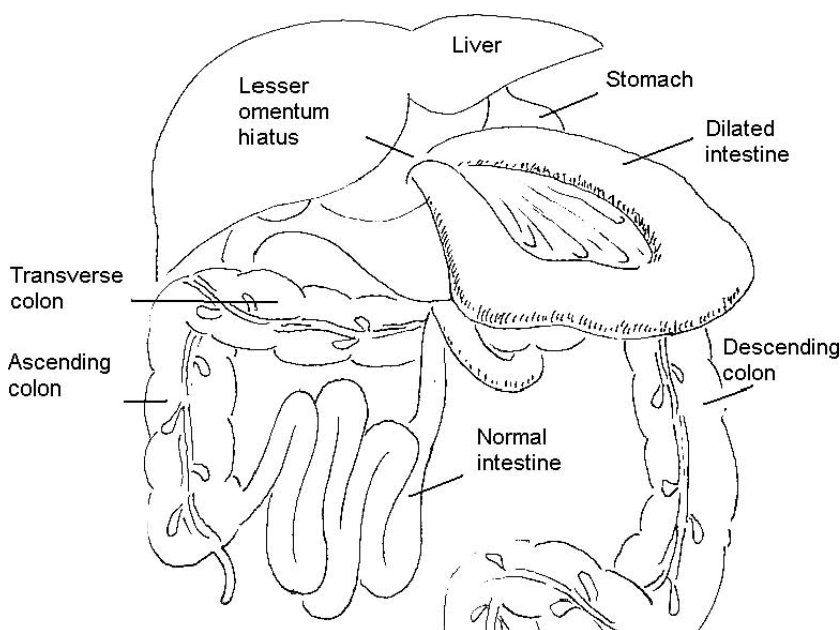
hiatus hernia, septic shock, anemia, acute renal failure, ovarian cysts, geneogenous hypogenetic mesocolon, gastrocolic ligament, and greater omentum. We resected the necrotic intestine, closed the lesser omentum hiatus, and rearranged the remaining 300-cm-long intestine. After the nutritional and anti-inflammatory treatments, this patient recovered enough to be released 10 days after operation.

### Discussion

Sudden onset of primary lesser omentum hiatus hernia in a patient who had no previous history of abdominal operation is rare. It is related to its unique anatomic structures. The major cause of this case is the congenital defect of lesser omentum. In addition, because of the congenital dysplasia of transverse mesocolon, omentum, and gastrocolic ligament, intestine easily leapt over the transverse colon and into the lesser omentum hiatus. These

anatomic factors were the morphologic bases of this rare case. In this case, small intestine drilled through the lesser omentum hiatus into the spacious subhepatic space when this patient lay down on a full stomach. Because of the lack of restraint effect of hernia sac, peristaltic action prompted more small intestine to drill into the sac. Binding force of hernia ring accelerated the necrotic process of incarcerated bowel. Septic shock and acute renal failure occurred after the absorption of endotoxin.

In the beginning, in a local hospital this patient underwent an unenhanced abdominal CT scan, which revealed gas-fluid levels in the upper abdomen. The radiologic diagnosis was intestinal obstruction. However, the cause was unclear. After her transfer to our hospital, contrast-enhanced abdominal CT scan revealed the local approach of thin small intestine, mesentery, and blood vessel. This was due to the oppression of the hernia ring. We call these direct signs of intraperitoneal hernias.



**Fig. 3** Schema of anatomic structure in this case.

In addition, contrast-enhanced CT scan also revealed the passive shift of surrounding organs caused by dilated intestine.<sup>3</sup> We call these indirect signs of intraperitoneal hernias. In summary, compared with unenhanced CT, contrast-enhanced CT provides more information to establish the pathogeny of intraperitoneal hernia.

Intestinal obstruction caused by primary intraperitoneal hernia is infrequent and difficult to diagnose. We propose three diagnostic points of this disease: (1) “three-no” pathography, which means no history of abdominal operation, abdominal trauma, or abdominal infection. (2) The disease begins with mechanical intestinal obstruction, then easily turns into strangulated intestinal obstruction. (3) It excludes intestinal wall lesions and intestinal blockage. Because the obstructive intestines of primary intraperitoneal hernia easily necrose, with a death rate of >75%,<sup>4</sup> it is better to undergo surgical treatment before ischemic necrosis. We summarize the surgical procedure for primary intraperitoneal hernia as follows: First, find and release the hernia ring. Second, reset the hernia contents. Then, judge intestinal blood supply condition carefully. Intestine with good blood supply can be retained, whereas intestine with poor blood supply should be resected. In order to reduce the absorption of toxin, necrotic intestine and mesentery should be clamped by intestinal clamps before bowel resection. Third, close the hernia ring and abnormal intraperitoneal gaps. Fourth, intestinal plication is advised to reduce the recurrence rate.

This case suggested that we should not neglect the possible diagnosis of primary intraperitoneal hernia in acute intestinal obstruction cases, although the probability is very small.<sup>5</sup> Contrast-enhanced abdominal CT scan is recommended for early revelation of direct and indirect signs of intraperitoneal hernias. Timely diagnosis and timely surgical treatment are very important for reducing the occurrence rate of intestinal necrosis and even more serious complications. Meanwhile, intraoperative inspection and the closing of abnormal intraperitoneal gaps are effective to avoid the recurrence of hernias.

### Acknowledgments

There are no conflicts of interest.

### References

1. Wu J, Qiu F, Wu M, Wu Z, Chen H, Chen X. *Huang Jiasi Surgery*. 7th ed. Beijing, China: People's Medical Publishing House, 2008:1497
2. Meyers MA. *Dynamic Radiology of the Abdomen: Normal and Pathologic Anatomy*. 4th ed. New York, NY: Springer-Verlag, 1994:1–6
3. Takeyama N, Gokan T, Ohgiya Y, Satoh S, Hashizume T, Hataya K *et al*. CT of internal hernias. *Radiographics* 2005;25(4):997–1015
4. Wu J, Qiu F, Wu W, Wu M. *Huang Jiasi Surgery*. 6th ed. Beijing, China: People's Medical Publishing House, 1999:1078
5. Martin LC, Merkle EM, Thompson WM. Review of internal hernias: radiographic and clinical findings. *AJR Am J Roentgenol* 2006;186(3):703–717