



Case Report

Clinical Experience of Mini-Open Hepatectomy to Aid a Laparoscopic Approach: A Case Series

Hiroya Iida^{1,2}, Takayoshi Nakajima¹, Shinichi Ikuta¹, Tsukasa Aihara¹, Naoki Yamanaka¹

¹Department of Surgery, Meitwa Hospital, Meitwa, Japan

²Department of Surgery, Shiga University of Medical Science, Shiga, Japan

Introduction: Laparoscopic surgery is recently becoming widespread in the area of liver treatment. However, mobilization of the liver is difficult using laparoscopy alone because of its volume and weight. Ensuring a wider visual field and controlling blood loss are also difficult. We used a hybrid approach involving direct vision and laparoscopy for performing hepatectomy through a small incision to overcome these problems.

Case Presentation: Mini-open hepatectomy was performed on 64 patients between January 2010 and December 2013. Mobilization of the liver was performed using the smallest possible laparotomy incision. Detachment of right or left triangular ligaments was done using laparoscopy because direct vision of the operation field was impossible. Hepatectomy was performed through a small laparotomy incision. Most operations (47%) involved partial resections. Of these, segmentectomies were performed on 20 patients, whereas lobectomy was performed on 7 patients. The median intraoperative bleeding was 565 mL, and the operative time was 247 minutes. The median postoperative hospital stay was 14 days. There was no postoperative mortality.

Conclusion: We present the clinical use of mini-open hepatectomy to aid the laparoscopic approach with satisfactory short-term results.

Key words: Minimally invasive hepatectomy – Laparoscopic liver surgery – Small laparotomy

Hepatectomy used to require a large laparotomy; however, the use of laparoscopic surgery has now become more common in liver surgery. The advantage of laparoscopic surgery is the use of a small incision, but this is accompanied by increased difficulties in the necessary surgical procedures. This is particularly relevant in liver surgery, in which the shape, location, and weight of the liver

Corresponding author: Hiroya Iida, MD, PhD, Department of Surgery, Shiga University of Medical Science, Seta Tsukinowa-cho, Otsu, Shiga 520-2192, Japan.

Tel.: +81 775 48 2238; Fax: +81 775 48 2240; E-mail: hiroya@belle.shiga-med.ac.jp

make its mobilization difficult. In addition, ensuring a wider visual field and controlling blood loss are difficult when laparoscopy is used to perform a hepatectomy.

To overcome these problems, we used a hybrid approach for performing hepatectomy that enables a wide visual operating field combined with laparoscopy through a small incision.

This mini-open method is similar to normal hepatectomy, except that it involves the use of a small incision. The laparoscope is only used to illuminate the deep interior of the abdomen, a necessary step because of the insufficient light that is available through a small incision. As for the surgical sites that are inoperable from the small incision, the surgery is going to be using laparoscopy. Here, we report the application of the proposed method and important aspects related to the surgical technique and discuss the reliability of the short-term results of using this method.

Materials and Methods

Mini-open hepatectomies were performed between January 2010 and December 2013 on 64 patients who fulfilled the inclusion criteria for the current study without combined resection of other organs and the necessity of resecting 2 or more liver parenchyma. We retrospectively investigated the patients' background, tumor factors, operative factors, morbidity, and postoperative course. Written informed consent was obtained from all patients, and the study was approved by the ethics committee at our institution.

Surgical technique: Indications for mini-open surgery

The surgical method was based on the hepatic functional reserve and remnant liver volume. The selection criteria used were the same as those used for normal laparotomy established by Yamanaka *et al.*^{1,2}

An example of an indication for partial resection using mini-open surgery was the presence of small peripheral tumor sites of less than 4 cm. In contrast, lesions exceeding 5 cm in size would be likely to lie within close proximity to a major blood vessel, unless positioned at the periphery or surface of the liver and would not be considered for partial resection. However, segmentectomy or lobectomy was still possible in cases where the lesions exceeded 5 cm but were located deep inside the liver.

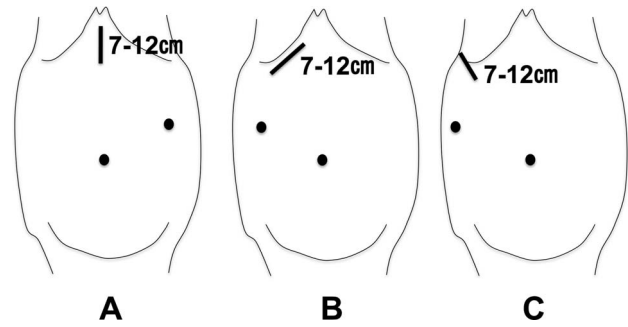


Fig. 1 Area of skin incision and trocar. (A) Left lateral segmentectomy or partial resection of segment 2 or 3. (B) Right lobectomy or partial resection of segment 4, 5, or 8. (C) Posterior segmentectomy or partial resection of segment 6 or 7.

Operative procedures

Skin incision and position of the trocar

A 7- to 12-cm incision was made as follows: a median incision for S2 and S3 partial resection and lateral segmentectomy and a right subcostal area incision for S4, S5, and S8 partial resection. Depending on the tumor location, the left subcostal area incision may be used for S2 or S3 partial resection. Anterior segmentectomy and lobectomy were performed with the patient in the supine position. The ninth intercostal incision for S6 and S7 partial resection and posterior segmentectomy was selected with the patient in the right lateral position. Trocars were inserted from the umbilical region and the left side of the abdomen for lateral segmentectomy, left lobectomy, and S2 and S3 partial resection and from the umbilical region and right side of the abdomen for anterior segmentectomy, posterior segmentectomy, right lobectomy, and S4, S5, S6, S7, and S8 partial resection (Fig. 1). Trocars could be safely inserted because small incisions were made before inserting trocars. Additional trocars could be used in cases where mobilization of the liver was difficult.

Obtaining a wider vision field

An Alexis wound protector/retractor (Applied Medical, Rancho Santa Margarita, California) was inserted at the incision. The use of a Kent retractor (Takasago Medical Industry, Tokyo, Japan) to elevate the wound was sufficient to obtain a wider field of view. If this approach was unsuccessful, surgical instruments used in the abdominal wall lift method (Mizuho Medical, Tokyo, Japan) were used in the umbilical region (Fig. 2). There was no risk of carbon dioxide embolism because a pneumoperitoneum

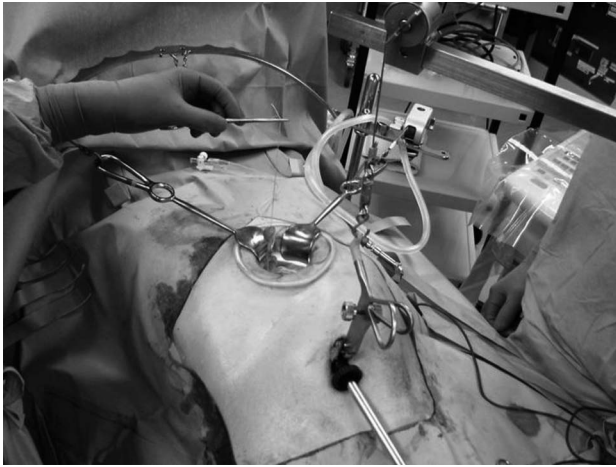


Fig. 2 Intraoperative view of light- and video-guided mini-open hepatectomy.

would not be established in this situation. If a pneumoperitoneum was necessary (e.g., because of the presence of large amounts of fat in the abdominal cavity), it was performed using the wound retractor covered by a surgical glove containing trocars (Fig. 3).

Mobilization of liver

The mobilization of the liver was achieved over as wide an area as possible while the operation was under direct vision. Moving the operating window was made possible by changing the right and left traction pressure of the Kent retractor. Only the outermost parts of the right or left triangular ligament were impossible to cut under direct vision. The dissection was made laparoscopically using laparoscopic coagulating shears (Fig. 4).

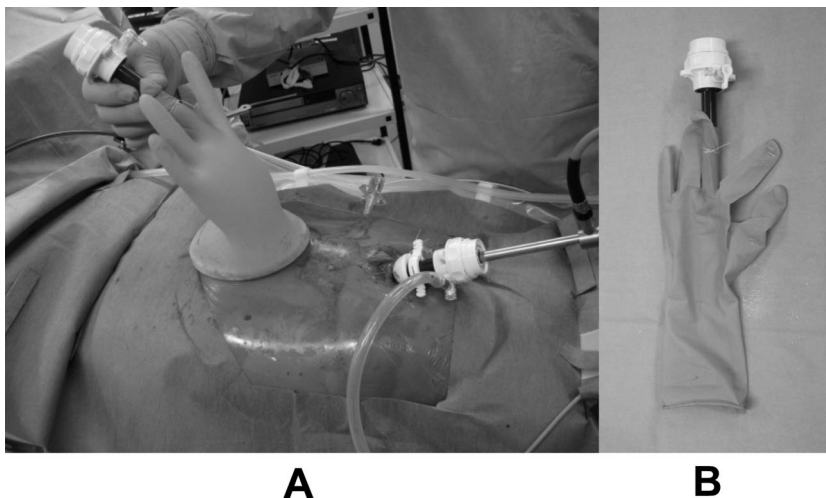


Fig. 3 Method of pneumoperitoneum. (A) Intraoperative view of pneumoperitoneum. (B) The trocar is attached to the glove.

Hepatic resection

Left lateral segmentectomy: Glisson's capsule of segment 3 and segment 2 was resected before any hepatic resection. This was because of the positioning of the roots of segment 3 and segment 2 just under the wound. If this was impossible, the liver parenchyma was resected before Glisson's capsule (Fig. 5).

Hepatic resection was performed using an ultrasonic aspirator (CUSA Excel, Integra Lifesciences Corporation, Princeton, New Jersey) or an ultrasonically activated scalpel. The larger vessels and Glisson's capsules were ligated before resection. The left hepatic vein was gripped by blood vessel forceps for resection or was resected using endoscopic linear staplers (Fig. 6).

Right lobectomy: Because the hepatic hilum was located directly under the wound, the hepatoduodenal ligament could be encircled under direct vision. Although the right Glisson's pedicle could completely be ligated, it was safer to first proceed to the hepatic resection to resect the anterior and posterior branches separately. This strategy avoided involving the left bile duct when the Glisson's pedicle was resected. Hepatic resection was performed in the same manner as normal laparotomy, but the resection in the deep interior of the incision site became easier using a hanging maneuver (Fig. 7).³

Partial resection: Partial resection tended to cause more bleeding than anatomical hepatic resection. Coagulation of the to-be-resected surgical site using microwave coagulation was sometimes performed before the hepatic resection procedure (Fig. 8).

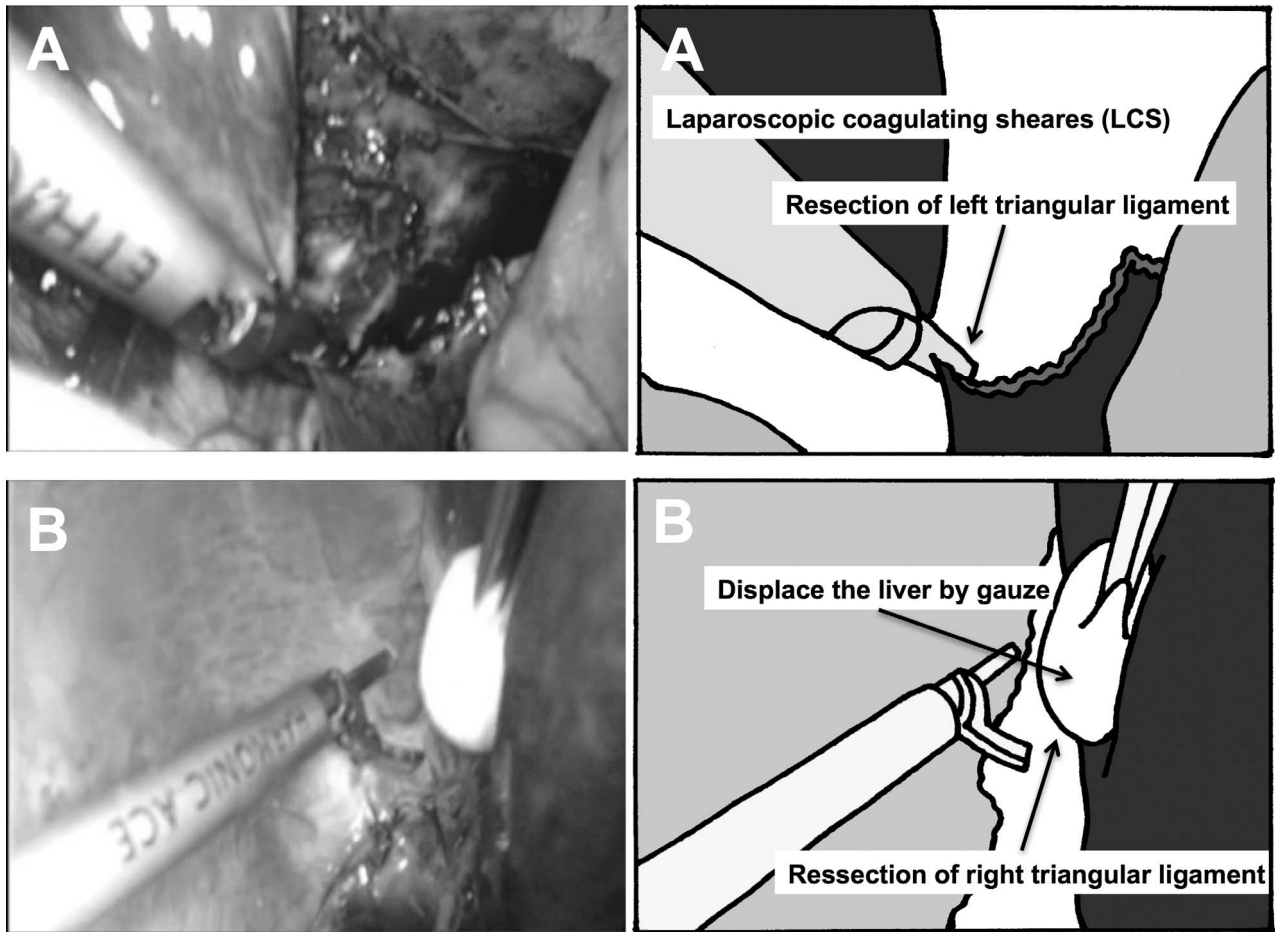


Fig. 4 (A) Resection of the left triangular ligament. (B) Resection of the right triangular ligament.

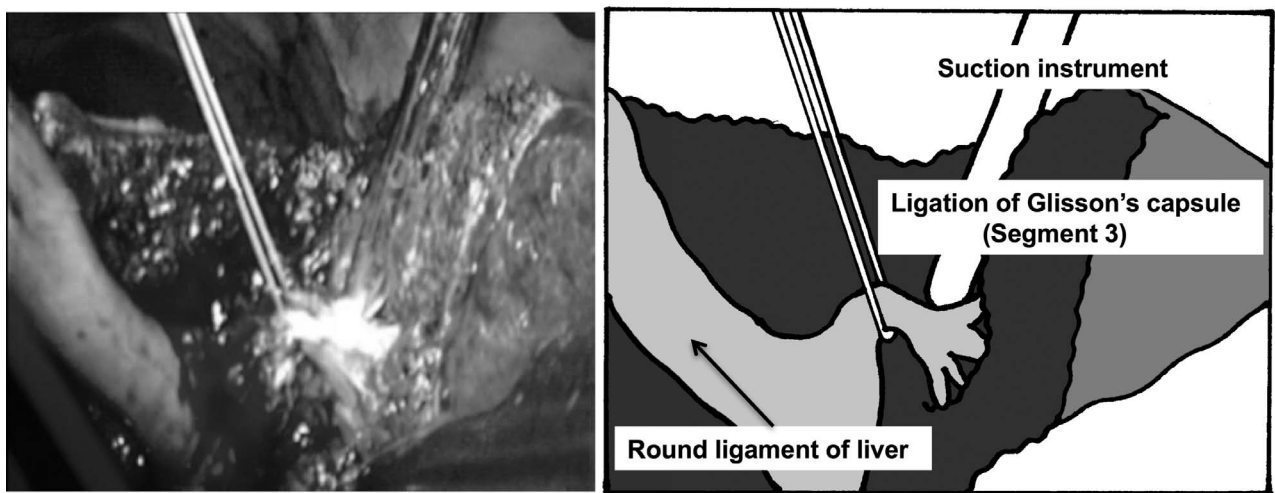


Fig. 5 Hepatic resection and ligation of Glisson's capsule (left lateral segmentectomy).




Fig. 6 (A) Method of suture closing of the left hepatic vein. (B) Division of the left hepatic vein using endoscopic linear staplers.

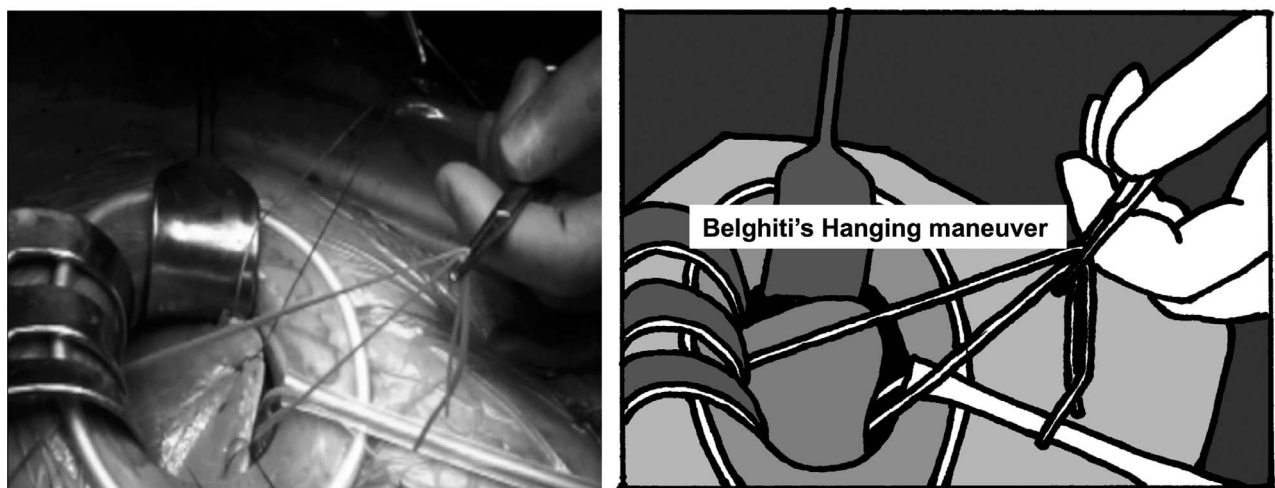


Fig. 7 A Nelaton catheter was placed between the inferior vena cava and liver using the Belghiti hanging maneuver to elevate the liver.




Fig. 8 Use of microwave coagulation before hepatic resection to reduce bleeding.

Results

Partial resection was performed in 30 patients. Subsegmentary resections were performed in 6 patients. Twenty patients underwent segmentary resections: 8 underwent lateral segmentectomies, 8 underwent posterior segmentectomies, and 4 underwent anterior segmentectomies. Right lobectomies were performed in 3 patients, and left lobectomies were performed in 4 patients.

The average age of the patients was 66 years, and hepatocellular carcinoma (HCC) was the largest cause of primary disease. The median operative time for all the cases in which light- and video-guided mini-open hepatectomy was used was 247 minutes. The median blood loss was 565 mL. Only 1 case of bleeding requiring the incision length to be increased.

The median hospitalization time after surgery was 14 days. Postoperative complications were observed in only 6 patients: 3 patients had grade B postoperative liver failure (PHLF) according to the definition of the International Study Group of Liver Surgery (ISGLS),⁴ 1 patient had a grade 3 deep incisional surgical site infection (SSI), and 2 patients had a grade 3 organ/space SSI according to the Clavien-Dindo classification (Table 1).^{5,6}

Discussion

There have recently been increasing reports on laparoscopic hepatic resection. The advantage of laparoscopic surgery is the small size of the surgical wound. The estimation of the physiologic ability

Table 1 Characteristics of light- and video-guided mini-open hepatectomy

Factors	Patients (n = 64)
Operative method	
Partial resection	30 (S2; 5, S3; 5, S4; 6, S5; 3, S6; 5, S7; 3, S8; 3)
Subsegmentectomy	6 (S3; 1, S4; 1, S5; 1, S6, 1, S8; 1)
Segmentectomy	20 (lateral; 8, anterior; 4, posterior; 8)
Lobectomy	7 (left; 4, right; 3)
Other	1 (central bisegmentectomy)
Age (yr)	66 ± 11
Sex	
Male	41
Female	23
Primary disease	
HCC	41
Liver metastasis	19
ICC	3
Other	1 (hemangioma)
Maximum tumor size (cm)	3.0 (1.0, 5.0)
Tumor number	
Single	45
Multiple	19
Albumin level (g/dL)	4.0 (3.5, 4.5)
Bilirubin level (mg/dL)	0.7 (0.4, 1.1)
PT level (%)	88 (70, 100)
Operative time (min)	247 (126, 334)
Bleeding (mL)	565 (100, 1975)
Complications	
PHLF	3 (grade 2)
SSI	3 (deep incisional; 1, space/organ; 2)
Hospitalization (days)	14 (10, 24)

Data are mean ± SD in age or median (10, 90 percentiles). HCC, hepatocellular carcinoma; ICC, intrahepatic cholangiocellular carcinoma; PHLF, posthepatectomy liver failure; PT, prothrombin activity; SSI, surgical site infection.

and surgical stress (E-PASS) is known as an evaluation index of surgical stress in gastroenterologic medicine. It has been used to define a thoracoscopic wound, a laparoscopic wound alone, or a wound of 10 cm or less as requiring low-invasive surgery.⁷ Laparoscopy is also commonly understood to be a low-invasive surgery because of the decreased destruction of the abdominal wall compared with laparotomy. Hepatic resection, even when performed using a laparoscope, requires the use of laparotomy (to a certain extent) to remove the entire lesion because the resected tissues are large and hard.

Considering the aforementioned factors, we performed a small laparotomy relatively early in the operation without hesitation. It is generally called a hybrid method to perform mobilization of the liver laparoscopically before performing a small laparotomy.⁸ This mini-open method can be considered a type of hybrid method, in which minimal surgery is combined with open liver resection, but it is distinguishable from others in that, during surgery, most processes are performed through the small initial incision site.

The detachment of the right or left triangular ligaments was the only procedure to be done under laparoscopy, whereas all the other surgical procedures were performed under direct vision. Another advantage was that the pneumoperitoneum was immediately formed using gloves covering the wound retractors. This meant that there was a reduction in the time needed for laparoscopy, resulting in no extension to the total surgery time.

Many cases have reported the usefulness of laparoscopic hepatic resection compared with normal laparotomy.^{9–15} A recent study described laparoscopic hepatic resection performed during donor liver transplantation.¹⁶ There have also been reports on laparoscopic hepatic resection performed on a patient with cirrhosis¹⁷ and single-incision laparoscopic hepatic resection.¹⁸ These examples illustrate the increasing use of laparoscopic hepatic resection. However, the use of only laparoscopic hepatic resection requires a longer operation time, and the safety of the procedure for anatomic resection has not yet been established.

To our knowledge, we were the first to describe the use of laparoscopic microwave coagulation therapy and laparoscopic hepatic resection.^{19,20} Based on these experiences, we continued with the approach of performing hepatectomy through a small laparotomy incision.

The current study has a limitation: the data were retrospectively collected from a single facility in a small number of patients. The feasibility of performing hepatectomy with total laparoscopic approach has been confirmed by many experiences. Therefore, this technique can be used as an option when total laparoscopic hepatectomy is difficult, for example, when the adhesion is severe or when the tumor is large and the field of view cannot be obtained.

In conclusion, mini-open hepatectomy is a useful option for total laparoscopic hepatectomy. It is important to acquire the technique of performing surgery from a small wound using the particular method when operation is difficult to achieve with a totally laparoscopy.

References

1. Yamanaka N, Okamoto E, Kuwata K, Tanaka N. A multiple regression equation for prediction of posthepatectomy liver failure. *Ann Surg* 1984;**200**(5):658–663
2. Yamanaka N, Okamoto E, Oriyama T, Fujimoto J, Furukawa K, Kawamura E *et al*. A prediction scoring system to select the surgical treatment of liver cancer. Further refinement based on 10 years of use. *Ann Surg* 1994;**219**(4):342–346
3. Belghiti J, Guevara OA, Noun R, Saldinger PF, Kianmanesh R. Liver hanging maneuver: a safe approach to right hepatectomy without liver mobilization. *J Am Coll Surg* 2001;**193**(1):109–111
4. Rahbari NN, Garden OJ, Padbury R, Brooke-Smith M, Crawford M, Adam R *et al*. Posthepatectomy liver failure: a definition and grading by the International Study Group of Liver Surgery (ISGLS). *Surgery* 2011;**149**(5):713–724
5. Clavien PA, Barkun J, de Oliveira ML, Vauthey JN, Dindo D, Schulick RD *et al*. The Clavien-Dindo classification of surgical complications: five-year experience. *Ann Surg* 2009;**250**(2):187–196
6. Dindo D, Demartines N, Clavien PA. Classification of surgical complications: a new proposal with evaluation in a cohort of 6336 patients and results of a survey. *Ann Surg* 2004;**240**(2):205–213
7. Haga Y, Ikei S, Ogawa M. Estimation of Physiologic Ability and Surgical Stress (E-PASS) as a new prediction scoring system for postoperative morbidity and mortality following elective gastrointestinal surgery. *Surg Today* 1999;**29**(3):219–225
8. Koffron AJ, Kung RD, Auffenberg GB, Abecassis MM. Laparoscopic liver surgery for everyone: the hybrid method. *Surgery*. 2007;**142**(4):463–468
9. Nguyen KT, Gamblin TC, Geller DA. World review of laparoscopic liver resection—2,804 patients. *Ann Surg* 2009;**250**(5):831–841

10. Sarpel U, Hefti MM, Wisniewsky JP, Roayaie S, Schwartz ME, Labow DM. Outcome for patients treated with laparoscopic versus open resection of hepatocellular carcinoma: case-matched analysis. *Ann Surg Oncol* 2009;**16**(6):1572–1577
11. Dagher I, Belli G, Fantini C, Laurent A, Tayar C, Lainas P *et al*. Laparoscopic hepatectomy for hepatocellular carcinoma: a European experience. *J Am Coll Surg* 2010;**211**(1):16–23
12. Morise Z, Ciria R, Cherqui D, Chen KH, Belli G, Wakabayashi G. Can we expand the indications for laparoscopic liver resection? A systematic review and meta-analysis of laparoscopic liver resection for patients with hepatocellular carcinoma and chronic liver disease. *J Hepatobiliary Pancreat Sci* 2015;**22**(5):342–352
13. Morino M, Morra I, Rosso E, Miglietta C, Garrone C. Laparoscopic vs open hepatic resection: a comparative study. *Surg Endosc* 2003;**17**(12):1914–1918
14. Vigano L, Tayar C, Laurent A, Cherqui D. Laparoscopic liver resection: a systematic review. *J Hepatobiliary Pancreat Surg* 2009;**16**(4):410–421
15. Buell JF, Cherqui D, Geller DA, O'Rourke N, Iannitti D, Dagher I *et al*. The international position on laparoscopic liver surgery: The Louisville Statement, 2008. *Ann Surg* 2009;**250**(5):825–830
16. Wakabayashi G, Nitta H, Takahara T, Shimazu M, Kitajima M, Sasaki A. Standardization of basic skills for laparoscopic liver surgery towards laparoscopic donor hepatectomy. *J Hepatobiliary Pancreat Surg* 2009;**16**(4):439–444
17. Suzuki H, Shimura T, Suehiro T, Araki K, Okada K, Kobayashi T *et al*. Laparoscopic partial liver resection for hepatocellular carcinoma in liver cirrhosis. *Hepatogastroenterology* 2008;**55**(88):2228–2232
18. Patel AG, Belgaumkar AP, James J, Singh UP, Carswell KA, Murgatroyd B. Video. Single-incision laparoscopic left lateral segmentectomy of colorectal liver metastasis. *Surg Endosc* 2011;**25**(2):649–650
19. Yamanaka N, Okamoto E, Tanaka T, Oriyama T, Fujimoto J, Furukawa K *et al*. Laparoscopic microwave coagulation necrotic therapy for hepatocellular carcinoma. *Surg Laparosc Endosc* 1995;**5**(6):444–449
20. Yamanaka N, Tanaka T, Tanaka W, Yamanaka J, Yasui C, Ando T *et al*. Laparoscopic partial hepatectomy. *Hepatogastroenterology* 1998;**45**(19):29–33