



# Surgical Treatment of Substernal Goiters Extending to Posterior Mediastinum

Yao Peng<sup>1</sup>, Xinying Li<sup>1</sup>, Zhejia Zhang<sup>1</sup>, Bo Jiang<sup>1</sup>, Tiecheng Feng<sup>1</sup>, Jingdong Li<sup>1</sup>, Hui Tan<sup>1</sup>, Zhiming Wang<sup>1</sup>, Wei Zhuang<sup>2</sup>

<sup>1</sup>Division of Thyroid Surgery, General Surgery Department, Xiangya Hospital, Central South University, Changsha, China

<sup>2</sup>Department of Thoracic Surgery, Xiangya Hospital, Central South University, Changsha, China

**Aim:** The purpose of this study was to identify the clinical features of posterior mediastinal goiters and surgical treatment strategies on the basis of our experiences.

**Methods:** Clinical data of 23 cases of posterior mediastinal goiters in 122 substernal goiters from a total of 4381 thyroidectomies performed in the Division of Thyroid Surgery of the General Surgery Department of Xiangya Hospital, Central South University, China, during a 6-year period (2010–2016) were analyzed.

**Results:** Posterior mediastinal goiters have a greater prevalence of compression symptoms compared with anterior mediastinal goiters ( $P < 0.05$ ). Substernal goiters that extend to posterior mediastinum have a higher probability of mass bottom below the aortic arch than those extending to anterior mediastinum ( $P < 0.05$ ). A total of 20 posterior mediastinal goiters (87.0%) underwent thyroidectomies by cervical approach without additional incision. In 3 of the 23 patients (13.0%), 1 thoracotomy and 2 thoracoscopic approaches were performed for a complete and safe removal. Postoperative complications occurred in 5 of 23 patients (21.7%), including temporary recurrent laryngeal nerve paralysis and transient hypoparathyroidism in our series.

**Conclusions:** Surgical removal of posterior mediastinal goiters can be performed safely by a single cervical approach in most patients. Thoracoscopic approach proposes a new treatment strategy with feasibility.

**Key words:** Substernal goiter – Posterior mediastinum – Thyroidectomy – Thoracotomy – Thoracoscopy

Substernal goiters (SSGs) were first described by Albrecht von Haller<sup>1</sup> in 1749 and were defined as the presence of the goiter below the thoracic inlet.<sup>1</sup> The prevalence of SSG in all thyroidectomies varies from 1% to 20% based on the different definitions in the literature.<sup>2-4</sup> The diagnosis of SSG is usually made in the fifth or sixth decade of life and has a female to male ratio of 4:1. The enlarging goiter in the mediastinum manifests as compression problems of the close organs, including the trachea, esophagus, large venous structures, etc. A minority of SSGs expand to posterior mediastinum. Of importance, these goiters push the trachea anteriorly and splay the great vessels anteriorly, which presents a clinical significance different from that of anterior mediastinal goiters.

Surgical removal is standard treatment for SSGs, which was considered a challenge for surgeons because of the difficulty in dissecting the thoracic portion of mass. The cervical approach can deal with most SSGs and additional extracervical incisions usually required when encountering difficulty in goiter resection by a single cervical incision and complicated cases, especially those extending to posterior mediastinum.

## Materials and Methods

Clinical data from 122 SSG cases from 4381 thyroidectomies performed between June 2010 and 2016 in the Division of Thyroid Surgery, General Surgery Department of Xiangya Hospital, Central South University, were retrospectively analyzed. We diagnosed SSGs as more than 50% of the mass located below the thoracic inlet based on medical history, clinical manifestation, imaging findings, and eventually intraoperative findings.<sup>5,6</sup> According to the findings on axial computed tomography (CT) scanning, we differentiated SSGs according to anterior and posterior mediastinum to which the intrathoracic portion of the goiter extended. The demographic data, laboratory and imaging findings, and clinical manifestation of anterior mediastinal goiters and posterior mediastinal goiters in our series are outlined in Table 1, respectively.

Laboratory workup, including serum thyroid-stimulating hormone, free T3, and free T4 hormone measurements, was done in all SSG patients. Chest X-ray examination was conducted to evaluate the presence of trachea deviation and compression generally. Thyroid ultrasound is important to evaluate in differentiating benign and malignant thyroid nodules preoperatively. Fine-needle aspira-

Table 1 The clinical data of anterior and posterior mediastinal goiters

Clinical data	AMG (n = 99)	PMG (n = 23)
Average age, y, mean $\pm$ SD	56.23 $\pm$ 11.56	54.19 $\pm$ 15.31
Sex, female:male, n (ratio)	80:19 (4.21:1)	19:4 (4.74:1)
Duration, mo, mean $\pm$ SD	55.9 $\pm$ 19.78	60.6 $\pm$ 21.57
Symptoms at presentation, n (%)		
Asymptomatic	21 (21.2)	3 (13.0)
Neck mass*	78 (78.8)	12 (52.2)
Compression symptoms* <sup>a</sup>	29 (29.3)	13 (56.5)
Bottom of the goiter, n*		
Above AA	54	6
Below AA	45	17
Side of extension, n		
Right	47	14
Left	52	9
Pathology, n		
Benign	95	23
Malignant	4	0

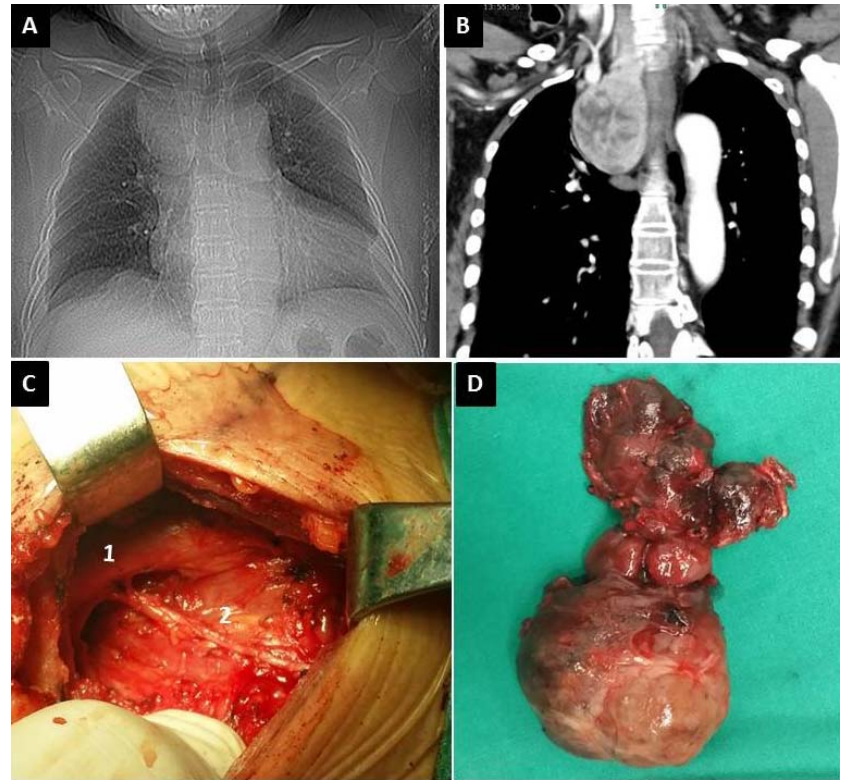
AA, aortic arch; AMG, anterior mediastinum goiter; PMG, posterior mediastinum goiter.

<sup>a</sup>Compression symptoms include dyspnea, dysphagia, hoarseness, etc.

\* $P < 0.05$ .

tion biopsy was not performed in our series for obvious indication for surgery. Contrast-enhanced slice CT scan should be conducted from the cranial base to the hilum of the lungs to gather enough information. In addition, preoperative evaluation should be performed by a multidisciplinary team, including a thyroid surgeon, thoracic surgeon, anesthetist, and relevant physicians.

All operations were performed under general anesthesia with endotracheal intubation. Nasal trachea cannula under the guidance of fiber bronchoscope was used in the patients who exhibited severe tracheal deviation or compression. The patients were placed in a supine position, the same as for thyroidectomy. First, a collar cervical incision was used to dissect the upper pole of thyroid and all surrounding structures so that the cervical section of the goiter was fully freed. Patients who need an additional approach were turned from the supine to the lateral position for lateral thoracotomy or thoracoscopic resection. Additional approaches (thoracotomy or thoracoscopy), in collaboration with cardiothoracic surgeons, were applied to achieve safe and complete removal of the mass when there was failure to resect the goiters through cervical incision. The preoperative imaging findings, intraoperative field, and excised goiter of cervical approach (Fig. 1) and thoracoscopic approach (Fig. 2) are shown below.



**Fig. 1** Preoperative imaging findings, intraoperative field, and excised goiter: cervical approach.

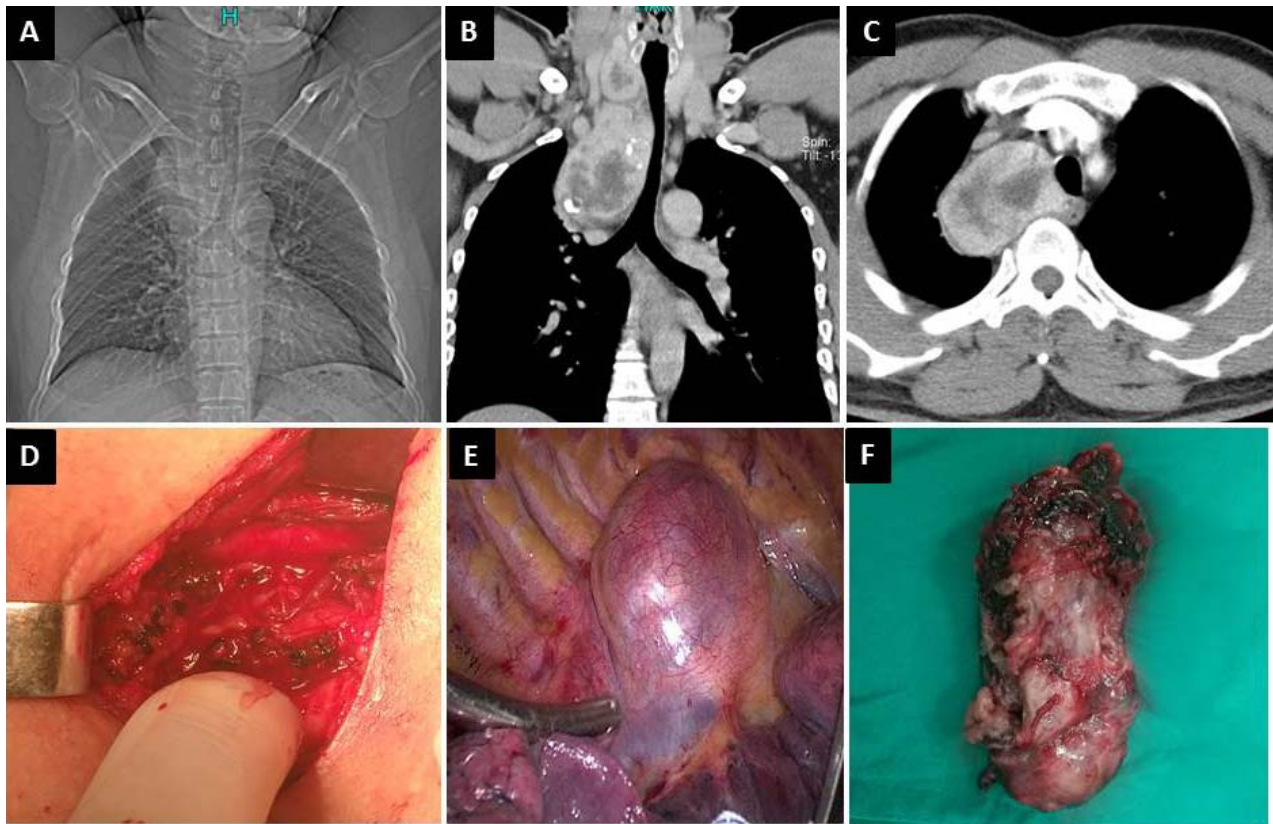
## Results

There were no significant differences between anterior and posterior mediastinal goiters with respect to demographic data, duration of disease, sides of extension, and pathology. The common symptoms of SSG in our series were neck mass, and compression symptoms caused by the deviation and compression of upper airway and esophagus. Neck mass was a predominant symptom in 78 of 99 patients (78.8%) in anterior mediastinal goiters compared with posterior mediastinal goiters (12 of 23; 52.2%;  $P < 0.05$ ). On the contrary, compression symptoms, including dyspnea, dysphagia, hoarseness, and vena cava syndrome, were more seen in posterior mediastinal goiters (13 of 23; 56.5%) than in anterior mediastinal goiters (29 of 99; 29.3%;  $P < 0.05$ ). SSGs that extend into the posterior mediastinum have a higher probability of mass bottom below the aortic arch compared with anterior mediastinum (45 of 99; 45.5% vs. 17 of 23; 73.9%;  $P < 0.05$ ).

Of 23 SSG cases extending to posterior mediastinum, 20 patients (87.0%) underwent dissection of the goiter by cervical approach without additional incision. In 3 of the 23 patients (13.0%), 1 thoracotomy and 2 thoracoscopic approach plus cervical

incision procedures were performed for complete and safe removal. Characteristics of SSG, including the bottom of the goiters, the presence of recurrent goiters, side of goiter extension, and pathologic results, are shown in Table 2 according to the surgical approaches in the present study. The final pathologic results reveal that 4 papillary thyroid cancers (4 of 23; 17.4%) of the encapsulated type were diagnosed and all of these thyroidectomies were performed by single cervical approach. In 2 of 3 patients (66.7%), using combinatory approaches (cervical plus intrathoracic approaches) presented with mediastinal extension of the goiters on the right side, whereas only 1 presented on the left side. Recurrent SSGs were present in 2 of 3 patients (66.7%) who needed an intrathoracic approach in our series. All 3 goiters resected using an intrathoracic approach showed the extension below the aortic arch on CT scan findings.

A total of 7 postoperative complications occurred in 5 of 23 patients (30.4%), including temporary recurrent laryngeal nerve (RLN) paralysis and transient hypoparathyroidism in our series. The 2 complications occurred simultaneously in 2 patients who underwent thyroidectomies (1 by cervical approach and 1 by combinatorial approaches). For cervical approach (without adjunct incision), 3 of 20



**Fig. 2** Preoperative imaging findings, intraoperative field, and excised goiter: thoracoscopic approach.

patients (15.0%) developed postoperative complications, which were composed of transient hypoparathyroidism in 3 patients and temporary RLN paralysis in 1 patient. As for combinatorial approaches, 2 in 3 patients (66.7%) experienced postoperative complications, including 2 cases of transient hypoparathyroidism and 1 case of tempo-

rary RLN paralysis. No postoperative persistent bleeding that required reoperation occurred, and no permanent RLN paralysis and permanent hypoparathyroidism happened. Also, no patients died in our series. All 5 patients who experienced transient hypocalcemia were initially treated with intravenous calcium gluconate, followed by oral calcium and vitamin D. Measurement of parathyroid hormone and serum calcium showed recovery of parathyroid function at 1 month postoperatively. No special treatment was conducted for temporary hoarseness, and the 2 patients' voices recovered to normal at 15 days and 1 month after surgery, respectively.

SPSS version 15.0 for Windows (SPSS Inc, Chicago, Illinois) was used to analyze the data, and comparisons were done by *t*-test and  $\chi^2$  test. Statistical significance was set at a level of  $P < 0.05$ .

**Discussion**

A review of the literature confirms that posterior mediastinal goiter is rare, accounting for 10% to 15% of all intrathoracic goiters.<sup>7</sup> Facilitated by negative

*Table 2* Characteristics of posterior mediastinal goiter according to the surgical approaches

	Cervical approach, n (n = 20)	Intrathoracic approaches, n (n = 3)
Lower border of the goiter		
Above aortic arch	13	0
Below aortic arch	7	3
Reoperation		
Yes	3	2
No	17	1
Side		
Right	8	2
Left	12	1
Final pathology		
Benign	16	3
Malignant	4	0



intrathoracic pressure, gravity, and traction forces during swallowing, the goiters migrate downward into the posterior mediastinum, where the mass comes to rest posteriorly to the innominate vein, carotid sheath, innominate and subclavian arteries, RLN, and inferior thyroid artery. Because of these positional variations, the patients are more susceptible to exhibiting compression symptoms, including dyspnea, dysphagia, hoarseness, vena cava syndrome, etc. In our series, the posterior mediastinal goiters had a greater prevalence of compression symptoms compared with anterior mediastinal goiters ( $P < 0.05$ ). On the contrary, the anterior mediastinal goiters were more likely to manifest neck mass than posterior mediastinal goiters ( $P < 0.05$ ). According to Randolph classification, SSGs extending to posterior mediastinum are type II, in which additional thoracotomy usually can be considered for safe and complete dissection, especially for those extending to the contralateral side.<sup>7,8</sup>

Surgical treatment is the standard strategy for SSGs. Most SSGs can be surgically removed through cervical incision, especially for anterior mediastinal goiters. Besides a cervical approach, a variety of adjunct extracervical approaches, such as sternotomy and thoracotomy, may be required to manage huge, complex, and posterior mediastinal goiters.<sup>9-11</sup> In our series, single cervical approach successfully resolved most posterior mediastinal goiters (20 of 23; 87.0%). Based on our experience, technique of delivery is the most important for removal of goiter by a single cervical approach. Finger dissection in a strictly capsular plane, with slow and incremental mobilization, is essential for mediastinal goiters' delivery. On the right side, removal of the posterior mediastinal goiter may be difficult for the reason that the narrow space encircled by carotid sheath, right innominate artery, and tracheal and prevertebral fascia prevents the enlarged goiter from being pulled out from the mediastinum. Blind dissection is usually used through a cervical approach based on the fact that intrathoracic goiters are in continuity with the cervical portion and receive their blood supply through branches of the inferior thyroid artery. Preoperative intensive evaluation of the goiters' border and density is very important to avoid a perilous dissection. After deliberate evaluation, a posterior mediastinal goiter, even when the diameter of intrathoracic part is greater than available confines, can be safely removed (as shown in Fig. 1). Therefore, surgeons should endeavor to remove goiters from the mediastinum via cervical incision

before making a decision on whether to employ intrathoracic approaches.

Meticulous dissection of all tissue adhesions around the thyroid gland at the cervical region is essential for completing the removal of goiters and preparing for a consequently intrathoracic approach. Until now, there have been no clear indications for preoperative identification regarding adjunct intrathoracic approaches. The most reported indications for adjunct approaches include the characteristics observed on CT, extension of more than 70% of the gland below the thoracic outlet, and extension below the carina tracheae or the aortic arch.<sup>12,13</sup> Cohen<sup>14</sup> suggested that factors significantly increasing the need for sternotomy include the presence of malignancy, involvement of the posterior mediastinum, extension of the goiter below the aortic arch, and the presence of ectopic goiter. In our series, malignant diseases existed in 4 of 20 patients, all of whom underwent goiter dissection through a cervical approach without additional incision, and all of the 4 thyroid cancers were completely encapsulated. It is the well-defined boundary rather than malignant lesion that determines the difficulty of resecting the mass from the neck. Recurrent SSGs have a greater chance of intrathoracic resection because of structural distortion, adhesion caused by the first operation, and development of a parasitic blood supply to the substernal component of the goiter.<sup>15</sup> McKenzie and Rook<sup>16</sup> analyzed CT image characteristics of SSGs and found thyroid tissue density is the strongest factor and increases the risk of sternotomy 47-fold. Interestingly, we found that right posterior mediastinal goiter may have a greater probability of requiring an intrathoracic approach. The possible reason is that the innominate artery anterior to the goiter confines the removal from thoracic inlet via cervical incision.

Ojanguren Arranz *et al*<sup>8</sup> proposed that transcervical and lateral thoracotomy is the best approach for the complete and safe removal of posterior mediastinal goiter. Meanwhile, the author implies that sternotomy is not suitable to perform dissection for the posterior mediastinal goiter because of the presence of heart and great vessels anterior to the mass, which makes it inaccessible. The novel thoroscopic technique provides a feasible and minimally invasive approach for SSG extending into posterior mediastinum.<sup>17,18</sup> Thoroscopic approach that does not damage the thoracic skeleton offers the benefit of both superior exposure of the paratracheal space and less pain, lower morbidity, and more rapid recovery.

The increased bulk of large goiter and subsequent anatomic variances makes it difficult to identify the RLN and parathyroid glands during thyroidectomies. The literature reported that people with posterior mediastinal goiters are likely to present with postoperative voice problems and hypocalcemia.<sup>11,19</sup> In our series, 5 patients experienced 7 postsurgical complications (7 of 23; 30.4%), including transient hypocalcemia and temporary vocal cord paralysis, which is similar to those in large series of thyroidectomies.<sup>20</sup> In addition to meticulous dissection during operation, the collaboration of thyroid and thoracic surgeons is important for the prevention of postsurgical complications, based on our experiences.

## Conclusions

In conclusion, posterior mediastinal goiters are more likely to be presented with compression symptoms. Most posterior mediastinal goiters can be safely removed by a single cervical approach. A thoracoscopic approach proposes a feasible new treatment strategy.

## Acknowledgments

This study was supported by the National Natural Science Foundation of China (grant nos. 81372860 and 81672885).

## References

- Haller A. *Disputationes Anatomicae Selectae*. Göttingen: Vandenhoeck, 1749
- Vadasz P, Kotsis L. Surgical aspects of 175 mediastinal goiters. *Eur J Cardiothorac Surg* 1998;**14**(4):393–397
- Sand ME, Laws HL, McElvein RB. Substernal and intrathoracic goiter: reconsideration of surgical approach. *Am Surg* 1983;**49**(4):196–202
- Huins CT, Georgalas C, Mehrzad H, Tolley NS. A new classification system for retrosternal goitre based on a systematic review of its complications and management. *Int J Surg* 2008;**6**(1):71–76
- Agha A, Glockzin G, Ghali N, Iesalnieks I, Schlitt HJ. Surgical treatment of substernal goiter: an analysis of 59 patients. *Surg Today* 2008;**38**(6):505–511
- Katlic MR, Wang CA, Grillo HC. Substernal goiter. *Ann Thorac Surg* 1985;**39**(4):391–399
- Randolph GW. Surgery of cervical and substernal goiter. In: Randolph GW. *Surgery of the Thyroid and Parathyroid Glands*. 2nd ed. Philadelphia, PA: Saunders, 2012:63–77
- Ojanguren Arranz A, Baena Fustegueras JA, Ros Lopez S, Santamaria Gomez M, Ojanguren Arranz I, Olsina Kissle JJ. Best approach for posterior mediastinal goiter removal: transcervical incision and lateral thoracotomy. *Arch Bronconeumol* 2014;**50**(6):255–257
- Testini M, Pasculli A, Di Meo G, Ferraro V, Logoluso F, Minerva F *et al*. Advanced vessel sealing devices in total thyroidectomy for substernal goitre: a retrospective cohort study. *Int J Surg* 2016;**35**:160–164
- Khan MN, Goljo E, Owen R, Park RC, Yao M, Miles BA. Retrosternal goiter: 30-day morbidity and mortality in the transcervical and transthoracic approaches. *Otolaryngol Head Neck Surg* 2016;**155**(4):568–574
- Nankee L, Chen H, Schneider DF, Sippel RS, Elfenbein DM. Substernal goiter: when is a sternotomy required? *J Surg Res* 2015;**199**(1):121–125
- Mackle T, Meaney J, Timon C. Tracheoesophageal compression associated with substernal goitre: correlation of symptoms with cross-sectional imaging findings. *J Laryngol Otol* 2007;**121**(4):358–361
- Flati G, De Giacomo T, Porowska B, Flati D, Gaj F, Talarico C *et al*. Surgical management of substernal goitres: when is sternotomy inevitable? *Clin Ter* 2005;**156**(5):191–195
- Cohen JP. Substernal goiters and sternotomy. *Laryngoscope* 2009;**119**(4):683–688
- Hsu B, Reeve TS, Guinea AI, Robinson B, Delbridge L. Recurrent substernal nodular goiter: incidence and management. *Surgery* 1996;**120**(6):1072–1075
- McKenzie GA, Rook W. Is it possible to predict the need for sternotomy in patients undergoing thyroidectomy with retrosternal extension? *Interact Cardiovasc Thorac Surg* 2014;**19**(1):139–143
- Bhargav PR, Amar V, Mahilvayganan S, Nanganandadevi V. Feasibility of thoracoscopic approach for retrosternal goitre (posterior mediastinal goitre): personal experiences of 11 cases. *J Minim Access Surg* 2016;**12**(3):240–244
- Gupta P, Lau KK, Rizvi I, Rathinam S, Waller DA. Video assisted thoracoscopic thyroidectomy for retrosternal goitre. *Ann R Coll Surg Engl* 2014;**96**(8):606–608
- Heineman TE, Kadkade P, Kutler DI, Cohen MA, Kuhel WI. Parathyroid localization and preservation during transcervical resection of substernal thyroid glands. *Otolaryngol Head Neck Surg* 2015;**152**(6):1024–1028
- Padur AA, Kumar N, Guru A, Badagabettu SN, Shanthakumar SR, Virupakshamurthy MB *et al*. Safety and effectiveness of total thyroidectomy and its comparison with subtotal thyroidectomy and other thyroid surgeries: a systematic review. *J Thyroid Res* 2016;**2016**:7594615