



Iatrogenic Port Site Parasitic Myoma; Case Report and Literature Review.

Nicel Tasdemir¹, Remzi Abali¹, Didem Akkus¹, Mucahit Dogru², Ufuk Goker Tasdemir³

¹Namik Kemal University Faculty of Medicine, Department of Obstetrics and Gynecology, Altinova, 59100, Tekirdag, Turkey

²Namik Kemal University Faculty of Medicine, Department of Radiology, Altinova, 59100, Tekirdag, Turkey

³Optimed Hospital, Department of Obstetrics and Gynecology, Cerkezkoy, 59500, Tekirdag, Turkey

Introduction: We report a case of iatrogenic parasitic myoma of the anterior abdominal wall and discuss the differential diagnosis, treatment, and prevention of complication with relevant literature.

Case Report: A 33-year-old woman presented with anterior abdominal wall mass 3 years after initial laparoscopic myomectomy surgery. A mass with a 38 × 26 mm diameter was observed in the anterior abdominal wall at the site of inferior left side port of previous surgery. It was excised from the anterior abdominal wall outside of the peritoneum, below the fascia. The pathologic examination of the excised mass revealed cellular myoma. This case is the 4th port site parasitic myoma in literature.

Conclusion: The risk of implantation and subsequent growth of minute myoma fragments should be kept in mind during morcellation procedures and, in order to avoid such complications, all fragments should be tracked during morcellation. The inspection of trocar sites after the removal of trocars for retained fragments would prevent such recurrences.

Key words: Abdominal wall – Iatrogenic parasitic myoma – Laparoscopic myomectomy – Port site

Corresponding Author: Nicel Tasdemir, MD, Namik Kemal University, Faculty of Medicine, Department of Gynecology and Obstetrics, 100. yil Mah. Barbaros Cad, No:132, Tekirdag/Turkey.

Tel.: +90 282 2620130, +90 505 8198668; Fax: +90 282 2626810; E-mail: nicelta@gmail.com, ntasdemir@nku.edu.tr

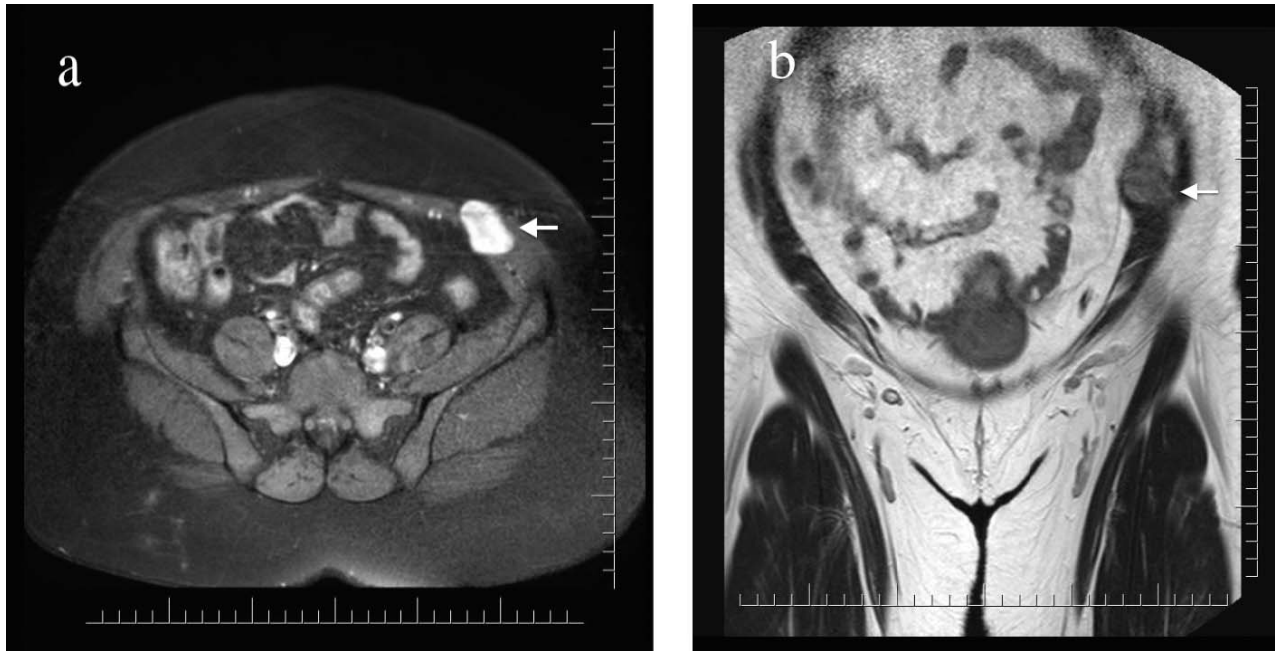


Fig. 1 (a) T1 weighted axial MR image shows homogenous enhancing, extra-peritoneal, infra-fascial mass (arrow) within the anterior abdominal wall muscles. (b) T2 weighted coronal image shows the mass (arrow).

Myoema uteri is the most common type of female pelvic tumor. Twenty percent of women of reproductive age have clinically detectable myomas, whereas 70%–75% have subclinical myomas.¹ Surgery is the definitive treatment modality for symptomatic myomas. Advances in technology provide minimally invasive options for surgical interventions.^{2,3} Laparoscopic, hysteroscopic, and robotic techniques are assigned in selected cases. The minimally invasive techniques have advantages such as shorter hospital stay, better cosmetic results and less pain and less morbidity. However, the myomas should be divided into small parts in order to remove them from the abdominal cavity through the trocar port. The disseminated small particles can cause parasitic myomas in limited occasions. In our case report, we present an extremely rare complication of laparoscopic myomectomy.

Case Report

A 33-year-old gravida 1, parity 1 woman presented with menorrhagia to the outpatient gynecology clinic of Namik Kemal University Hospital in 2011. An ultrasound examination of the patient revealed a 54 × 62 mm intramural myoma located in the posterior wall of the uterus. The myoma was excised

by laparoscopic myomectomy and a power morcellator (Karl Storz, Germany) was used to remove the myoma from the abdominal cavity through the trocar port. We used 3 ports with a 5-mm diameter including 2 right and left inguinal ports and 1 left upper quadrant port. We used another 10-mm intraumbilical port for optic. We did not observe any disseminated intraperitoneal leiomyomatosis during the surgery. The pathologic examination of the excised myoma was reported as cellular leiomyoma.

The follow-up interval was 6 months for the 1st year and then annual thereafter. We observed a new intraural myoma with a 20 × 25 mm diameter on the 1st-year visit. However, it was stable during the follow-up. The patient mentioned left inguinal region tenderness and a palpable mass at the last visit in 2014. The physical examination revealed a palpable semimobile mass. The location of the mass was below the left inguinal trocar incision. An abdominal MRI showed a 38 × 26 mm well circumscribed, homogenous-enhancing mass within the muscles of the anterior abdominal wall (Fig. 1).

The mass was excised with a 4 cm incision under general anesthesia. It was located below the fascia of the abdominal wall but outside of the peritoneum (Fig. 2). The pathologic examination of the mass revealed cellular leiomyoma.

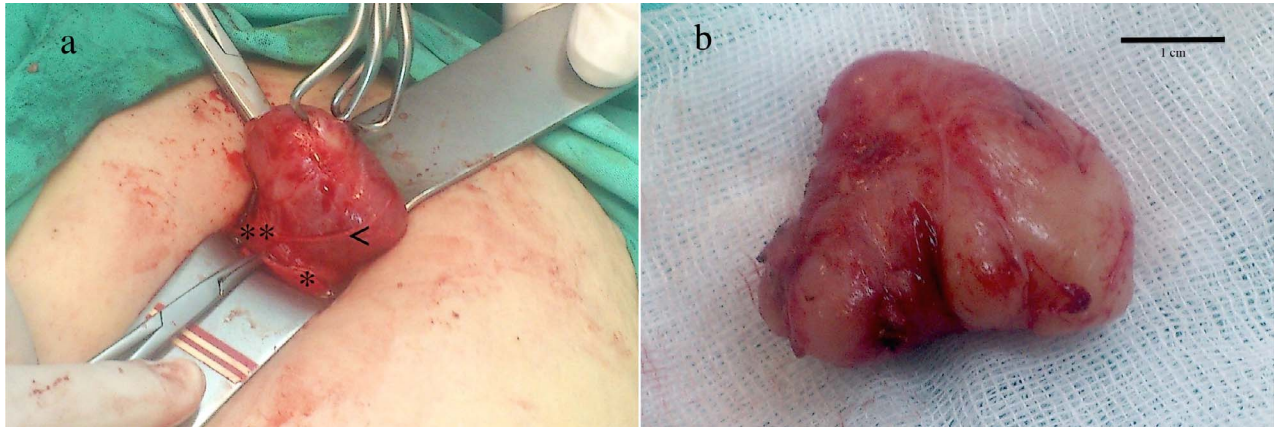


Fig. 2 (a) Figure shows intraoperative appearance of parasitic myoma, (*) shows the cut fascia that was dissected to be able to reach mass, (**) shows anterior abdominal wall muscles, (<) shows vessels arising from anterior abdominal wall muscles through mass. (b) Appearance of mass after excision.

The intuitional review board of Namik Kemal University approved presentation of the case report (no: 2015/29/02/17).

Discussion

Laparoscopic and robotic techniques are advantageous due to their low postoperative morbidity. However, during laparoscopic myomectomy, the excised mass should be broken into smaller parts in order to take it out of the abdominal cavity. Therefore, various morcellation techniques are described in the literature.^{4,5} The minute fragments would retain or spread in the abdominal cavity during the morcellation process. Thus, the anxiety involved in spreading possible malignancies, which cannot be identified prior to surgery, is a major concern. In April, 2014, the US Food and Drug Administration (FDA) issued a warning about using morcellators, especially on perimenopausal and postmenopausal women or women who are at high risk for malignancy. Moreover, the FDA suggested obtaining informed consent regarding the use of morcellators (For the risks such as dissemination of tumor cells with power morcellation and possible poor prognosis due to dissemination). The American College of Obstetricians and Gynecologists (ACOG) published a special report about the possible complications of morcellation and pointed to the need for risk assessment before the use of power morcellators. On the other hand, the dissemination of benign leiomyoma particles and the potential for recurrent disease are other rare issues of minimally invasive techniques and morcellation.

A total of 42 cases were reported indicating iatrogenic parasitic myomas in the literature.⁶ Most of the reports were after 2006 when the use of power morcellators became widespread. Six of these cases were observed after laparotomy and the rest of the cases were observed after laparoscopic procedures.

The recurrences were observed in different anatomic locations such as the uterus, ovaries, bowels, liver, gallbladder, and the omentum. Only 3 cases of port site parasitic leiomyomas were reported.⁷⁻⁹ The 2-port site parasitic leiomyomas were diagnosed 3 years after the initial surgery, which is similar to our case. The incisional endometriosis would be the differential diagnosis of such a lesion. The location of the lesion may be beneficial in differential diagnosis. In 3 reports, and in our case, the lesion was located just below the anterior abdominal wall fascia and out of the peritoneum. However, most of the incisional endometriosis cases are located over the abdominal fascia.

The risk of implantation and subsequent growth of minute myoma fragments should be kept in mind during morcellation procedures and, in order to avoid such complications, all fragments should be tracked during morcellation. The inspection of trocar sites after the removal of trocars for fragments would prevent such recurrences. Moreover, in-bag morcellation techniques would also reduce iatrogenic parasitic myoma.⁵ With this technique the surgeon introduces a transparent bag and inflates it in the peritoneal cavity. The mass is morcellated in the bag so the small particles stay inside the bag. The technique applied in animal models and various case reports without any complications.¹⁰

Acknowledgments

Financial Support: none; Conflict of Interest: nothing to declare.

References

1. Lee CL, Wang CJ. Laparoscopic myomectomy. *Taiwanese J Obstet Gynecol* 2009;**48**(4):335–341
2. Istre O, Langebrekke A, Qvigstad E. Changing hysterectomy technique from open abdominal to laparoscopic: new trend in Oslo, Norway. *Minim Invasive Gynecol* 2007;**14**(1):74–77
3. Hurst BS, Matthews ML, Marshburn PB. Laparoscopic myomectomy for symptomatic uterine myomas. *Fertil Steril* 2005;**83**(1):1–23
4. Ou CS, Harper A, Liu YH, Rowbotham R. Laparoscopic myomectomy technique. Use of colpotomy and the harmonic scalpel. *J Reprod Med* 2002;**47**(10):849–853
5. Einarsson JI, Cohen SL, Fuchs N, Wang KC. In-bag morcellation. *J Minim Invasive Gynecol* 2014;**21**(5):951–953
6. Huang PS, Chang WC, Huang SC. Iatrogenic parasitic myoma: a case report and review of the literature. *Taiwan J Obstet Gynecol* 2014;**53**(3):392–396
7. Ostrzenski A. Uterine leiomyoma particle growing in an abdominal-wall incision after laparoscopic retrieval. *Obstet Gynecol* 1997;**89**(5 pt 2):853–854
8. Paul PG, Koshy AK. Multiple peritoneal parasitic myomas after laparoscopic myomectomy and morcellation. *Fertil Steril* 2006;**85**(2):492–493
9. Moon HS, Koo JS, Park SH, Park GS, Choi JG, Kim SG. Parasitic leiomyoma in the abdominal wall after laparoscopic myomectomy. *Fertil Steril* 2008;**90**(4):1201 e1–2
10. Rimbach S, Holzknacht A, Nemes C, Offner F, Craina M. A new in-bag system to reduce the risk of tissue morcellation: development and experimental evaluation during laparoscopic hysterectomy. *Arch Gynecol Obstet* 2015;**292**(6):1311–1320