



Long-Term Survival of Rectal Cancer With Lung Metastasis—A Case Report of Possible Metronomic Effect of Tegafur-Uracil

Tzu-Chi Hsu^{1,2,3}, Ming-Jen Chen^{1,3}

¹*Division of Colon and Rectal Surgery, Department of Surgery, Taipei Mackay Memorial Hospital, Taipei, Taiwan*

²*Department of Surgery, Taipei Medical University, Taipei, Taiwan*

³*Department of Surgery, Mackay Medical School, Taipei, Taiwan*

Background: A 76-year-old woman underwent a low anterior resection in May 2000 for a moderately differentiated Dukes' C adenocarcinoma of rectum. She started to take fluorouracil and leucovorin as adjuvant chemotherapy after surgery. A chest X-ray taken 7 months later was reported as having an irregular soft tissue nodule in right middle lung field. A subsequent computerized tomography (CT) scan of chest confirmed the lesion. A thoracotomy was suggested; however, the patient refused surgery. She also refused needle biopsy of the lung lesion for making a definite diagnosis.

Case summary: The patient had been continuously taking fluorouracil and leucovorin as chemotherapeutic agent; in July 2001 she was switched to tegafur-uracil (UFUR) and leucovorin. She was admitted in October 2005 for shortness of breath. After conservative management, her condition improved and she was discharged. The patient still refused any workup for tissue diagnosis and any further aggressive treatment. Since then, she had been continuously taking UFUR and leucovorin then. An abdominal CT scan of in December 2009 was negative for metastasis. Several ultrasound examinations were also reported as having no metastasis in the follow-up period. A chest CT scan did show slow enlargement of the lung metastasis. Her carcinoembryonic antigen level was 3.85 ng/mL prior to surgery, and then fluctuated between 2.42 ng/mL and 6.34 ng/mL. In spite of progressive enlargement of the mass in her lung, the patient is asymptomatic and living well by herself. The only medication she is taking at the moment is UFUR and leucovorin.

Reprints: Tzu-Chi Hsu, MD, FACS, FACRS, Division of Colon and Rectal Surgery, Department of Surgery, Taipei Mackay Memorial Hospital, Taipei, Taiwan, No. 92, Section 2, Chung-San North Road, Taipei, Taiwan.
Tel.: 011 8862 2543 3535; Fax: 011 8862 2543 3642; E-mail: tzuchi@mmh.org.tw

Conclusions: This case suggested that long-term survival could be observed in a patient with metastatic disease from rectal cancer without aggressive chemotherapy. The metronomic effect of UFUR and leucovorin might be contributory to the patient's long-term survival. Elevation of CEA level is not necessarily observed with the presence and progress of metastasis of rectal cancer.

Key words: Rectal cancer – Lung metastasis – Computerized tomography – Tegafur-uracil

Incidence of colorectal cancer is increasing worldwide, and many of the people who have the disease die of it.^{1,2} Long-term survival is possible with curative resection and multiple modality of treatment.^{3,4} However, even with the recent advancement of multimodality of management, it is still rare to have a patient survive more than 10 years following diagnosis of metastasis from colorectal cancer. This report describes a case of a patient who lived more than 14 years without surgery or aggressive chemotherapy following the discovery of lung metastasis from rectal cancer.

Case Report

A 76-year-old woman was admitted to the colorectal service of Taipei Mackay Memorial Hospital on April 28, 2000, following a diagnosis of rectal cancer. She had a low anterior resection on May 1, 2000, and was discharged a week later following an uneventful postoperative course. Pathology reported it was a moderately differentiated Dukes' C adenocarcinoma, with 2 of 13 lymph nodes showing metastasis. She started to take 300 mg of fluorouracil and 45 mg of leucovorin per day as adjuvant chemotherapy. At follow-up, a chest X-ray taken on December 1, 2000, was reported as "having an irregular soft tissue nodule, measured about 2 cm in diameter in the right middle lung field." A computerized tomography (CT) scan of chest on December 27, 2000, was reported: "a mass lesion about 2.5×2×2 cm in size is noted in the right upper lobe, irregular border of the lesion is noted." She was admitted on January 30, 2001, for the preparation of a thoracotomy. However, the patient refused surgery and was discharged against advice on February 6, 2001. She also refused needle biopsy of the lung lesion for making a definite diagnosis.

Because the patient was unwilling to undergo aggressive chemotherapy or biologics, she was continuously taking 300 mg of fluorouracil and 45 mg of leucovorin per day in the clinic. Oral chemotherapeutic agent was then switched to 400 mg of

tegafur-uracil (UFUR, TTY BioPharm Co Ltd, Taipei, Taiwan) and 60 mg of leucovorin per day from July 16, 2001. On October 3, 2005, she visited our clinic and complained about exertional dyspnea. She was admitted on October 4, 2005, for management of her lung metastasis. After conservative management, her condition improved, and she was discharged on October 7, 2005. During the admission, CT scan of chest on October 6, 2005, was reported as "a 3 cm speculated mass with mild enhancement in the right lower lobe compatible with lung metastasis from colon cancer. Another small nodule abutting the left major fissure is also noted. Lung metastasis can not be ruled out." The patient refused any workup of tissue diagnosis and any further aggressive treatment. Starting then, she took continuously 400 mg of UFUR and 60 mg of leucovorin per day. An abdominal CT scan on December 25, 2009, reported: "Status of rectal cancer post LAR without CT evidence of local recurrence or distant metastasis." Report of a chest CT scan on March 24, 2010, was "A 3.5×3.2cm enhancing lobulated soft tissue tumor abutting Rt. minor fissure with RUL and RLL extension, appearing mild enlargement as compared with last chest CT taken on Oct. 06, 2005." On June 4, 2012, repeated chest CT scan was reported as "Slightly enlarged of the lobulated soft tissue tumor abutting Rt. minor fissure with RUL and RLL extension as compared with last chest CT taken on 2010/03/24." On October 14, 2013, chest CT scan was reported as "Size increase of the lobulated soft tissue tumor (the maximal diameter increased from 3.4cm to 4cm) abutting Rt. minor fissure with RUL and RLL extension as compared with last chest CT taken on 2012/06/04." Last CT scan of chest on October 2, 2014, was reported as "Size increase of the lobulated soft tissue tumor (the maximal diameter increased from 4cm to 4.6cm) abutting Rt. minor fissure with RUL and RLL extension as compared with last chest CT taken on 2013/10/14" (Fig. 1). Her tumor marker of carcinoembryonic antigen (CEA) level was 3.85 ng/microl on May 2, 2000, prior to surgery; 1.31 ng/microl on August 25,

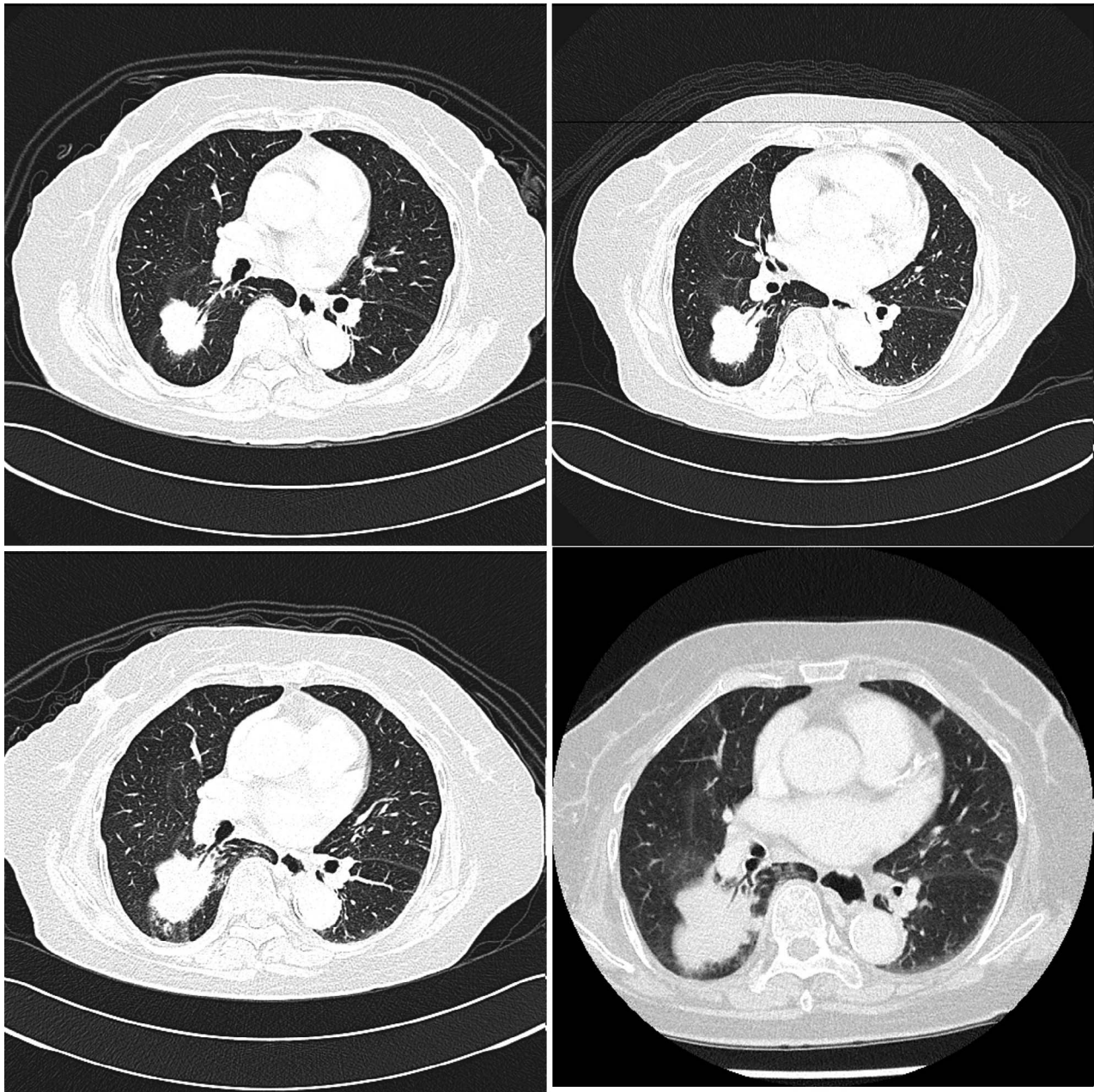


Fig. 1 Change of CT scan of chest (top left taken on March 24, 2010, top right on June 4, 2012, bottom left on October 14, 2013, and bottom right on October 2, 2014).

2000; 3.23 ng/microl on November 29, 2000; 3.92 ng/microl on March 21, 2001; 4.84 ng/microl on June 20, 2001; 6.34 ng/microl on March 24, 2003; 2.42 ng/microl on October 4, 2005; 4.26 ng/microl on March 23, 2010; 3.90 ng/microl on June 4, 2012; 4.12 ng/microl on October 14, 2013. Her last CEA level was 3.83 ng/microl on October 2, 2014 (Fig. 2). In spite of progressive enlargement of the mass in her lung, the patient is asymptomatic and living well by

herself, 15 years following discovery of lung metastasis. The only medication she is taking at the moment is UFUR and leucovorin.

Discussion

Colorectal cancer is the second leading cause of malignancies and the third leading cause of cancer-related death in Taiwan. The principal treatment

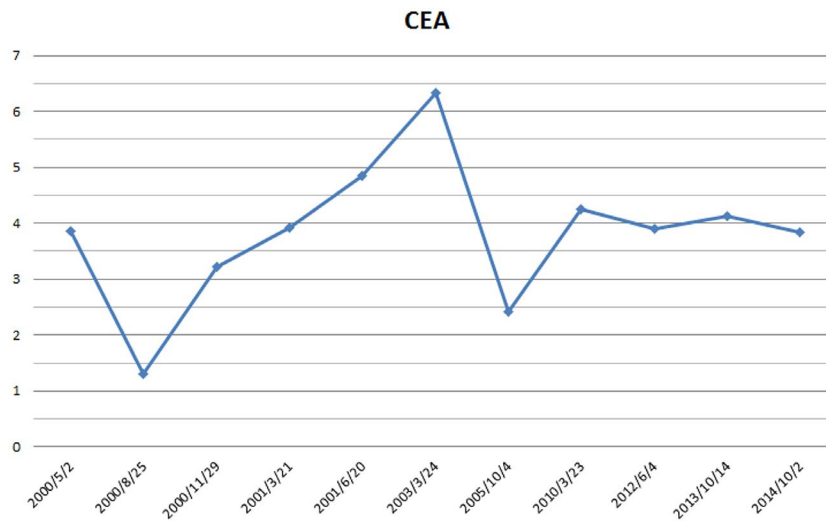


Fig. 2 Serial change of CEA.

strategy for colorectal cancer is curative resection. Chemotherapy is currently the main treatment for metastatic and recurrent cancer disease.^{3,5} Many of those metastases or recurrences have been proven to respond well to chemotherapy.³⁻⁵ Although chemotherapy is currently the main treatment for metastatic disease,³⁻⁶ the aim of chemotherapy is not to cure but to control the disease. It is not unusual to see patients living with metastatic disease for a few years; however, it is certainly very unusual to have a patient live with metastatic disease 14 years following detection of the metastatic disease. Besides, the patient was not undergoing aggressive chemotherapy, such as intravenous irinotecan or oxaliplatin, which are the gold standard of chemotherapy today. Nor did the patient receive any biologics, such as bevacizumab or cetuximab.

Tegafur, an oral fluoropyrimidine, is metabolized to fluorouracil (5-FU) *in vivo*, and it has been reported to be active and less toxic in the management of metastatic colorectal cancer. Uracil is a naturally occurring pyrimidine that is capable of incorporating into nucleic acids. Oral UFUR comprises tegafur, which is an oral prodrug of 5-FU, combined with uracil in 4:1 molar ratio. Preclinical studies showed that the combination of tegafur and uracil was associated with higher plasma levels of 5-FU than with tegafur alone, and this difference was associated with greater antitumor activity. Two phase 3 studies comparing uracil-tegafur/leucovorin and 5-FU/leucovorin have shown that the response rate, time to progression, and overall survival were similar between the 2 regimens, with overall survival of 12 to 13 months. On the other hand, diarrhea, nausea and vomiting, and stomatitis

and mucositis were significantly less frequent with uracil-tegafur/leucovorin, as was myelosuppression.^{7,8} Besides, UFUR and its metabolites inhibited tumor-induced angiogenesis in an *in vivo* mode via a pathway linked with vascular endothelial growth factor that was the most potent angiogenic factor.^{9,10} The metronomic effect of UFUR and leucovorin was also mentioned in the literature with long-term survival of patients with metastasis.¹¹

Oral chemotherapy of UFUR and leucovorin is advantageous because there is no requirement for admission, no requirement for additional apparatus for injection, good tolerance by most patients, and acceptable hematologic and nonhematologic side effects. Disadvantages include poor patient compliance for various reasons, such as lacking the desire to take oral medications, and side effects, such as vomiting and diarrhea, may affect the actual intake of oral medications.

Gold and Freedman^{12,13} identified CEA in extracts from colon cancer tissue. Thompson *et al*¹⁴ described a radioimmunoassay for CEA in the serum and reported positive results in 97% of patients with colon cancer.

Levels of CEA can be applied usefully in assessing the prognosis of individuals with colorectal cancer. Subsequent elevation after return to normal levels implies recurrence of the tumor. The primary application of the CEA test is for the postoperative patients, when increased values suggest recurrence and persistently normal values suggest absence of recurrence. However, the patient in this report did not have any elevation of CEA level over the years, and so this was not helpful in assessing the progress of the tumor. The only

reliable tool for assessment of metastatic disease for the patient relies on the image study of CT scan. During the 14 years there has been slow growth of the tumor mass. However, the patient is still living well with her metastasis, without any disability. The reason for this might be the patient's own strong immunity, and also possibly the metronomic effect of the UFUR and leucovorin.

This case suggested that long-term survival could be observed in some patients with metastatic disease from rectal cancer, without aggressive chemotherapy. The metronomic effect of UFUR and leucovorin might contribute to the patient's long-term survival. Elevation of CEA is not necessarily observed with the presence and progression of metastasis of rectal cancer.

Limitation of the report was that there was no biopsy-proven metastasis because the patient refused any kind of surgery, including biopsy, for her lung lesion. However, many modern clinical trials have not required all patients to have tissue proof of metastatic lesion before entering of the trials. With a clear history of colon cancer and the progressive growth of the lung lesion for years, truly a diagnosis of a metastatic lesion should be logical and reasonable.

References

1. Jemal A, Tiwari RC, Murray T, Ghafoor A, Samuels A, Ward E *et al.* Cancer statistics 2004. *CA Cancer J Clin* 2004;**54**(1):8–29
2. Parkin DM, Pisani P, Ferlay J. Global cancer statistics. *CA Cancer J Clin* 1999;**49**(1):33–64
3. Yeh KH, Cheng AL, Lin MT, Hong RL, Hsu CH, Lin JF *et al.* A phase II study of weekly 24-hour infusion of high-dose 5-fluorouracil and leucovorin (HDFL) in the treatment of recurrent or metastatic colorectal cancers. *Anticancer Res* 1997;**17**(5B):386–371
4. Douillard JY, Cunningham D, Roth AD, Navarro M, James RD, Karasek P *et al.* Irinotecan combined with fluorouracil compared with fluorouracil alone as first-line treatment for metastatic colorectal cancer: a multicenter randomized trial. *Lancet* 2000;**355**(9209):1041–1047
5. Van Custem E, Pozzo C, Starkhammar H, Dirix L, Terzoli E, Cognetti F *et al.* A phase II study of irinotecan alternated with five days bolus of 5-fluorouracil and leucovorin in first-line chemotherapy of metastatic colorectal cancer. *Ann Oncol* 1998;**9**(11):1199–2204
6. DeVita VT Jr, Rosenberg SA. *Cancer Principles and Practice of Oncology*. Philadelphia, PA: Lippincott-Raven, 1997:437–452
7. Douillard JY, Hoff P, Skillings JR, Eisenberg P, Davidson N, Harper P *et al.* Multicenter phase III study of uracil/tegafur and oral leucovorin versus fluorouracil and leucovorin in patients with previously untreated metastatic colorectal cancer. *J Clin Oncol* 2002;**20**(17):3605–3616
8. Carmichael J, Popiela T, Radstone D, Falk S, Borner M, Oza A *et al.* Randomized comparative study of tegafur/uracil and oral leucovorin versus parenteral fluorouracil and leucovorin in patients with previously untreated metastatic colorectal cancer. *J Clin Oncol* 2002;**20**(17):3617–3627
9. Bsaki Y, Chikahisa L, Aoyagi K, Miyadera K, Yonekura K, Hashimoto A *et al.* Gamma- Hydroxybutyric acid and 5-fluorouracil, metabolites of UFT, inhibit the angiogenesis induced by vascular endothelial growth factor. *Angiogenesis* 2001;**4**(3):163–173
10. Basaki Y, Aoyagi K, Chikahisa L, Miyadera K, Hashimoto A, Yonekura K *et al.* UFT and its metabolites inhibit cancer-induced angiogenesis via a VEGF-related pathway. *Oncology* 2000;**14**(10 suppl 9):68s–71s
11. Kerbel RS, Kamen BA. The anti-angiogenic basis of metronomic chemotherapy. *Nat Rev Cancer* 2004;**4**(6):423–436
12. Gold P, Freedman SO. Specific carcinoembryonic antigens of the human digestive system. *J Exp Med* 1965;**122**(3):467–481
13. Gold P, Freedman SO. Demonstration of tumor-specific antigens in human colonic carcinomata by immunological tolerance and absorption techniques. *J Exp Med* 1965;**121**:439–462
14. Thompson DM, Krupey J, Freedman SO, Gold P. The radioimmunoassay of circulating carcinoembryonic antigen of the human digestive system. *Proc Natl Acad Sci U S A* 1969;**64**(1):161–167