



## Case Report

# Successful Laparoscopic Treatment for Refractory Rectovaginal Fistula of Behçet's Disease: A Case Report and Review of the Literature

Ryo Inada<sup>1</sup>, Masaharu Oishi<sup>1</sup>, Tomoko Matsumoto<sup>1</sup>, Shigeyoshi Iwamoto<sup>1</sup>, Taku Michiura<sup>1</sup>, Kentaro Inoue<sup>1</sup>, Masanori Kon<sup>1</sup>, Toshiro Fukui<sup>2</sup>, Kazuichi Okazaki<sup>2</sup>, Madoka Hamada<sup>3</sup>

<sup>1</sup>*Department of Surgery, Kansai Medical University, Osaka, Japan*

<sup>2</sup>*The Third Department of Internal Medicine, Kansai Medical University, Osaka, Japan*

<sup>3</sup>*Department of Gastrointestinal Surgery, Kansai Medical University, Osaka, Japan*

Rectovaginal fistula caused by Behçet's disease is extremely rare, and the clinical course is very unfavorable. We describe rectovaginal fistula of Behçet's disease with successful laparoscopic treatment and review the literature. A 30-year-old woman with Behçet's disease was diagnosed with rectovaginal fistula and treated medically after fecal diversion colostomy. However, the fistula remained, and she underwent radical surgery. Laparoscopically, after mobilization of the rectum, the fistula was removed. The rectum was transected on the anal side of the fistula and removed after extraction through the vaginal incision. The vaginal incision was repaired by suturing, and rectal anastomosis was performed using a double-stapling technique. The omentum was fixed between the rectum and vagina, and the operation was completed. Six months after the laparoscopic surgery, no evidence of fistula recurrence has been seen on colonoscopy. We have reported a rare case of rectovaginal fistula of Behçet's disease treated with an altogether new surgical approach that might prove effective for refractory rectovaginal fistula.

*Key words:* Rectovaginal fistula – Behçet's disease – Laparoscopic surgery

---

Corresponding author: Ryo Inada, MD, PhD, Department of Gastrointestinal Surgery, Kansai Medical University Hospital, 2-3-1, Shinmachi, Hirakata, Osaka 573-1191, Japan.

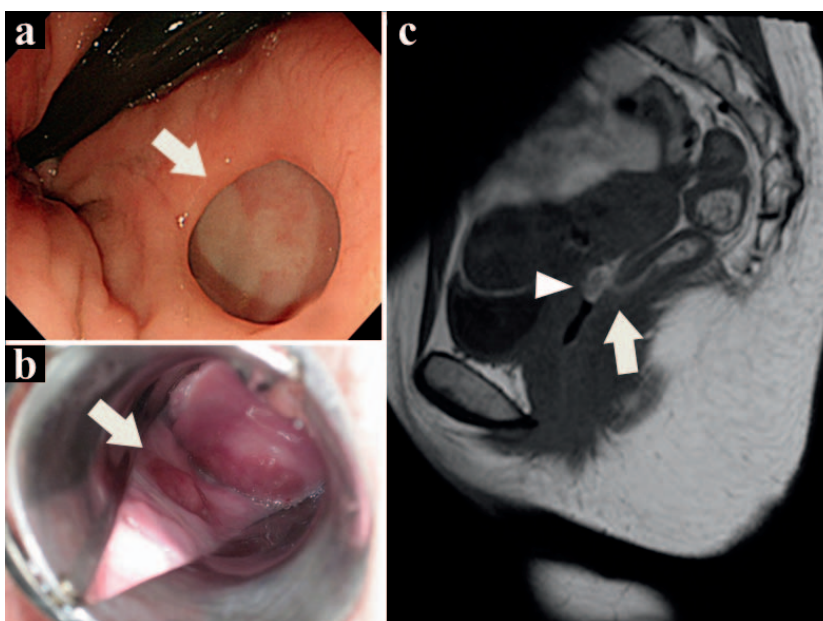
Tel.: +81 72 804 0101; Fax: +81 72 804 2578; E-mail: inadary@hirakata.kmu.ac.jp; ryo\_inada@hotmail.com

Behçet's disease is an inflammatory disorder of unknown etiology, characterized by exacerbated and remitted symptoms, including oral aphthous ulcers, genital ulcers, ocular inflammation, and skin lesions.<sup>1-3</sup> The pathophysiology of Behçet's disease mainly involves systemic vascular injuries leading to ischemic changes, and biopsies of the lesions show nonspecific inflammation with vasculitis.<sup>2-4</sup> Severe ischemic changes caused by vasculitis can lead to fistula formation between neighboring organs.<sup>5</sup> However, rectovaginal fistula caused by Behçet's disease is extremely rare; to the best of our knowledge, only 9 cases have been reported in the English literature.<sup>5-9</sup> In terms of clinical outcomes, most have shown unfavorable courses.<sup>5-8</sup> We describe a patient with refractory rectovaginal fistula caused by Behçet's disease who underwent laparoscopic radical treatment and who achieved good clinical outcomes.

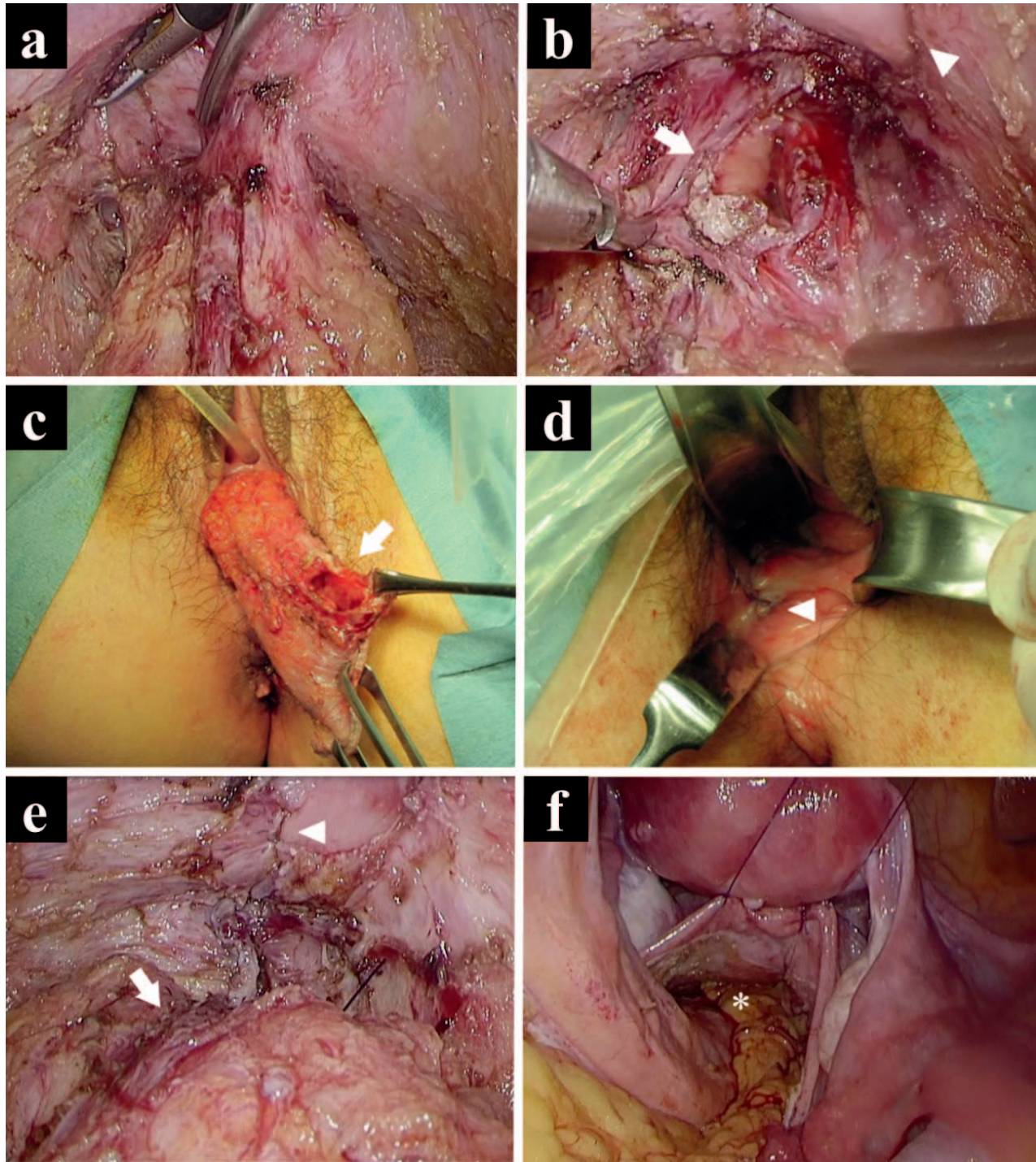
### Case Report

A 30-year-old woman with a history of Behçet's disease was admitted with complaints of involuntary defecation and flatus from the vagina in January 2014. She had received a diagnosis of Behçet's disease in 1994 due to characteristic systemic symptoms, including oral aphthous ulcers, genital ulcers, and erythema nodosum, and her symptoms had exacerbated and remitted after treatment with steroids and colchicine. On this admission, she underwent a colonoscopy, specu-

lum examination, and magnetic resonance imaging, which showed a rectovaginal fistula without other severe colorectal ulcerations (Fig. 1). Biopsy of the rectovaginal fistula showed nonspecific inflammatory changes with no evidence of granuloma. Based on the diagnosis of rectovaginal fistula caused by Behçet's disease, she was administered adalimumab subcutaneously (160 mg in week 0, 80 mg in week 2, and 40 mg every other week after that) and prednisolone (20 mg/day) for 4 months after laparoscopic loop sigmoid colostomy for the purpose of fecal diversion. However, the fistula remained present. We performed radical surgical treatment for this refractory rectovaginal fistula (Fig. 2). Intraoperatively, pneumoperitoneum was achieved, and access to the abdomen was gained using 4 trocars at the periumbilicus, right upper abdomen, right lower abdomen, and left upper abdomen. After posterolateral mobilization of the rectum along the mesorectal plane to the intersphincteric space, the rectovaginal fistula was identified as a well-demarcated passage with a width of about 10 mm. To remove the fistula, we incised the vaginal wall and removed the orifice of the fistula using an ultrasonically activated device. The rectovaginal septum was then dissected as caudally as possible, and the rectum was transected at the anal side of the fistula. The proximal end of the rectum, including the fistula, was extracted through the vaginal incision, and the rectal specimen with the fistula was removed. An anvil head with a diameter of 28 mm (EEA; Covidien, New



**Fig 1** Colonoscopy (a), speculum (b), and magnetic resonance imaging (c) showing the rectovaginal fistula. Feces (arrowhead) flow into the vagina through the round fistula (arrows) in the lower rectum.



**Fig 2** Intraoperative findings. (a) The rectovaginal fistula observed from an abdominal approach. The rectum is mobilized posterolaterally, and the rectovaginal fistula is identified as a demarcated passage. (b) The fistula in the rectum (arrow) and vagina (arrowhead). The rectovaginal fistula is incised and removed on the vaginal side. (c) Transvaginal extraction of the rectum. The rectum is transected on the anal side of the rectal fistula (arrow) and removed. (d) Suture site of the vagina (arrowhead). The vaginal fistula is sutured transvaginally. (e) Rectal anastomosis (arrow) and vaginal suture site (arrowhead). Distance is maintained between the rectal anastomosis and vaginal repair site. (f) The omentum (asterisk) placed between the rectum and vagina. To maintain distance between the rectal anastomosis and vaginal repair site and secure the blood supply, the omentum is fixed by suturing between the rectum and vagina.

Haven, Connecticut) was inserted into the rectal stump. After returning the rectum to the abdominal cavity, the vaginal incision was repaired transvaginally with interrupted 3-0 absorbable sutures. Pneumoperitoneum was re-established, and rectal anastomosis was performed in a double-stapling technique. The operation was completed once the omentum was placed between the rectum and vagina to cover the incision and fixed by suturing. The duration of surgery was 275 minutes, with blood loss of 65 ml. The postoperative course was favorable, and she was discharged on postoperative day 14. Six months after this hybrid natural orifice transluminal endoscopic surgery (NOTES) for rectovaginal fistula of Behçet's disease, a colonoscopy showed no evidence of fistula recurrence or anastomotic leakage, and we are planning closure of the sigmoid colostomy.

## Discussion

The most common cause of rectovaginal fistula is maternal trauma during birth. In terms of inflammatory bowel disease (IBD), almost all cases are caused by Crohn's disease.<sup>10,11</sup> Rectovaginal fistula caused by birth trauma is relatively easy to treat surgically compared with that caused by IBD. A multimodal approach has been recommended for patients with rectovaginal fistula of Crohn's disease, and medical treatment and drainage of local sepsis have been required before definitive surgical repair.<sup>10,11</sup> Although various surgical treatments have been suggested, including direct repair, fistulotomy, fibrin glue instillation, endorectal or vaginal advancement flap, abdominal procedures with colorectal or coloanal anastomosis, and episiotomy, the primary healing rates appear unfavorable, at 29% to 86%, and recurrence rates are reported as relatively high, at 10% to 54%.<sup>10</sup> Rectovaginal fistula caused by Behçet's disease is extremely rare, and only 9 cases appear to have been reported in the English literature.<sup>5-9</sup> Among these, 5 cases were described in detail. Age at onset and duration of illness have been reported as somewhat variable, and 3 cases showed complicated rectovaginal fistula after external stimulation, including episiotomy, transanal endoscopic surgery, and anastomosis after intestinal resection.<sup>5,9</sup> In terms of clinical outcomes, the only case that received multimodal therapy (mucosal advancement flap after fecal diverting stoma and systemic treatment with infliximab) recovered from the rectovaginal fistula, whereas the other cases re-

ceived only either medical or surgical treatment and ended in unfavorable results.<sup>5-9</sup>

Our case had satisfied the clinical criteria for the diagnosis of Behçet's disease<sup>12</sup> and involved rectovaginal fistula after about 20 years of undulating progression. Initially, the patient received medical treatment, including anti-tumor necrosis factor- $\alpha$  antibody, after fecal diversion. The fistula was unfortunately not closed, although symptoms improved. The patient strongly desired to give birth, and we planned radical surgical treatment because the disease was controlled as well as possible after systemic medical treatment. To avoid recurrence after surgical treatment, we paid attention when deciding on a procedure to (1) separate the repair sites between the vaginal and rectal fistula; (2) maintain blood supply to the sites; and (3) relieve tension on the rectal anastomosis. Our hybrid NOTES technique allowed us to maintain distance and blood supply between the vaginal repair site and the rectal anastomotic site by sufficiently mobilizing the rectum on the abdominal approach and placing the omentum between the rectum and vagina. Our procedure seems favorable to prevent anastomotic leakage, because it can reduce tension at the anastomotic site and, furthermore, provide better optical magnification while minimizing invasiveness. We have reported a rare case of rectovaginal fistula of Behçet's disease treated with an altogether new surgical approach that might prove effective for refractory rectovaginal fistula.

## References

1. Kaklamani VG, Vaiopoulos G, Kaklamanis PG. Behcet's disease. *Semin Arthritis Rheum* 1998;**27**(4):197-217
2. Sakane T, Takeno M, Suzuki N, Inaba G. Behcet's disease. *N Engl J Med* 1999;**341**(17):1284-1291
3. Verity DH, Wallace GR, Vaughan RW, Stanford MR. Behcet's disease: from Hippocrates to the third millennium. *Br J Ophthalmol* 2003;**87**(9):1175-1183
4. Ehrlich GE. Vasculitis in Behcet's disease. *Int Rev Immunol* 1997;**14**(1):81-88
5. Chung HJ, Goo BC, Lee JH, Bang D, Lee KH, Lee ES *et al*. Behcet's disease combined with various types of fistula. *Yonsei Med J* 2005;**46**(5):625-628
6. Smith GE, Kime LR, Pitcher JL. The colitis of Behcet's disease: a separate entity? Colonoscopic findings and literature review. *Am J Dig Dis* 1973;**18**(11):987-1000

7. Teh LS, Green KA, O'Sullivan MM, Morris JS, Williams BD. Behcet's syndrome: severe proctitis with rectovaginal fistula formation. *Ann Rheum Dis* 1989;**48**(9):779–780
8. Adiamah A, Wong LS. Behçet's disease: a rare cause of rectovaginal fistula. *BMJ Case Rep* 2010;**2010**:bcr0620103130
9. Chawla S, Smart CJ, Moots RJ. Recto-vaginal fistula: a refractory complication of Behcet's disease. *Colorectal Dis* 2007;**9**(7):667–668
10. Zhu YF, Tao GQ, Zhou N, Xiang C. Current treatment of rectovaginal fistula in Crohn's disease. *World J Gastroenterol* 2011;**17**(8):963–967
11. Andreani SM, Dang HH, Grondona P, Khan AZ, Edwards DP. Rectovaginal fistula in Crohn's disease. *Dis Colon Rectum* 2007;**50**(12):2215–2222
12. Criteria for diagnosis of Behcet's disease. International Study Group for Behcet's Disease. *Lancet* 1990;**335**(8697):1078–1780