

POECIVIRUS IS PRESENT IN INDIVIDUALS WITH BEAK DEFORMITIES IN SEVEN SPECIES OF NORTH AMERICAN BIRDS

Maxine Zylberberg,^{1,4} Caroline Van Hemert,² Colleen M. Handel,² Rachel M. Liu,¹ and Joseph L. DeRisi^{1,3,4}

¹ Department of Biochemistry and Biophysics, University of California, 1700 4th Street, QB3 Room 404, San Francisco, California 94158, USA

² US Geological Survey, Alaska Science Center, 4210 University Drive, Anchorage, Alaska 99508, USA

³ Chan Zuckerberg Biohub, 499 Illinois Street, San Francisco, California 94158, USA

⁴ Corresponding authors (emails: MaxineZylberberg@gmail.com; joe@derisilab.ucsf.edu)

ABSTRACT: Avian keratin disorder (AKD), a disease of unknown etiology characterized by debilitating beak overgrowth, has increasingly affected wild bird populations since the 1990s. A novel picornavirus, poecivirus, is closely correlated with disease status in Black-capped Chickadees (*Poecile atricapillus*) in Alaska, US. However, our knowledge of the relationship between poecivirus and beak deformities in other species and other geographic areas remains limited. The growing geographic scope and number of species affected by AKD-like beak deformities require a better understanding of the causative agent to evaluate the population-level impacts of this epizootic. Here, we tested eight individuals from six avian species with AKD-consistent deformities for the presence of poecivirus: Mew Gull (*Larus canus*), Hairy Woodpecker (*Picoides villosus*), Black-billed Magpie (*Pica hudsonia*), American Crow (*Corvus brachyrhynchos*), Red-breasted Nuthatch (*Sitta canadensis*), and Blackpoll Warbler (*Setophaga striata*). The birds were sampled in Alaska and Maine (1999–2016). We used targeted PCR followed by Sanger sequencing to test for the presence of poecivirus in each specimen and to obtain viral genome sequence from virus-positive host individuals. We detected poecivirus in all individuals tested, but not in negative controls (water and tissue samples). Furthermore, we used unbiased metagenomic sequencing to test for the presence of other pathogens in six of these specimens (Hairy Woodpecker, two American Crows, two Red-breasted Nuthatches, Blackpoll Warbler). This analysis yielded additional viral sequences from several specimens, including the complete coding region of poecivirus from one Red-breasted Nuthatch, which we confirmed via targeted PCR followed by Sanger sequencing. This study demonstrates that poecivirus is present in individuals with AKD-consistent deformities from six avian species other than Black-capped Chickadee. While further investigation will be required to explore whether there exists a causal link between this virus and AKD, this study demonstrates that poecivirus is not geographically restricted to Alaska, but rather occurs elsewhere in North America.

Key words: Avian keratin disorder, beak, bird, deformity, disease, epizootic, picornavirus, virus.

INTRODUCTION

Recently, a widespread epizootic of beak deformities consistent with avian keratin disorder (AKD) has been documented in dozens of avian species in North America and other parts of the world (Handel et al. 2010; Harrison 2011; Zylberberg et al. 2016; British Trust for Ornithology 2020). Birds affected by AKD develop beak deformities characterized by elongation, often with crossing and marked curvature (Handel et al. 2010). These deformities limit the ability of an individual to feed, preen, and cope with parasites, resulting in decreased fitness and survival (Handel et al. 2010; Van Hemert et al.

2012, 2013; Wilkinson et al. 2016). While the population-level impacts of AKD remain unknown, the high prevalence, fitness impacts, and widespread occurrence of AKD across multiple species suggest that this pathology could have negative consequences for wild bird populations (Handel et al. 2010; Van Hemert and Handel 2010; Zylberberg et al. 2016).

Avian keratin disorder was first observed in Alaskan Black-capped Chickadees (*Poecile atricapillus*) in the late 1990s. In Black-capped Chickadees, AKD is typically seen in adult birds, with an average prevalence of 6.5% in south-central Alaska, where most research on this disease has been conducted

(Handel et al. 2010). However, AKD-like deformities are not limited to Alaska or to Black-capped Chickadees. Morphologically similar deformities have been documented in more than 40 avian species in North America and over 30 species in the UK (Craves 1994; Handel et al. 2010; Harrison 2011; British Trust for Ornithology 2020) and appear to be particularly common in corvids, cavity-nesting passerines, and raptors (Handel et al. 2010; Van Hemert and Handel 2010; British Trust for Ornithology 2020). In American Crows (*Corvus brachyrhynchos*; formerly Northwestern Crows, *Corvus caurinus*) in Alaska, AKD-like deformities are even more prevalent than in Black-capped Chickadees, with 17% of adults displaying clinical signs consistent with AKD (Van Hemert and Handel 2010). Moreover, this emergence of beak deformities has occurred concurrently across multiple species and the deformities appear to cluster geographically, with clusters of deformities observed, for example, in Alaska, the Pacific Northwest of North America, and the South of England (Handel et al. 2010; British Trust for Ornithology 2020). While numerous species display similar gross pathology, the cause of these deformities is not known, and so it remains undetermined if a common factor is responsible. The increasing geographic scope and number of species potentially affected by AKD warrant a better understanding of the causative agent in order to evaluate the population-level impacts of this disease.

A variety of factors can contribute to beak deformities, including environmental contaminants, nutritional deficiencies, trauma, and exposure to infectious agents (Dorrestein 2009; Harcourt-Brown 2009). However, multiple studies have failed to find clear evidence of a contaminant exposure, nutritional deficiency, or bacterial or fungal infection underlying AKD (Handel et al. 2010; Van Hemert et al. 2013; Handel and Van Hemert 2015). Using unbiased metagenomic sequencing of beak tissue from Black-capped Chickadees affected by AKD, we previously identified poecivirus, a novel picornavirus, as a potential candidate agent (Zylberberg et al. 2016).

Subsequent screening of 124 Black-capped Chickadees revealed that 28/28 individuals affected by AKD tested positive for poecivirus compared with only 9/96 asymptomatic individuals (Zylberberg et al. 2018). Two American Crows and two Red-breasted Nuthatches (*Sitta canadensis*) with AKD-consistent pathology also tested positive for poecivirus (Zylberberg et al. 2016). Furthermore, we previously used both *in situ* hybridization and a strand-specific expression assay to localize poecivirus to beak tissue of AKD-positive individuals and to provide evidence of active viral replication (Zylberberg et al. 2018). This evidence establishes a strong correlation between disease status in Black-capped Chickadees and the presence of poecivirus (Zylberberg et al. 2016, 2018), although a definitive causal link remains to be tested.

Here, we use targeted PCR followed by Sanger sequencing to test for the presence of poecivirus in the beak and cloacal tissue of four opportunistically collected individuals with deformed beaks, representing four species not previously tested for poecivirus: Mew Gull (*Larus canus*), Hairy Woodpecker (*Picoides villosus*), Black-billed Magpie (*Pica hudsonia*), and Blackpoll Warbler (*Setophaga striata*). We then used unbiased metagenomic sequencing to analyze tissues of six individuals: the Hairy Woodpecker and the Blackpoll Warbler plus two American Crows and two Red-breasted Nuthatches from Alaska that we had previously found to be positive for poecivirus (Zylberberg et al. 2016). We tested these six specimens for the presence of other pathogens and to obtain additional viral genome sequence.

MATERIALS AND METHODS

Specimen collection

We opportunistically obtained one Mew Gull, one Hairy Woodpecker, one Black-billed Magpie, two American Crows, two Red-breasted Nuthatches, and one Blackpoll Warbler with grossly overgrown beaks between 1999 and 2016 (Table 1 and Fig. 1). The Mew Gull, Hairy Woodpecker, and Black-billed Magpie were submitted to a wildlife rehabilitation center in Anchorage, Alaska, and later euthanized. The Blackpoll Warbler

TABLE 1. Avian specimens that exhibited beak overgrowth characteristic of avian keratin disorder were tested for the presence of poecivirus and other pathogens. Common and scientific names of birds, specimen identification, collection location and date, number of next-generation sequencing (NGS) paired-end reads, and tissues in which poecivirus was detected.

Common name	Species	Specimen ID	Location	City, state	Date	NGS reads ^a	Poecivirus detected	
							Beak	Cloaca
Mew Gull	<i>Larus canus</i>	993	61°10'12''N, 149°51'36''W	Anchorage, Alaska	5 September 2016	—	Yes	Yes
Hairy Woodpecker	<i>Picoides villosus</i>	969	61°5'24''N, 149°46'48''W	Anchorage, Alaska	8 April 2015	7.1×10 ⁷	Yes	Yes
Black-billed Magpie	<i>Pica hudsonia</i>	992	61°19'48''N, 149°33'36''W	Eagle River, Alaska	26 August 2016	—	No	Yes
American Crow	<i>Corvus brachyrhynchos</i>	674	58°16'48''N, 134°24'36''W	Juneau, Alaska	11 July 2005	1.4×10 ⁷	Yes	Yes
American Crow	<i>Corvus brachyrhynchos</i>	848	58°21'36''N, 134°34'48''W	Juneau, Alaska	27 February 2007	5.5×10 ⁷	Yes	Yes
Red-breasted Nuthatch	<i>Sitta canadensis</i>	12	61°7'48''N, 149°54'36''W	Anchorage, Alaska	29 March 1999	7.2×10 ⁷	No	Yes
Red-breasted Nuthatch	<i>Sitta canadensis</i>	929	61°24'36''N, 149°28'48''W	Chugiak, Alaska	10 December 2012	5.9×10 ⁷	Yes	Yes
Blackpoll Warbler	<i>Setophaga striata</i>	1020	43°10'12''N, 70°36'36''W	Cape Neddick, Maine	8 November 2016	6.0×10 ⁷	Yes	No

^a — = no NGS data.




FIGURE 1. Specimens exhibiting beak overgrowth characteristic of avian keratin disorder: (A) Mew Gull 993 (*Larus canus*), (B) American Crow 674 (*Corvus brachyrhynchos*), (C) Black-billed Magpie 992 (*Pica hudsonia*), (D) Blackpoll Warbler 1020 (*Setophaga striata*), (E) Hairy Woodpecker 969 (*Picoides villosus*), and (F) Red-breasted Nuthatch 929 (*Sitta canadensis*). Images are not to scale.

was submitted to a wildlife rehabilitation center in Maine and later euthanized. One American Crow was submitted to a wildlife rehabilitation center in Juneau, Alaska, and later euthanized. The second crow was collected by shotgun as part of airport safety measures in Juneau. The two Red-breasted Nuthatches were salvaged after dying in the wild in Anchorage and Chugiak, Alaska. Specimens were stored frozen at -20 C until processed.

All work was conducted with the approval of the US Geological Survey Alaska Science Center Institutional Animal Care and Use Committee (assurance no. 2016-14) and under the US Fish and Wildlife Service Scientific Collecting permit number MB789758.

Detection of poecivirus

We tested for the presence of poecivirus in beak and cloacal tissue from all individuals using targeted PCR primers followed by Sanger sequencing. We extracted RNA from tissue samples using a Direct-zol RNA MicroPrep kit (Zymo Research, Irvine, California, USA). Briefly, 5 mg of tissue was ground using a pellet pestle (cloacal

tissue) or a mortar and pestle on liquid nitrogen (beak tissue) and the extraction proceeded as described in the manufacturer's protocol. Next, 200 ng of RNA were reverse transcribed in 10 μL reactions containing 100 pmol random hexamer, 1 \times reaction buffer, 5 mM dithiothreitol, 1.25 mM (each) deoxynucleoside triphosphates, and 100 U Superscript III (Life Technologies, Carlsbad, California, USA); mixtures were incubated at 25 C for 5 min, 42 C for 60 min, and 70 C for 15 min. Samples were then screened via PCR using poecivirus-specific primers (Table 2). PCR mixtures contained 1 \times iProof master mix (Bio-Rad Laboratories, Hercules, California, USA), 0.5 M primer, and 5 μL complementary DNA. Thermocycler conditions were set at 98 C for 30s, then 40 cycles of 98 C for 10 s, 58–62 C for 10 s, and 72 C for 30 s, and then a 5-min elongation step of 72 C. Annealing temperature was optimized for each set of primers using a gradient cycler. Amplicons were visualized on 1.5% agarose gels, and those in the correct size range were extracted and purified using a Zymoclean gel DNA recovery kit (Zymo Research) and Sanger sequenced (Quintara Biosciences, South San Francisco, California, USA).

TABLE 2. Primers used to test for the presence of poecivirus via PCR.

Primer pair	Primer name	Sequence
1	BCCHpic_2F	CCAACTGAGTCGGATTCTACTG
	BCCHpic_2R	GTGAAACACCACCCAACATCA
2	BCCHpic_9F	GCTGGAAGACTCGCGTAAT
	BCCHpic_9R	TTGCTCCCCACCCATTGTAT
3	Poeci_1F	TGGCTGCTCTAGAGGATAAAGG
	Poeci_1R	ACTGCACTACAACCAAATCTGT
4	Poeci_2F	AGCTTGGCCCTCTAATTGT
	Poeci_2R	GATTACTGTTCCGGTCTCTTGG
5	Poeci_4F	TGGGCATTGTCTCGAGTGTA
	Poeci_4R	TACGAAAAGCCTCAGTCGGA
6	Poeci_8F	TCTTGTTGTGGTGGAGACT
	Poeci_8R	GTGAAACACCACCCAACATCA
7	Poeci_9F	TGTTGATGTTGAGCAGTGTAGC
	Poeci_9R	TTGCTCCCCACCCATTGTAT
8	Poeci_10F	AGCCAATGTATCAAAGTCCAGTG
	Poeci_10R	CGACCGCATATCTTGTACGT
9	Poeci_11F	TGTAATTTGGCAGGGTGTCT
	Poeci_11R	ACTCCTTCAAAGCATCACCC
10	Poeci_12F	GATGTTTTCGTTTGTGGACCT
	Poeci_12R	TGCCTGGACAGATAAGGAGG
11	Poeci_13F	GGGCTCAGATTTTCAATTAAGGG
	Poeci_13R	CTATTCACCTGCACCGACAC
12	Poeci_14F	GAAATCTGGGGCCCAATG
	Poeci_14R	AAGCCTCAGTCGGATTTAACA

Positive controls included beak tissue from three Black-capped Chickadees that had previously tested positive for the presence of poecivirus (Zylberberg et al. 2016). Negative controls included water as well as separate beak and cloacal tissue samples from four Black-capped Chickadees without gross beak deformities and that had previously tested negative for the presence of poecivirus (Zylberberg et al. 2016). When testing of beak and cloacal tissue samples from the same individual resulted in contradictory results, tests were confirmed in triplicate; in each case, the results for each individual tissue were consistent across replicates.

Virus discovery: Sample processing for high-throughput sequencing

A sample of beak tissue and a sample of cloacal tissue from each Hairy Woodpecker, American Crow, Red-breasted Nuthatch, and Blackpoll Warbler were individually subjected to metagenomic deep sequencing (Table 1). The RNA extraction proceeded as described earlier. Samples were prepped for high-throughput sequencing using the NEBNext Ultra RNA Library Prep Kit for Illumina (New England Biolabs, Ipswich,

Massachusetts, USA) following the manufacturer's protocol. Sequencing was conducted on the Illumina HiSeq 4000 using a single sequencing lane and resulted in 135 nucleotide (nt)-long paired-end reads.

Sequence analysis

Sequences were analyzed using Bowtie 2 (Langmead and Salzberg 2012) to align reads to the poecivirus reference genome (GenBank accession no. KU977108; Zylberberg et al. 2016). Aligned reads were assembled to the poecivirus reference genome to obtain consensus sequence from poecivirus present in each specimen. In addition, to conduct an unbiased search for other pathogens that may be present in the specimens, sequences were analyzed using a rapid computational pipeline developed to identify potential pathogens present in metagenomic data as previously described (Doan et al. 2016). The pipeline filters out low-quality reads, identifies the best match for each read in the National Center for Biotechnology Information (NCBI) nt database, and indicates credible organism hits warranting further confirmatory testing if >20 nonredundant read pairs per million read pairs

map to an organism at the species level based on nt alignment. Briefly, reads were aligned to available avian reference genomes: *Corvus brachyrhynchos* (assembly ASM69197v1), *Zonotrichia albicollis* (assembly Zonotrichia_albicollis-1.0.1), and *Geospiza fortis* (assembly GeoFor_1.0). Unaligned (i.e., nonavian) reads were quality-filtered using PriceSeqFilter (Ruby et al. 2013) and compressed by cd-hit-dup (version 4.6.1). Then low-complexity reads were removed via the Lempel-Ziv-Welch algorithm (Ziv and Lempel 1977; Fu et al. 2012). We used GSNAPL (version 2015-12-31; Wu and Nacu 2010) to align the remaining nonavian reads to the NCBI nt database. The same reads were also aligned to the NCBI nonredundant protein database using the Rapssearch2 algorithm (Zhao et al. 2012).

RESULTS

Using targeted PCR followed by Sanger sequencing, we detected poecivirus in 8/8 specimens that displayed AKD-consistent beak deformities, representing six avian species (Table 1). Poecivirus was not detected in negative controls (neither in water nor in beak and cloacal tissue from Black-capped Chickadees without beak deformities and previously confirmed poecivirus-negative). In 6/8 of the specimens with beak deformities, we detected virus in the beak tissue, while in 7/8 we detected virus in the cloaca. The Blackpoll Warbler was the only specimen in which we detected virus in the beak but not in the cloaca. All sequenced regions had high pairwise nt identity (93–96.5%; Fig. 2) to Black-capped Chickadee poecivirus (GenBank no. KU977108).

Unbiased sequencing of RNA from six individuals with beak deformities on the Illumina HiSeq platform generated approximately 1.4×10^7 to 7.2×10^7 126-nt single-read sequences per specimen (Table 1). Retrospective mapping of the sequenced reads to the poecivirus genome revealed the full polyprotein coding region (7,588 nt) of poecivirus in one Red-breasted Nuthatch (929). In addition, it revealed portions of the poecivirus polyprotein coding region of variable size (789–3,166 nt) in the other specimens tested (Fig. 2). Metagenomic sequencing combined with our bioinformatic pathogen discovery pipeline

failed to detect a pathogen other than poecivirus present in the specimens tested.

Comparison to the NCBI nt and non-redundant protein databases revealed that the full polyprotein sequence from Red-breasted Nuthatch 929 (validated by Sanger sequencing) was more closely related to poecivirus than to any other known virus, exhibiting 96.5% pairwise nt identity and 98.2% amino acid identity with poecivirus isolated from Alaskan Black-capped Chickadees (Zylberberg et al. 2016). The 7,588 nt viral genome recovered from the Red-breasted Nuthatch exhibited a total of 267 mutations compared to the Black-capped Chickadee poecivirus genome as determined by Sanger sequencing. Of these mutations, 202 (75.7%) were supported by Illumina sequencing data with an average depth of coverage of 427 reads per nt, and 112 were nonsynonymous. Both our negative controls and the large number of Illumina- and Sanger-confirmed variants observed in this full-length polyprotein support the notion that this sequence did not arise from contaminating poeciviruses previously amplified in this laboratory.

All raw nongenomic data that support the findings of this publication can be found in the accompanying US Geological Survey data release (Zylberberg et al. 2020). Genomic data are available at NCBI (GenBank nos. MN944596–MN944619).

DISCUSSION

In this study, we investigated whether poecivirus was present in individuals of multiple species that exhibited clinical signs consistent with AKD, a disease characterized by gross beak deformities. The concurrent emergence of beak deformities across species and the geographic proximity of clusters lend support to the idea that multiple species are being afflicted by a disease with a common etiology (Handel et al. 2010). While we previously demonstrated a strong association between poecivirus and AKD in Black-capped Chickadees, our current study provided evidence that the same etiologic agent could be

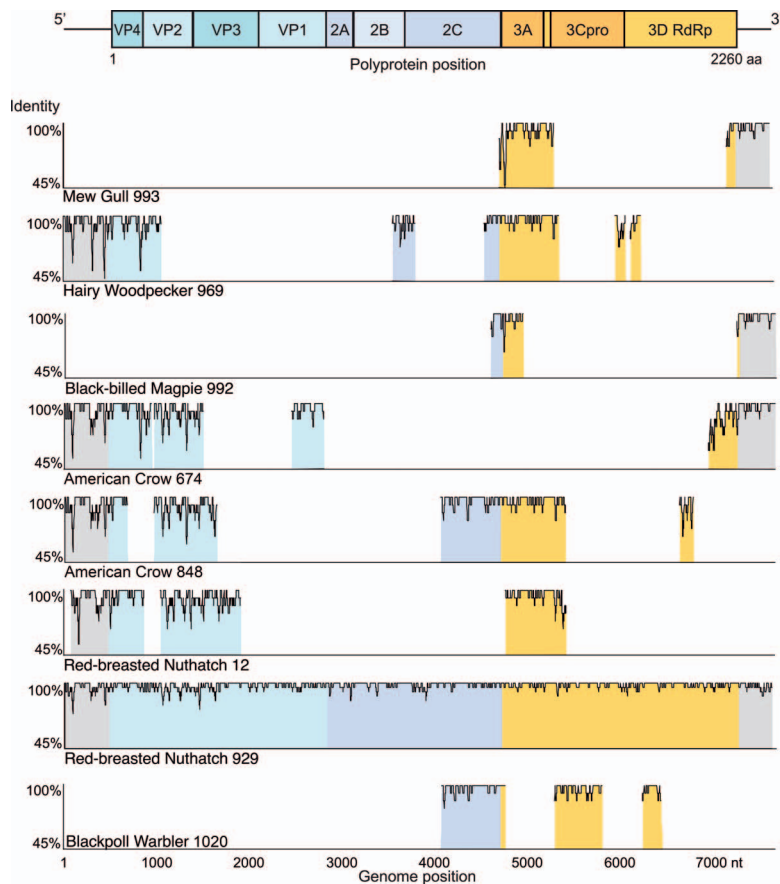


FIGURE 2. Homology to Black-capped Chickadee poecivirus (GenBank no. KU977108). (Top) Predicted poecivirus genome organization. Remaining rows show nucleotide homology between viral sequence obtained from each specimen and poecivirus, measured as the pairwise identity of a moving 15-nucleotide window. Turquoise (VP4, VP2, VP3, VP1) represents viral structural proteins, lavender (2A, 2B, 2C) and orange (3A, 3Cpro, 3d RdRp) represent nonstructural proteins, and gray represents the 5' and 3' noncoding regions.

responsible for similar beak deformities in other avian species.

In keeping with the hypothesis that the emergence of beak deformities across species is causally linked, we found poecivirus to be present in 8/8 (100%) of individuals tested using targeted PCR followed by Sanger sequencing, albeit not consistently across sample types. Meanwhile, unbiased metagenomic sequencing of beak and cloacal tissue failed to detect another candidate pathogen. While we cannot rule out the presence of additional pathogens in other tissues, this result is consistent with our previous finding of poecivirus but no other pathogens in the

beaks of AKD-affected Black-capped Chickadees.

We recovered the complete polyprotein coding region of virus from a single specimen, Red-breasted Nuthatch 929. In addition, we obtained more than 25% of the viral genome from Hairy Woodpecker 969 and American Crow 848 (2.5 kb and 3.2 kb, respectively). Despite efforts to obtain the full polyprotein coding regions of the virus from other specimens, we were unable to do so. This is likely due to the variable condition of the specimens, which were collected opportunistically and underwent variable handling conditions prior to sample processing at the University of California. Sequence analysis

revealed that viruses from Hairy Woodpecker 969, Red-breasted Nuthatch 929, and American Crow 848 (GenBank nos. MN944614–MN944618, MN944596, and MN944600–MN944602, MN 944604, respectively) are closely related to the virus sampled from Black-capped Chickadees, exhibiting 96, 94, and 94% nt identity, respectively, with the poecivirus reference genome (GenBank no. KU977108). In the case of the Red-breasted Nuthatch and American Crow, these data expand upon, and are consistent with, previous analysis of more-limited viral sequences from these specimens (Zylberberg et al. 2016). Except for the Red-breasted Nuthatch, next-generation sequencing of better-preserved specimens will be necessary to obtain the full viral genome from each of these hosts to confirm that they are infected by poecivirus as opposed to a related but distinct species of virus.

Previous studies of poecivirus have largely focused on Black-capped Chickadees from Alaska. Therefore, it was unknown if poecivirus was limited to Alaska. The Blackpoll Warbler included here was the first specimen tested for poecivirus that was collected outside of Alaska (Maine); detection of poecivirus in this specimen provides evidence that this pathogen is present elsewhere in North America. However, Blackpoll Warblers that breed as far west as Alaska stop over on the Atlantic coast of North America on their migration route to South America (DeLuca et al. 2019). We do not know where the individual that we tested became infected with poecivirus.

The focus of our study was to determine whether poecivirus was present in individuals with beak deformities of avian species other than the Black-capped Chickadee. Our sample sizes were small, as specimens were obtained opportunistically and, as a result, our conclusions are necessarily limited. Of particular importance is the lack of corresponding control individuals from the additional species because we had none available to test at the time of this study. However, the lack of detection of poecivirus in negative controls from Black-capped Chickadees indi-

cates that positive detections in the newly tested species were not the result of lab contamination. Moreover, the detection of 202 nt differences between the strain of poecivirus obtained from the Red-breasted Nuthatch, supported by both Sanger and next-generation sequencing data, further corroborates this as a distinct viral specimen. While we have demonstrated the presence of poecivirus in additional species, families, and orders of birds, screening of larger numbers of individuals of each species, including individuals with no clinical signs of AKD, will be required to test the association between poecivirus and beak deformities in these species. The use of cloacal and buccal swabs to test individuals for infection provides an effective, nonterminal method of sampling Black-capped Chickadees for poecivirus (Zylberberg et al. 2018). However, the efficacy of these methods needs to be evaluated in additional species. Ultimately, a viral challenge of healthy individuals with poecivirus is needed to determine with certainty the role of poecivirus in AKD.

ACKNOWLEDGMENTS

We thank Lisa Pajot, Rachel Richardson, Diana Dumais, Sonja Ahlberg, the Bird Treatment and Learning Center, US Department of Agriculture Animal and Plant Health Inspection Service Wildlife Services, and members of the public for assisting with specimen collection. We thank Danielle Gerik for assistance in managing the data release associated with this article. Sarah Sonsthagen and James Angus Chandler provided helpful comments on earlier versions of this manuscript. Funding was provided by a National Science Foundation postdoctoral research fellowship (M.Z.), the Howard Hughes Medical Institute (J.L.D.), the Chan Zuckerberg Biohub (J.L.D.), and the US Geological Survey Ecosystems Mission Area (C.M.H and C.V.H.). Any use of trade, firm, or product names is for descriptive purposes only and does not imply endorsement by the US Government.

LITERATURE CITED

British Trust for Ornithology. 2020. *Species affected, geographical distribution*. British Trust for Ornithology, The Nunnery, Thetford, Norfolk, UK. <http://www.bto.org/volunteer-surveys/gbw/about/>

- background/projects/bgbw/results/species. Accessed July 2020.
- Craves JA. 1994. Passerines with deformed bills. *North Am Bird Bander* 19:14–18.
- DeLuca WV, Woodworth BK, Mackenzie SA, Newman AE, Cooke HA, Phillips LM, Freeman NE, Sutton AO, Tauzer L, McIntyre C, et al. 2019. A boreal songbird's 20,000 km migration across North America and the Atlantic Ocean. *Bull Ecol Soc Amer* 100: e02651.
- Doan T, Wilson MR, Crawford ED, Chow ED, Khan LM, Knopp KA, O'Donovan BD, Xia D, Hacker JK, Stewart JM. 2016. Illuminating uveitis: Metagenomic deep sequencing identifies common and rare pathogens. *Genome Med* 8:90.
- Dorrestein GM. 2009. Nursing the sick bird. In: *Handbook of avian medicine*, 2nd Ed., Tully TN Jr, Dorrestein GM, Jones AK, Cooper JE, editors. Elsevier/Saunders, Philadelphia, Pennsylvania, pp. 101–137.
- Fu L, Niu B, Zhu Z, Wu S, Li W. 2012. CD-HIT: Accelerated for clustering the next-generation sequencing data. *Bioinformatics* 28:3150–3152.
- Handel CM, Pajot LM, Matsuoka SM, Van Hemert C, Terenzi J, Talbot SL, Mulcahy DM, Meteyer CU, Trust KA. 2010. Epizootic of beak deformities among wild birds in Alaska: An emerging disease in North America? *Auk* 127:882–898.
- Handel CM, Van Hemert C. 2015. Environmental contaminants and chromosomal damage associated with beak deformities in a resident North American passerine. *Environ Toxicol Chem* 34:314–327.
- Harcourt-Brown NH. 2009. Psittacine birds. In: *Handbook of avian medicine*, 2nd Ed., Tully TN Jr, Dorrestein GM, Jones AK, Cooper JE, editors. Elsevier/Saunders, Philadelphia, Pennsylvania, pp. 138–168.
- Harrison T. 2011. Beak deformities of garden birds. *Brit Birds* 104:538–541.
- Langmead B, Salzberg SL. 2012. Fast gapped-read alignment with Bowtie 2. *Nat Methods* 9:357–359.
- Ruby JG, Bellare P, DeRisi JL. 2013. PRICE: Software for the targeted assembly of components of (meta) genomic sequence data. *G3 (Bethesda)* 3:865–880.
- Van Hemert C, Armien AG, Blake JE, Handel CM, O'Hara TM. 2013. Macroscopic, histologic, and ultrastructural lesions associated with avian keratin disorder in Black-capped Chickadees (*Poecile atricapillus*). *Vet Pathol* 50:500–513.
- Van Hemert C, Handel CM. 2010. Beak deformities in Northwestern Crows: Evidence of a multispecies epizootic. *Auk* 127:746–751.
- Van Hemert C, Handel CM, O'Brien DM. 2012. Stable isotopes identify dietary changes associated with beak deformities in Black-capped Chickadees (*Poecile atricapillus*). *Auk* 129:460–466.
- Wilkinson LC, Handel CM, Van Hemert C, Loiseau C, Sehgal RNM. 2016. Avian malaria in a boreal resident species: Long-term temporal variability, and increased prevalence in birds with avian keratin disorder. *Int J Parasitol* 46:281–290.
- Wu TD, Nacu S. 2010. Fast and SNP-tolerant detection of complex variants and splicing in short reads. *Bioinformatics* 26:873–881.
- Zhao Y, Tang H, Ye Y. 2012. RAPSearch2: A fast and memory-efficient protein similarity search tool for next-generation sequencing data. *Bioinformatics* 28: 125–126.
- Ziv J, Lempel A. 1977. A universal algorithm for sequential data compression. *IEEE Transact Inform Theory* 23:337–343.
- Zylberberg M, Van Hemert C, Dumbacher JP, Handel CM, Tihan T, DeRisi JL. 2016. Novel picornavirus associated with avian keratin disorder in Alaskan birds. *mBio* 7:e00874-16.
- Zylberberg M, Van Hemert C, Handel CM, DeRisi JL. 2018. Avian keratin disorder of Alaska Black-capped Chickadees is associated with poecivirus infection. *Virology* 15:100.
- Zylberberg M, Van Hemert C, Handel CM, Liu RM, DeRisi JL. 2020. *Data associated with poecivirus testing of individual birds with beak deformities: US Geological Survey data release*. <https://doi.org/10.5066/P9YQCHSR>. Accessed November 2020.

Submitted for publication 29 January 2020.

Accepted 8 August 2020.