

Congenital Diseases in Harbor Seals (*Phoca vitulina richardsii*) from the Salish Sea

Erin R. D’Agnese,^{1,8,9} Dyanna M. Lambourn,² Jennifer K. Olson,³ Jessica L. Huggins,⁴ Stephen Raverty,⁵ Michael M. Garner,⁶ John Calambokidis,⁴ Alyssa A. Scott,³ Steven J. Jeffries,² and Joseph K. Gaydos⁷ ¹D’Agnese EcoConsulting LLC, Sherwood, Oregon 97140, USA; ²Washington Department of Fish and Wildlife, Marine Mammal Investigations, 7801 Phillips Road SE, Lakewood, Washington 98498, USA; ³The Whale Museum, 62 1st Street N, PO Box 945, Friday Harbor, Washington 98250, USA; ⁴Cascadia Research Collective, 218 W 4th Avenue, Olympia, Washington 98501, USA; ⁵Animal Health Center, 1767 Angus Campbell Road, Abbotsford, British Columbia, Canada V3G 2M3; ⁶Northwest ZooPath, 654 W Main Street, Monroe, Washington 98272, USA; ⁷The SeaDoc Society, UC Davis Karen C. Drayer Wildlife Health Center—Orcas Island Office, 942 Deer Harbor Road, Eastsound, Washington 98245, USA; ⁸Current address: University of Washington, School of Marine and Environmental Affairs, 3707 Brooklyn Avenue NE, Seattle, Washington 98105, USA; ⁹Corresponding author (email: erdagnese@gmail.com)

ABSTRACT: Postmortem data for harbor seals (*Phoca vitulina richardsii*) in the Salish Sea were analyzed for epidemiologic trends in congenital diseases. Cleft palate, cleft lips, or both ($n=8$) and cardiac defects ($n=5$) were the most common congenital abnormalities, followed by cases with multiple defects ($n=4$). No temporal trends or spatial clusters of cases were seen from 2003 to 2019, during which time monitoring effort was consistent. Cases could not be linked to specific causes such as environmental contamination or maternal malnutrition. Our study suggests that a yearly prevalence of $2.9\% \pm 2.2$ is the endemic level of congenital disease in this stable harbor seal population. Continued monitoring of birth defects and overall harbor seal population status could help to identify emerging teratogens.

Key words: Birth defects, congenital defects, harbor seal, malformation, *Phoca vitulina*, Puget Sound, Salish Sea.

Congenital diseases (structural or functional developmental abnormalities present at birth) have been previously identified in harbor seals (*Phoca vitulina*). They include odontogenic (Suzuki et al. 1990), cephalic, and occipital bone malformations (Dennison et al. 2009); cleft palate (Suzuki et al. 1992); conjoined twins (Olson et al. 2016); fetus in fetu (Buckles et al. 2006); ectrodactyly (Tarasoff and Piérard 1970); dwarfism (Newby 1971); hemicerebral anomaly (McKnight et al. 2005); intestinal atresia (St. Leger and Nilson 2014); and neuroglial heterotopia (Harris et al. 2011). Congenital deformities in animals can be associated with infectious diseases (Konno et al. 1982), maternal exposure to toxins (Harris et al. 2011), or genetic defects (Mansfield and Land 2002), or they

can be idiopathic and related to disordered embryonic migration and fusion (Olson et al. 2016). Few species-specific spatiotemporal evaluations of congenital diseases have been made at the ecosystem level. We used data from marine mammal mortality investigations to evaluate congenital diseases in the harbor seal population at equilibrium in Washington’s portion of the Salish Sea (SS; Ashley et al. 2020a).

We evaluated postmortem reports from harbor seals stranded from January 1985 to August 2020. Trained biologists or veterinarians completed postmortem examinations on dead-stranded or euthanatized animals (Ashley et al. 2020a). Confirmed cases of congenital disease were those in which defects could be identified as present at birth. Suspect cases could not be confirmed as present at birth. Stable funding facilitated uniform stranding responses beginning in 2003; therefore, 2003–20 data were used for analyses. Gross and histologic examinations were consistent, thorough, and expected to identify congenital diseases. Additional diagnostic tests conducted on cases varied, with the following performed most frequently: aerobic bacterial culture ($n=25$), hepatic trace mineral analysis ($n=22$), and hepatic vitamin A level ($n=19$) (Ashley et al. 2020a, b).

Prevalence of congenital disease in the SS was calculated as number of cases proportionate to the number of necropsied pups. Spatiotemporal analysis was undertaken with a Bernoulli case-control method in SaT-ScanTM (version 9.6; Kulldorff 1997; Kulldorff

and Information Management Services Inc. 2009) to identify case clusters. Additionally, we calculated annual prevalence between 2003 and 2020 in a subpopulation within the region at a consistently and frequently monitored haul-out site (Gertrude Island [GI], Washington; 47°13'2"N, 122°39'38"W). We carried out correlation testing with R software (version 4.0.3; R Core Team 2020), and figures were produced with the package ggplot2 (Wickham 2009) to determine correlations between the yearly number of cases, number examined postmortem, year, and number of dead pups (which includes seals both examined and not examined postmortem).

From 2003 to 2020, 3.0% ($n=29$) of 971 nursing and weaned pups had congenital disease. Three more cases were detected in the 97 animals examined from 1985 to 2002. Cases were widely distributed, and no significant spatiotemporal clusters were identified (Fig. 1).

The most common malformations were orofacial clefts and cardiac defects (Table 1). From the lips, alveolus, and hard and soft palate system used for canids (Moura and Pimpão 2017), cleft lip and palate severity varied (Fig. 2). The least severe case had a unilateral third degree left cleft of the lip, whereas the most severe cases included medial clefts in hard and soft palates. Clefts in lip and alveolus affecting oral alignment occurred in six cases, and medial clefts in hard and soft palates without cleft in the lip or alveolus occurred in two cases.

Congenital hydronephrosis was grossly apparent in pups and presented alone in four cases (one confirmed, three suspect) in which one or both kidneys were enlarged or characterized by degenerate and dilated reniculi and by dilation of the renal pelvis and calyces with no evidence of calculi or other causes of ureteral constriction. The confirmed case was a lanugo pup with underdeveloped kidneys. Additionally, two cases of confirmed hydronephrosis presented with other defects, discussed below. Several heart defects were noted, including a ventricular septal defect, mitral valvular dysplasia

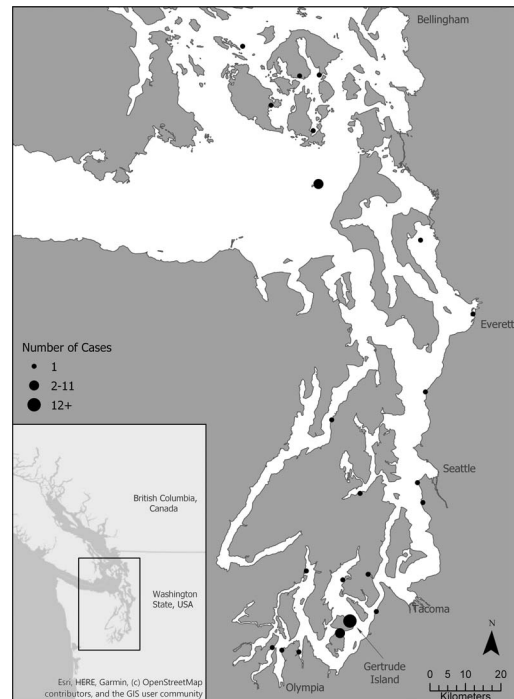


FIGURE 1. Map showing harbor seal (*Phoca vitulina richardsii*) congenital disease case locations in the Washington, USA, inland waters of the Salish Sea ($n=33$) between 1985 and 2020; point size reflects the number of cases at that location.

with associated hydrothorax, myocardial fibrosis, and mitral valvular thickening. Patent foramen ovale were noted in two weaned pups and one yearling, animals older than expected for persistent fetal circulation (Denison et al. 2011).

Dwarfism was seen in two cases without additional defects and in two cases that presented with multiple defects. The four cases of dwarfism had varied presentations, but generally had disproportionately short and malformed flippers (limbs), a diminutive head relative to the length of the body, and the body shorter than is typical for harbor seal pups (Fig. 3).

Four cases had multiple congenital defects. One pup (GI08-20) had hydronephrosis plus myocardial fibrosis. Another (WDFW2015-058) had a cleft lip, tricuspid valve reduction, attenuated valve leaflets of the right atrioventricular valve, associated valvular leaflet nodularity, and dwarfism (Fig. 3). Cleft lip was

TABLE 1. The number of confirmed and suspected cases of each congenital birth defect found in examined harbor seal pups (*Phoca vitulina richardsii*) in Washington, USA, from 1985 to 2020.

Type of defect	Confirmed cases	Suspected cases
Orofacial clefts (cleft palate or lip)	8	0
Cardiac defects	5	0
Multiple defects ^a	4	0
Brain or cranial malformation	2	0
Hydronephrosis	1	3
Dwarfism ^b	2	0
Hiatal hernia	1	0
Scoliosis	1	0
Arthrogryposis (with severe scoliosis)	1	0
Lens triplication (related to cataract)	1	0
Macroglossia	1	0
Anorectal malformation and vaginal artesia	1	0
Malformed flippers (severe: leading to paralysis)	0	1
Hydrothorax	0	1
Premature with elevated hepatic copper	0	1
Total	27	6

^a Cases with multiple defects including dwarfism ($n=2$).

^b Cases with no additional defects.

noted in one of the previously described conjoined twins (2013-SJ013; Olson et al. 2016). One case (WDFW2016-075) presented with dwarfism, cataracts, and abnormally long non-lanugo fur.

Brain and skull malformations were found in two cases. One stillborn pup (WDFW2020-085) had florid hydrocephalus and severely decreased brain mass, with only small remnant portions of cerebral cortex and brain stem; the cerebrum adhered to the perioste-

um of the skull (Fig. 4). This pup also had hydronephrosis. Cerebral spinal fluid volume was markedly increased and cream colored and had marked lymphocytic pleocytosis with chronic hemorrhage. Histologic examination revealed multiple abscesses in the remnant meninges and neuropil. Aerobic culture identified light growth of an unidentified gram-negative rod. The second pup (WDFW2015-050), live-stranded, presented with body tremors and died shortly thereafter. There

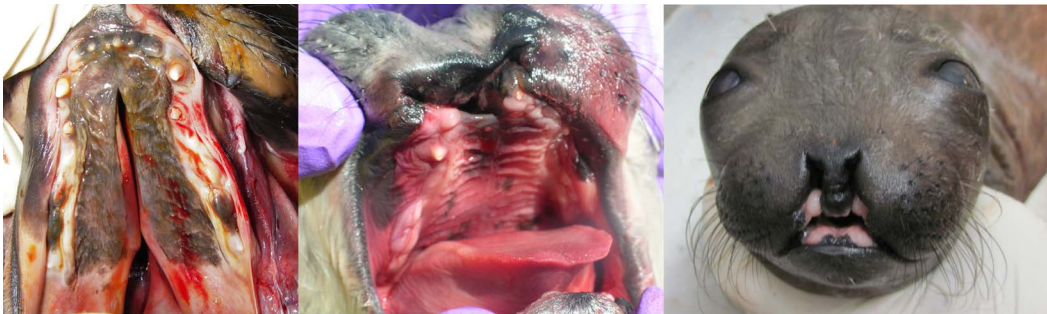

FIGURE 2. Examples of varied severity seen in cleft palate and lip in harbor seal pups (*Phoca vitulina richardsii*) found in the inland waters of Washington, USA, between 1985 and 2003. (left image) Medial third degree cleft in both the hard and soft palate (G106-31); (middle image) bilateral third degree lip clefts and bilateral second (right side) and first degree (left side) alveolar clefts (2007-SJ028); (right image) third degree bilateral cleft lip and first degree cleft alveolus (WDFW2015-058).

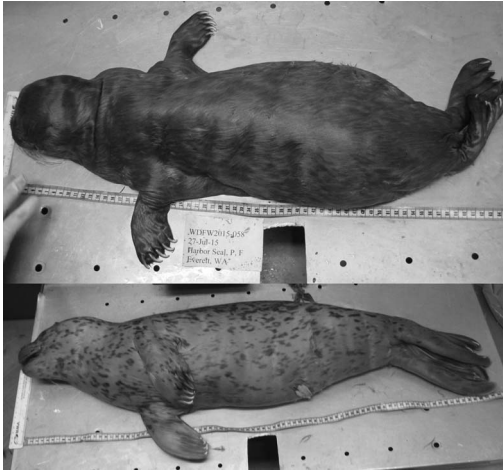

FIGURE 3. (Top) A representative case of harbor seal (*Phoca vitulina richardsii*) dwarfism, evidenced by diminutive head, flipper, and body size; this case was found in 2015 in Everett, Washington, USA, and presented with additional defects of cleft palate and lip and a heart defect (WDFW2015-058); (bottom) for comparison, a normal pup from a similar life-stage.

was bilateral 25% reduction in the size of the cerebellum; cerebellar dysplasia and meningoencephalitis were identified histologically (Fig. 4). In both cases, an infectious etiology presumably related to in utero exposure was considered possible in the pathogenesis of the lesions.

Analysis of the liver as per Ashley et al. (2020b) revealed that 14 of 20 pups with congenital disease (11 confirmed, three suspect) had reduced hepatic vitamin A levels (adult harbor seal reference range: 200–3,500 $\mu\text{g/g}$). Although no apparent gross or histologic lesions could be directly attributed to vitamin A deficiency, the possibility of a corollary or contributing factor cannot be discounted. Three cases had markedly increased levels of hepatic copper (adult harbor seal reference range: 4–25 ppm), and two cases had increased hepatic zinc levels (adult harbor seal reference range: 30–80 ppm). The elevated levels of these trace minerals may be attributed to enzymatic deficiencies or in utero exposure and assimilation and did not appear to affect normal fetal development directly. The previously described case of conjoined twins had detectable hepatic levels

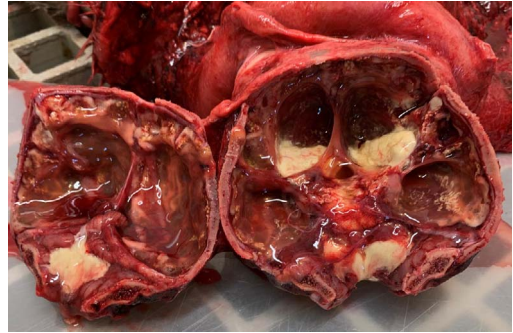


FIGURE 4. The skull of a stillborn harbor seal pup (*Phoca vitulina richardsii*) found in Port Orchard, Washington, USA, and examined postmortem in 2020, which presented with severe hydrocephalus and only a thin layer of remnant cerebral cortex adhered to the skull accompanied by cream-colored cerebral spinal fluid (WDFW2020-085).

of phenol, indole, and hydrocinnamic acid (Olson et al. 2016).

From 2003 to 2020, the yearly prevalence of congenital cases in seal pups from the SS examined postmortem ranged from 0% to 7.4%, with a mean yearly prevalence of $2.9\% \pm 2.2$. Although the cases over time showed no significant trend, we observed a significant positive correlation between number of cases with number of pups examined postmortem in both the SS ($P < 0.02$, Pearson correlation coefficient=0.55) and at GI ($P < 0.018$, Pearson correlation coefficient=0.56). We also observed a significant positive correlation between the number of dead pups (regardless of postmortem exam status) and the number of congenital cases at GI ($P < 0.04$, Pearson correlation coefficient=0.50). These findings indicate a need to continue postmortem protocols to discern any potential changes in prevalence in lieu of other variables. Average annual prevalence of cases per all dead pups in the GI subpopulation was 1.4%, and average annual prevalence of cases per pups examined postmortem was 3.1%. Annual proportion of cases in the pups examined postmortem from 2003 to 2019 at GI was similar to the proportion of cases seen in the SS. Any spikes in the proportions at GI are probably due to the differences in sample sizes between the full dataset and the GI

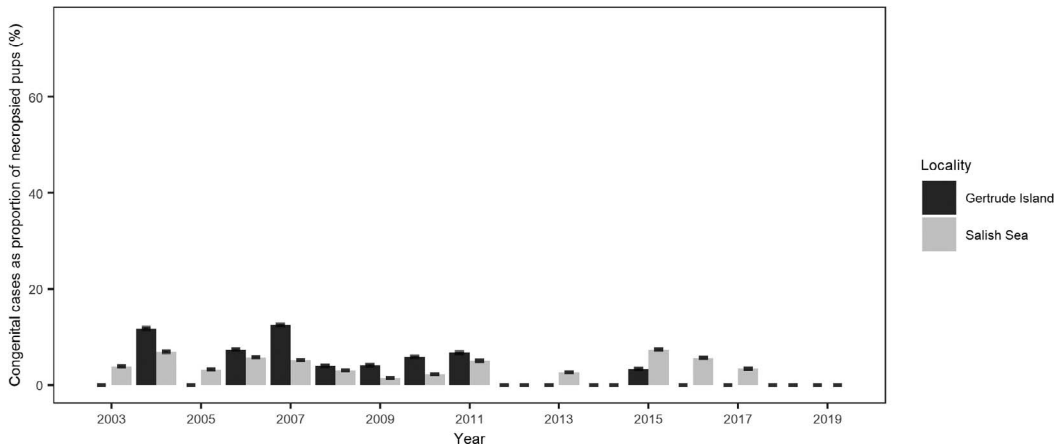


FIGURE 5. The annual proportion of congenital disease cases observed in harbor seal (*Phoca vitulina richardsii*) pups examined postmortem in the Washington, USA, portion of the Salish Sea (gray) compared with the proportion found within the study subpopulation at Gertrude Island (black) between 2003 and 2019. Annual prevalence for the Salish Sea includes the cases from Gertrude Island, whereas the annual prevalence at Gertrude Island was calculated only from the cases and pups examined postmortem at that single well-studied site. The 95% confidence intervals are shown.

dataset, and no differences exceeded a 7% difference between GI and SS (Fig. 5).

The average yearly prevalence of 2.9% probably represents the endemic prevalence of congenital diseases in the region. Yearly prevalence at GI was similar to that of the entire SS on the basis of cases examined postmortem, suggesting that, when prior work fails to identify spatiotemporal hotspots, intense surveillance of a single site serves as an adequate sentinel to measure congenital disease prevalence. Prevalence of congenital disorders in other wildlife populations range widely. Polydactyly has been noted in 0.18% of alligator hatchlings (*Alligator mississippiensis*; Eley et al. 2017), facial deformities in 10% of a wild chimpanzee population (*Pan troglodytes*; Krief et al. 2014), and cryptorchidism in 49% of inbred Florida panthers (*Felis concolor*; Mansfield and Land 2002). The amount of variability seen in wild populations supports our conclusion that 2.9% prevalence is probably the endemic level and within acceptable limits for this population.

Because of the retrospective nature of this study and manner of tissue collection, testing, and archiving, we were unable to infer underlying causes for the identified congenital

diseases. In cattle, vitamin A deficiency has been linked to congenital hydrocephaly, craniofacial malformations, and ocular malformations (Millemann et al. 2007). Six of 13 cases presenting with craniofacial malformations or dwarfism had moderately to severely low hepatic vitamin A levels. These were fresh carcasses and postmortem vitamin A degradation was unlikely; however, a case control study is necessary to determine the viability of vitamin A levels as a biomarker for craniofacial malformations in harbor seal pups. In conclusion, the prevalence of congenital defects does not appear to be changing in this harbor seal population, which is believed to be at equilibrium (Ashley et al. 2020a). If the prevalence increases, potential underlying causes should be investigated.

We thank all stranding network volunteers in the region, specifically Josh Oliver and Bethany Diehl at Washington Department of Fish and Wildlife and Amy Traxler at The Whale Museum. Most of this work was conducted thanks to funding from the John H. Prescott Marine Mammal Stranding and Rescue Assistance grant through National Oceanic and Atmospheric Administration Fisheries.

LITERATURE CITED

- Ashley EA, Olson JK, Adler TE, Raverty S, Anderson EM, Jeffries S, Gaydos JK. 2020a. Causes of mortality in a harbor seal (*Phoca vitulina*) population at equilibrium. *Front Mar Sci* 7:319.
- Ashley EA, Olson JK, Raverty S, Wilkinson K, Gaydos JK. 2020b. Trace element concentrations in Pacific harbor seals (*Phoca vitulina richardii*) from San Juan County, Washington. *J Wildl Dis* 56:429–436.
- Buckles EL, Gulland FMD, Aldridge BM, Gelatt TS, Ross PS, Haulena M, Lowenstine LJ. 2006. Fetus in fetu in a harbor seal (*Phoca vitulina richardii*): Histopathologic, genetic, and toxicologic analysis. *Vet Pathol* 43:541–544.
- Dennison SE, Boor M, Fauquier D, Van Bonn W, Greig DJ, Gulland FMD. 2011. Foramen ovale and ductus arteriosus patency in neonatal harbor seal (*Phoca vitulina*) pups in rehabilitation. *Aquat Mamm* 37: 161–166.
- Dennison SE, Forrest LJ, Fleetwood ML, Gulland FMD. 2009. Concurrent occipital bone malformation and atlantoaxial subluxation in a neonatal harbor seal (*Phoca vitulina*). *J Zoo Wildl Med* 40:385–388.
- Elsley RM, LeJeune D, Landry B, Reed K, Miller M, Kaller MD. 2017. Prevalence and details of polydactylism in the American alligator, *Alligator mississippiensis*, in Louisiana, USA. *Herpetol Conserv Biol* 12: 342–349.
- Harris HS, Facemire P, Greig DJ, Colegrove KM, Ylitalo GM, Yanagida GK, Nutter FB, Fleetwood M, Gulland FMD. 2011. Congenital neuroglial heterotopia in a neonatal harbor seal (*Phoca vitulina richardsi*) with evidence of recent exposure to polycyclic aromatic hydrocarbons. *J Wildl Dis* 47:246–254.
- Konno S, Moriwaki M, Nakagawa M. 1982. Akabane disease in cattle: Congenital abnormalities caused by viral infection. Spontaneous disease. *Vet Pathol* 19: 246–266.
- Krief S, Krief J-M, Seguya A, Couly G, Levi G. 2014. Facial dysplasia in wild chimpanzees. *J Med Primatol* 43:280–283.
- Kulldorff M. 1997. A spatial scan statistic. *Commun Stat Theory Methods* 26:1481–1496.
- Kulldorff M, Information Management Services Inc. 2009. *SaTScan™: Software for the spatial, temporal, and space-time scan statistics*. Version 9.6. <http://www.satscan.org/>. Accessed May 2020.
- Mansfield KG, Land ED. 2002. Cryptorchidism in Florida panthers: Prevalence, features, and influence of genetic restoration. *J Wildl Dis* 38:693–698.
- McKnight CA, Reynolds TL, Haulena M, DeLahunta A, Gulland FMD. 2005. Congenital hemispheric anomaly in a stranded Pacific harbor seal (*Phoca vitulina richardsi*). *J Wildl Dis* 41:654–658.
- Millemann Y, Benoit-Valiergue H, Bonnin J-P, Fontaine J-J, Maillard R. 2007. Ocular and cardiac malformations associated with maternal hypovitaminosis A in cattle. *Vet Rec* 160:441–443.
- Moura E, Pimpão CT. 2017. A numerical classification system for cleft lip and palate in the dog. *J Small Anim Pract* 58:610–614.
- Newby TC. 1971. *Distribution, population dynamics and ecology of the harbor seal, Phoca vitulina richardii, of the Southern Puget Sound, Washington*. Master's Thesis, University of Puget Sound, Tacoma, Washington, 75 pp.
- Olson JK, Gaydos JK, McKlveen T, Poppenga R, Wicinas K, Anderson E, Raverty S. 2016. Conjoined fetal twins in a harbor seal (*Phoca vitulina*). *J Wildl Dis* 52:173–176.
- R Core Team. 2020. *R: A language and environment for statistical computing*. R Foundation for Statistical Computing, Vienna, Austria. <http://www.R-project.org/>. Accessed September 2020.
- St. Leger JA, Nilson EM. 2014. Intestinal atresia in a harbor seal (*Phoca vitulina*) and a review of congenital conditions of the species. *Aquat Mammals* 40:207–212.
- Suzuki M, Kishimoto M, Hayama S, Ohtaishi N, Nakane F. 1992. A case of cleft palate in a Kuril seal (*Phoca vitulina stejnegeri*), from Hokkaido, Japan. *J Wildl Dis* 28:490–493.
- Suzuki M, Ohtaishi N, Nakane F. 1990. Supernumerary postcanine teeth in the Kuril seal (*Phoca vitulina stejnegeri*), the larga seal (*Phoca largha*) and the ribbon seal (*Phoca fasciata*). *Jpn J Oral Biol* 32:323–329.
- Tarasoff FJ, Piérard J. 1970. Ectrodactylism in the harbour seal, *Phoca vitulina L.* (Mammalia: Phocidae). *Can J Zool* 48:1381–1384.
- Wickham H. 2009. *ggplot2: Elegant graphics for data analysis*. 2nd Ed. Springer, New York, New York, 260 pp.

Submitted for publication 21 October 2020.

Accepted 4 March 2021.