

Cleaning Efficacy of Poly-ether-ether-ketone Tips in Eliminating Cement Remnants Around Implants With Different Abutment Heights

Çenker Zeki Koyuncuoglu, DDS, PhD^{1*}

Haluk Baris Kara, DDS, PhD²

Sinan Akdemir, CDT³

Becen Demir, DDS, PhD⁴

Nadin Al-Haj Husain⁵

Mutlu Özcan, DDS, DMD, PhD^{1,6}

The excess cement not removed after the cementation of fixed implant-supported restorations may cause loss of peri-implant attachment or adjacent bone. The aims of this study were to evaluate the amount of residual cement at different abutment-crown connection levels and to test the cleaning efficacy of poly-ether-ether-ketone (PEEK) ultrasonic tips after cementation. One implant was placed in an anterior central tooth position 5 mm below the gingival margin in an acrylic model, and 32 stone models were obtained with implant analogs. Abutment heights of 1–2 and 2.5–4 mm were used on the vestibular and lingual sides, respectively. Crowns were cemented and cleaned, and half of the samples were cleaned again using PEEK tips. The abutment-crown suprastructure was then disconnected, and cleaning efficacy was evaluated. Varying amounts of excess cement were found on all specimens except for the PEEK group with abutment-crown connections 1 mm below the gingival margin. An increase of undetected cement remnants was observed when the restoration margins were located deeper subgingivally. Various amounts of excess cement associated with margin location were detected on the abutment-restoration complex despite meticulous cleaning efforts. Ultrasonic PEEK tips were effective at cleaning the cement remnants around implants to a certain depth.

Key Words: *abutment heights, cleaning methods, excess cement, implant restorations, PEEK*

INTRODUCTION

Long-term clinical studies have demonstrated the considerable success of dental implants.^{1,2} However, varying rates of biological, technical, or esthetic complications may occur.³ A common biological complication of the peri-implant mucositis is a reversible inflammatory process defined by soft tissue redness, swelling, and bleeding on probing.⁴ Similarly, peri-implantitis is characterized as an inflammatory reaction, although suppuration on probing and loss of implant-supporting bone is also evident.⁵

Screw-retained or cement-retained restoration types are preferred for fixed implant prostheses.^{6,7} In a recent systematic review, it was concluded that no statistically significant difference in survival or failure rate was found between these 2 types of restorations.⁷ However, cement-retained restorations are commonly preferred over screw-retained devices because of their lower cost, technical sensitivity, and superior esthetics.^{8,9} Furthermore, dentists are generally more familiar with cementation procedures.¹⁰ In contrast, cementation procedures present inevitable problems such as difficulties eliminating all entire cement remnants from peri-implant soft tissues.¹¹ Excess/residual cement was established as a risk factor for multifactorial peri-implant diseases by the American Academy of Periodontology.¹² Cement remnants can cause peri-implant inflammation/infection and bone resorption because of foreign body reactions.^{13,14} Residual cement may also become a mechanical irritant or a reservoir for bacteria because of the rough material surfaces.¹⁵

The abutment margin position could affect the amount of residual cement regardless of careful cleaning efforts.^{16,17} In vitro studies proved that more cement remained undetected with deeper margin positions,¹⁷ which was also supported by clinical trial findings.^{11,13,15,18} Excess cement might not only adhere to abutment or restoration surfaces but also be found in

¹ Department of Periodontology, Faculty of Dentistry, Istanbul Aydin University, Istanbul, Turkey.

² Department of Prosthetic Dentistry, Faculty of Dentistry, Medipol University, Istanbul, Turkey.

³ Dental Prosthetics Technology Program, Health Sciences High School, Medipol University, Istanbul, Turkey.

⁴ Private practice, Istanbul, Turkey.

⁵ Department of Reconstructive Dentistry and Gerodontology, School of Dental Medicine, University of Bern, Bern, Switzerland.

⁶ Division of Dental Biomaterials, Center for Dental and Oral Medicine, Clinic for Reconstructive Dentistry, University of Zurich, Zurich, Switzerland.

* Corresponding author, e-mail: cenker.k@gmail.com
<https://doi.org/10.1563/aaid-joi-D-19-00095>

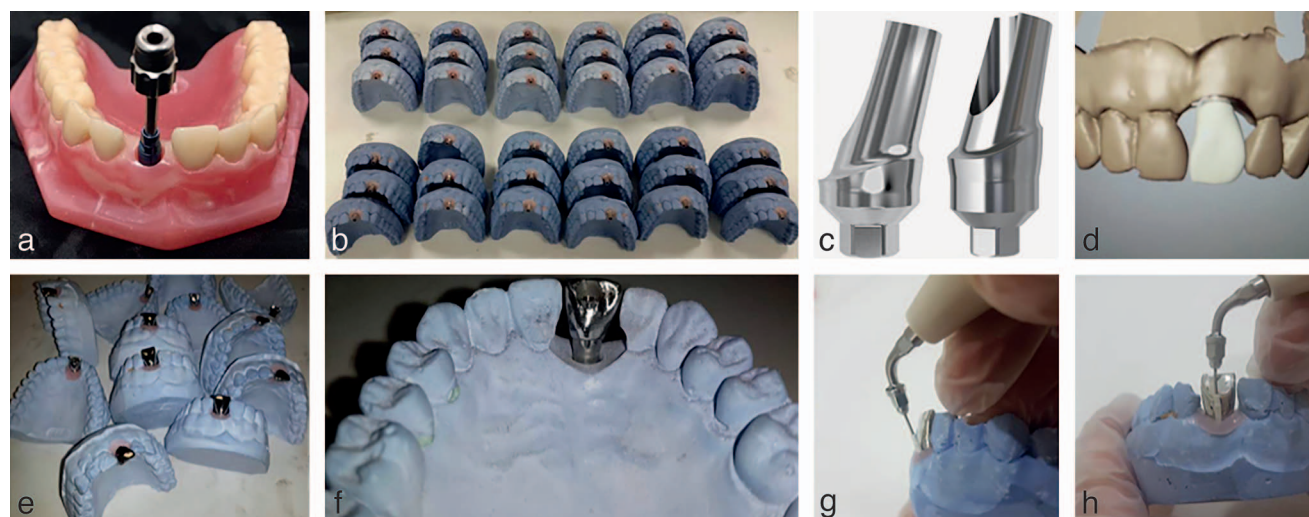


FIGURE 1. (a–h) Laboratory steps of the study.

peri-implant sulci, especially with deeper margins. Although extra-oral cementation techniques have been introduced to minimize excess cement on abutments and restorations and within peri-implant tissues,^{19–21} this type of complication has not been completely eliminated. Fortunately, the removal of cement remnants usually reduces the signs of inflammation.^{15,18}

Novel cementation methods or effective cleaning techniques and materials may prevent the problem of excess cement. Poly-ether-ether-ketone (PEEK) was commercialized in the 1980s. Since then, it has been used for different medical purposes such as orthopedic and spinal implants or as prophylactic instruments for dental implants.^{22,23} The effectiveness of ultrasonic plastic tips (PEEK) was tested for implant prophylaxis with superior results compared with classic plastic currettes.²³

Therefore, the objectives of this study were as follows: (1) to evaluate the amount of residual cement at various abutment margin locations and (2) to test the cleaning efficacy of PEEK tips after cementation.

MATERIALS AND METHODS

One implant (RSX-Line Implants, BEGO GmbH & Co KG, Bremen, Germany) was placed on an anterior central tooth 5 mm below the gingival margin in an acrylic maxillary jaw model (Figure 1a). Next, impressions were made, and 32 stone models with implant analogs were produced (Figure 1b). All the casts were prepared with improved type III dental stone (Siladent, Dr. Böhme & Schöps GmbH, Goslar, Germany). Flexible Laboratory A-Silicone (Gingifast Elastic, Zhermack SpA, Badia Polesine, Italy) was used as gingival mask. Standard abutments (RSX-Line Solid Abutments, BEGO GmbH & Co KG) of 2 different heights were used. In group A (n = 16), the heights were 1 and 2 mm on the vestibular and lingual sides, respectively. In group B (n = 16), the heights were 2.5 and 4 mm on the vestibular and lingual sides, respectively (Figure 1c). After mounting the abutments on implant analogs, 4 groups were created based on the

abutment-crown connection depths with respect to gingival margins as follows: group 1, vestibular sides of group A abutments were 1 mm in height with abutment-crown connections 4 mm below the gingival margins (n = 16); group 2, lingual sides of group A abutments were 2 mm in height with abutment-crown connections 3 mm below the gingival margin (n = 16); group 3, vestibular sides of group B abutments were 2.5 mm in height with abutment-crown connections 2.5 mm below the gingival margins (n = 16); group 4, lingual sides of group B abutments were 4 mm in height with abutment-crown connections 1 mm below the gingival margins (n = 16; Figures 2 and 3a and b).

The metal crowns were fabricated using a computer-aided design/computer-aided manufacturing system (Figure 1d and e). Lingual holes were prepared on the crowns to facilitate access to the abutment screws after cementation (Figure 1f). Before cementation, the abutment screw holes were sealed with a dental wax (Boxing Wax, KaVo Kerr Group, Orange, Calif), and the lingual holes were closed with a composite material (Clip Flow, VOCO GmbH, Cuxhaven, Germany) to prevent cement from entering the screw hole and flowing out of the lingual hole.

Methacrylate cement (Premier Implant Cement, Plymouth Meeting, Pa) consisting of a catalyst and a base material was selected as the luting agent. The cement was mixed according to manufacturer instructions, and a thin layer was applied 2 mm

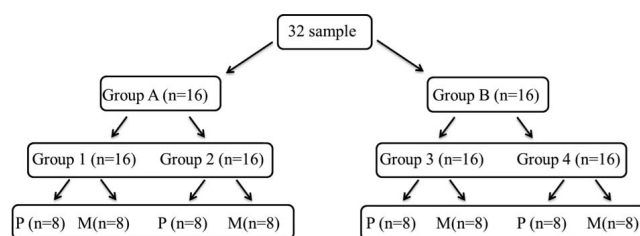


FIGURE 2. Flowchart of the study represents the groups (the margin below the gingiva) and cleaning methods. Group 1 (–4 mm), group 2 (–3 mm), group 3 (–2.5 mm), and group 4 (–1 mm). P indicates PEEK and manual method; M, manual method.




FIGURE 3. The 2 types of prosthetic abutments with different location of cementation margins: (a) abutment heights: V, 2.5 mm; L, 4 mm and (b) abutment heights: V, 1 mm; L, 2 mm.

from the cervical margins of the crown internal surfaces. Care was taken to avoid filling the crowns completely. The crowns were then seated on the abutments using finger pressure during the setting time. After setting was complete, excess cement was removed from all samples using a stainless-steel explorer (Hu-Friedy Mfg. Co, LLC, Chicago, Ill), plastic curettes (Hu-Friedy Mfg. Co, LLC), and super-floss (Oral-B, Proctor & Gamble, Cincinnati, Ohio) until the researcher was confident of complete cleaning. Half of the samples were then chosen randomly for extra cleaning using ultrasonic oscillating PEEK plastic tips (Piezon Master 400 with Pi-Instrument, EMS, Nyon, Switzerland) by another researcher (a periodontist) until this researcher was also confident of complete cleaning (Figure 1g and h). The oscillation speed was set for classical periodontal treatment (70% power) with maximum water cooling. Typically, the instrument tips were placed subgingivally and held nearly tangential to the abutment surfaces without any applied pressure. The PEEK group was evaluated as the test group (PEEK and manual method; P group), and the other group was evaluated as the control group (manual method; M group). Each group consisted of 8 samples (Figure 2).

After the cleaning session, the composite material on the lingual side of the crown and the dental wax covering the screw hole were removed, the abutment screw was removed, and the abutment-crown superstructure was disconnected from the cast for evaluation. A blinded researcher evaluated the effectiveness of the different cleaning methods using a computerized planimetric technique similar to a previous *in vitro* study.¹⁷ Briefly, 2 surfaces (vestibular and lingual) of the specimens were photographed using a custom-designed device and a tripod to maintain a standardized distance between the digital camera (Canon EOS 550D, Canon Euroasia, Istanbul, Turkey) and the abutment. The images were imported and analyzed using Adobe Photoshop CS6 (Adobe Systems Incorporated, New York, NY). The areas of the specimen lingual and vestibular surfaces were measured manually. The number of pixels overlying the total surface area was recorded using the histogram option, and the same method was applied to the

cement remnant areas (Figures 4 and 5). The ratio between these results was calculated for each surface of the specimen.

RESULTS

Lingual and vestibular surfaces of the specimens were considered a statistical unit. Therefore, each specimen had 2 measurements, resulting in 64 measurements for all 32 samples, with a sample size of 8 for each group. Statistical analyses were performed using SPSS v22 for Windows (SPSS Inc, Chicago, Ill). The results were averaged (mean values with SDs) for all parameters. The normal distribution of the data was tested using the Shapiro-Wilk test, and the data were found not to be normally distributed. The Mann-Whitney *U* test was used accordingly to test the differences between the 2 cleaning methods. Additionally, the influence of margin location on the amount of undetected cement was evaluated using the Kruskal-Wallis test followed by the Mann-Whitney *U* test. Differences of $P < .05$ were considered statistically significant. The methodology of this study was reviewed by an independent statistician.

Excess cement was found in varying amounts on all test specimens except in the P group with abutment-crown connections 1 mm below the gingival margin. The quantity of undetected cement remnants increased with deeper subgingival restoration margins ($P < .05$; Table 1).

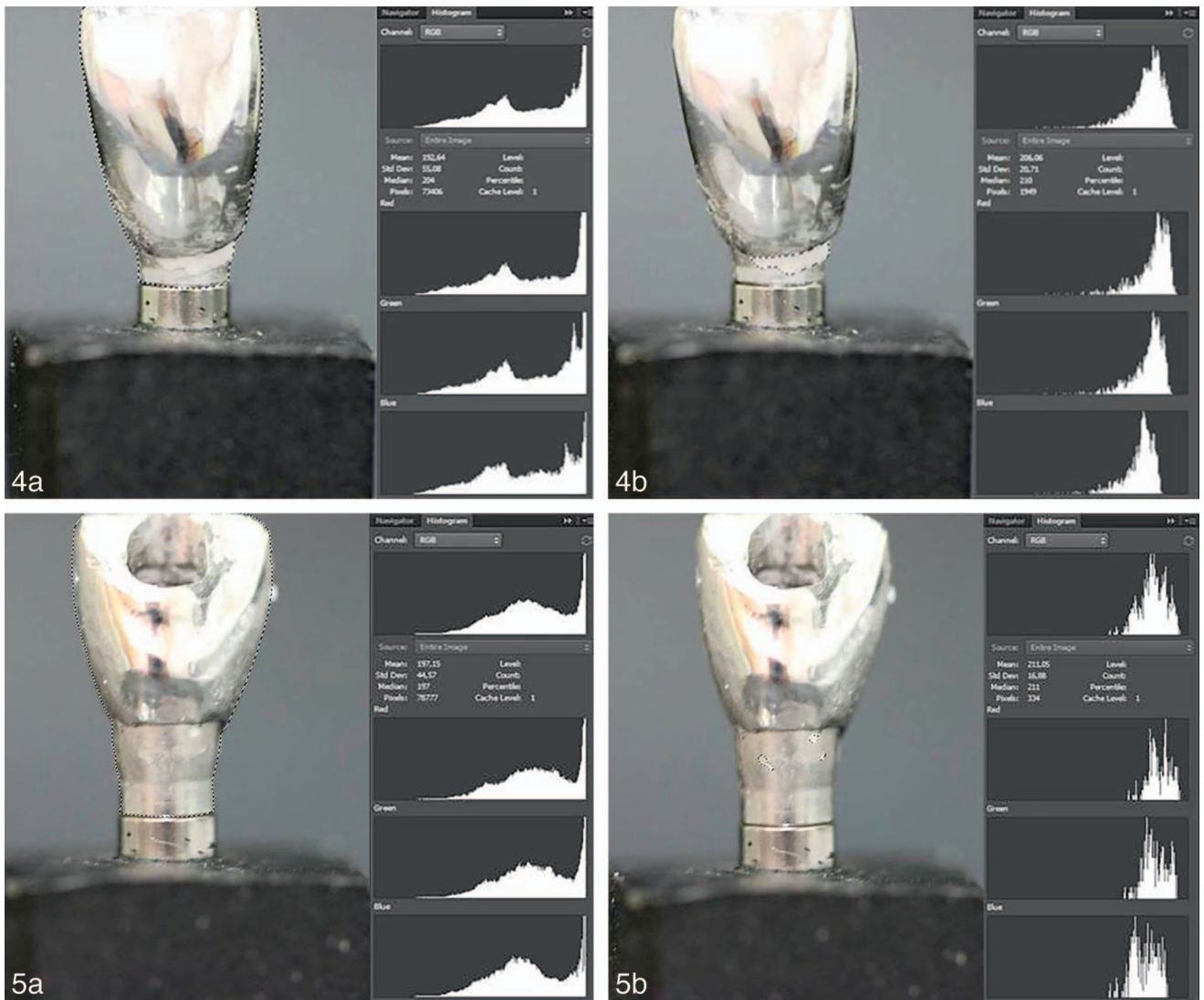
Irrespective of the cleaning method, the greatest amount of undetected cement was found in group 1 ($P > .05$). The fewest cement remnants were found after the PEEK cleaning method when the margin was 1 mm below the gingival level ($P < .05$). Comparison of cleaning methods revealed statistically significant differences only in group 4 ($P < .05$); no statistically significant results were obtained from groups 1, 2, or 3.

After manual cleaning, more undetected cement was observed with deeper subgingival margins. However, statistically significant differences were evident only between groups 1 and 4 and groups 1 and 3 (Table 2). Combined manual and PEEK cleaning demonstrated statistically significant differences between all groups ($P < .05$) except between groups 1 and 2 and groups 3 and 4 ($P > .05$).

DISCUSSION

The main findings of the present study were as follows: (1) varying amounts of excess cement associated with margin location were detected on the abutment/restoration complex despite meticulous cleaning efforts, and (2) ultrasonic PEEK tips were effective at cleaning the cement remnants to a certain depth.

Clinical studies and case reports suggested that cement-retained restorations may increase the prevalence of peri-implant diseases.^{15,18,24,25} Wilson¹⁵ investigated the association between excess cement and peri-implant disease using dental endoscopy and reported that the majority (81%) of cases exhibiting persistent bleeding on probing and signs of peri-implantitis had cement remnants in the subgingival areas. Clinical and endoscopic signs of inflammation and peri-implant disease resolved in 74% of the implants after the excess cement



FIGURES 4 AND 5. FIGURE 4. (a) Total surface area of buccal site of the abutment/restoration is marked. (b) Cement remnants on buccal site of the area in group 1. **FIGURE 5.** The 2 types of prosthetic abutments with different location of cementation margins. (a) Total surface area of lingual site of the abutment/restoration is marked. (b) Cement remnants on lingual site of the area in group 4.

Depth (mm)	Cleaning Methods		Z	P†
	M, Mean ± SD (Median)	P, Mean ± SD (Median)		
Group 1 (−4 mm)	0.021 ± 0.01 (0.018)	0.019 ± 0.023 (0.017)	−0.736	.462
Group 2 (−3 mm)	0.016 ± 0.021 (0.007)	0.013 ± 0.012 (0.01)	−0.840	.401
Group 3 (−2.5 mm)	0.01 ± 0.018 (0.004)	0.002 ± 0.003 (0)	−0.987	.324
Group 4 (−1 mm)	0.006 ± 0.008 (0.001)	0 ± 0 (0)	−2.208	.027‡
Kruskal-Wallis test	8,152	17,719		
P§	.043‡	.001‡		

*M indicates manual method; P, PEEK and manual method.

†Mann-Whitney U test.

‡P < .05.

§Kruskal-Wallis test.

TABLE 2

Differences between groups with respect to proportions of cement excess on abutment/restoration complexes based on margin location*

Groups	Location of Margins	
	M	P
1 and 2	$P > .05$	$P > .05$
1 and 3	$P = .046$	$P = .048$
1 and 4	$P = .008$	$P = .004$
2 and 3	$P > .05$	$P = .002$
2 and 4	$P > .05$	$P = .000$
3 and 4	$P > .05$	$P > .05$

*M indicates manual method; P, PEEK and manual method.

was cleaned. Similarly, in vitro experiments demonstrated a surprising number of cement remnants after cementation, especially in deeper restorations.^{16,17} In a recent systematic review, Renvert and Quirynen³ suggested that excess cement should be considered a risk factor for the development of peri-implantitis. In another systematic review, it was concluded that the prevalence of peri-implant diseases varied between 1.9% and 75% among implants with cement-retained restorations, with 33%–100% of those cases associated with excess cement.²⁶ Microbial loads colonizing inner surfaces and peri-implant sulci (PIS) were compared between cement- and screw-retained superstructures over 5 years of follow-up. The cement-retained group exhibited significantly higher bacterial loads in PIS. However, the screw-retained group had significantly higher bacterial loads on the inner surfaces of the implant connections.²⁷ It should be noted that screw-retained crowns have considerable disadvantages, including inferior esthetics (because of the screw holes), the risk of screw fractures, and increased laboratory costs.^{7–9,28} In a split-mouth prospective clinical study of 12 patients over 4 years, no differences were reported between cement- and screw-retained restorations.²⁹ The same research group re-evaluated these outcomes after 10 years of follow-up and found no significant differences in terms of either peri-implant soft tissue or bone levels.³⁰ Additionally, positive results have been reported regarding cement-retained crowns in other retrospective studies.^{9,31} Nissan et al³¹ emphasized that cement-retained crowns had better performance than screw-retained crowns in both biological and technical aspects. Furthermore, they reported that cement-retained crowns exhibited lower rates of peri-implant diseases.³¹ In a retrospective study, researchers evaluated implant-supported fixed restorations after 10–23 years and concluded that the use of zinc oxide cement provided sufficient long-term retention for these restorations without biological complications.⁹ In a recent prospective study, Kotsakis et al³² reported that there was no direct association between retention type (cement or screw) and peri-implant diseases. In contrast, all of these researchers emphasized the issue of excess cement and its negative effect on peri-implant health. They also suggest that clinicians can limit cement-associated biological complications using evidence-based cementing methods, proper material selection, and abutment margin location.

Previous studies and consensus statements recommended placing abutment margins subgingivally for esthetic rea-

sons.^{33–35} The reasons for this recommendation were to obscure the abutment–restoration interface for a more natural emergence profile and to compensate for potential peri-implant tissue recession over time.⁴ Additionally, implant system components and local anatomy support the placement of deep subgingival crown margins in many cases (implant-supported restorations).⁹ In a previous review, Belser et al³⁴ recommended that implant shoulders be positioned 1–2 mm apical to the facial cemento-enamel junctions of adjacent teeth under regular circumstances. As a result, the restoration margins were located 2–3 mm below the gingiva. Anderson et al³³ concluded that if cementation margins were placed deeper than 2 mm subgingivally, it could be difficult to detect or remove excess cement. An experimental study by Agar et al¹⁶ was the first to demonstrate that it is almost impossible to clean all cement remnants if the restoration margin is placed 1.5–3 mm below the peri-implant tissue level. Another review suggested that the subgingival abutment margin should not exceed 2 mm on the facial aspect.³⁶ Additionally, it was emphasized that the implant shoulder should be placed subgingivally in most esthetic areas, resulting in deeper interproximal restoration margins. In these cases, difficulties occur when seating the restorations and removing cement remnants by professional cleaning^{17,35} or daily hygiene procedures is impossible.¹⁷ Therefore, Belser et al³⁵ advised using screw-retained restorations to reduce these complications. In a recent retrospective study, Korsch et al³⁷ revised implant restorations on 126 implants, which were cemented for a maximum of 1.5 years prior with resin cement. Although the abutment margins were placed at subgingival depths ≤ 1.5 mm, almost 60% of the implants exhibited cement remnants after all superstructures and abutments were removed. Linkевичus et al¹⁷ designed an experimental study and concluded that it was impossible to clean cement remnants around the implant restorations, especially when abutment margins were located subgingivally 2 mm or deeper. The results demonstrated that excess cement could be completely removed only from abutments with visible margins. The present in vitro study demonstrated superior results with both cleaning methods compared with the study of Linkevicius et al. The reasons for these differences may be explained by either cement preferences or cleaning techniques. Additionally, no cement remnants were found in the gingival mask area. Similarly, no cement was observed in the same area in a previous study.¹⁷ However, the same group reported that excess cement was found in the peri-implant sulcus and on the abutment/restoration system in one clinical study.²⁵ They also reported a statistically significant increase of excess cement in the peri-implant sulcus as the abutment margin position was deepened. These findings demonstrate that cement remnants may remain within peri-implant sulci, although they are detached from the abutment or restoration surfaces during cleaning.^{15,25} In a recent systematic review, Staubli et al²⁶ recommended setting restoration margins at the gingival level to reduce the risks linked with excess cement.

Use of a conventional ultrasonic scaler tip on an implant may cause surface modifications.^{38,39} This, in turn, may facilitate microbial dental plaque and calculus formation around implants.^{40,41} Therefore, the use of plastic or titanium curettes,

rubber polishing cups, brushes, air-powder abrasive systems, and poly-tetra-fluoro-ethylene-coated scaler tips has been recommended.^{42,43} Kawashima et al³⁸ tested different piezo-electric ultrasonic scalers with plastic, carbon, or metallic tips in a clinical study. It was concluded that abutment surface roughness did not differ between the plastic and carbon groups, whereas the metallic group had significantly rougher surfaces. In an experimental study, an erbium:yttrium, aluminium and garnet (Er:YAG) laser was tested at levels recommended by the manufacturer for implant decontamination procedures. It was concluded that the Er:YAG laser could alter the surfaces of titanium implants and that these modifications could negatively affect osseointegration.⁴⁴ Schmage et al²³ evaluated different implant prophylaxis instruments and found that manual plastic and carbon-reinforced fiber plastic curettes had the poorest cleaning effectiveness on polished surfaces, whereas sonic and ultrasonic PEEK plastic tips and air polishing had the best results on different implant surfaces. Although PEEK tips have advantages over other instrumentation techniques, plastic instruments can contaminate implant surfaces.⁴⁵ In a recent in vitro study, surface area coverage by plastic remnants (8.9–17.7%) was demonstrated after different instrumentation techniques. This study also demonstrated the difficulty of removing plastic remnants using a water spray or a chlorhexidine-soaked cotton pellet.⁴⁶ The present study was the first to test PEEK tips for cleaning cement remnants. Manual cleaning combined with PEEK use demonstrated significantly positive results only in group 4.

Radiopacity of the cement materials improve the detection of cement remnants in interproximal areas; however, the restoration, abutment, and/or implant may obscure excess cement in the buccal/lingual view.⁴⁷ Wadhvani et al⁴⁸ demonstrated that radiographic density of cements in implant prosthetics is poor, and smaller remnants would remain unseen. In a recent clinical study, it was stated that excess cement were only visible mesial or distal areas of implant restorations at a low rate. They concluded that dental radiographs should not be considered a reliable method for excess cement evaluation.⁴⁹ In the present study, any radiographic methods were used because of the reasons listed above.

In a previous study, 3 types of commonly used cement (glass-ionomer, resin, and zinc phosphate) were compared, and the resins was found to be the most difficult to remove; zinc phosphate cement was the easiest.¹⁶ In addition, zinc oxide eugenol cement showed signs of dissolution after a short time in contact with artificial saliva.⁵⁰ Tarica et al⁵¹ showed that resin-modified glass ionomer was the most popular cement for inserting implant restorations in US dental faculties. Korsch et al^{18,37} reported a number of complications related to methacrylate cement in clinical studies. It may be speculated that if the different cement types used in the present study, the results could be changed.

The other limitations of the present study as follows: (1) the excess cement was cleaned in a laboratory environment and the effects of saliva, temperature, and time could not be evaluated; (2) the flexibility and structure of the gingival mask might affect the results either positively or negatively; and (3)

the cleaning effectiveness might be negatively affected by the PEEK tip thickness.

CONCLUSIONS

Increased amount of cement remnants could be detected at deeper locations of abutment margins. Despite their thickness, PEEK tips effectively removed excess cement, especially when the margin was 1 mm below the gingival level. Future clinical studies should test the efficacy of PEEK tips with different types of cement to eliminate excess cement-related inflammation around implants.

ABBREVIATIONS

Er:YAG: erbium:yttrium, aluminium and garnet laser
PEEK: poly-ether-ether-ketone
PIS: peri-implant sulci

ACKNOWLEDGMENTS

The authors acknowledge Bego Implants (Bremen, Germany) for kindly providing the implant and the abutments. Ebru Osmanoglu Akyol (Varyans Statistical Consultancy) reviewed the methodology, results, and conclusions sections of this article.

NOTE

The authors have no conflicts of interest relevant to this article.

REFERENCES

- Dierens M, Vandeweghe S, Kisch J, Nilner K, De Bruyn H. Long-term follow-up of turned single implants placed in periodontally healthy patients after 16–22 years: radiographic and peri-implant outcome. *Clin Oral Implants Res.* 2012;23:197–204.
- van Velzen FJ, Ofec R, Schulten EA, Ten Bruggenkate CM. 10-Year survival rate and the incidence of peri-implant disease of 374 titanium dental implants with a SLA surface: a prospective cohort study in 177 fully and partially edentulous patients. *Clin Oral Implants Res.* 2015;26:1121–1128.
- Renvert S, Quirynen M. Risk indicators for peri-implantitis. A narrative review. *Clin Oral Implants Res.* 2015;26:15–44.
- Mombelli A, Muller N, Cionca N. The epidemiology of peri-implantitis. *Clin Oral Implants Res.* 2012;23:67–76.
- Lindhe J, Meyle J. Group D of European Workshop on Periodontology. Peri-implant diseases: consensus report of the sixth European workshop on periodontology. *J Clin Periodontol.* 2008;35:282–285.
- Jung RE, Pjetursson BE, Glauser R, Zembic A, Zwahlen M, Lang NP. A systematic review of the 5-year survival and complication rates of implant-supported single crowns. *Clin Oral Implants Res.* 2008;19:119–130.
- Witneben JG, Millen C, Bragger U. Clinical performance of screw-versus cement-retained fixed implant supported reconstructions: a systematic review. *Int J Oral Maxillofac Implants.* 2014;29:84–98.
- Hebel KS, Gajjar RC. Cement-retained versus screw-retained implant restorations: achieving optimal occlusion and esthetics in implant dentistry. *J Prosthet Dent.* 1997;77:28–35.
- Woelber JP. Decementation Rates and the peri-implant tissue status of implant-supported fixed restorations retained via zinc oxide cement: a retrospective 10–23-year study. *Clin Implant Dent Relat Res.* 2016; 18:917–925.

10. Taylor TD, Agar JR. Twenty years of progress in implant prosthodontics. *J Prosthet Dent.* 2002; 88:89–98.
11. Chee WW, Duncan J, Afshar M, Moshaverinia A. Evaluation of the amount of excess cement around the margins of cement-retained dental implant restorations: the effect of the cement application method. *J Prosthet Dent.* 2013;109:216–221.
12. Rosen P, Clem D, Cochran D. Peri-implant mucositis and peri-implantitis: a current understanding of their diagnoses and clinical implications. *J Periodontol.* 2013; 84:436–443.
13. Wilson TG Jr, Valderrama P, Burbano M, Blansett J, Levine R, Kessler H, Rodrigues DC. Foreign bodies associated with peri-implantitis human biopsies. *J Periodontol.* 2015;86:9–15.
14. Albrektsson T, Canullo L, Cochran D, De Bruyn H. “Peri-implantitis”: a complication of a foreign body or a man-made “disease.” Facts and fiction. *Clin Implant Dent Relat Res.* 2016;18:840–849.
15. Wilson TG Jr. The positive relationship between excess cement and peri-implant disease: A prospective clinical endoscopic study. *J Periodontol.* 2009;80:1388–1392.
16. Agar JR, Cameron SM, Hughbanks JC, Parker MH. Cement removal from restorations luted to titanium abutments with simulated subgingival margins. *J Prosthet Dent.* 1997;78:43–47.
17. Linkevicius T, Vindasiute E, Puisys A, Peculiene V. The influence of margin location on the amount of undetected cement excess after delivery of cement-retained implant restorations. *Clin Oral Implant Res.* 2011;22: 1379–1384.
18. Korsch M, Robra BP, Walther W. Cement-associated signs of inflammation: retrospective analysis of the effect of excess cement on peri-implant tissue. *Int J Prosthodont.* 2015;28:11–18.
19. Wadhvani C, Piñeyro A. Technique for controlling the cement for an implant crown. *J Prosthet Dent.* 2009;102:57–58.
20. Yuzbasioglu E. A modified technique for extraoral cementation of implant retained restorations for preventing excess cement around the margins. *J Adv Prosthodont.* 2014;6:146–149.
21. Canullo L, Cocchetto R, Marinotti F, Oltra DP, Diago MP, Loi I. Clinical evaluation of an improved cementation technique for implant supported restorations: a randomized controlled trial. *Clin Oral Implants Res.* 2016;27:1492–1499.
22. Lee WT, Koak JY, Lim YJ, Kim SK, Kwon HB, Kim MJ. Stress shielding and fatigue limits of poly-ether-ether-ketone dental implants. *J Biomed Mater Res B Appl Biomater.* 2012;100:1044–1052.
23. Schmage P, Kahili F, Nergiz I, Scorziello TM, Platzer U, Pfeiffer P. Cleaning effectiveness of implant prophylaxis instruments. *Int J Oral Maxillofac Implants.* 2014;29:331–337.
24. Weber HP, Kim DM, Ng MW, Hwang JW, Fiorellini JP. Peri-implant soft-tissue health surrounding cement and screw-retained implant restorations: a multi-center, 3-year prospective study. *Clin Oral Implants Res.* 2006; 17:375–379.
25. Linkevicius T, Puisys A, Vindasiute E, Linkeviciene L, Apse P. Does residual cement around implant-supported restorations cause peri-implant disease? A retrospective case analysis. *Clin Oral Implants Res.* 2013;24:1179–1184.
26. Staubli N, Walter C, Schmidt JC, Weiger R, Zitzmann NU. Excess cement and the risk of peri-implant disease: a systematic review. *Clin Oral Implants Res.* 2017;28:1278–1290.
27. David Penarrocha-Oltra. Microbial colonization of the peri-implant sulcus and implant connection of implants restored with cemented versus screw-retained superstructures: a cross-sectional study. *J Periodontol.* 2016; 87:1002–1011.
28. Shadid R, Sadaqa N. A comparison between screw- and cement-retained implant prostheses. A literature review. *J Oral Implantol.* 2012;38: 298–307.
29. Vigolo P, Givani A, Majzoub Z, et al. Cemented versus screw-retained implant-supported single-tooth crowns: a 4-year prospective clinical study. *Int J Oral Maxillofac Implants.* 2004;19:260–265.
30. Vigolo P, Mutinelli S, Givani A, Stellini E. Cemented versus screw-retained implant-supported single-tooth crowns: a 10-year randomised controlled trial. *Eur J Oral Implants.* 2012;5:355–365.
31. Nissan J, Narobai D, Gross O, Ghelfan O, Chaushu G. Long-term outcome of cemented versus screw retained implant-supported partial restorations. *Int J Oral Maxillofac Implants.* 2011;26:1102–1107.
32. Kotsakis AG. Investigation of the association between cement retention and prevalent peri-implant diseases: a cross-sectional study. *J Periodontol.* 2016;87:212–220.
33. Andersson B, Odman P, Lindvall AM, Lithner B. Single-tooth restorations supported by osseointegrated implants: results and experiences from a prospective study after 2 to 3 years. *Int J Oral Maxillofac Implants.* 1995;10:702–711.
34. Belsler UC, Buser D, Hess D, Schmid B, Bernard JP, Lang NP. Aesthetic implant restorations in partially edentulous patients: a critical appraisal. *Periodontol 2000.* 1998;17:132–150.
35. Belsler U, Buser D, Higginbottom F. Consensus statements and recommended clinical procedures regarding esthetics in implant dentistry. *Int J Oral Maxillofac Implants.* 2004;19:73–74.
36. Belsler UC, Mericske-Stern R, Bernard JP, Taylor TD. Prosthetic management of the partially dentate patient with fixed implant restorations. *Clin Oral Implants Res.* 2000;11:126–145.
37. Korsch M, Obst U, Walther W. Cement-associated periimplantitis: a retrospective clinical observational study of fixed implant-supported restorations using a methacrylate cement. *Clin Oral Implants Res.* 2014; 25: 797–802.
38. Kawashima H, Sato S, Kishida M. Treatment of titanium dental implants with three piezoelectric ultrasonic scalers: an in vivo study. *J Periodontol.* 2007;78:1689–1694.
39. Baek SH, Shon WJ, Bae KS, Kum KY, Lee WC, Park YS. Evaluation of the safety and efficiency of novel metallic ultrasonic scaler tip on titanium surfaces. *Clin Oral Implants Res.* 2012;23:1269–1274.
40. Rapley JW, Swan RH, Hallmon WW, Mills MP. The surface characteristics produced by various oral hygiene instruments and materials on titanium implant abutments. *Int J Oral Maxillofac Implants.* 1990;5:47–52.
41. Quirynen M, Bollen CM, Papaioannou W, Van Eldere J, van Steenberghe D. The influence of titanium abutment surface roughness on plaque accumulation and gingivitis: short-term observations. *Int J Oral Maxillofac Implants.* 1996;11:169–178.
42. Sato S, Kishida M, Ito K. The comparative effect of ultrasonic scalers on titanium surfaces: an in vitro study. *J Periodontol.* 2004;75:1269–1273.
43. Seol HW, Heo SJ, Koak JY, Kim SK, Baek SH, Lee SY. Surface alterations of several dental materials by a novel ultrasonic scaler tip. *Int J Oral Maxillofac Implants.* 2012;27:801–810.
44. Galli C, Macaluso GM, Elezi E, Ravanetti F, Cacchioli A, Gualini G, Passeri G. The effects of Er:YAG laser treatment on titanium surface profile and osteoblastic cell activity: an in vitro study. *J Periodontol.* 2011;82:1169–1177.
45. Rühling A, Kocher T, Kreuzsch J, Plagmann HC. Treatment of subgingival implant surfaces with Teflon-coated sonic and ultrasonic scaler tips and various implant curettes. An in vitro study. *Clin Oral Implants Res.* 1994;5:19–29.
46. Yang SM, Park JB, Ko Y. Use of confocal microscopy for quantification of plastic remnants on rough titanium after instrumentation and evaluation of efficacy of removal. *Int J Oral Maxillofac Implants.* 2015;30: 519–525.
47. Pette GA1, Ganeles J, Norkin FJ. Radiographic appearance of commonly used cements in implant dentistry. *Int J Periodontics Restorative Dent.* 2013;33:61–68.
48. Wadhvani C, Hess T, Faber T, Piñeyro A, Chen CS. A descriptive study of the radiographic density of implant restorative cements. *J Prosthet Dent.* 2010;103:295–302.
49. Linkevicius T, Vindasiute E, Puisys A, Linkeviciene L, Maslova N, Purieni A. The influence of the cementation margin position on the amount of undetected cement. A prospective clinical study. *Clin Oral Implants Res.* 2013;24:71–76.
50. Yanikoğlu N1, Yeşil Duymuş Z. Evaluation of the solubility of dental cements in artificial saliva of different pH values. *Dent Mater J.* 2007;26:62–67.
51. Tarica DY, Alvarado VM, Truong ST. Survey of United States dental schools on cementation protocols for implant crown restorations. *J Prosthet Dent.* 2010;103:68–79.