

Success of Biodentine and Ferric Sulfate as Pulpotomy Materials in Primary Molars: A Retrospective Study

Kelsey A Brar*/ Evelina Kratunova**/ David Avenetti***/ Marcio A da Fonseca****/ Ian Marion*****/ Satish Alapati*****

Objective: To determine the clinical and radiographic success of Biodentine® (BD) and Ferric Sulfate (FS) as primary molar pulpotomy materials and to compare their outcomes. **Study design:** Retrospective data was obtained from the electronic health records (EHR) of a university-based pediatric dental clinic. Participants were enrolled according to specified inclusion and exclusion criteria. Two trained and calibrated examiners evaluated the EHR using validated criteria for clinical and radiographic outcomes. Study data was numerically coded and analyzed. Cohen's Kappa and Chi-square tests were used ($p < 0.05$). **Results:** Eighty-three participants (62.7% females, age range two to eight years, average age of 4.5 years) with 102 pulpotomies were enrolled. FS was used in 78% ($n=79$) and BD in 22% ($n=23$) of the cases. Follow-up periods ranged from six to 36 months (mean of 17 months). BD showed 100% clinical and radiographic success, while FS demonstrated 84% clinical and 70% radiographic success. The two groups were compared at one year with no statistically significant differences. At 18 months, BD outperformed FS clinically ($p=.012$) and radiographically ($p=.001$). Intra-rater and inter-rater agreement were $\kappa > 0.88$. **Conclusions:** Both materials can be recommended for clinical practice, however BD may be the preferred choice for its better outcomes at 18 months.

Keywords: Biodentine, Ferric Sulfate, Pulpotomy, Primary Molar, Pediatric Dentistry

From the College of Dentistry, University of Illinois at Chicago, Chicago, Ill., USA.

*Kelsey A Brar, DMD, MS, MPH: Pediatric dentist in private practice, Chicago, IL.

**Evelina Kratunova, MDS, D.Ch.Dent; Clinical Associate Professor, Department of Pediatric Dentistry.

***David Avenetti, DDS, MPH, MSD; Clinical Associate Professor and Post-graduate Program Director, Department of Pediatric Dentistry.

****Marcio A da Fonseca, DDS, MS; Chicago Dental Society Foundation Professor and Head, Department of Pediatric Dentistry.

*****Ian Marion, DDS, MS; Clinical Assistant Professor, Department of Pediatric Dentistry and Pre-Doctoral Program Director.

*****Satish Alapati, DDS, MS, PhD; Associate Professor, Department of Endodontics.

Send all Correspondence to:

Evelina Kratunova
Department of Pediatric Dentistry, College of Dentistry, University of Illinois at Chicago
801 South Paulina Street M/C 850, Room 269D
Chicago, IL 60612
Phone: (312) 996-1984
Fax: (312) 413-8006
Email Address: evekrat@uic.edu

INTRODUCTION

Primary molar pulpotomy is a type of vital pulp therapy indicated for treatment of teeth diagnosed with reversible pulpitis.¹ The procedure entails amputation of the inflamed coronal pulp and application of a suitable therapeutic material over the remaining radicular pulp stump, which can promote disease-free survival of the deciduous tooth.^{1,2} While the immediate outcome of successful pulpotomy is an asymptomatic tooth with preserved radicular pulp, its ultimate objective is to prevent premature tooth loss and to maintain integrity of the dental arch.^{2,3} The clinical technique and indications for the pulpotomy procedure have remained unchanged for decades, however the utilized therapeutic materials have been widely diverse and are continuously evolving over the years.⁴ The existing pulpotomy materials can be classified into three main categories based on their effect on the remaining radicular pulp tissue.⁵ These include agents producing devitalization (e.g., formocresol, gluteraldehyde), preservation in a healthy state (e.g., ferric sulfate, bioactive cements, calcium hydroxide, sodium hypochlorite, lasers, etc.) or promoting regeneration (e.g., bone morphogenetic proteins).^{5,6}

For many years since the 1930s, the Buckley's solution (19% formaldehyde and 35% cresol diluted with glycerin and distilled water) has been the benchmark pulpotomy medicament.² Formocresol (FC) has protein-binding properties and works by fixation of

the radicular pulp tissue, making it inert.^{2,6} Its overall success has been estimated around 87%.² However, in 2004 the International Agency for Research on Cancer classified formaldehyde as carcinogenic to humans.⁷ Such toxicity and mutagenicity concerns have led to the discouragement of FC wider use and prompted new research looking for viable replacement options.² Ferric Sulfate (FS) in a 15.5% solution is a hemostatic agent and has been proposed as one such alternative.^{2,4} Animal and human studies have reported that its success as pulpotomy medicament (79.3%–93%) is similar to that of FC.^{6,8,9} FS forms a ferric ion-protein complex when it comes to contact with blood which upon agglutination produces plugs that mechanically occlude the cut blood vessels to achieve coagulation and hemostasis.¹⁰ This reaction causes minimal damage to the radicular pulp tissue and helps preserve its vitality.¹⁰ While FS has gained popularity over the past decade as the pulpotomy agent of choice in pediatric dentistry, more recently bioceramic materials such as Mineral Trioxide Aggregate (MTA) and Biodentine® (BD) have come to the scientific spotlight as successful endodontic therapy materials.^{2,11}

BD is a novel calcium-silicate based cement, first introduced on the market in 2010 by Septodont (St Maur des Faussés, France).¹¹ It has gained attention as a contemporary dentine replacement and repair material and has been proposed for use in therapeutic pulpotomies in primary teeth due to its excellent salability and biocompatibility.^{11,12} BD is a commercialized tricalcium silicate and thus undergoes an extensive manufacturing process utilizing active biosilicate technology, which eliminates aluminates and other metal impurities.¹¹ Therefore, the manufacturer claims that BD has improved mechanical properties when compared to MTA products including faster setting time, increased compressive strength, increased density, decreased porosity, induction of reparative dentine synthesis, and more manageable handling characteristics.^{11,12} When used as a pulpotomy agent, BD creates a layer of superficial necrosis on contact with vital pulp tissue.¹² This stimulates a healthy inflammatory response of the radicular pulp and the formation of reparative dentin layer that serves as a hard tissue barrier sealing off and protecting the vital radicular pulp.^{11,12} As a primary molar pulpotomy agent, BD has shown promising initial clinical results with reported 92% to 100% success rates.¹²⁻¹⁴ However, the research investigating the outcomes of BD remains limited and further trials are needed for clinical practice recommendations.

The purpose of this study was to determine the clinical and radiographic success of primary molar pulpotomies completed with BD and FS at a university-based pediatric dental clinic and to compare the outcomes of the two materials.

MATERIALS AND METHOD

The Institutional Review Board of the University of Illinois at Chicago (UIC), Chicago, Ill., USA granted permission to conduct this retrospective cohort study. To estimate the required sample size, a prospective power calculation, based on reported clinical success rates for BD and FS from previous studies, showed that 60 teeth would achieve a power of 80%. To account for inconsistent patient attendance at recall, our study included for initial review the first consecutive 400 pulpotomies completed since April 1, 2016. The list was generated from the dental electronic health record (EHR) system of the College of Dentistry, UIC and was based on

completed insurance codes for therapeutic pulpotomy. The specific date was chosen because at that time both materials were used in the university-based pediatric dental clinics. FS was available as Astringent™ (Ultradent Products, Inc., 3935, 505 W 10200 S, South Jordan, UT 84095, USA) and BD is a product of Septodont (94100 St Maur des Faussés, France). The principal investigator (PI), who was a post-graduate student in Pediatric Dentistry (PD), accessed all patient records and evaluated the information against the inclusion and exclusion criteria of the study (Table 1). Patients, who had teeth with completed pulpotomies that met the inclusion criteria, were enrolled as participants. Each of these teeth received a specific study number. All pulpotomies were completed by post-graduate PD students. The procedures were supervised by faculty members, specialists in PD. The EHR notes and radiographs corresponding to the dates of completion of the pulpotomy procedures of the study teeth, as well as all consecutive notes and radiographs from the periodic oral examinations were reviewed by the PI. Typically, patients with completed comprehensive exam and/or dental care are recalled at the clinics every six months for regular periodic dental examinations. Two sets of clinical and radiographic criteria validated by previous research¹⁴ were used in this study to evaluate the information about the study teeth gathered from the EHR (Tables 2 and 3).

The participants' demographic information was collected, such as age at the time of pulpotomy, sex, ethnicity and medical background. Race was not included due to lack of consistent documentation. For each study tooth, the PI searched the EHR for information on the primary molar diagnosis (i.e., caries, trauma, developmental defect) that provided justification for carrying out the pulpotomy procedure. The type of behavior management modality (i.e., nitrous oxide sedation, oral sedation or general anesthesia) used at the time of pulpotomy procedure as well as the type of dental visit (i.e., routine or urgent care) were also recorded. A second examiner, faculty member and specialist in PD, evaluated the radiographs. This was done first independently and then the cases were discussed between the two examiners in order to resolve any disagreements. The PI and the second examiner were calibrated using a questionnaire with 20 randomly selected radiographs of teeth with pulpotomies (for inter-rater reliability). The questionnaire was created by an independent to the study person. The PI completed the questionnaire on two separate occasions with two weeks apart (for intra-rater reliability). The examiners were trained for the study purposes by reviewing pertinent literature discussing therapeutic materials and primary molar pulpotomies. Research data was numerically coded. The clinical and radiographic scores were further converted into dichotomous outcomes combining scores of 1 and 2 into category "Success" and scores 3 and 4 into category "Failure". The inter- and intra-examiner reliability were assessed using Cohen's Kappa, and statistical analysis was completed using Statistical Product and Service Solutions (SPSS) software (Version 25.0, IBM SPSS Statistics, Armonk, N.Y., USA). A chi-square was utilized to assess for difference in outcomes between FS and BD groups with a level of significance of $p < 0.05$.

Table 1. Inclusion and Exclusion Criteria of the Study

Inclusion Criteria	Exclusion Criteria
Deciduous molar	Tooth other than a deciduous molar
Radiograph with clear visualization of the furcation pre-operatively	No pre-operative radiograph or a pre-operative radiograph without clear visualization of the furcation
Radiograph with clear visualization of the furcation at least 6-months post-operatively	No post-operative radiograph or a post-operative radiograph without clear visualization of the furcation
Clinical evaluation at least 6-months post-operatively	No clinical evaluation or clinical evaluation only less than 6-months post-operatively
Adequate documentation in the patient record on the date of the procedure and at all follow-up examinations	Poor/Improper documentation on the date of the procedure or at any recall examinations
Pulpotomy completed with Ferric Sulfate (FS) or Biodentine (BD)	Pulpotomy completed with a medicament other than FS or BD or medicament not documented in the chart

Table 2. Criteria for Clinical Success (adapted from Rajasekharan et al.¹⁴)

Score	Clinical Criteria	Description
1	Asymptomatic	<input type="checkbox"/> Pathology: Absent <input type="checkbox"/> Normal functioning <input type="checkbox"/> Naturally exfoliated <input type="checkbox"/> Exfoliation prematurely due to ectopic eruption <input type="checkbox"/> Mobility (physiological) ≤1 mm
2	Slight discomfort	<input type="checkbox"/> Pathology: Questionable <input type="checkbox"/> Percussion sensitivity <input type="checkbox"/> Chewing sensitivity, short-lasting <input type="checkbox"/> Gingival inflammation (due to poor oral hygiene) <input type="checkbox"/> Mobility (physiological) >1mm but <2mm
3	Minor discomfort	<input type="checkbox"/> Pathology: initial changes present <input type="checkbox"/> Chewing sensitivity, long lasting <input type="checkbox"/> Gingival swelling (not due to poor oral hygiene) <input type="checkbox"/> Periodontal pocket formation (no exudate) <input type="checkbox"/> Mobility >2mm but <3mm
4	Major discomfort	<input type="checkbox"/> Pathology: Late changes present <input type="checkbox"/> Spontaneous pain <input type="checkbox"/> Gingival swelling (not due to poor oral hygiene) <input type="checkbox"/> Periodontal pocket formation (exudate) <input type="checkbox"/> Sinus tract present <input type="checkbox"/> Mobility ≥ 3mm <input type="checkbox"/> Premature tooth loss, due to pathology

Table 3. Criteria for Radiographic Success (adapted from Rajasekharan et al.¹⁴)

Score	Radiographic Criteria	Description
1	No changes present	<input type="checkbox"/> Internal root canal form tapering from chamber to the apex <input type="checkbox"/> Periodontal ligament (PDL)/periapical regions: normal width and trabeculation
2	Pathological changes of questionable clinical significance	<input type="checkbox"/> External changes are not allowed (widened PDL) <input type="checkbox"/> Abnormal inter-radicular trabeculation or variation on radiodensity <input type="checkbox"/> Internal resorption acceptable (nonperforated) <input type="checkbox"/> Calcific metamorphosis is acceptable and defined as: uniformly thin root canal; shape (non-tapering); variation in radiodensity from canal to canal (one cloudier than the other) <input type="checkbox"/> Dentin bridge formation (one or more canals)
3	Pathological changes present	<input type="checkbox"/> External changes are present, but not large <input type="checkbox"/> Mildly widened PDL <input type="checkbox"/> Minor inter-radicular radiolucency with trabeculation still present <input type="checkbox"/> Minor external root resorption <input type="checkbox"/> Internal resorption changes are acceptable, but not if external change is also present (perforated form)
4	Pathological changes present requiring an immediate extraction of the tooth	<input type="checkbox"/> Frank osseous radiolucency present, endangering permanent successor

RESULTS

After reviewing the 400 EHR, 102 deciduous molars in 83 pediatric patients satisfied the selection criteria and were included in the study sample. The flow diagram of the study process is illustrated in Figure 1.

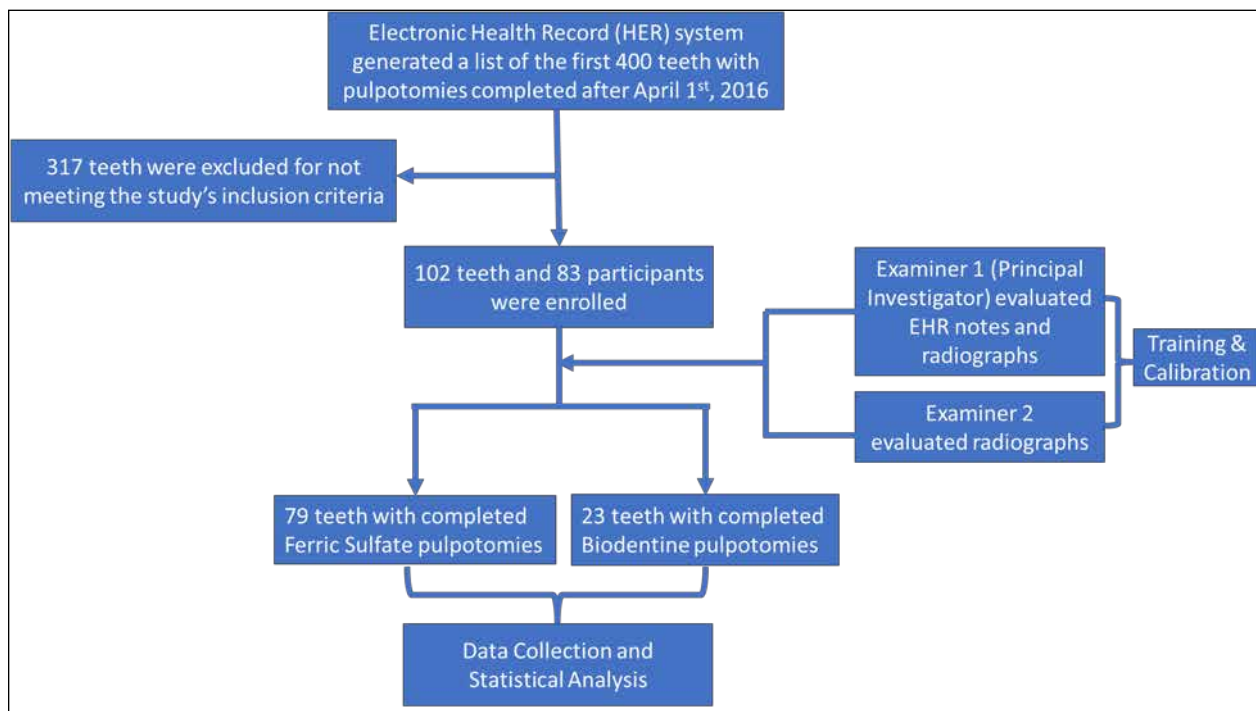
Demographic Results

The study sample consisted of 62.7% (n=52) female and 37.3% (n= 31) male participants. The mean age of the participants was 4.5 years and the median was four years, while the age range was two to eight years. The sample included 1.2% (n=1) two years old, 25.3% (n=21) three years old, 27.7% (n=23) four years old, 21.7% (n=18) five years old, 19.3% (n=16) six years old, 1.2% (n=1) seven years old, and three 3.6% (n=3) eight years old participants. Ninety four percent of the participants were within the age group of 3 to 6 years. There was a higher prevalence of Hispanics (53%, n=44), which mirrored the population seen in our PD clinics. Ninety-five percent (n=78) of the participants were healthy and the remaining 4.8% (n=4) had well-controlled asthma.

Descriptive Results of the Study Teeth

Almost 80% of the participants had a single pulpotomy (n=66), while 22.5% (n=17) had two. With respect to the diagnostic justification for the pulpotomy procedures, all of the study teeth were described as having deep caries approaching the pulp and with pulpal exposure occurring during caries excavation. Seventy-eight percent of the teeth (n=79) were treated with FS and 22% (n=23) with BD. Specific considerations for using FS or BD by the clinicians were not provided in the EHR notes. All study teeth were restored with prefabricated stainless-steel crowns immediately after the pulpotomy completion. Eighteen percent (n=18) of the pulpotomies were performed on maxillary first primary molars, 16% (n=17) on maxillary second primary molars, 27% (n=28) on mandibular first primary molars, and 39% (n=39) on mandibular second primary molars.

Figure 1. Flow Chart of Study Progress



Descriptive Results on Behavior Management Modality

With regard to patient management modality at the time of pulpotomy completion, 41 % (n=34) of the participants (with 41.2%, n=42 study teeth) received comprehensive care under general anesthesia (GA), 12% (n=10) of the participants (with 13.7%, n=14 study teeth) were managed with oral conscious sedation and 47% (n=39) participants (with 45.1%, n=46 study teeth) had treatment carried out under nitrous oxide inhalation sedation. Out of the 23 BD pulpotomies, 30.4% (n=7) were completed under GA while 69.6% (n=16) were done with nitrous oxide inhalation sedation. In the FS group, 44.3% (n=35) of the pulpotomies were completed under GA, 17.7% (n=14) under oral conscious sedation and 38% (n=30) with nitrous oxide inhalation sedation. All pulpotomies were completed during routine dental care and none were done as urgent care procedures.

Descriptive Results of Follow-up Periods

The follow-up evaluation period for all study teeth ranged from six to 36 months (mean was 17 months). The follow-up time for the BD group ranged from 12 months to 20 months (mean was 15 months). Eleven BD pulpotomies were reviewed at around one year (12 ± 2 months) and 12 at around a year and a half (18 ± 2 months). For the FS group, the follow-up periods ranged from six to 36 months (mean was 17 months). Five FS pulpotomies were reviewed at half a year (6 ± 2 months), 19 at a year (12 ± 2 months), 18 at a year and a half (18 ± 2 months), 18 at two years (24 ± 2 months), 16 at two and a half years (30 ± 2 months) and 7 at three years (36 ± 2 months).

Descriptive Results of Clinical and Radiographic Outcomes

A total of 87.3% (n=89) of all pulpotomies had no clinical signs or symptoms of pathology (scores 1 and 2) and were categorized as successful. The remaining 12.7% (n=13) were categorized as

Downloaded from http://meridian.allenpress.com/jop/article-pdf/45/1/22/2790148/1053-4628-45-1-22.pdf by guest on 15 June 2024

failures (combined scores 3 and 4). Minor discomfort (score 3) was reported for 5.9% (n=6) of the study teeth, while 6.9% (n=7) had major discomfort (score of 4). Radiographically, 23% (n=24) of the whole tooth sample failed (combined radiographic scores of 3 and 4), of which 5.9% (n=6) had required an immediate extraction (score 4).

The sample of BD pulpotomies included teeth that were clinically asymptomatic (score 1) and radiographically successful (score 1 for n=19; score 2 for n=4). Four BD pulpotomies (17.4%) had a radiographic score of 2 at a year and a half (18 ± 2 months) as changes consistent with calcific metamorphosis of the intracanal space (pulp canal obliteration) were found. The overall success rate of BD was 100% both clinically and radiographically.

The FS group, however had both clinical and radiographic failures. Overall, 16.4% (n=13) of the teeth treated with FS displayed signs of clinical failure (n=6 with score 3; n=7 with score 4) and 30% (n=24) displayed signs of radiographic failure (n=18 with score 3; n=6 with score 4). Consistent with the descriptions from the scoring system we used, the most common cause for radiographic failure was internal root resorption (IRR) with external changes (41.7%, n=10 out of 24). The clinical and radiographic failures for the teeth treated with FS occurred at different time intervals over 36 months (Figures 2 and 3). The highest number of FS failures occurred between 13 to 18 months post-operatively with 61.5% (n=8 out of the 13) clinical and 41.7% (n=10 out of the 24) radiographic failures.

Figure 2. Time Intervals of FS pulpotomies Clinical Failures

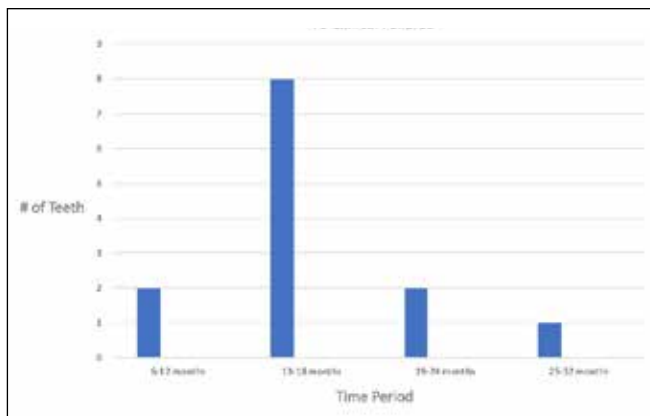
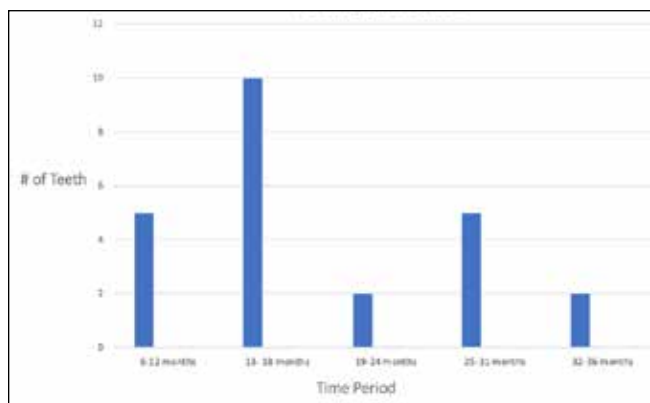


Figure 3. Time Intervals of FS pulpotomies Radiographic Failures



Comparative Analysis and Differences between FS and BD Groups

Clinical and radiographic data was available for both BD and FS at one year (12 ± 2 months) and at a year and a half (18 months ± 2 months). Eleven BD pulpotomies showed 100% clinical and radiographic success at one year, while at a year and a half 12 BD pulpotomies were found 100% successful. From the FS group, at one year 89.5% (n=17/19) of the pulpotomies were clinically successful, while 73.7% (n=14/19) were successful radiographically. At a year and a half, 55.6% (n=10/18) of the FS pulpotomies showed clinical success and 44.4% (n=8/18) had radiographic success. Statistical analysis was run using Chi-square test and it was determined that there was no statistical difference between the two groups at one-year clinical (p=0.220) as well as radiographic (p=0.289) follow-up. At a year and a half follow up, statistically significant differences were found with BD outperforming FS both clinically (p=0.012) and radiographically (p=0.001).

Intra-rater and inter-rater agreement were assessed with Cohen’s Kappa Statistic with both generating a score of κ>0.88 (good reliability).

DISCUSSION

The ideal pulpotomy material should be bactericidal, harmless to the pulp and its surrounding structures, promote healing and continuous vitality of the radicular pulp, as well as allow for normal physiological process of root resorption.^{2,4} All commercially available products have different advantages and disadvantages and the search for the ideal one is ongoing.^{2,15} Furthermore, there is a lack of general consensus regarding the best therapeutic pulpotomy agent.¹⁵ While FS has been widely used in clinical practice, BD is a relatively novel material that has similar composition and indications as MTA products.^{12,15} Calcium-silicate-based cements are increasingly popular in regenerative endodontics as they are biocompatible (nontoxic, noncarcinogenic), bactericidal (highly alkaline), insoluble in tissue fluids, and dimensionally stable.¹⁶ BD has been shown to be capable of inducing pulp healing and dentin formation.^{12,16}

Our study contributes to the literature evaluating the performance of FS and BD as pulpotomy materials in primary molars in a short and medium term by reviewing retrospectively a sample treated at a university-based PD clinic. We found that the pulpotomies completed with BD were 100% successful a year and a half post-operatively While all teeth remained clinically asymptomatic, 17.4% (n=4) of the BD group developed radiographic changes consistent with pulp canal obliteration (PCO). We considered these teeth successful radiographically (score 2). However, there is controversy in the literature regarding the categorization of PCO. Some authors deem PCO as a radiographic failure acknowledging that it presents an aberration from normal pulp.¹⁷ Others, argue that PCO is an evidence of preserved pulp vitality because is a result of hyperactivity of odontoblast-like cells, hence it should not be classified as a pathologic change or failure.¹⁸ Our results are consistent with recent studies.^{14, 19, 20} In a randomized controlled trial conducted by Rajasekharan *et al.*¹⁴, BD was compared to ProRoot® White MTA and Tempophore™ over a period of 18 months in a total sample of 69 teeth. The authors reported 95.7% clinical and 94.4% radiographic success for BD with statistically significantly more PCO compared to the other two materials.¹⁴

El Meligy *et al.*¹⁹ compared the outcomes for BD and FC in a sample of 108 primary teeth. The authors determined 100% clinical and radiographic success in the BD group, while FC had also similar outcomes (100% clinical and 98.1% radiographic success).¹⁹ Sirohi *et al.*²⁰ conducted a randomized controlled trial and evaluated the performance of BD versus FS in a sample of 50 primary molars (25 per group) over a period of 9 months. BD outperformed FS with 100% clinical and 92% radiographic success, versus 96% clinical and 84% radiographic success for the FS group.²⁰

In our study, the FS pulpotomies had an overall clinical success rate of 84% and a radiographic success of 70%, which fell within the range reported in the literature.^{2,20-22} Havale *et al.*²¹ demonstrated that in 12 months in a sample of 30 participants FS had 96.7% clinical and 63.3% radiographic success. Odabas *et al.*²² examined a sample of pulpotomies completed by dental students and reported 84.7% clinical and 78.2% radiographic success for the FS group after one year. Our cohort of FS pulpotomies showed signs of radiographic and clinical failures as early as six months post-operatively and as late as 36 months. However, the highest number of FS failures occurred between 13 to 18 months follow-up. We also determined that the most common cause for radiographic failure was IRR with external changes. Such findings are consistent with other studies.^{2,15,22,23} IRR is believed to be caused by a chronic inflammation in a tooth with a vital pulp.²³ Osteoclasts break down dentin and cementum, which leads to progressive loss of tooth structure.²³ The process of IRR stops once the pulp becomes necrotic, and thus no more viable osteoclasts and nutrients are available for the destructive process to continue.²³ FS is a known irritant, especially at higher concentrations, which can lead to the cascade ultimately causing IRR.^{15,23}

Our study had limitations, most of which are inherent to the retrospective design. Our sample size was relatively small, but it is consistent with most published studies, particularly in the BD group, and a loss to follow up is a common issue.¹⁸⁻²² Another limitation was the reliance on EHR past notes of multiple providers and existing radiographs, which were not standardized. There was a lack of information describing specific considerations regarding the choice of pulpotomy material, hence we can only hypothesize that this decision was made based primarily on clinician's preference. The inconsistent follow-up periods of the pulpotomies was a challenge but expected in the population seen in a public health setting.

Our study also had strengths. Two trained and calibrated examiners evaluated the radiographs. Prospective power analysis was utilized to estimate the initial number of EHR for assessment, as well as only consecutively completed procedures were reviewed to minimize tooth selection bias. All pulpotomy procedures were completed by post-graduate PD students with various clinical experience. However, all critical steps of their work were overseen by attending faculty members, specialists in PD. The pediatric endodontics training of the post-graduate students included the regular pulp therapy course provided by the PD department and the standard pulpotomy technique recommended by the American Academy of Pediatric Dentistry was followed in the clinic.¹ Given that FS was traditionally the standard choice of pulpotomy agent, it is understandable that more teeth of the study sample were treated with this product. Furthermore, providers have had longer experience and better expertise using FS, while utilization of BD was a novelty.

While our study showed promising results for using BD in primary molar pulpotomies, perhaps of even higher practical value to pediatric dental providers is learning more about our experience with the failed teeth treated with FS. We found that FS pulpotomies failed most frequently within 13-18 months post-operatively. Although BD is more costly than FS, its price is not prohibitive for wide clinical use, given its higher success rate. Since pediatric dentists strive to provide the most optimal therapeutic solutions for their patients, FS could be a reasonable choice for teeth with more limited life span remaining (up to two years until exfoliation), while BD can be the preferred material for younger children or those treated with advanced behavior management modalities (e.g. oral sedation, general anesthesia).

Future high-quality clinical trials with longer follow-up are needed to enhance our knowledge of the different therapeutic pulpotomy materials and for more definitive clinical practice recommendations.

CONCLUSIONS

Based on the results of this study, we can conclude that:

1. FS showed good outcomes, both clinically and radiographically, and its performance may be considered appropriate for clinical practice.
2. The highest number of FS failures occurred between 13 to 18 months post-operatively and the most common cause for FS radiographic failures was advanced internal root resorption.
3. BD outperformed FS and should be the preferred choice of primary molar pulpotomy material.
4. Pulp canal obliteration was the most common radiographic finding in the BD group.

Data Accessibility:

Data is available on request from the corresponding author.

Funding:

This was an unfunded study.

Conflict of Interest:

The authors have no conflicts of interest to declare

REFERENCES

1. Pulp Therapy for Primary and Immature Permanent Teeth. *Pediatr Dent*. Sep 15;39(6):325-333. 2017.
2. Coll JA, Seale NS, Vargas K, Marghalani AA, Al Shamali S, Graham L. Primary Tooth Vital Pulp Therapy: A Systematic Review and Meta-analysis. *Pediatr Dent*. Jan 15;39(1):16-123. 2017.
3. Ngan P, Alkire RG, Fields H. Management of Space Problems in the Primary and Mixed Dentitions. *J Am Dent Assoc*;130(9):1330-1339. 1999.
4. Fuks AB, Kupietzky A, Guelmann M. Pulp Therapy for the Primary Dentition. *Pediatr Dent*; January:329-351. 2019.
5. Ranly DM. Pulpotomy therapy in primary teeth: new modalities for old rationales. *Pediatr Dent*;16(6):403-409.1994.
6. Srinivasan V, Patchett CL, Waterhouse PJ. Is there life after Buckley's Formocresol? Part I—a narrative review of alternative interventions and materials. *Int J Paediatr Dent*; 16(2):117-27.2006.
7. International Agency for Research on Cancer. Press release no. 153. 15 June 2004. Available at <http://www.iarc.fr/pageroot/PRELEASES/pr153a.html>. Accessed August 28, 2020.
8. Landau MJ, Johnsen DC. Pulpal responses to ferric sulfate in monkeys. *J Dent Res*; 67:215.1988.
9. Lemon RR, Steele PJ, Jeansonne BG. Ferric sulfate hemostasis: effect on osseous wound healing. Left in situ for maximum exposure. *J Endod*;19(4):170-173.1993.
10. Bandi M, Mallineni SK, Nuvvula S. Clinical applications of ferric sulfate in dentistry: A narrative review. *J Conserv Dent*;20(4):278-281.2017.
11. About I. Biodentine: from biochemical and bioactive properties to clinical applications. *G Ital Endod*;30(2):81-88. 2016.
12. Mohamed S, Alamoudi NM, Meligy OAES EI. Clinical Applications of Biodentine in Pediatric Dentistry: A Review of Literature. *J Oral Hyg Heal*;03(03):1-6. 2015.
13. Zanini M, Sautier JM, Bernal A, Simon S. Biodentine Induces Immortalized Murine Pulp Cell Differentiation into Odontoblast-like Cells and Stimulates Biom mineralization. *J Endod*;38(9):1220-1226. 2012.
14. Rajasekharan S, Martens LC, Vandenbulcke J, Jacquet W, Bottenberg P, Cauwels RGEC. Efficacy of three different pulpotomy agents in primary molars: a randomized control trial. *Int Endod J*;50(3):215-228.2017.
15. Bossù M, Iaculli F, Di Giorgio G, Salucci A, Polimeni A, Di Carlo S. Different Pulp Dressing Materials for the Pulpotomy of Primary Teeth: A Systematic Review of the Literature. *J Clin Med*. Mar 19;9(3). 2020.
16. Priyalakshmi S, Manish R. Review on Biodentine: A bioactive dentin substitute. *IOSRJ Dent Med Sci* 2014;13(1):13-7.
17. Waterhouse PJ, Nunn JH, Whitworth JM. An investigation of the relative efficacy of Buckley's Formocresol and calcium hydroxide in primary molar vital pulp therapy. *Br Dent J* Jan 8;188(1):32-6. 2000.
18. Subramaniam P, Konde S, Mathew S, Sugnani S. Mineral trioxide aggregate as pulp capping agent for primary teeth pulpotomy: 2 year follow up study. *J Clin Pediatr Dent*. Summer;33(4):311-4. 2009.
19. El Meligy OAES, Alamoudi NM, Allazzam SM, El-Housseiny AAM. Biodentine™ versus formocresol pulpotomy technique in primary molars: a 12-month randomized controlled clinical trial. *BMC Oral Health*;19(1):3. 2019.
20. Sirohi K, Marwaha M, Gupta A, Bansal K, Srivastava A. Comparison of Clinical and Radiographic Success Rates of Pulpotomy in Primary Molars using Ferric Sulfate and Bioactive Tricalcium Silicate Cement: An in vivo Study. *Int J Clin Pediatr Dent*;10(2):147-151. 2017.
21. Havale R, Aneundi RT, Indushekar K, Sudha P. Clinical and radiographic evaluation of pulpotomies in primary molars with formocresol, glutaraldehyde and ferric sulphate. *Oral Health Dent Manag*;12(1):24-31.2013.
22. Odabaş ME, Alaşam A, Sillelioğlu H, Deveci C. Clinical and radiographic success rates of mineral trioxide aggregate and ferric sulphate pulpotomies performed by dental students. *Eur J Paediatr Dent*;13(2):118-122.2012.
23. Mittal S, Kumar T, Mittal S, Sharma J. "Internal root resorption: An endodontic challenge": A case series. *J Conserv Dent*.Nov;17(6):590-3. 2014.