

Occlusal Disorders in Patients with Sickle Cell Disease: Critical Literature Review

Caroline Maria Igrejas Lopes* / Suzana Silva Lira ** / Jakeline Cabral da Silva Oliveira *** / Ana Cláudia Alves e Luna **** / Paula Andréa de Melo Valença ***** / Valdenice Aparecida de Menezes*****

Objective: To identify the association of occlusal disorders in patients with sickle cell disease (SCD). **Study design:** A literature review was conducted, and articles published between 2010 and 2019 were searched on Bireme and PubMed websites and in MEDLINE and LILACS databases, in English, Portuguese, and Spanish, using the keywords “malocclusion,” “sickle cell disease,” and “cephalometry,” combined by Boolean operators AND and OR. One of the criteria for the selection of articles was the presence of adolescents in the sample. This methodology followed the PRISMA recommendations. Seventy-nine articles were found, seven of which were included in the review as they met the inclusion criteria and the study goals. **Results:** The prevalence of malocclusion in SCD patients ranged from 62.9% to 100%, which was considered very severe in 30.1% to 80.6%. The most common occlusal changes were Angle’s class II malocclusion, increased maxillary overjet, and anterior open bite. In addition, class II skeletal pattern was the most prevalent due to mandibular retrusion. **Conclusion:** Malocclusion prevalence in SCD patients is high and considered to be a risk factor, with a significant rate of very severe malocclusion when compared to healthy patients.

Keywords: Malocclusion. Sickle cell disease. Cephalometry.

INTRODUCTION

Sickle cell disease (SCD), an autosomal recessive genetic disorder¹ that originated in Africa and was brought to the Americas by the forced immigration of slaves, is highly prevalent in the black population and in its descendants². Around 20 to 25 million individuals worldwide harbor the homozygous allele, 12-15 million in Sub-Saharan Africa, 5-10 million in India, and approximately three million in other regions of the world. Approximately 8% of Afro-Americans carry the mutated gene, and the expected incidence of SCD is one in 625 births^{3,4}.

This disease is considered one of most common hereditary hemoglobinopathies in the world, and it is regarded as a global health problem⁵. It is caused by a mutation in nucleotides resulting from the replacement of glutamic acid with valine at position 6 in the beta-globin subunit. This amino acid replacement causes changes in the physical properties of the globin chain, in such a way that during physiological stresses, mainly hypoxia, hemoglobin S (HbS) polymerizes into crystals, distorting red blood cells into a sickle shape. This event also induces the expression of several cell adhesion molecules that facilitate the physical interaction of sickle-shaped erythrocytes with leukocytes and endothelium, leading to vaso-occlusive events and to hemolytic anemia, which play a key role in the clinical complications of SCD⁶.

From the Department of Pediatric Dentistry, University of Pernambuco, Camaragibe, PE, Brazil

*Caroline Maria Igrejas Lopes, PhD Student.

**Suzana Silva Lira, PhD Student.

***Jakeline Cabral da Silva Oliveira, MSc Student.

****Ana Cláudia Alves e Luna, PhD in Pediatric Dentistry.

***** Paula Andréa de Melo Valença, PhD in Pediatric Dentistry.

*****Valdenice Aparecida de Menezes, PhD, Associate Professor.

Send all Correspondence to:

Caroline Maria Igrejas Lopes

Av. General Newton Cavalcanti, nº 1650, CEP: 54753-020 Camaragibe-PE, Brazil.

Phone: + 55 81 3184-7661 / +55 81 99905-8998.

E-mail: carol_igrejas@hotmail.com

SCD is a generic term that encompasses a group of hereditary hemolytic anemias⁷ with some peculiarities, but with similar clinical and hematologic manifestations⁸. Among genetic disorders, sickle cell anemia (SCA) is clinically and hematologically the most severe and also the most prevalent⁹.

It is important to bear in mind that SCD is characterized by several acute and chronic complications, including anemia, severe infections, hemolytic and vaso-occlusive events, bouts of recurrent pain, stroke, acute chest syndrome, pulmonary hypertension, and chronic lesions in different organs^{10,11}.

SCD can affect various bodily systems, including the stomatognathic system¹². The oral manifestations of SCD are not pathognomonic for the disease and can be present in individuals with other systemic disorders¹³. The most common clinical signs are: mucosal pallor, delayed tooth eruption, enamel and dentin demineralization, hypercementosis, pulp calcifications, changes in tongue surface cells, and bone changes, resulting in maxillary protrusion and formation of a dense trabecular pattern¹⁴.

SCD also seems to be a risk factor for the development of malocclusion because erythrocytes are short-lived and need to be produced constantly and thus patients often have hyperplasia and compensatory bone marrow hyperplasia, which may cause craniofacial deformities¹⁵. Craniofacial anomalies can be observed as midfacial outgrowth/protrusion, maxillary expansion, predominantly vertical growth, mandibular retrusion, convex profile, and maxillary protrusion¹⁶.

Craniofacial anomalies may contribute to malocclusion in any individual¹⁷. In SCD patients, these anomalies may result from bone marrow hyperplasia and expansion as a way to compensate for the early destruction of red blood cells^{18,19}.

Children and adolescents with SCD often present with maxillary prognathism, caused by compensatory bone marrow hyperplasia and diastemas as a result of growth changes^{8,20,21,22}. Besides these manifestations, most SCD patients have respiratory and masticatory dysfunctions, which contribute to malocclusion²³. Thus, SCD appears to be a risk factor for moderate to very severe malocclusion, especially if related to tooth loss, anterior spacing, overjet, anterior crossbite, and open bite¹⁵. Note that malocclusion can remarkably affect the oral health-related quality of life of these patients, who require earlier dental care²⁴.

The aim of this study was to establish an association of SCD with occlusal disorders based on a literature review.

MATERIALS AND METHOD

Search strategy

The literature was reviewed through the active search of information on Bireme and PubMed websites in the MEDLINE and LILACS databases. The following descriptors (DeCs/MeSH) were used: “malocclusion,” “sickle cell disease,” and “cephalometry, combined with Boolean operators AND and OR. The search and analysis processes were conducted by two researchers. Publications were accessed for the last time on December 2019.

Eligibility criteria

Original studies on malocclusion in SCD patients were selected, and one of the selection criteria was the presence of adolescents in the sample. The search was made in English, Portuguese, or Spanish between 2010 and 2019 and only included scientific papers. Review articles and case reports were excluded.

Selection of publications and data extraction

The assessment and selection of the articles were made by two independent researchers with later comparison of the results for consensus selection of the texts. In cases of disagreement or uncertainty about the inclusion of the articles, a third researcher was consulted. Duplicate articles indexed in both databases were included only once. The selection of the publications was carried out in two stages: (1) selection by titles and abstracts and (2) qualitative analysis of full articles (Figure 1). This method followed PRISMA (Preferred Reporting Items for Systematic Reviews and Meta-Analyses) guidelines²⁵. After the selected articles were critically read, the data were analyzed, discussed, and tabulated to describe the prevalence, severity, and types of malocclusion in SCD patients.

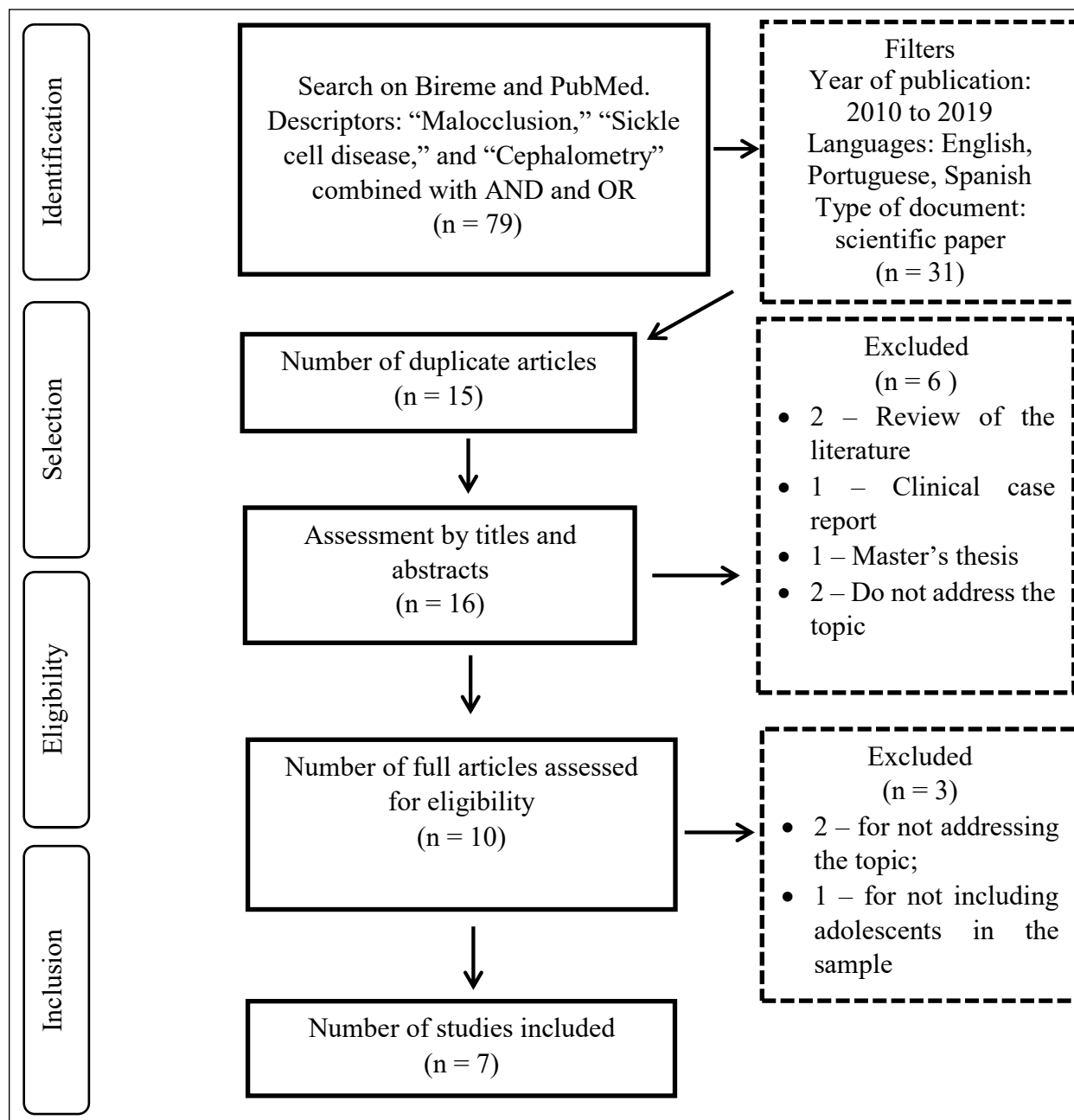
DISCUSSION

The general manifestations of SCD are widely known and well described; however, details about the oral consequences of the disease are lacking. There exist different oral manifestations of SCD, but most are not pathognomonic for the disease²⁹. Therefore, dental surgeons play a crucial role in a multidisciplinary team as they can adopt preventive measures and select effective treatments with improvements in the quality of life of patients.

The results of the present review show that SCD patients tend to develop malocclusion when compared to healthy individuals. Basyouni *et al*²⁰ demonstrate that 87.5% of Saudi Arabian adolescents with SCD presented with malocclusion compared to 54% in the control group. The rate of SCD patients with severe malocclusion was larger than in the control group (37.5% vs. 26.6%). Hence, the authors underscore the importance of regular dental assessments and early orthodontic treatment for improvement of oral health and, consequently, of the quality of life of SCD patients. Al-Hummayani and Taibah³⁰ assessed occlusion in healthy Saudi Arabian adolescents and concluded that 24.3% had severe malocclusion, which frequently consisted of crowding (48.8%) and increased overjet (21.8%). Open bite and posterior crossbite had low prevalence rates (4.8% and 3%, respectively). Therefore, when compared to healthy individuals, SCD patients had more severe and more frequent occlusal disorders such as incisal crowding (72.4%), increased overjet (67.3%), open bite (38.4%), and posterior crossbite (67%)²⁰.

Costa *et al*¹⁵ concluded that SCA is a risk factor for moderate to very severe malocclusion. The prevalence of malocclusion was 76.3% in SCA patients, and among these 30.1% was classified as very severe. As for healthy individuals, the prevalence was 52.7%, with very severe malocclusion in 2.7%. This corroborates the findings described in the literature. Onyaso and Da costa³¹ observed very severe malocclusion in 31.3% of SCA patients, whereas Luna, Godoy and Menezes²² observed it in 80.6% of their sample. Overjet (67.7%) was statistically significant between the groups and was regarded as a probable consequence in SCA patients¹⁵. Da costa *et al*³² noted increased overjet in 48.2% of SCA patients. Helaly and Abuaffan²⁷ also revealed a high prevalence of malocclusion in children and adolescents with SCD and they concluded that this disease seems to be a risk factor for malocclusion, especially when related to Angle's Class II malocclusion, increased overjet, and anterior open bite. These studies are in line with the one conducted by Pashine *et al*²⁶, in which children with SCD showed a remarkable tendency to Class II molar relationship, crowding in the incisal segment, open bite, and

Figure 1. Flowchart showing search strategy and selection of articles on Bireme and PubMed websites.



Downloaded from <http://meridian.allenpress.com/jcpd/article-pdf/45/2/117/2821732/1053-4628-45-2-117.pdf> by guest on 18 June 2024

RESULTS

Author (Year) / Country	Type of study	Sample (n)/ age range (months to years)	Orthodontic diagnostic method	Results
Pashine et al. (2019) ²⁶ / India	Comparative cross-sectional	50 with SCD 50 healthy (10–18 years)	Dental Health Component of Index of Orthodontic Treatment Need (DHC -IOTN) Dental Aesthetic Index (DAI) Cephalometric analysis	SCD patients: 24% of malocclusion, (p=0.004), (4% regarded as severe). Class II molar relationship (60%), crowding in the incisal segment (24%), increased overjet (62%), and open bite (10%) (p<0.001). SNB (77.18°) (p= 0.001) and ANB (5.58°) (p = 0.034). Control group: 4% of malocclusion (0% regarded as severe) Class II molar relationship (2%), crowding in the incisal segment (14%), increased overjet (4%), and open bite (0%). SNB (79.52°) and ANB (4.56°).

RESULTS

Author (Year) / Country	Type of study	Sample (n)/ age range (months to years)	Orthodontic diagnostic method	Results
Basyouni et al. (2018) ²⁰ / Saudi Arabia	Comparative cross-sectional	112 with SCD 124 healthy (12–18 years)	DAI Cephalometric analysis	<p>SCD patients: 87.5% of malocclusion, ($p = 0.0001$), (37.5% regarded as severe).</p> <p>Crowding in the incisal segment (72.4%) ($p = 0.016$), overjet (67.3%) ($p < 0.0001$), and upper jaw misalignment in the anterior segment (56%) ($p < 0.0001$).</p> <p>Open bite (38.4%) ($p = 0.001$). Posterior crossbite (67%) ($p < 0.0001$).</p> <p>Cephalometric analysis: SNA (86.7°) and ANB (9.9°) ($p < 0.05$).</p> <p>Control group: 54% of malocclusion (26.6% regarded as severe).</p> <p>Crowding in the incisal segment (56.7%), overjet (32.8%), and upper jaw misalignment in the anterior segment (30%). Open bite (19.3%). Posterior crossbite (37.1%).</p> <p>Cephalometric analysis: SNA (81.5°) and ANB (2°).</p>
Helaly and Abuaffan (2016) ²⁷ / Sudan	Retrospective cohort	212 with SCD 212 healthy (4–14 years)	Clinical assessment (Angle's classification)	<p>SCD patients: 4–6 years: crowding (1.3%) ($p = 0.000$), overjet (7.9%) ($p = 0.002$), increased overbite (2.6%), and anterior open bite (5.3%) ($p = 0.063$; RR= 6.1);</p> <p>7–11 years: Angle's Class II (19.7%) ($p = 0.002$), overjet (30.3%) ($p = 0.000$), increased overbite (10.6%), and anterior open bite (24.2%) ($p = 0.000$).</p> <p>12–14 years: Angle's Class II (22.9%) ($p = 0.000$), overjet (42.9%) ($p = 0.000$), increased overbite (21.4%), and anterior open bite (15.7%) ($p = 0.000$).</p> <p>Control group: 4-6 years: crowding (0%), overjet (0%), increased overbite (0%), and anterior open bite (1.3%);</p> <p>7–11 years: Angle's Class II (3%), overjet (0%), increased overbite (0%), and anterior open bite (4.5%).</p> <p>12–14 years: Angle's Class II (0%), overjet (0%) increased overbite (0%), and anterior open bite (4.3%).</p>
Costa et al. (2015) ¹⁵ / Brazil	Retrospective cohort	93 with sickle cell anemia (SCA) 186 healthy patients (16–60 years)	DAI	<p>SCA patients: 76.3% of malocclusion (30.1% regarded as very severe) ($p < 0.001$).</p> <p>SCA is correlated with loss of anterior teeth (41.9%) (RR = 1.94), anterior spacing (60.2%) (RR = 1.66), overjet (67.7%) (RR = 1.87), anterior crossbite (12.9%) (RR = 1.94), and open bite (12.9%) (RR = 1.94).</p> <p>Control group: 52.7% of malocclusion (2.7% regarded as very severe).</p> <p>Loss of anterior teeth (37.1%), anterior spacing (36%), overjet (36%), anterior crossbite (3.2%), and open bite (0.5%).</p>
Pithon et al. (2014) ²⁸ / Brazil	Cross-sectional	15 SCA patients 15 healthy patients (18–29 years)	Cephalometric analysis	<p>SCA patients: The mean SNA was 83.0°, indicating proper positioning of the mandible from the skull base. A high ANB mean was observed (5.47°) ($p < 0.001$), indicating a tendency to Class II skeletal malocclusion due to mandibular retrusion.</p> <p>Control group: The mean SNA was 79.7°, indicating proper positioning of the mandible from the skull base. The mean ANB was 1.80°.</p>
Luna, Godoy and Menezes (2014) ²² / Brazil	Cross-sectional	35 children with SCD (5 years) 36 adolescents with SCD (12–18 years)	DAI	<p>Children with SCD: The prevalence of malocclusion was 62.9%. The main types of malocclusion were Class II (37.1%), increased overjet (28.6%), poor overbite reduction (28.6%), and open bite (17.1%).</p> <p>Adolescents with SCD: The prevalence of malocclusion was 100%, and 80.6% was regarded as very severe. The most prevalent types of malocclusion were maxillary overjet (63.9%) and upper jaw misalignment (58.3%).</p>

RESULTS

Author (Year) / Country	Type of study	Sample (n)/ age range (months to years)	Orthodontic diagnostic method	Results
Maia et al. (2011) ¹⁶ / Brazil	Cross-sectional	50 SCA patients (18–43 years)	Cephalometric analysis	SCD patients: The mean SNA was 84.56°, indicating proper positioning of the maxilla from the skull base. The prevalence of Class II was 32% and 31% had maxillary protrusion; the effective maxillary length decreased by 64%. Mandibular retrusion was observed in 30% and 76% revealed shorter mandibular length. The mean ANB was 4.44°.

increased overjet when compared to healthy children. A possible explanation for this increased overjet could be the higher bone marrow activity and maxillary growth dysplasia observed in SCD patients³³. Moreover, the larger number of malocclusions in these patients could be related to muscle imbalance, lip incompetence, or changes in bone base, which indicates the need for orthodontic intervention³⁴.

Pithon *et al*²⁸ performed a cephalometric analysis of SCD patients and noted a class II skeletal pattern due to mandibular retrusion. However, in this sample, most patients did not exhibit compensatory upper jaw expansion, determined by normal mandibular length and absence of maxillary protrusion, which is at odds with studies that describe this compensatory maxillary expansion as one of the possible causes of malocclusion in these patients. Likewise, Maia *et al.*¹⁶ concluded that most patients did not have compensatory maxillary expansion determined by the prevalence of shorter maxillary length and by the absence of maxillary protrusion in SCA patients. This study also indicated a slight increase in the ANB angle (anteroposterior relationship between the maxilla and the mandible) in these patients, suggesting a tendency towards a class II pattern¹⁶. Basyouni *et al*²⁰ demonstrated a tendency towards class II malocclusion in SCD patients as the ANB angle was significantly larger than in the control group. Conversely, this study²⁰ is at odds with that carried out by Pithon *et al*²⁸ concerning the SNA angle, which represents the anteroposterior positioning of the maxilla relative to the skull base, since the mean angle observed by Basyouni *et al*²⁰ was enlarged (86.7°) and that resulted in maxillary prognathism when compared to the former study (83.0°), which indicates absence of maxillary protrusion in SCD patients²⁸.

Likewise, in the study conducted by Pashine *et al*²⁶, SCD patients had severe malocclusion that tended towards class II skeletal type, as the ANB was significantly higher in this group. In addition, SNB, used to assess the position of the mandible relative to the skull base, was significantly lower in children with SCD than in healthy ones, indicating mandibular retrusion²⁶.

Luna, Godoy and Menezes²² also verified a high prevalence of malocclusion in SCD patients, which affected 62.9% of the children. Similarly, in the latest epidemiological survey on oral health conducted by the Brazilian Ministry of Health, the prevalence of malocclusion was 66.7% in 5-year-old healthy children³⁵. On the other hand, the major types of malocclusion observed by Luna, Godoy and Menezes²² in children with SCD were Class II molar relationship (37.1%), increased overjet (28.6%), poor overbite reduction (28.6%), and anterior open bite (17.1%), with higher rates than those obtained for healthy Brazilian children, who showed class II molar relationship in 16.6% of the sample, increased overjet in 22%, poor overbite reduction in 11.9%, and anterior open bite in 12.1%³⁵. However, posterior crossbite was more prevalent (21.9%)

in healthy children according to SB Brasil³⁵ compared to 8.6% in children with SCD²². Helaly and Abuaffan²⁷ observed increased overjet in 7.9% and open bite in 5.3% of children with SCD, showing lower rates than those described in the aforementioned studies. Nevertheless, when compared to the control group, patients with SCD had higher and more significant rates of malocclusion than did healthy children²⁷.

The prevalence of malocclusion in adolescents with SCD was 100% in the study by Luna, Godoy and Menezes²², and most adolescents had very severe or incapacitating malocclusion (80.6%). These findings do not concur with those of the study carried out by SB Brasil³⁵ with healthy adolescents, in which prevalence rates were 38.8% for malocclusion at the age of 12 years, 6.5% for very severe occlusal disorders, and 35.6% for adolescents aged 15 to 19 years, with 9.1% of very severe malocclusion. The most common types of malocclusion among adolescents with SCD were maxillary overjet (63.9%) and maxillary anterior misalignment (58.3%)²². Martins *et al*³⁶ observed a significant prevalence of 31.3% for malocclusion in healthy adolescents, 5.2% for increased maxillary overjet, and 7.4% for upper jaw misalignment. The most frequent types of malocclusion were dental crowding in 51.9% of adolescents, spacing in 32.1%, and diastema in 23.7%³⁶. In adolescents with SCD, these types of malocclusion had lower prevalence rates (22.2%, 16.7%, and 13.9%, respectively)²².

This demonstrates that SCD patients tend to develop certain types of malocclusion when compared to healthy individuals, which could be explained by increased bone marrow activity, possibly leading to changes in the trabecular bone associated with bone expansion and with increased overjet between the arches due to maxillary protrusion^{8,18-22}.

However, owing to the paucity of studies on oral manifestations in SCD patients, further longitudinal studies are needed to confirm this association between malocclusion and SCD. Public policies targeted at SCD patients are of paramount importance for assessment of malocclusion and, if necessary, for early treatment, given the impact of malocclusion on the quality of life of these patients.

CONCLUSION

Studies have revealed a high prevalence of malocclusion in SCD patients, showing a high rate for very severe malocclusion when compared to that observed in healthy individuals. The most common types of malocclusion were class II molar relationship, increased overjet, and anterior open bite. Class II skeletal pattern was the most prevalent due to mandibular retrusion. Therefore, SCD patients should be followed up by dentists as well in order to initiate orthodontic treatment as soon as possible, preventing severe impact on the dentition and thus contributing to improving quality of life.

REFERENCES

1. Ashorobi D, Bhatt R. Bone Marrow Transplantation in Sickle Cell Disease. In: StatPearls. Treasure Island (FL): StatPearls Publishing, 2019. Available at: <https://www.ncbi.nlm.nih.gov/books/NBK538515/>.
2. Brasil. Ministério da Saúde. Manual de diagnóstico e tratamento de doenças falciformes. Brasília: Agência Nacional de Vigilância Sanitária – Anvisa, 2002.
3. Hassell KL. Population estimates of sickle cell disease in the U.S. *Am J Prev Med* 38: 512-521, 2010.
4. Saraf SL, Molokie RE, Nouraie M et al. Differences in the clinical and genotypic presentation of sickle cell disease around the world. *Paediatr Respir Rev* 15: 4-12, 2014.
5. Curtis K, Lebedev A, Aguirre E et al. A Medication Adherence App for Children with Sickle Cell Disease: Qualitative Study. *JMIR Mhealth Uhealth* 7: 1-26, 2019.
6. Raghunathan VM, Whitesell PL, Lim SH. Sleep-disordered breathing in patients with sickle cell disease. *Ann Hematol* 97: 755-762, 2018.
7. Felix AA, Souza HM, Ribeiro SBF. Epidemiologic and social aspects of sickle cell disease. *Rev. Bras. Hematol. Hemoter* 32: 203-208, 2010.
8. Brasil. Ministério da Saúde. Secretaria de Atenção à Saúde. Departamento de Atenção Hospitalar e de Urgência. Doença falciforme: saúde bucal: prevenção e cuidado. Brasília: Ministério da Saúde, 2014.
9. Naoum PC. Erythrocytes and environmental interferences on sickle cell anaemia. *Rev Bras Hematol Hemoter* 22: 5-22, 2000.
10. Steinberg MH. Genetic etiologies for phenotypic diversity in sickle cell anemia. *Sci World J* 9: 46-67, 2009.
11. Therrell BL, Lloyd-Puryear MA, Eckman JR et al. Newborn screening for sickle cell diseases in the United States: A review of data spanning 2 decades. *Semin Perinatol* 39: 238-251, 2015.
12. Brasil. Ministério da Saúde. Secretaria de Atenção à Saúde. Departamento de Atenção Especializada. Manual de saúde bucal na doença falciforme. Brasília: Editora do Ministério da Saúde, 2007.
13. Fonseca M, Queis HS, Casamassimo PS. Sickle cell anemia: a review for the pediatric dentist. *Pediatr. Dent* 29: 159-169, 2007.
14. Pithon MM. Orthodontic treatment in a patient with sickle cell anemia. *Am J Orthod Dentofacial Orthop* 140: 713-719, 2011.
15. Costa CP, Carvalho HL, Souza SF et al. Is sickle cell anemia a risk factor for severe dental malocclusion? *Braz Oral Res* 29: 1-7, 2015.
16. Maia NG, Dos Santos LA, Coletta RD et al. Facial features of patients with sickle cell anemia. *Angle Orthod* 81: 115-120, 2011.
17. Heimer MV, Tornisiello Katz CR, Rosenblatt A. Non-nutritive sucking habits, dental malocclusions, and facial morphology in Brazilian children: a longitudinal study. *Eur J Orthod* 30: 580-585, 2008.
18. Ramakrishna Y. Dental considerations in the management of children suffering from sickle cell disease: a case report. *J Indian Soc Pedod Prev Dent* 25: 140-143, 2007.
19. Brasil. Ministério da Saúde. Secretaria de Atenção à Saúde. Departamento de Atenção Especializada. Manual de Educação em Saúde. Brasília: Editora do Ministério da Saúde, 2008.
20. Basyouni A, Almasoud NN, Al-khalifa KS et al. Malocclusion and craniofacial characteristics in Saudi adolescents with sickle cell disease. *Saudi J Med Med Sci* 6: 149-154, 2018.
21. Javed F, Correa FO, Nooh N et al. Orofacial manifestations in patients with sickle cell disease. *Am J Med Sci* 345: 234-237, 2013.
22. Alves e Luna AC, Godoy F, De menezes VA. Malocclusion and treatment need in children and adolescents with sickle cell disease. *Angle Orthod* 84: 467-472, 2014.
23. Botelho DS, Vergne AA, Bittencourt S et al. Sistemic profile and clinical dental procedures in pacientes with sickle cell disease. *Int. J. Dent* 8: 28-35, 2009.
24. Fernandes MLMF, Kawachi I, Fernandes AM et al. Oral health-related quality of life of children and teens with sickle cell disease. *Rev Bras Hematol Hemoter* 38: 106-112, 2016.
25. Moher D, Liberati A, Tetzlaff J, Altman DG. The PRISMA Group. Preferred Reporting Items for Systematic Reviews and Meta-Analyses: The PRISMA Statement. *PLoS Med* 6: 1-6, 2009.
26. Pashine A, Shetty RM, Shetty SY et al. Craniofacial and occlusal features of children with sickle cell disease compared to normal standards: a clinical and radiographic study of 50 paediatric patients. *Eur Arch Paediatr Dent*, 2019.
27. Helaly M, Abuaffan AH. Association between Sickle Cell Disease and Malocclusion among a Sample of Sudanese Children. *IJDE* 9: 81-87, 2016.
28. Pithon MM, Palmeira LM, Barbosa AA et al. Craniofacial features of patients with sickle cell anemia and sickle cell trait. *Angle Orthod* 84: 825-829, 2014.
29. Chekroun M, Chérifi H, Fournier B et al. Oral manifestations of sickle cell disease. *Br Dent J* 226: 27-31, 2019.
30. Al-hummayani FM, Taibah SM. Orthodontic treatment needs in Saudi young adults and manpower requirements. *Saudi Med J* 39: 1-16, 2018.
31. Onyeano CO, Da Costa OO. Dental aesthetics assessed against orthodontic treatment complexity and need in Nigerian patients with sickle-cell anemia. *Spec Care Dentist* 29: 249-253, 2009.
32. Da Costa OO, Kehinde MO, Ibidapo MO. Occlusal features of sickle cell anaemia patients in Lagos, Nigeria. *Niger Postgrad Med J* 12: 121-124, 2005.
33. Williams AO, Lagundoye SB, Johnson CL. Lamellation of the diploe in the skulls of patients with sickle cell anemia. *Arch Dis Child* 50: 948-952, 1975.
34. Okafor LA, Nonnoo DC, Ojehanon PI et al. Oral and dental complications of sickle cell disease in Nigerians. *Angiology* 37: 672-675, 1986.
35. Ministério da Saúde, Secretaria de Atenção à Saúde. Departamento de Atenção Básica. SB Brasil, Pesquisa Nacional de Saúde Bucal 2010—Resultados Principais. Brasília (DF): Ministério da Saúde, 2011.
36. Martins LP, Bittencourt JM, Bendo CB et al. Malocclusion and social vulnerability: a representative study with adolescents from Belo Horizonte, Brazil. *Cien Saude Colet* 24: 393-400, 2019.