

# Lesion Sterilization Tissue Repair (LSTR) Approach Of Non-Vital Primary Molars With A Chloramphenicol-Tetracycline-ZOE Antibiotic Paste: A Scoping Review

Arturo Garrocho-Rangel\* / Carolina Jalomo-Ávila\*\* / Miguel Ángel Rosales-Berber\*\*\* / Amaury Pozos-Guillén\*\*\*\*

*The study aimed to perform a systematic scoping review with the need of exploring the actual clinical applications of the chloramphenicol-tetracycline-ZOE antibiotic paste (CTZ) as a lesion sterilization tissue repair (LSTR) therapy agent. Following a scoping framework suggested by Arksey and O'Malley, relevant articles (randomized controlled trials, literature reviews, observational studies, in vitro studies, and clinical case-series reports) published over the last 15 years (in English, Spanish, or Portuguese languages) were identified and retrieved from five internet databases: PubMed, Embase/Ovid, Cochrane Library, Google Scholar, and EBSCO. By title and abstract screening and after removing duplicates, 11 articles were finally included in the present scoping review: five randomized/non-randomized clinical trials, five in vitro studies, and one case-series report. According to the collected information, there were no differences between CTZ paste and conventional pulpectomy, antibiotic pastes, and intracanal filling materials, considering the clinical, radiographic, antimicrobial activity, and periapical tissue biocompatibility outcomes. CTZ has shown excellent rates of clinical success and good radiographic results, with adequate antimicrobial effects; however, its biocompatibility has been put into doubt. Contemporary pediatric dentists should carefully consider the CTZ paste as an alternative endodontic approach for pulpally involved primary molars, with the advantages of being simple and fast, and taking into account the limitations of instrumental pulpectomy such as the microbiological and morphological complexity of primary root canals.*

**Keywords:** CTZ Paste; Necrotic Primary Teeth; Pulp Therapy

## INTRODUCTION

The main purpose of pulp treatment in primary dentition is to maintain the integrity, health, and functionality of the teeth and supporting tissues until their natural exfoliation.<sup>1</sup> Whenever it is possible, the vitality of the pulp tissue must be preserved in cases of deep caries, traumatic injuries, or other abnormal conditions. Invasive pulp treatments are therefore primordial to avoid premature tooth loss and potential subsequent abnormal changes in mastication, speech/phonetics, esthetics, and length of dental arches, and the occurrence of harmful oral habits.<sup>2,3</sup> Thus, different techniques have been proposed in the dental literature for the debridement, cleansing, and disinfection of the root canal system in irreversible inflamed/infected/necrotic primary teeth.<sup>4</sup>

Untreated decay or trauma can cause the pulp tissue of the primary tooth to become irreversibly inflamed, abscessed, or necrotic, as a result of deep caries or trauma, and other related factors that influence the endodontic treatment's success. Treatment options include extraction, conventional root canal therapy, or the application of topical antibiotic pastes.<sup>3</sup> Given the complex morphology of the primary root canal system and the physiological root resorption process, both characteristic of the primary molars,

From the Pediatric Dentistry Postgraduate Program, Faculty of Dentistry, San Luis Potosí University, San Luis Potosí, SLP, México.

\*Arturo Garrocho-Rangel, DDS, PhD, Associated Professor.

\*\*Carolina Jalomo-Ávila, DDS, Resident.

\*\*\* Miguel Ángel Rosales-Berber, DDS, MS, Associated Professor.

\*\*\*\* Amaury Pozos-Guillén, DDS, PhD, Associated Professor.

### Corresponding author:

Amaury Pozos-Guillén, Faculty of Dentistry, San Luis Potosí University, Av. Dr. Manuel Nava # 2, Zona Universitaria, C.P. 78290; San Luis Potosí, SLP, México.

Phone: +52 4448262300 X 5134.

E-mail: apozos@uaslp.mx

and the lack of cooperation from some children, the conventional access and biomechanical instrumentation may be challenging. Considering the limitations of the primary tooth canal preparation, the use of simplified techniques employing antibiotic pastes has been encouraged during the routine clinical practice not only because they significantly reduce the operative time on the dental chair and the associated treatment costs, but also promote the reduction of pathogenic bacteria within the root canals, especially in those inaccessible locations.<sup>5</sup> These pastes are placed on the pulp chamber floor, performing no type of canal preparation.<sup>6</sup> The procedure is referred to as *noninstrumental endodontic treatment* and is based on the *lesion sterilization and periapical tissue repair approach* (LSTR). Despite LSTR has been practiced and promoted more than 25 years ago in Japan, Brazil, and other countries, it was not until recently that the AAPD has recognized it as a useful option in pediatric endodontics for irreversible inflamed or necrotic primary teeth, under several diagnostic criteria.<sup>1</sup>

LSTR was initially promoted by Soller and Capiello (Argentina), and by Sato and Hoshino (Japan).<sup>4,7</sup> In 1959, Soller y Capiello described a biocompatible antibiotic mixture (called CTZ paste), composed of chloramphenicol 500 mg, tetracycline 500 mg, Zinc Oxide 1 g, and eugenol (one drop), as an alternative for traditional endodontic treatment of primary molars with irreversible pulpitis or pulp necrosis. The CTZ paste possesses good antimicrobial activity, with reported excellent clinical and radiographic outcomes; the paste application procedure is simple, can be carried out in one session, promotes stabilization of bone resorption, and does not cause tissue sensitivity.<sup>8</sup> Its major disadvantages are the potential pigmentation of the crown and the enamel hypoplasia in the successor premolar because of the presence of tetracycline, which exhibits a high affinity for calcified tissues.<sup>3,9</sup>

In this context, the present scoping review study aimed to perform a systematic scoping review with the need of exploring the actual clinical applications of the CTZ paste as an LSTR therapy agent, a simple and quick endodontic procedure for non-vital primary molars, through the most valuable current literature describing its potential clinical and radiographic effectiveness.

## MATERIALS AND METHOD

The present scoping study was conducted following the framework suggested by Arksey and O'Malley<sup>10</sup> and Bragge *et al*<sup>11</sup> This framework comprise five steps: (i) designing the research question; (ii) identifying relevant studies through a literature search; (iii) analyzing selected studies; (iv) extracting and charting data; and (v) collating, summarizing, and reporting the results. Besides, this review used the PRISMA (Preferred Reporting Items for Systematic Reviews and Meta-Analyses) reporting guideline and adjusted them to apply to a scoping review.<sup>12</sup> In addition, the protocol of the present review was registered in the Open Science Framework (OSF) database, under the Registration DOI 10.17605/OSF.IO/KMN7U.

First, a research question was structured based on the PICO format (**P**atient/**I**ntervention/**C**omparison/**O**utcome) to scope the extent of the research available on the clinical topic and to avoid the early exhaustion of literature during the search process. Thus, the research question was: In primary molars with irreversible pulpitis or pulp necrosis, is the CTZ antibiotic paste clinical and

radiographic effective when placed over the pulp canals entrance, regarding conventional pulpectomy and other LSTR pastes?

To find potentially relevant articles to answer this question, an initial electronic search was performed by three authors (CJA, MARB, and DATH) to identify appropriate titles and abstracts between January 2006 and May 2021, in the following databases: PubMed, EMBASE/Ovid, Google Scholar, the EBSCO Dentistry and Oral Sciences Source, and the Cochrane Library. This search included and combined several keywords, synonyms, and free terms; it also included subject terms from each database's thesaurus (Medical Subject Headings or MeSH) as well as keyword searching of title and abstract fields.

The search strategy was carefully implemented by employing four major concepts: 'CTZ paste', 'primary (or deciduous) teeth', 'pulpectomy (or endodontic treatment)', and 'LSTR'. This procedure was appropriately adapted for each selected database. The exact search terminology used in PubMed is described in Figure 1.

**Figure 1. The used searching algorithm in PubMed for the present scoping review.**

```
("ctz"[All Fields] AND ("ointments"[MeSH Terms] OR "ointments"[All Fields] OR "paste"[All Fields] OR "pastes"[All Fields] OR "pasting"[All Fields]) AND ("primaries"[All Fields] OR "primary"[All Fields] OR ("deciduous"[All Fields] OR "deciduousness"[All Fields])) AND ("teeth s"[All Fields] OR "teeth"[All Fields] OR "tooth"[MeSH Terms] OR "tooth"[All Fields] OR "teeth"[All Fields] OR "tooth s"[All Fields] OR "tooth"[All Fields]) AND ("pulpectomy"[MeSH Terms] OR "pulpectomy"[All Fields] OR "pulpectomies"[All Fields]) AND (("endodontal"[All Fields] OR "endodontic"[All Fields] OR "endodontical"[All Fields] OR "endodontically"[All Fields] OR "endodontics"[MeSH Terms] OR "endodontics"[All Fields]) AND ("therapeutics"[MeSH Terms] OR "therapeutics"[All Fields] OR "treatments"[All Fields] OR "therapy"[MeSH Subheading] OR "therapy"[All Fields] OR "treatment"[All Fields] OR "treatments"[All Fields]))
```

To be eligible for review, articles had to meet the following criteria: articles written in English, Spanish or Portuguese languages published in the last 15 years (January 2006 up to May 2021), whose main purpose was to study the clinical and radiographic outcomes of CTZ paste applied in primary teeth with irreversible pulpitis or pulp necrosis. The selected methodological designs were randomized clinical trials, observational studies (cohorts, case-control designs, cross-sectional studies, and clinical case-series reports), *in vitro* trials, or review articles; for longitudinal studies, a minimum of 4 months of follow-up was required. Clinical single-case reports, gray literature, comments, editorials, short communications, and letters were excluded from the review. The chosen articles were then retrieved in full text and were read and assessed by two experienced reviewers (JAGR and AJPG) separately to create the definitive list of studies to be included. The reference lists of selected articles were also manually screened to find other potentially eligible studies. Any discrepancy was discussed and resolved by consensus with the aid of a third examiner (MARB).

Important data from included studies were extracted and entered a predesigned and piloted standardized tracking and review form to present a narrative account of the relevant literature and avoid overlapping. From each article, the following information was recorded: general characteristics (authors, year of publication, geographical location); study methodological design; participants' clinical features (range and mean age, gender, oral status, etc.); comparative or control endodontic material or technique; main clinical

and radiographic outcomes; follow-up time and treatment success evaluation criteria; key findings or conclusions, and authors' recommendations. A judgment was also performed concerning whether each outcome was primarily clinician-centered. Thereafter, data was collected, detailed, cross-checked, summarized, and discussed accordingly. The present scoping review process was structured as a flow diagram (Figure 2).

**RESULTS**

The initial search on January 4, 2021, yielded 37 titles of potential relevance. When the search was manually updated on May 20, 2021, an additional 4 references were identified. Eleven of them were then excluded because of duplications. Collectively, both searches resulted in 30 abstracts that were subsequently screened by two reviewers (AJPG and JAGR), and 12 of them were excluded because of non-related or irrelevant intervention. Thus, 18 full-text articles were further assessed in detail for eligibility by the same two reviewers; any conflicts were resolved with a third reviewer (MARB).

Seven articles were then excluded because of following reasons: three could not be retrieved in full-text form, one was not written in English, Spanish, or Portuguese, two were associated with other endodontic therapy different from pulpectomy (e.g. pulpotomy), and one was published in a predatory journal with notorious methodological deficiencies. As a result, 11 full-length papers were included in the present scoping review.

Eight articles were written in English, two in Spanish, and one in Portuguese; they were published between 2006 and 2021. The entire selection process is described in the flow diagram depicted in Figure 2. Table 1 exhibits the general characteristics of the studies included. Most of the studies retrieved were conducted in Latin America (mainly from Brazilian authors) and were five randomized/non-randomized controlled clinical trials;<sup>6,13-16</sup> five *in vitro* studies;<sup>5,9,17-19</sup> and one extensive case-series report.<sup>7</sup> After exploring the final selection of the studies, an extensive amount of relevant clinical information was condensed. The main findings from this entire process are described in the discussion section.

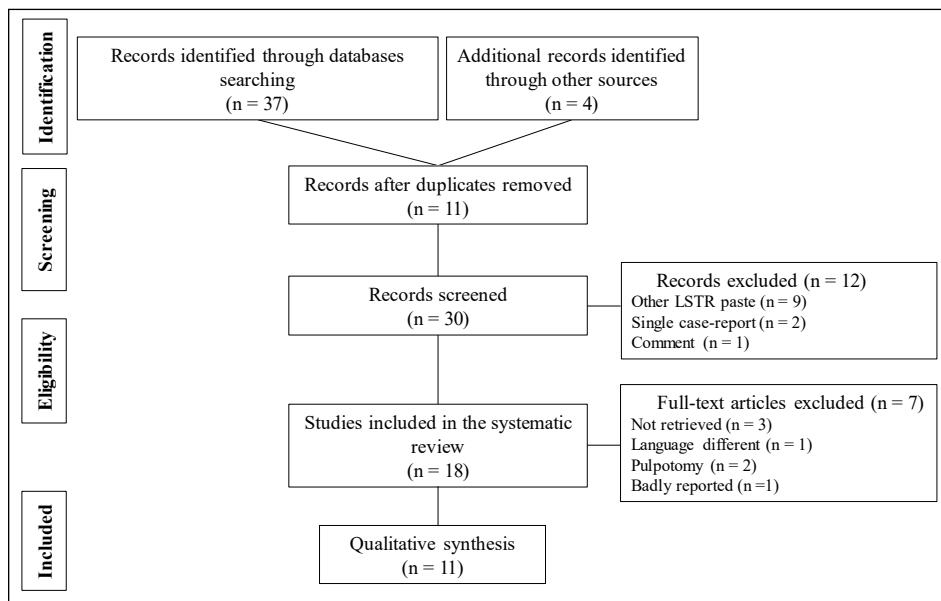
**DISCUSSION**

Scoping reviews are designed to examine the main body of available published evidence with a broad approach regarding a specific topic in dentistry and other health sciences to identify the boundaries and the context of that topic, as well as summarize the most important information and results of the included studies. Currently, many published articles use this type of review to provide a concise qualitative analysis.<sup>20</sup> These reviews also summarize the current knowledge to find conclusions and tendencies from the general data. In addition, scoping reviews may identify the literature gaps, directing future researches.<sup>21</sup>

Despite the extensive implementation of several preventive and rehabilitative measures for dental caries in young children worldwide, around 50% of them still exhibit at least one primary tooth with a caries lesion needing dental treatment.<sup>22</sup> Primary teeth with severe carious lesions and pulp involvement, particularly those with infected root canals and periradicular tissues, are a common problem, which leads to a negative impact on the oral health-related quality of life.<sup>22,23</sup> For these cases, dental literature has described and proposed diverse techniques like conventional/instrumental pulpectomy (bio or necropulpectomy). This procedure comprises a series of steps including absolute/total isolation, odontometry, chemical/mechanical preparation (debridement and modeling) of the pulp canals, profuse irrigation, and canal drying and filling. These procedures require competent clinicians' performance and involve special instruments and materials that are not always available in public dentistry services. However, many deprived children have no choice but the extraction of the affected tooth. Private dental clinics and offices may a possibility but such treatments are often too pricey for this vulnerable population.<sup>6</sup>

Pediatric endodontic therapy plays an important role in eliminating pathogenic bacteria, their byproducts, and substrates through the neutralization of their ecosystem by biochemical instrumentation. Those bacteria present in the superficial layers of infected root canal dentin may be easily removed, but microorganisms in the deep layers may survive and migrate to the periapical/periradicular regions and cause complications; additionally, pathogenic bacteria may smear the root canal during the endodontic instrumentation.<sup>23,24</sup>

**Figure 2. Flow diagram for literature search.**



**Table 1. General characteristics of the studies included in the scoping review.**

Author (Year)	Study design	Aim and procedures	Country	Main outcomes/findings
Amorim et al. (2006) <sup>17</sup>	<i>In vitro</i> study	<ul style="list-style-type: none"> <li>• <i>Aim.</i> To compare the antimicrobial action of five root canal filling pastes (Guedes-Pinto paste, zinc oxide-eugenol, calcium hydroxide, CTZ, and Vitapex)</li> <li>• Five microbial strains (<i>S. aureus</i>, <i>E. faecalis</i>, <i>P. aeruginosa</i>, <i>B. subtilis</i>, and <i>C. albicans</i>)</li> <li>• At 1, 24, 48, and 72 h</li> </ul>	Brazil	<ul style="list-style-type: none"> <li>• All pastes exhibited complete their antimicrobial effects after 24 h</li> <li>• In the agar diffusion test, all materials, except Vitapex, induced the formation of inhibition zones (6.0–39.0 mm)</li> </ul>
Piva et al. (2008) <sup>5</sup>	<i>In vitro</i> study	<ul style="list-style-type: none"> <li>• <i>Aim.</i> To evaluate the antimicrobial activity of six root canal filling pastes (Guedes-Pinto paste, zinc oxide-eugenol, Calen, CTZ, L&amp;C, and MTA)</li> <li>• Five microbial strains (<i>S. aureus</i>, <i>E. faecalis</i>, <i>P. aeruginosa</i>, <i>B. subtilis</i>, and <i>C. albicans</i>) in a microbial mixture</li> <li>• At 24, 48, and 72 h</li> </ul>	Brazil	<ul style="list-style-type: none"> <li>• A complete antimicrobial activity was observed only for CTZ and MTA pastes</li> <li>• Guedes-Pinto, ZOE, Calen, and L&amp;C exhibited microbial growth at the different evaluation times</li> </ul>
Lacativa et al. (2012) <sup>18</sup>	<i>In vitro</i> study	<ul style="list-style-type: none"> <li>• <i>Aim.</i> To compare the biocompatibility, by the intra-osseous implant technique, of three root canal filling pastes (Guedes-Pinto paste, calcium hydroxide, and CTZ)</li> <li>• Thirty Guinea pigs, two experimental periods (4 and 12 weeks)</li> <li>• At the end of these periods, an histological evaluation was carried out</li> </ul>	Brazil	<ul style="list-style-type: none"> <li>• 4 weeks: CH and CTZ induced severe inflammation, large amounts of necrotic tissue, lymphocytes, foreign body cells, and bone resorption; while Guedes-Pinto paste exhibited little or no inflammation</li> <li>• 12 weeks: Guedes-Pinto and CH pastes showed absent/mild reactions, with recently replacement bone tissue formation; CTZ presented moderate/severe inflammatory response</li> <li>• Guedes-Pinto paste exhibited high biocompatibility, CH acceptable biocompatibility, and CTZ no compatibility</li> </ul>
Pérez-Hernández et al. (2012) <sup>13</sup>	Quasi-experimental study	<ul style="list-style-type: none"> <li>• <i>Aim.</i> To compare the clinical and radiographic effectiveness of CTZ antibiotic paste and conventional biopulpectomy</li> <li>• 60 necrotic primary teeth of children aged 4-8 years</li> <li>• The evaluations were performed at 2 weeks, 3, and 6 months</li> </ul>	México	<ul style="list-style-type: none"> <li>• Both procedures exhibited a similar clinical and radiographic effectiveness after 6 months of follow-up</li> <li>• However, CTZ present more persistence of radiolucencies at the 3 and 6-month evaluations (<math>p &lt; 0.01</math>)</li> </ul>
Mariz-Sousa et al. (2014) <sup>14</sup>	Quasi-experimental (before-after) study	<ul style="list-style-type: none"> <li>• <i>Aim</i> To assess the clinical and radiographic effectiveness of CTZ antibiotic paste</li> <li>• 24 patients with 36 necrotic primary teeth treated between 2005 and 2010</li> <li>• <i>Aim</i> To determine the clinical and radiographic effectiveness of CTZ compared to Guedes-Pinto modified paste</li> </ul>	Brazil	<ul style="list-style-type: none"> <li>• 15 teeth (42%) exhibited some type of clinical and radiographic alteration, mainly crown color alterations</li> <li>• There were also 5 cases of pain and 2 cases of fistulae</li> <li>• Enamel hypoplasia was found in the succedaneous permanent teeth (30%) after treatment</li> <li>• Both pastes showed similar symptoms/signs decrease rates at the different evaluation times</li> </ul>
Calixto-Chanca et al. (2014) <sup>15</sup>	Randomized controlled clinical trial	<ul style="list-style-type: none"> <li>• 48 patients aged 3-6 years with 56 necrotic primary teeth randomly assigned (27 teeth treated with CTZ and 29 with GPM)</li> <li>• Evaluations were performed at 2, 8, and 16 weeks</li> </ul>	Perú	<ul style="list-style-type: none"> <li>• CTZ and GPM exhibited clinical and radiographic effectiveness in every period assessments</li> <li>• CTZ presented faster radiographic outcomes regarding periradicular radiolucencies healing</li> </ul>

Downloaded from <http://meridian.allenpress.com/jcpd/article-pdf/45/6/369/3000345/1053-4628-45-6-369.pdf> by guest on 18 June 2024

Author (Year)	Study design	Aim and procedures	Country	Main outcomes/findings
Siegl et al. (2015) <sup>6</sup>	Randomized controlled clinical trial	<ul style="list-style-type: none"> <li><i>Aims.</i> To follow (1) the radiolucent areas (in pixels) in the furcal area and (2) the clinical behavior of the endodontically treated primary molars with two LSTR techniques (CTZ and Guedes-Pinto pastes as pulp chamber fillings)</li> <li>20 necrotic primary teeth indicated for necropulpectomy were randomly assigned to study groups (10 teeth treated with CTZ and 10 with GP)</li> <li>Evaluations were performed at 6 and 12 months</li> <li><i>Aim.</i> To present a series of 38 cases of necrotic primary molars (some with abscess and/or furcal radiolucencies) treated with CTZ antibiotic based past, performed between March 2010 and December 2014</li> </ul>	Brazil	<ul style="list-style-type: none"> <li>Both pastes showed similar clinical effectiveness rates at the two evaluation times</li> <li>CTZ presented higher reduction of radiolucent areas after 6 months (<math>p &lt; 0.01</math>) and 12 months (<math>p &lt; 0.01</math>)</li> <li>GP paste exhibited a non-significant reduction in the furcal area after 12 months (<math>p &lt; 0.9</math>)</li> </ul>
Almeida de Deus-Moura et al. (2016) <sup>7</sup>	Case-series	<ul style="list-style-type: none"> <li>CTZ paste was placed at the entrance of root canals</li> <li>28 children aged 4 to 10 years</li> <li>Treatments were evaluated at 3-6 months, 7-12 months, 13-24 months, and 24-36 months</li> <li><i>Aim</i> To quantitatively and qualitatively evaluate the blood inflammatory cell profile from the alveolar region (tooth socket) after the extraction of primary molars treated with CTZ paste</li> </ul>	Brazil	<ul style="list-style-type: none"> <li>There were 100% of clinical success and 93% of radiographic success</li> <li>The blood cellularity in the tooth socket from teeth treated with CTZ paste was very similar to that of healthy extracted teeth and physiologically different from untreated decayed teeth</li> </ul>
Almeida de Deus-Moura et al. (2018) <sup>19</sup>	<i>In vitro</i> cross-sectional study	<ul style="list-style-type: none"> <li>48 primary molars indicated for extraction were divided into three groups: (1) healthy, (2) untreated decayed, and (3) treated with CTZ</li> <li>Immediately after the extraction, a blood sample from the socket was collected for evaluation</li> <li><i>Aim</i> To evaluate the clinical and radiographic success of three different LSTR techniques applied in primary molars requiring pulpectomy</li> </ul>	Brazil	<ul style="list-style-type: none"> <li>These findings suggest that teeth endodontically treated with CTZ paste maintain a tooth socket integrity after the extraction and the paste's ability to control infection after endodontic treatment</li> </ul>
Lokade et al. (2019) <sup>16</sup>	Randomized controlled clinical trial	<ul style="list-style-type: none"> <li>63 primary molars requiring pulpectomy of 50 children aged 4 to 8 years</li> <li>Three study groups: (1) modified 3Mix paste without removal of accessible radicular pulp, (2) modified 3Mix paste with the removal of accessible radicular pulp, and (3) CTZ paste.</li> <li>The children were followed up clinically for 1, 6, and 12 months; and radiographically for 6 and 12 months</li> <li><i>Aim</i> To determine and compare the prevalence of enamel defects in premolars whose infected predecessors (primary molars) were endodontically treated with CTZ paste or extraction</li> </ul>	India	<ul style="list-style-type: none"> <li>After twelve months of observation, the clinical success rates were (1) 90%, (2) 90.5%, and (3) 81.8%; the radiographical success rates were (1) 75%, (2)76.2%, and (3) 63.6%</li> <li>Enamel defects were globally present in 22.5% of premolars</li> </ul>
Santos-Sousa et al. (2020) <sup>9</sup>	<i>In vitro</i> study	<ul style="list-style-type: none"> <li>1017 premolars from children and adolescents divided into three groups: (1) primary molars with pulp necrosis treated with CTZ, (2) extracted necrotic primary molars, and (3) healthy primary molars physiologically exfoliated</li> </ul>	Brazil	<ul style="list-style-type: none"> <li>Group 2 exhibited an OR (3.52, CI95% 2.29-5.4) about CTZ</li> <li>The prevalence of enamel defects in premolars was highest in extracted necrotic primary molars than those treated with CTZ paste</li> </ul>

LSTR approach is a simplified technique that has been proposed as a biologic alternative to conventional pulpectomy, as a long term endodontic treatment, in order to facilitate the sterilization/disinfection/healing of dentin carious lesions, necrotic/abscessed pulp canals, and periapical regions in primary teeth, with the advantages of being faster and simpler; also, it does not require multiple visits and can be applied independently of the physiologic root resorption degree.<sup>4,24</sup> Taking into account that the long-term successful outcome of conventional pulpectomy has been reported in the dental literature up to 85%, the use of such alternative pulp procedures should be considered a suitable therapy with comparable or better rates; nevertheless, radiographic success is lower in the long-term follow-up.<sup>25</sup> Besides, and according to Coll and colleagues' recommendations, even primary teeth with significant preoperative root resorption can be maintained in the dental arches if they are managed with LSTR therapy. This procedure should be the treatment choice over pulpectomy to save such teeth for up to 12 months; if retained longer, they have to be periodically monitored with clinical examinations and radiographs at least every 12 months.<sup>3</sup>

LSTR strategy comprises the topical placement of a combination or mixture of antibacterial drugs in the pulp chamber floor with no mechanical instrumentation to eliminate or minimize the number of pathogenic microorganisms in the root canal system of primary teeth; thus, LSTR prevents unnecessary enlargement of root canals and irritation of periapical tissues.<sup>26</sup> The operative process is as follows: after opening the pulp chamber, the canal orifices are carefully enlarged with a round bur to create medication receptacles. Then, these receptacles are irrigated and cleaned, and the antibiotic paste is placed directly on them. The paste is covered with glass ionomer cement and the tooth is restored with a preformed stainless steel crown.<sup>1</sup> For the LSTR approach, the selected antimicrobial drugs should possess the ability to deeply penetrate the root dentin wall tubules. A single antimicrobial cannot be effective enough even if it has a broad spectrum activity; this is because of the complex polymicrobial composition inside the contaminated root canal system of primary molars mainly comprising aerobe and obligate anaerobes.<sup>23,27,28</sup> Alone, a single antibiotic is unable to eliminate bacteria, but, in combination, these drugs can to consistently sterilize the pulp canal system.<sup>28</sup>

Different LSTR antibiotics and their combinations have been tested in clinical trials to date. The present scoping review assessed the clinical and radiographic of CTZ antibiotic paste applied on pulpally involved primary molars, following the principles of the LSTR approach. According to the retrieved results, CTZ therapy showed no significant differences regarding conventional pulpectomy, given the favorable findings from the selected studies, published fifteen years ago. This paste has evidenced both clinical and radiographic successes rate up to almost 100% and 93% respectively in previous studies, under different evaluation criteria and follow-up times.<sup>7,16</sup> It has also shown equivalent clinical and radiographic results to those reported by 3-Mix paste (metronidazole or ornidazole, ciprofloxacin, and minocycline or cefaclor) and different root canal filling materials (Vitapex®, calcium hydroxide, and zinc-oxide eugenol alone) in previous studies.<sup>23,26,29</sup> On the other hand, Nakornchai and colleagues<sup>26</sup> do not recommend the application of LSRT pastes in children at risk of infective endocarditis and also by the potential damage to the successor tooth or cyst formation in the periapical area.

Bacteria play a crucial role in the initiation, progression, and persistence of infection inside pulp root canals. Microorganisms can remain viable deeply in dentin and cementum despite profuse irrigation with sodium hypochlorite and contribute to endodontic failure. Therefore, these bacteria must be neutralized to ensure a successful outcome.<sup>28</sup> As an LSTR agent, CTZ paste contains two broad-spectrum and bacteriostatic antibiotics: tetracycline and chloramphenicol. Tetracycline acts against several aerobic bacteria, facultative anaerobes, spirochetes, and Gram (+) and Gram (-) microorganisms; whereas chloramphenicol possesses bactericidal properties against Gram (+) bacteria and many anaerobes.<sup>2</sup> Both drugs are mixed with eugenol, which also has sedative and antimicrobial (vs. *Staphylococcus*, *Micrococci*, *Bacillus*, and *Enterobacteria* for over 30 days) properties and zinc-oxide as the vehicle.<sup>30</sup> In this same regard, CTZ has demonstrated strong microbial growth inhibition of aerobic and anaerobic microorganisms (*S. aureus*, *E. faecalis*, *P. aeruginosa*, *B. subtilis*, and *C. albicans*), commonly found in infected non-vital primary teeth.<sup>5,17</sup> CTZ evenly distributes throughout the primary canal system, inducing a sterilization process and promoting tissue repair and healing.<sup>7,16</sup> In addition, CTZ stimulates a bone deposition in the radiolucent areas and resolves pretreatment clinical signs and symptoms.<sup>1</sup> In this same regard, CTZ demonstrated strong microbial growth inhibition of aerobic and anaerobic microorganisms (*S. aureus*, *E. faecalis*, *P. aeruginosa*, *B. subtilis*, and *C. albicans*), commonly found in infected non-vital primary teeth.<sup>5,17</sup>

Regarding the biocompatibility and/or possible histological harm to periapical tissues and successor premolar enamel by the CTZ paste, diverse *in vitro* studies have been conducted. Clinicians should consider that the furcal region in primary molars has a reduced dentin/cementum thickness with areas of resorption, and it is permeated by accessory foramen and channels. Thus, the increased permeability in this area favors the potential diffusion of drugs used in pulp therapy, which can trigger an inflammatory reaction and promote the formation of periradicular lesions involving surrounding tissues and developing successor premolar buds.<sup>9,19</sup> Two studies concluded that the CTZ paste exhibited a low risk of damage to the periodontal ligament or enamel defects in premolars.<sup>9,19</sup> However, Lacativa and co-workers,<sup>18</sup> in a guinea-pig study, observed that the paste induced moderate/severe inflammation, necrotic tissue, and bone resorption after twelve weeks of the CTZ paste application, possibly due to its eugenol content; these authors rated this paste as no biocompatible, with highly irritating potential to periapical tissues.

**Limitations.** Unlike systematic reviews, scoping reviews do not incorporate a quality assessment of the studies included. This scoping review was aimed at collecting useful clinical information that is available and easily accessible to help pediatric dentistry practitioners during the treatment of pulpally involved primary molars. Through this approach, we intended to define the scope of the literature relevant to this clinical topic. However, as with any scoping review, a likely publication bias was present because of the selection of studies conducted only in English-or Spanish-or Portuguese-speaking countries, primarily due to limited resources for translation. Furthermore, the article search was restricted to the last 15 years; thus, our reference screening might have been underrepresented. However, we are confident that a significant number of studies included here provided an overview and useful information for the pediatric endodontics practice. Other limitations of the present study were the highly

heterogeneous methodological issues of the detected articles and our limited ability to consistently summarize the details of the extracted data or findings from the retrieved articles.

## CONCLUSIONS

The outcomes and findings of the available studies included in this scoping review suggest that, to date, there were no confirmed differences between topical CTZ paste, as LSTR therapy agent, and conventional instrumental pulpectomy, other antibiotic pastes, and diverse intracanal filling materials, considering the clinical, radiographic, antimicrobial activity, and periapical tissue biocompatibility outcomes. According to this, CTZ has shown excellent rates of clinical success and good radiographic results in the long-term follow-up, with appropriate antimicrobial effects; however, its periapical tissue biocompatibility could be questionable. Further research through high-quality clinical trials should be conducted before this antibiotic paste can be considered an ideal material or a substitute for instrumental pulpectomy in the treatment of primary teeth with irreversible pulp disease or pulp necrosis.

## Conflict of interest.

The authors declare that they have no conflict of interest

## Ethical approval.

This article does not contain any studies with human participants or animals performed by any of the authors.

## Informed consent.

For this type of literature review, formal consent is not required.

## REFERENCES

- American Academy of Pediatric Dentistry. Pulp therapy for primary and immature permanent teeth. The Reference Manual of Pediatric Dentistry. Chicago, Ill; American Academy of Pediatric Dentistry; 384–392, 2020.
- Luengo-Ferreira J, Ayala-Jiménez S, Carlos-Medrano LE, Toscano-García I, Anaya-Álvarez M. Clinical and radiographic evaluation of formocresol and chloramphenicol, tetracycline and zinc oxide-eugenol antibiotic paste in primary teeth pulp tomies: 24 month follow up. *J Clin Pediatr Dent*; 2019; 43: 16–21.
- Coll JA, Dhar V, Vargas K, Chen CY, Crystal YO, AlShamali S, Marghalani AA. Use of non-vital pulp therapies in primary teeth. *Pediatr Dent*. 2020; 42: 337–349.
- Duarte ML, Pires PM, Masterson-Ferreira D, Braga-Pintor AV, de Almeida-Neves A, Cople-Maia L, Guimarães-Primo L. Is there evidence for the use of lesion sterilization and tissue repair therapy in the endodontic treatment of primary teeth? A systematic review and meta-analysis. *Clin Oral Invest*; 2020 24: 2959–2972.
- Piva F, Faraco-Junior IM, Estrela C. Antimicrobial activity of different root canal filling pastes used in deciduous teeth. *Material Res*; 2008; 11: 171–173.
- Siegl RMC, Lenzi TL, Politano GT, De Benedetto M, Imparato JCP, Pinheiro SL. Two endodontic techniques analysis in a primary molar with fistula. *Rev Gaúch Odontol Porto Alegre*. 2015; 63: 187–194.
- Almeida de Deus-Moura LF, Moura de Lima MD, Branco-Lima CC, Gomes-Machado JIA, Silva de Moura M, Vasconcelos de Carvalho P. Endodontic treatment of primary molars with antibiotic paste: A report of 38 cases. *J Clin Pediatr Dent*. 2016; 40: 175–177.
- Luengo-Ferreira J, Reyes-Rivas H, Toscano I, Garcia-Flores Y, Anaya-Álvarez M, Del Muro-Casas F. Clinical and radiographic evaluation of CTZ (chloramphenicol-tetracycline-zinc eugenol oxide) antibiotic paste in pulp treatment of primary molars. *J Dent Health Oral Dis Ther*. 2017; 8: 451–455.
- Santos-Sousa HC, Moura de Lima MD, Branco-Lima CC, Silva de Moura M, Lopes-Bandeira AV, Almeida de Deus-Moura LF. Prevalence of enamel defects in premolars whose predecessors were treated with extractions or antibiotic paste. *Oral Health Prevent Dent* 2020; 18: 793–798.
- Arksey H, O'Malley L, et al. Scoping studies: Towards a methodological framework. *Int J Soc Res Methodol*. 2005; 8: 19–32.
- Bragge P, Clavisi O, Turner T, Tavender E, Collie A, Gruen RL. The Global Evidence Mapping Initiative: Scoping research in broad topic areas. *BMC Med Res Methodol*. 2011; 11: 92.
- Moher D, Liberati A, Tetzlaff J, Altman DG, PRISMA Group. Preferred reporting items for systematic reviews and meta-analysis: The PRISMA statement. *Int J Surg*. 2010; 8: 336–341.
- Pérez-Hernández PE, Curioca-Rocha SA, Retana-Ugalde R. Efectividad terapéutica de la pasta CTZ vs. biomecánica convencional en pulpa necrótica de escolares de 4-8 años. *Odont Pediatr Act*. 2012; 2: 28–36.
- Mariz-Sousa P, Cavalcanti-Duarte R, Alves de Sousa S. Acompanhamento clínico e radiográfico de dentes decíduos submetidos à terapia pulpar com a pasta CTZ. *Braz Res Pediatr Dent and Integrat Clin*. 2014; 14(Supl 3): 56–68.
- Calixto-Chanca KS, Correa-Olaya EI, Anchelia-Ramírez SH. Efectividad clínica y radiográfica de dos pastas antibióticas empleadas en necrosis pulpar en niños de un hospital nacional del Perú. *KIRU*. 2014; 11: 115–122.
- Lokade A, Thakur S, Singhal P, Chauhan D, Jayam C. Comparative evaluation of clinical and radiographic success of three different lesion sterilization and tissue repair techniques as treatment options in primary molars requiring pulpectomy: An *in vivo* study. *J Indian Soc Pedod Prev*. 2019; 37: 185–191.
- Amorim LFG, De Toledo OA, Estrela CRA, Decurcio DA, Estrela C. Antimicrobial analysis of different root canal filling pastes used in pediatric dentistry by two experimental methods. *Braz Dent J*. 2006; 17: 317–322.
- Lacativa AM, Loyola AM, Alves-Sousa CJ. Histological evaluation of bone response to pediatric endodontic pastes: An experimental study in Guinea pig. *Braz Dent J*. 2012; 23: 635–644.
- Almeida de Deus-Moura LF, Moura de Lima MD, Branco-Lima CC, Lopes-Bandeira AV, Silva de Moura M, Mendes-Conde-Junior A, Dos Santos-Rizzo M. Cellular profile of primary molars with pulp necrosis after treatment with antibiotic paste. *Int J Exp Pathol*. 2018; 99: 264–268.
- Conde MC, Chisini LA, Sarkis-Onofre R, Schuch HS, Nor JE, Demarco FF, et al. A scoping review of root canal revascularization: Relevant aspects for clinical success and tissue formation. *Int Endod J*. 2017; 50: 860–874.
- Chisini LA, Muniz-Conde MC, Grazioli G, Schmidt-San Martin A, Varella de Carvalho R, et al. Bone, periodontal and dental pulp regeneration in dentistry: A systematic scoping review. *Braz Dent J*. 2019; 30: 77–95.
- Tedesco TK, Reis TM, Mello-Moura ACV, Da Silva GS, Scarpini S, Floriano I, et al. Management of Deep caries lesions with or without pulp involvement in primary teeth: A systematic review and network meta-analysis. *Braz Oral Res*. 2021; 35:e004.
- Prabhakar R, Sridevi E, Raju O, Satish V. Endodontic treatment of primary teeth using a combination of antibacterial drugs: An *in vivo* study. *J Indian Soc Pedod Prevent Dent*. 2008; 26 (Suppl 1): S5–S10.
- Raslan N, Manisour O, Assfoura L. Evaluation of antibiotic mix in non-instrumentation endodontic treatment of necrotic primary molars. *Int J Paediatr Dent*. 2018; 18: 285–290.
- Doneria D, Thakur S, Singhal P, Chauhan D, Keshav K, Uppal A. In Search of a novel substitute: Clinical and radiological success of lesion sterilization and tissue repair with modified 3Mix-MP antibiotic paste and conventional pulpectomy for primary molars with pulp involvement with 18 months follow-up. *Contemp Clin Dent*. 2017; 8: 514–521.
- Nakornchai S, Banditsing P, Visetratana N. Clinical evaluation of 3Mix and Vitapex® as treatment options for pulpally involved primary molar. *Int J Paediatr Dent*. 2010; 20: 214–221.
- Agarwal M, Mohan-Das U, Vishwanath D. A comparative evaluation of non-instrumentation endodontic techniques with conventional ZOE pulpectomy in deciduous molars: An *in vivo* study. *World J Dent*. 2011; 2: 187–192.
- Pinky C, Shashibhushan KK, Subbareddy VV. Endodontic treatment of necrosed primary teeth using two different combinations of antibacterial drugs: An *in vivo* study. *J Indian Soc Pedod Prevent Dent*. 2011; 2: 121–127.
- Mortasavi M, Mesbahi M. Comparison of zinc oxide and eugenol, and vitapex for root canal treatment of necrotic primary teeth. *Int J Paediatr Dent*. 2004; 14: 417–424.
- Reis B, Barbosa C, Soares L, Brum S, Barbosa O, Marques M. *In vitro* analysis of antimicrobial activity of CTZ binder used as material plug in deciduous teeth pulp. *R Pró-Uni*. 2016; 7: 39–42.