

# Multiple Idiopathic Internal Root Resorption in an Adolescent: A Case R Multiple Idiopathic Internal Root Resorption in an Adolescent: A Case Report

Jae-Gook Seung\*/ Jae-Gon Kim\*\*/ Yeon-Mi Yang\*\*\*/Dae-Woo Lee\*\*\*\*

*Internal root resorption (IRR) refers to a slow or rapid progressive resorption process that occurs in the pulp cavity of the tooth or the dentin of the root. IRR occurs as result of odontoclast action; in many cases, the pulp tissue exhibits chronic inflammation, and odontoblasts and predentin do not appear on the dentin wall near the pulp. Exact predisposing factors have not been clearly elucidated; therefore, it is difficult to identify reliable data on the prevalence of IRR because of its scarce occurrence and pathology. Reports have indicated that IRR is more common in the primary than in the permanent teeth. This case report discusses a 17-year-old girl with multiple idiopathic internal root resorptions of anterior permanent teeth in a short period of a time and its management.*

**Keyword:** Internal root resorption, Idiopathic resorption, Decoronation, Adolescent.

## INTRODUCTION

Internal root resorption (IRR) is a pathologic process in which dentin around the pulp chamber is degraded by the action of clastic cells.<sup>1,2</sup> Due to the rare occurrence and the lack of in vivo research, the etiology and pathogenesis of IRR have not been elucidated.<sup>3</sup> Possible etiologic factors for IRR have been suggested and include dental trauma, orthodontic treatment, caries, cracked teeth, and periodontal infection.<sup>4</sup> For dental practitioners, diagnosis and management of IRR are challenging due to its idiopathic occurrence.<sup>5</sup> The majority of IRR cases progresses without any symptoms and is detected accidentally in clinical or radiographic exams.<sup>6</sup> We report a case of a 17-year-old girl who showed a series of multiple idiopathic internal root resorptions on her anterior teeth.

## Case report

In March 2015, an 11-year-old girl was referred to the Jeonbuk National University Dental Hospital due to issues with mobility of #41. The patient did not experience any dental trauma or pain around #41 and had no known medical history except superior mesenteric artery syndrome. Intraoral examination did not reveal any specific pathologic findings on the tooth except increased mobility of #41, while adjacent teeth were normal. In radiographic examination, the periodontal ligament (PDL) space was normal, apical radiolucency was not prominent, while round radiopacity was prominent and reached the cemento-enamel junction from the pulp chamber (Fig. 1A). To preserve alveolar bone, decoronation of #41 was planned with professional tooth cleaning due to poor oral hygiene with severe plaque retention (Fig. 1B).

---

From the Department of Pediatric Dentistry and Institute of Oral Bioscience, School of Dentistry, and the Research Institute of Clinical Medicine of Jeonbuk National University-Biomedical Research and Institut Jeonbuk National University, Jeonju, Republic of Korea

\*Dae-Woo Lee, DDS, PhD.

\*\*Jae-Gook Seung, DDS.

\*\*\*Jae-Gon Kim, DDS, PhD.

\*\*\*\*Yeon-Mi Yang, DDS, PhD.

### Corresponding author:

Dae-Woo Lee

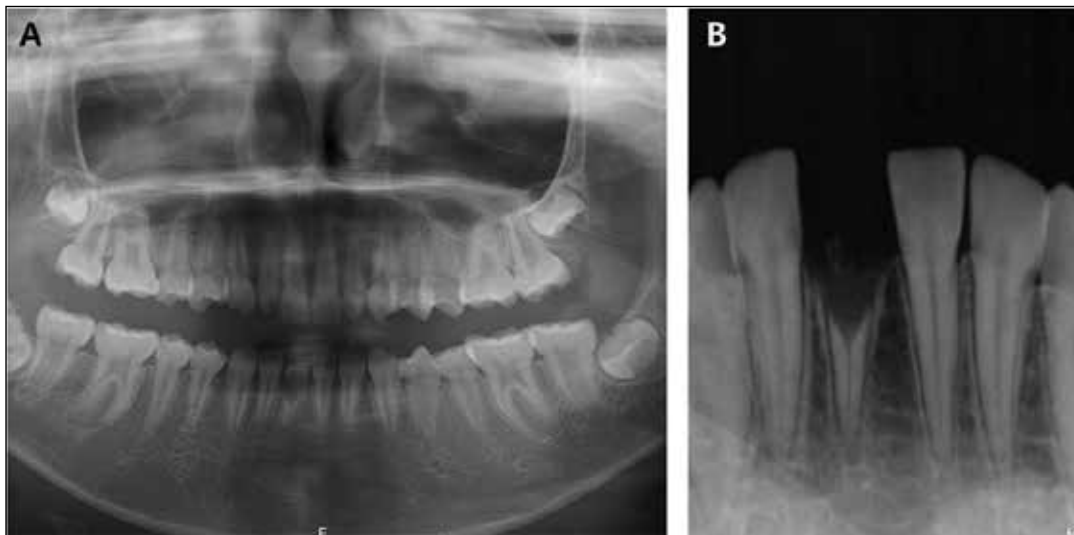
Department of Pediatric Dentistry, School of Dentistry, Jeonbuk National University, Jeonju, Korea  
567, Baekje-daero, Deokjin-gu, Jeonju-si, Jeollabuk-do, 561-712, Republic of Korea.

Phone: +82-63-250-2826

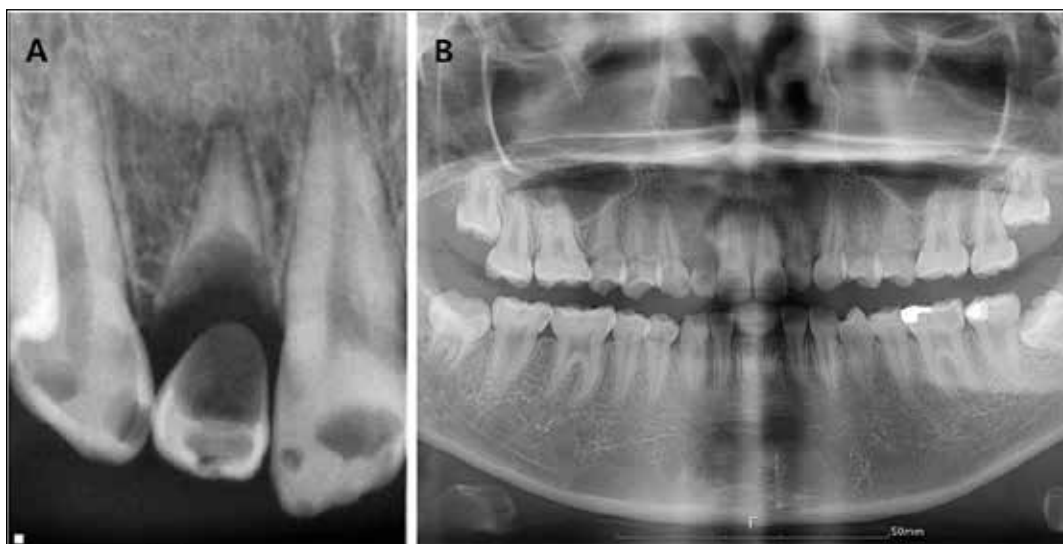Fax: +82-63-250-2131

E-mail: oklee@jbnu.ac.kr

**Figure 1. (A) Panoramic image of an 11-old girl with internal root resorption on tooth #41. (B) Periapical image of the root rest of #41 after decoronation.**



**Figure 2. (A) Periapical image of tooth #12 with progressed internal root resorption. (B) Panoramic image 4 years after the initial visit.**



In 2019, four years after receiving treatment, the patient visited the clinic for accompanying mobility of #12 without any pain. In the periapical view of #12, the crown and root part were separated almost completely due to a radiolucent lesion that reached the apical 1/3 even though an apical lesion was not identified (Fig. 2A). Intra-oral and radiographic examination revealed healthy periodontium in the edentulous region of #31 and #41 (Fig. 2B). Because of poor oral hygiene and multiple caries, comprehensive dental treatment was planned, including professional tooth cleaning, treatment for caries and extraction of #12. Due to loss of most of the #12 tooth structure, bone resorption due to inflammation rather than maintenance of alveolar bone was anticipated; therefore, extraction of the #12 tooth was planned. Additionally, to determine the relationship between the patient's physical condition and IRR, we measured her general status, conducted blood tests, and asked about her dietary habits. Compared to her age group, her height and weight

percentiles were 43th and 1st, respectively. Blood tests did not reveal any specific problems, and her calcium and phosphorus levels were within normal ranges. She ate once a day and rarely brushed her teeth.

Three months later, the patient visited the clinic due to issues with mobility of #22. Intraoral exam showed mobility of #22 without any pain from palpation or percussion. (Fig. 3A). Follow-up analysis of the extracted #12 was good. However, her oral hygiene had not improved significantly. Radiographic exam indicated remarkable IRR on #22, which was not clearly identified on the radiographic view from 3 months prior (Fig. 3B). Decoronation of #22 was planned to preserve alveolar bone, with consideration of additional prosthetic treatment. Upper and lower removable space maintainers were installed (Fig. 4).

Because the internal root resorption occurred multiple times and progressed within 3 months, full mouth periapical radiography

and CBCT were performed to evaluate hidden internal resorption on whole dentition (Fig 5A). Compared to #11, an enlarged pulp chamber was found in the CBCT view of #21 (Fig. 5B). The other teeth did not exhibit remarkable pathologic signs. After 2 weeks, IRR of #21 appeared remarkably changed in the periapical view (Fig. 5C).

Consequently, endodontic treatment of #21 was planned to halt the progression of the IRR. Root canal treatment was performed, and pulpal hyperemia was observed. During endodontic treatment, IRR of #21 did not progress further; after the endodontic treatment was completed, #21 was restored (Fig. 6). After finishing the treatment, professional tooth cleaning was performed with additional patient education to improve oral hygiene during follow-up (Fig. 7A). We

scheduled the patient once a month for additional follow-up to evaluate the remaining teeth with radiographic examinations (Fig. 7B). To date, new lesions associated with IRR have not been observed within the 1 year of follow-up after treatment.

**DISCUSSION**

Internal root resorption is a pathological type of tooth resorption which is initiated in most cases by an inflammatory pulp reaction, and starts within the tooth.<sup>4,7</sup> The cause of the pulp inflammation and subsequent resorption of tooth is unclear.<sup>1</sup> The pathological mechanism of internal resorption has not yet been clearly identified, however, according to the results of studies to date, internal resorption occurs when predentin and odontoblast layer damage occur in

Figure 3. (A) Intraoral image of both dentitions 3 month after #12 extraction. (B) Periapical image of #22.

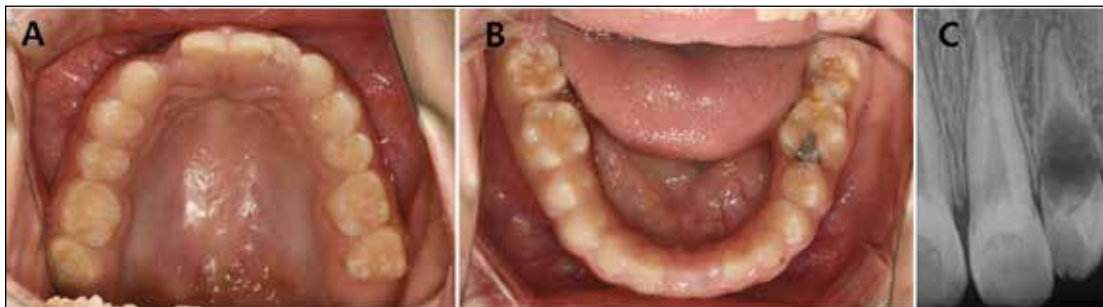


Figure 4. (A) Coronal part of #22 after decoronation. (B) Image prior to the delivery of the removable space maintainer (RSM). (C) After delivery of RSM.

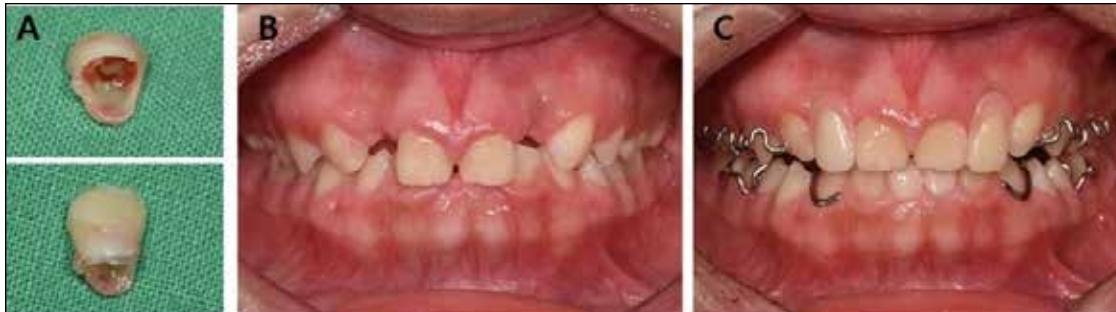

Figure 5. (A) Periapical image of #21. (B) CBCT view of tooth #21 compared to #11, with an enlarged pulp chamber. (C) Periapical image of #21, taken 2 weeks after CBCT and demonstrating remarkable IRR of #21.

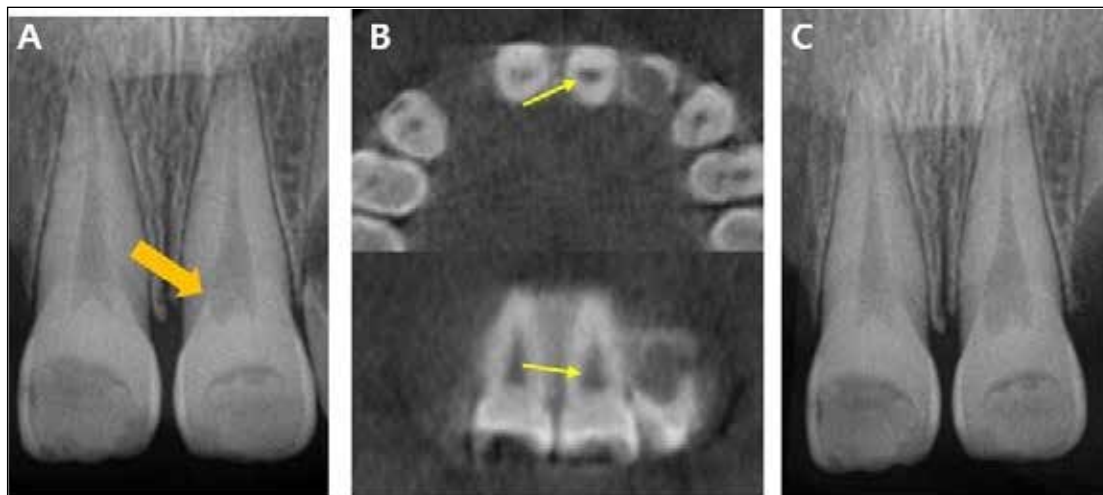


Figure 6. (A) Before root canal treatment of #21. (B) During the treatment. (C) After the canal filling was completed.

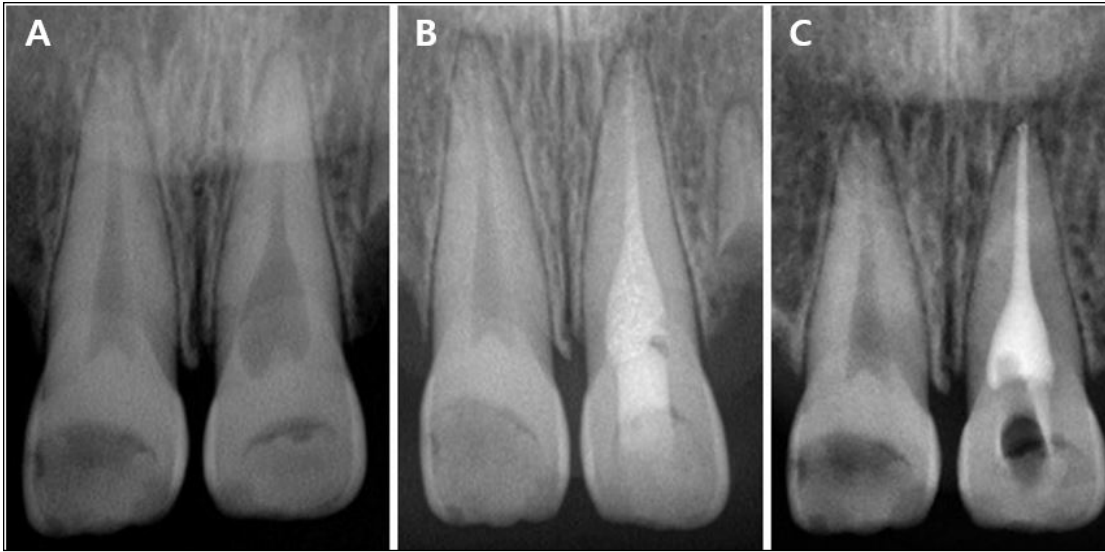
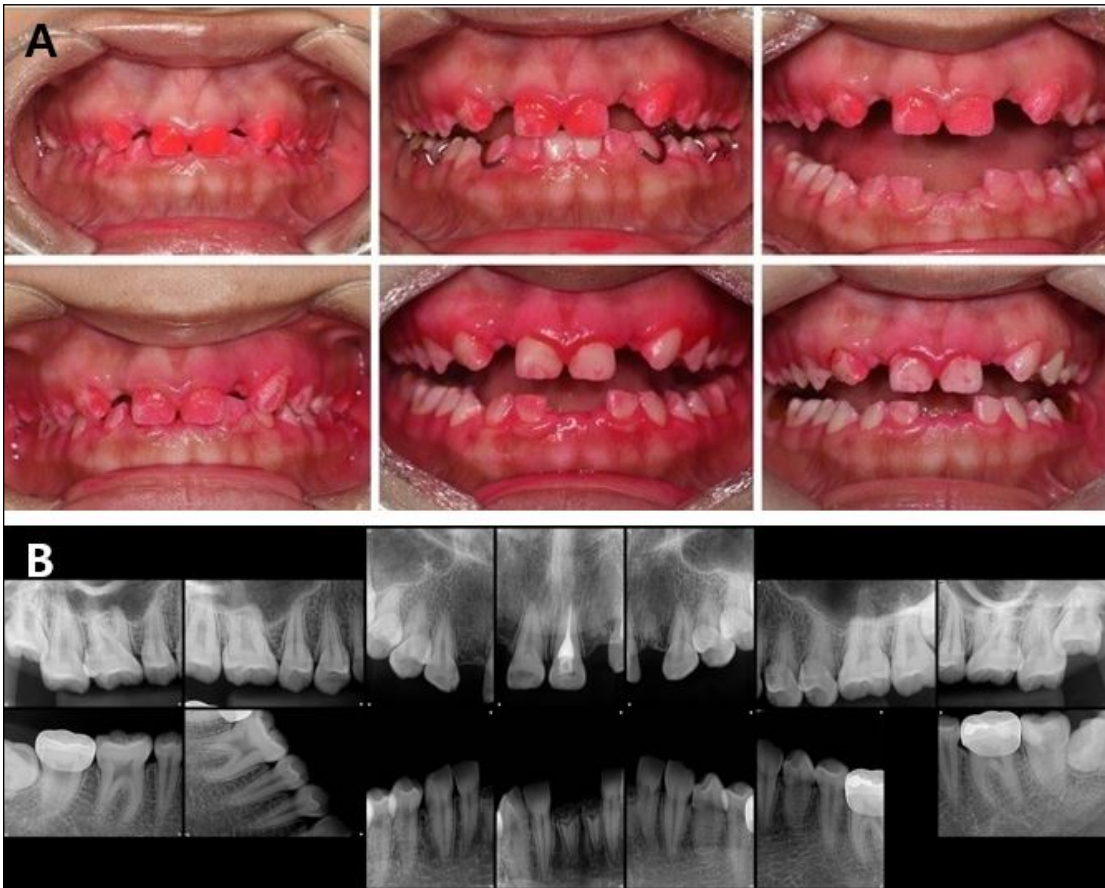

Figure 7. (A) Intraoral image after applying a disclosing agent, Improvement of oral hygiene after professional tooth cleaning and with patient education. (B) Full mouth periapical view at the latest follow-up, no remarkable pathologic findings are noted.



conjunction with inflammatory reactions.<sup>8</sup>

Various etiologic factors have been proposed for IRR such as trauma, caries, periodontal infections, excessive heat during restorative treatment, procedures using calcium hydroxide, vital root reactions, orthodontic treatment, cracked teeth, or simple idiopathic dystrophic changes within normal pulps.<sup>4</sup> Among these, the etiology in this case can be attributable to a history of treatment for caries,

poor oral hygiene, and malnutrition. However, to date, there are no clear pathologic findings of periodontal tissue, and no cases of internal root resorption due to multiple caries or malnutrition have been reported. Therefore, in this case, it is inferred that there could be an additional etiology that caused the IRR.

Several case reports have proposed causes for idiopathic IRR. Bitra Talebzadeh et al. report a case of IRR that was associated with



varicella zoster virus (VZV) and involved different dental quadrants.<sup>9</sup> In this case, there was no history of herpes zoster infection, and no antibody to VZV was detected in the antibody test.

Nagaraj *et al* also reported a case of a female patient with multiple IRRs that had a confirmed diagnosis of hyperparathyroidism.<sup>10</sup> Although no direct hormone test was performed in this case study, it can be inferred that there was no hyperparathyroidism based on the blood test results. Urban *et al* presented a case of monozygotic twins with idiopathic IRR on #21.<sup>11</sup> After additional analysis, polymorphism of the IL-1 gene was discovered by genetic analysis of these cases. The presence of the IL-1β+C3953 allele is a predisposing factor for susceptibility to an exaggerated inflammatory response, including a limited feedback mechanism due to IL-1RN mutation. Although we performed a genetic test, no polymorphism of the gene was found.

Depending on the degree of internal resorption, the following treatment plans can be considered for patients.<sup>12</sup> The teeth with IRR can be monitored if there are no signs or symptoms of infection. Extraction can be performed if the IRR has progressed to the extent that restoration is impossible. In general, when IRR occurs, root canal treatment is performed, and in the case of perforation, the root canal treatment is completed after the perforation is closed with a bioactive material such as mineral trioxide aggregate (MTA).<sup>12-14</sup>

In this case report, IRR was identified for #41, #31, #12, #21 and #22. Decoronation with crown removal but retention of the root without any intervention was performed to maintain the alveolar bone for later prosthetic restoration.<sup>15-17</sup> This approach can be used to prevent full extraction of a tooth that cannot be restored and can be maintained without significant further problems. Therefore, we recommend decoronation as an alternative method of extraction if there are no signs of severe inflammation.

IRR usually proceeds asymptotically and is most frequently found by chance on radiographic images.<sup>6, 8, 12</sup> However, in radiographic imaging, such as panoramic or periapical images, early stages of IRR might not be detected, and there are difficulties in determining a differential diagnosis from other diseases.<sup>18</sup> In contrast, cone beam computed tomography (CBCT), which is expressed in three dimensions, can obtain information on the location, size, and shape of the lesion.<sup>6</sup> Consequently, early detection and accurate diagnosis of IRR are possible using CBCT. This can minimize tooth structure loss, and a better prognosis can be expected if IRR is detected early. If multiple IRR occurs, as in this case, CBCT can be used to evaluate the IRR in other teeth.

Most studies on IRR currently exist in the form of case reports,<sup>9-11, 19, 20</sup> and studies about pathogenesis and etiology have been conducted only through limited *in vivo* experiments<sup>8</sup>, so our knowledge about IRR is still limited and further studies are needed.

**CONCLUSION**

This is a rare case of an adolescent patient with multiple, idiopathic internal root resorption (IRR) on permanent anterior teeth. The affected teeth were treated with decoronation, root canal therapy, and extraction, depending on the degree of the resorption. Furthermore, patients that present with multiple IRRs should be screened through a meticulous radiographic exam (like CBCT) with a short period of visits so that clinicians can identify IRR in the early stages and provide adequate treatment to preserve the teeth and optimize patient outcomes.

**Funding:**

This work was supported by the Biomedical Research Institute, Jeonbuk National University Hospital.

**Conflict of Interest:**

The authors declared no conflict of interest.

**REFERENCES**

1. Haapasalo M, Endal U. Internal inflammatory root resorption: the unknown resorption of the tooth. *Endodontic topics*, 2006; 14(1): 60-79.
2. Ilea A, Miclăuş V, Ruxanda F, Bianca Boşca A, Septimiu Câmpian R, Bianca Petrescu N, Băbţan A-M, Ştefania Mesaros A. Osteoclasts recruitment in internal root resorption associated with external granuloma. *Integrative Molecular Medicine*, 2018; 5(5).
3. Endal MHU. Internal inflammatory root: the unknown resorption of the tooth. *Endodontic topics*, 2006; 14: 60-79.
4. Patel S, Ricucci D, Durak C, Tay F. Internal root resorption: a review. *J Endod*, 2010; 36(7): 1107-1121.
5. Calişkan MK, Türkün M. Prognosis of permanent teeth with internal resorption: a clinical review. *Endod Dent Traumatol*, 1997;13(2): 75-81.
6. Patel S, Dawood A, Wilson R, Horner K, Mannocci F. The detection and management of root resorption lesions using intraoral radiography and cone beam computed tomography—an *in vivo* investigation. *Int Endod J*, 2009; 42(9): 831-838.
7. Wedenberg C, Lindskog S. Experimental internal resorption in monkey teeth. *Dent Traumatol*, 1985; 1(6): 221-227.
8. Thomas P, Krishna Pillai R, Pushparajan Ramakrishnan B, Palani J. An insight into internal resorption. *ISRN Dent* 2014: 759326, 2014.
9. Talebzadeh B, Rahimi S, Abdollahi AA, Nouroloyuni A, Asghari V. Varicella Zoster Virus and Internal Root Resorption: A Case Report. *J Endod*, 2015; 41(8): 1375-1381.
10. Eswar Nagaraj RPK, PH Raghuram, P Suresh Kumar. Multiple internal resorption in permanent teeth associated with hyperparathyroidism. *Indian J DentRes*, 2013;24(1): 128-131,.
11. Urban D, Mincik J. Monozygotic twins with idiopathic internal root resorption: A case report. *Aust Endod J* , 2010;36(2): 79-82.
12. Nilsson E, Bonte E, Bayet F, Lasfargues JJ. Management of internal root resorption on permanent teeth. *Int J Dent*, 2013; 929486. doi: 10.1155/2013/929486. Epub 2013 Nov 21
13. Main C, Mirzayan N, Shabahang S, Torabinejad M. Repair of root perforations using mineral trioxide aggregate: a long-term study. *J Endod*, 2004;30(2): 80-83.
14. Jacobovitz M, De Lima R. Treatment of inflammatory internal root resorption with mineral trioxide aggregate: a case report. *Intern Endod J*, 2008;41(10): 905-912,.
15. Cohenca N, Stabholz A. Decoronation—a conservative method to treat ankylosed teeth for preservation of alveolar ridge prior to permanent prosthetic reconstruction: literature review and case presentation. *Dent Traumatol* , 2007;23(2): 87-94.
16. Malmgren B. Ridge preservation/decoronation. *Pediatr Dent* 35(2): 164-169, 2013.
17. Sigurdsson A. Decoronation as an approach to treat ankylosis in growing children. *Pediat Dent* , 2009;31(2): 123-128.
18. Gulabivala K, Searson L. Clinical diagnosis of internal resorption: an exception to the rule. *Intern Endod J* , 1995;28(5): 255-260.
19. Choi EJ, Ahn BD, Lee JI, Kim JW. Multiple internal resorptions in deciduous teeth: a case report. *J Oral Pathol Med*, 2007; 36(4): 250-251.
20. Matsumoto-Nakano M, Kamakura N, Miyamoto E, Okawa R, Inagaki S, Fukuda Y, Ooshima T. Multiple sites of idiopathic internal resorption in primary dentition: A case report. *Pediat Dent J*, 2009; 19(1): 150-153.