

# Safety and Efficacy of IV Dexmedetomidine as an Adjunct to Propofol to Sedate Anxious and Uncooperative Pediatric Dental Patients: A Randomized Controlled Trial

Ferah Rehman\*/ Ashima Goyal\*\*/ Krishan Gauba \*\*\*/ Kajal Jain\*\*\*\* / Aditi Kapur\*\*\*\*\*

**Objective:** To evaluate the safety and efficacy of dexmedetomidine (dex) as an adjunct to propofol sedation in pediatric dental patients. **Study design :** This RCT enrolled 30 anxious ASA-I 2-5 year olds. Allocated into 2 groups either receiving IV propofol (1 mg/kg)(Gp-P) or [IV dex (1ug/kg) with propofol(1 mg/kg)] (Gp-D) after oral midazolam premedication (0.5 mg/kg). Sedation maintained with propofol infusion at 50-75ug/kg/min. Additional bolus/es of propofol (1mg/kg) was/were administered in case of inadequate sedation. Primary outcome was to compare requirement of propofol in two groups. Secondary outcomes were to compare vital signs, depth of sedation, induction, treatment and recovery time, intra & post-operative complications and analgesic requirement post-operatively. **Results:** Total propofol (in mgs) used and number of additional boluses were significantly higher in group P ( $p < 0.05$ ). Although within normal limits, heart rate was significantly lower in group D. Respiratory rate, oxygen saturation, NIBP were comparable. Depth of sedation achieved was comparable at all steps ( $p > 0.05$ ). Induction time (mins) was significantly lower in Group P ( $p < 0.05$ ), however treatment and recovery time were similar ( $p > 0.05$ ). Desaturation was observed in 3/15(group P) & 0/15(group D). Analgesic requirement post-operatively was significantly higher in group P ( $p < 0.05$ ). **Conclusion:** Dexmedetomidine is a safe and effective adjunct to propofol.

**Keywords:** Dexmedetomidine, deep sedation, analgesia, propofol, outpatient, pediatric dentistry

## INTRODUCTION

A significant proportion of children worldwide have dental caries, much of it untreated, and often leading to sepsis and pain.<sup>1</sup> The rehabilitation of grossly decayed primary incisors seen in ECC is a challenge due to behavior management of these young children especially when they are in the pre-cooperative stage which often require pharmacological approach.<sup>2</sup> Although various sedative agents either individually or in combinations have been used in dentistry, the ideal agent and its dosage remain to be established. Respiratory events make up a large proportion (5.5%) of complications of the sedation in children<sup>3</sup>. Propofol, a commonly used sedative in dental outpatient due to fast onset and rapid recovery, may depress ventilation, suppress pharyngeal and laryngeal reflexes and cause transient apnoea and desaturation.<sup>4,5</sup>

Dexmedetomidine (Dex) is a potent, highly selective  $\alpha_2$  adreno-receptor agonist.<sup>6</sup> It produces dose-dependent sedation, anxiolysis, and analgesia without respiratory depression.<sup>7,8</sup> Hall et al. and Ustun *et al* showed that sedation with dexmedetomidine preserves the respiratory rate and oxygen concentration during operation and recovery.<sup>9,10</sup> In the pediatric population, dexmedetomidine has been reported effective in various clinical scenarios, including the provision of sedation during mechanical ventilation, prevention of emergence delirium after general anaesthesia, procedural sedation during

\*Ferah Rehman, Research Associate, Department of Pedodontics and Preventive Dentistry, Maulana Azad Institute of Dental Sciences, New Delhi, India.

\*\*Ashima Goyal, Senior Professor, Unit of Pedodontics and Preventive Dentistry, PGIMER, Chandigarh, India.

\*\*\*Krishan Gauba, Professor and Head, Unit of Pedodontics and Preventive Dentistry, PGIMER, Chandigarh, India.

\*\*\*\*Kajal Jain, Professor, Department of Anaesthesia and Intensive Care Medicine, PGIMER, Chandigarh, India.

\*\*\*\*\*Aditi Kapur, Professor, Unit of Pedodontics and Preventive Dentistry, PGIMER, Chandigarh, India.

### Corresponding author:

Ferah Rehman, Department of pedodontics and preventive dentistry, Maulana Azad Institute of Dental Sciences, New Delhi, India  
Mobile: +09876667784, +8588941431  
E-mail : drferahrehman@gmail.com

non-invasive radiologic procedures, including magnetic resonance imaging, and in the control of withdrawal after the prolonged use of opioids and benzodiazepines. Takayuki Kunisawa<sup>11</sup> in his review article concluded that, dexmedetomidine can be expected to serve as an adding agent and/or alternative for dose reduction of traditional agents to minimize the respiratory effects. Hence this study was conducted with an aim to compare propofol alone with a combination of dexmedetomidine and propofol while performing endodontic treatment in anxious and uncooperative pediatric dental patients.

Our primary outcome was to compare the requirement of propofol in the two groups. Secondary outcomes were to compare vital signs such as heart rate, non-invasive blood pressure (NIBP), respiratory rate, SpO<sub>2</sub>; depth of sedation, induction, treatment & recovery time, intra-operative and post-operative complications and analgesic requirement post-operatively.

## MATERIALS AND METHOD

This randomised, parallel designed study was conducted in Pediatric dentistry unit of a tertiary care teaching hospital (PGIMER, Chandigarh, India) after obtaining approval from the ethical committee of the Institution (reference no. NK/303/MDS/8744-45). Written consent was obtained from the parents after explaining them the purpose & nature of the study and the possible risks & benefits. A total of 30 children in the age range of 2-5years, requiring endodontic treatment in a pair of primary maxillary incisors and showing anxiety and fear towards dental treatment (score 4 or 5 of Venham's Anxiety Rating Scale -1977) were selected from the children reporting to the Unit of Pediatric dentistry. Children belonging to physical status ASA I and requiring sedation for the first time were included. Children with known history of allergy to the drugs to be used in the present study, impaired renal and hepatic functions, known cardiovascular or respiratory disease and other medically compromised conditions were excluded from the study. Pre-anaesthetic clearance was sought and children were scheduled for endodontic treatment under sedation, written nil per oral (NPO) guidelines were given to the parents. The selected children were allocated to one of the two groups using block randomization method using opaque sealed envelopes pre prepared by one of the authors i.e. Group P- Propofol alone or Group D-Dex+Propofol. The drugs were prepared by the anaesthetist not involved further in the study. The outcome assessor as well as the participants of the present study were blinded to the drugs being given. Baseline recording of vitals i.e. heart rate, respiratory rate and peripheral oxygen saturation was done before Oral midazolam (Mezolam, Themis Medicare Ltd., Uttarakhand, India) was given in the dose of 0.5mg/kg body weight as premedication. After 20 minutes, IV cannulation was done and anaesthetic agent was administered according to the group allocated to the child. The dosage of different drugs administered were:

**Group P (n=15):** Children in this group received normal saline at the rate of 2ml/kg/hr over 10 minutes as placebo, followed by 1mg/kg propofol (Diprivan 1%w/v, Astrazenca Ltd., Banglore, India) as bolus dose and 50-75ug/kg/min as infusion. Normal saline, transparent in colour was administered in Group A in order to ensure blinding since Dex, an additional drug was given in Group B.

**Group D (n=15):** Children in this group received 1ug/kg dexmedetomidine (Dextomid, Neon Ltd. Mumbai; 100ug/ml) over 10 minutes as loading dose, followed by 1mg/kg propofol as bolus and 50-75ug/kg/min as infusion.

The infusion of drugs was titrated to achieve a Houpt's sedation rating score of  $\geq 4$  for overall behavior. Below this scoring the sedation level was termed as inadequate and additional propofol bolus (1mg/kg) was given and a note was made.

Once the desired sedation scores were achieved induction time was noted and the child was positioned for the clinical procedure. To ensure adequate mouth opening, rubber bite block was used for each child. Local anesthesia with 2% lignocaine hydrochloride in 1:80,000 dilution of adrenaline was administered using 26 G needle and the site of injection was anesthetized using topical application of lignocaine jelly prior to infiltration. The decayed portion of the maxillary incisors being treated was removed using a no.4 round bur mounted in a high speed contra-angle hand piece. Direct visualization and access to root canal was evident with slight preparation. Root canals were irrigated with normal saline. Canals were debrided and enlarged using H files and K files from #20 to #35, with simultaneous irrigation with normal saline and recapitulation. Once there was no evidence of intracanal bleeding which ensured complete removal of pulp, thorough irrigation with the placement of high volume suction close to the site was done followed by drying of canals using autoclaved cotton wrapped over #20 reamer. Obturation was then done using calcium hydroxide (Apexcal) which was condensed using #25 lentulospiral of 21 mm length followed by access cavity sealing with restorative Type II GIC.

The following parameters were recorded on a proforma during the clinical procedure: 1. Sedation scores using Houpt's Sedation Rating Scale (1986) at various endodontic procedural steps viz. Local anaesthetic administration, Rubber Bite block placement, Caries removal and Access cavity preparation, Pulp extirpation and debridement of canals, Obturation and restoration, Removal of Rubber Bite block, Exit from operator. 2. Number of additional boluses of propofol as well as total drug required to achieve the desired sedation in the two groups. 3. Any untoward complications like bradycardia, hypotension, vomiting, desaturation and their management. 4. Vitals i.e. heart rate, respiratory rate, NIBP and oxygen saturation (every 5minutes).

Once the clinical procedure was complete, propofol infusion was discontinued and treatment time was recorded. The child was shifted to the recovery room (equipped with vital sign monitor, oxygen etc.) where he/she was kept under close monitoring till he/she met Aldrette discharge criteria (1998). Once the child met the discharge criteria recovery time was noted, parents were given instructions regarding what to feed, noting and reporting of any unusual behaviour by the child at home and any complaint of pain by the child. In order to assess the requirement of an analgesic during 24-48 hours post discharge, a specific analgesic (Syrup Ibugesic-5mg/kg/dose) was prescribed for the child and parents were asked to maintain a record of number of times they had given the analgesic to their child and this record was collected from the parents at 48 hours post-discharge recall visit.

## Statistical analysis

Normality of data was tested using Kolmogorov -Smirnov test. As per the test results, data for variables like Heart rate, Blood pressure, Respiratory rate, oxygen saturation followed a normal distribution. So, for these variables, paired t-test was used for inter group comparison. For quantitative data following non-normal distribution i.e. Houpt's scores, induction time, procedure time,

recovery time and total propofol dose, Mann-Whitney U test was applied. For qualitative variables i.e. Venham's anxiety scores, Frankl behaviour ratings, venepuncture scores, requirement of additional boluses etc, Chi-square test was used for inter-group comparison. For intra-group comparison to evaluate change variables during treatment progression i.e. Heart rate, Blood pressure, Respiratory rate, oxygen saturation and Houpt's sedation scores, repeated measures of ANOVA were used. Significance level was taken at  $p \leq 0.05$ .

**RESULTS**

A total of 515 children in the age range of 2-5years reported to the Unit of Pedodontics and Preventive Dentistry for various treatment needs during January 2013 to October 2013. One hundred and forty four children required pharmacologic approach to fulfil their treatment needs due to highly uncooperative behaviour. Most of these children were in pre-cooperative stage and suffered from various grades of severity of ECC. Forty six children were assessed for eligibility and sent for PAC where thorough physical evaluation lead to exclusion of eight children due to ASA status II/III. Thirty eight children were then randomized and allocated to the two study groups. However, only fifteen children in each group could receive the allocated intervention because of several reasons like active URTI on the day of intervention, parent's did not report on the scheduled appointment, parents not given written consent, non-compliance regarding NPO instructions. CONSORT flow diagram and checklist are uploaded as an accompanying files.

**Demographics**

Patients were comparable in both the groups with respect to age, weight, gender and pre-operative anxiety and behaviour (Table-1). Data are presented as mean±SD or number of patients.

**Table 1: Showing the demographic data and behavior profile**

	Group P (N=15)	Group D (N=15)	p-value
Age (years)	2.73±0.623	2.57±0.538	0.440
Weight (kg)	12.93±1.75	12.00±2.0	0.185
Gender (M/F)	13/2	12/3	0.624
Pre-operative Venham's anxiety score	4.13±0.834	4.20±0.414	0.784
Pre-operative Frankl behaviour rating	1.40±0.632	1.13±0.352	0.168

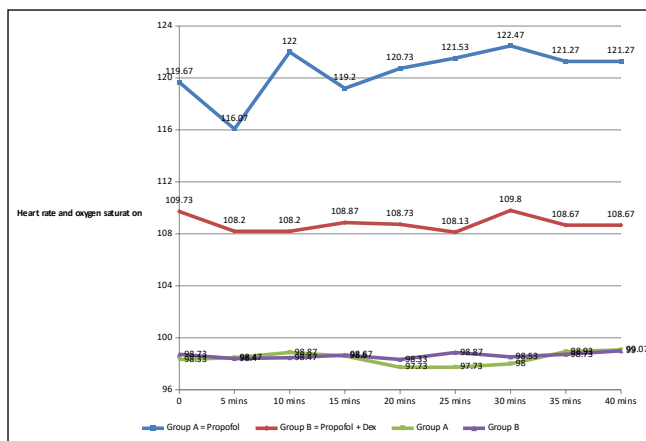
Induction time (mins) was significantly lower in Group P as compared to group D, values being 9.20±3.21 and 23.67±6.67 respectively ( $p < 0.05$ ), however procedure and recovery time were comparable ( $p > 0.05$ ). Although within normal limits, heart rate was found to be significantly lower in group D at all time intervals of recording after 20mins (figure 1). No incidence of bradycardia was observed in any group. Respiratory rate (figure 2), oxygen saturation (figure:1), NIBP (figure 3) were comparable in both the groups. No significant variability was found in any parameter from baseline. Desaturation was observed in 3 patients in group P as compared to none in group D. Total dose of propofol (in mgs) used and number of additional boluses required was significantly higher in group P (table:2). In addition, requirement of analgesic post-operatively was

significantly higher in group P (table:2). Depth of sedation achieved was comparable in both the groups at all the steps of recording starting from baseline to exit from operatory ( $p > 0.05$ ) (figure 4)

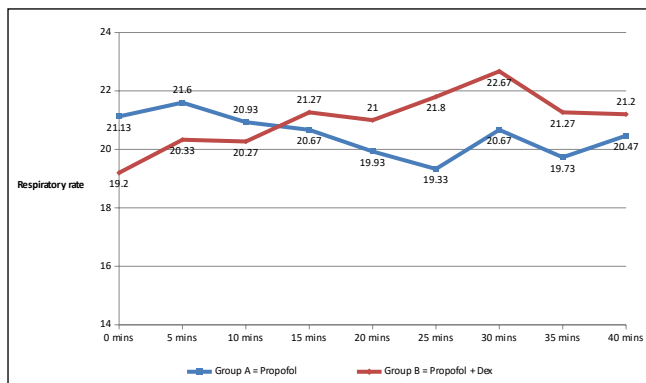
**Table 2: Showing the propofol and analgesic requirement in the two groups**

Parameters	Group P (mean±SD)	Group D (mean±SD)	p-value
Total propofol (in mgs)	54.53±28.90	37.07±12.14	<b>0.040*</b>
No.of additional boluses	2.33±1.54	0.80±0.5	<b>0.004*</b>
Post-op analgesic consumption (in mls)	4.33±3.0	1.00±0.5	<b>0.043*</b>

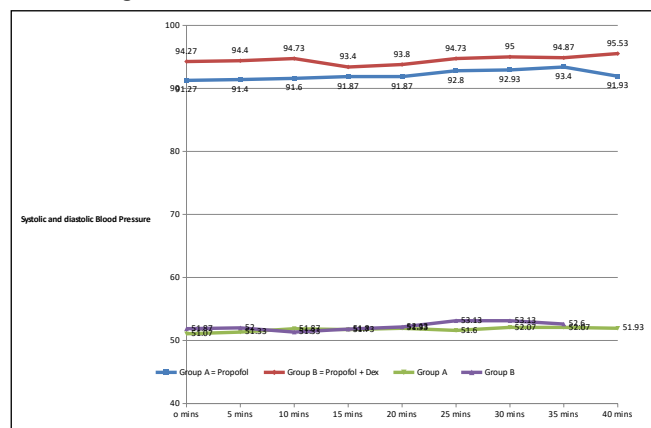
**Figure 1: Comparison of heart rates and oxygen saturation of children during treatment in the two sedation regimens.**



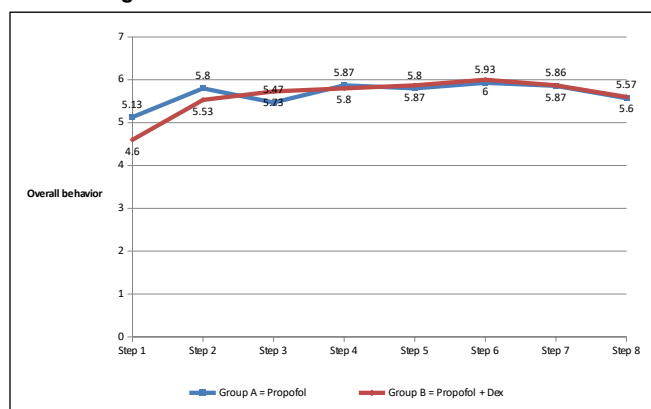
**Figure 2: Comparison of respiratory rates of children during treatment in the two sedation regimens.**



**Figure 3: Comparison of systolic and diastolic blood pressure of children during treatment in the two sedation regimens.**



**Figure 4: comparison of overall behavior according to Houpt's sedation rating during treatment in the two sedation regimens.**



**DISCUSSION**

In the present study, the children in the two study groups were well matched with respect to age, weight and sex. Pre-operative anxiety scores as well as behavior rating scores in the two groups were similar. Induction time was found to be statistically significantly different in the two groups, values being  $9.20 \pm 3.212$  and  $23.67 \pm 6.673$  respectively ( $p=0.000$ ). However, no significant differences were noted with respect to clinical procedure time and recovery time. In a study by Koroglu A *et al* (2006)<sup>12</sup> the onset of sedation for propofol group was reported to be significantly shorter in comparison to dexmedetomidine given to 2-7year old children undergoing magnetic resonance imaging.

Short recovery time as seen for propofol in the present study, although not significant statistically, has also been reported by F. Uzu *et al* (2008)<sup>13</sup>, Christopher Heard *et al* (2008)<sup>14</sup>, Mohamed Mahmoud *et al* (2009)<sup>15</sup>, Koruk *et al* (2010)<sup>16</sup> in medical scenario.

No case of bradycardia or tachycardia was observed in either of the two groups. Similar findings of statistically lower heart rate has been reported in medical setup when dex has been compared to propofol in adult cases by Venn and Grounds (2001)<sup>17</sup>, Samia *et al* (2004)<sup>18</sup>, Tsai *et al* (2010)<sup>19</sup>, Yokota *et al* (2010)<sup>20</sup>, Kang *et al* (2012)<sup>21</sup>.

Studies by Koroglu A *et al* (2006)<sup>13</sup>, Mason *et al* (2006)<sup>22</sup>, Heard *et al* (2008)<sup>15</sup>, Koruk *et al* (2010)<sup>17</sup>, where dexmedetomidine was used for sedating children for procedures like MRI, CT and other procedural sedation also found dexmedetomidine to significantly

lower the heart rate but it was found to be within the normal range for that age and did not required any intervention.

Studies evaluating blood pressure response to dexmedetomidine administered as a single bolus dose in children as in the present study have yielded conflicting results.

In a study of 36 children aged 5-12years undergoing urologic, lower abdominal or pelvic surgery, when dexmedetomidine was administered as a single dose (0.33, 0.66 or 1  $\mu\text{g}/\text{kg}$  over 10 min) systolic blood pressure (SBP) decreased by  $\leq 25\%$  compared to baseline in the first hour following, this decrease was found to be negatively correlated with dose ( $p < 0.028$ ) and time ( $p < 0.029$ ). Diastolic blood pressure also decreased with time ( $p = 0.02$ )<sup>23</sup>.

Similarly a RCT of dexmedetomidine (0.5  $\mu\text{g}/\text{kg}$  over 5 min) administered to 30 children following tonsillectomy and adenoidectomy reported a slightly lower blood pressure compared to control group ( $p < 0.05$ )<sup>24</sup>.

Contrary to these findings several randomized, controlled trials using<sup>25,26,27</sup> dexmedetomidine bolus dose (maximum 1  $\mu\text{g}/\text{kg}$  over 2 min) administered to children showed no significant effect on blood pressure and none of the studies reported clinically significant hypotension.

In the present study, statistically no significant difference was found in respiratory rate between the two groups, and it was well within the normal limits (20-30 breaths/min). Dexmedetomidine does not appear to contribute to laryngospasm or bronchospasm<sup>28,29</sup>. The  $\alpha 2$  agonists, by virtue of their very specific CNS activity have the unique property of producing sedation without the liability of central respiratory depression. In the present study oxygen saturation was found to be comparable between the two groups, well within the normal limits. However, 3/15 patients suffered desaturation episode ( $\text{SPO}_2 < 92\%$ ) in group P as compared to none in group D. The episode did not last for more than a few seconds and could be managed by chin lift/jaw thrust manoeuvre with supplemental oxygen administration using bag and mask ventilation. Among these three patients, treatment could be completed in 2 patients after their saturation reached 99%. One of these children, showed a second episode of desaturation and it was managed by stopping the propofol infusion and therefore treatment could not be completed. Propofol may depress ventilation, suppress pharyngeal and laryngeal reflexes, and cause transient apnoea and desaturation<sup>30, 31</sup>. In the present study, none of the patient in group B showed respiratory complications, this could be attributed to slow infusion of loading dose of dexmedetomidine over an extended period of 10 minutes which could be the reason of associated minimal respiratory complications.

In the present study, level of sedation depth was found to be almost similar in the two groups as shown in figure:4. Venn and Grounds (2001)<sup>18</sup> compared dexmedetomidine with propofol in 20 patients, aged 60-74 years, requiring sedation in intensive care unit and found level of sedation to be similar in both the groups, although in this study the age group evaluated was older compared to that in the present investigation. In the present study, total dose of propofol (in mgs) used was found to be significantly higher in group P as compared to group D. This could be attributed to dose sparing effect of dexmedetomidine which was used as an adjunct to propofol in group D. Lesser number of patients required additional rescue boluses of propofol in group D as compared to group P, also the number of boluses significantly reduced when dexmedetomidine was used. This finding of the present investigation has been

corroborated by similar finding reported by other authors also.<sup>32,33,34</sup> In the present study, the analgesic requirement post-operatively as reported based upon the data collected in subsequent follow up was found to be significantly less in group D as compared to group P (p=0.043). This again could be attributed to the addition of dexmedetomidine in group B which has prolonged analgesic action apart from having sedative, anxiolytic and amnesic effects. In dentistry, Cheung *et al* (2011)<sup>35</sup> reported dexmedetomidine to possess analgesic effect when administered locally after bilateral third molar surgery in their study on ninety nine patients, aged 22-45years requiring bilateral third molar extraction.

**CONCLUSION**

The conclusions that can be drawn from the present study include:

The depth of sedation achieved was comparable, hemodynamics and respiratory profile showed comparable stability in both the sedation regimen. The consumption of propofol was less in Dexmedetomidine +Propofol group as compared to propofol alone and this could be attributed to the dose sparing effect of dexmedetomidine. Analgesic required was less in Dexmedetomidine +Propofol group as compared to propofol alone. No intra and post-operative complications were observed in Dexmedetomidine +Propofol group as compared to propofol alone where three patients suffered desaturation intra-operatively. The time taken for induction and total treatment was longer in Dexmedetomidine +Propofol group, though the recovery time was comparable.

1. Ethical approval sought from the institutional ethics committee, relevant document attached as accompanying file.
2. Source of funding: nil
3. Any conflict of interest: none

**REFERENCES**

- 1 Jason Leitch and Avril Macpherson Current state of sedation/analgesia care in dentistry. *Curr Opin Anaesthesiol* 2007;20:384–387.
- 2 M. O. Folayan, A. Faponle & A. Lamikanra. A review of the pharmacological approach to the management of dental anxiety in children. *International Journal of Paediatric Dentistry* 2002;12:347–354.
- 3 Malviya S, Voepel LT, Eldevik OP et al. Sedation and general anaesthesia in children undergoing MRI and CT: adverse events and outcomes. *Br J Anaesth* 2000; 84: 743–8.
- 4 Tramer MR, Moore RA, McQuay HJ. Propofol and bradycardia: causation, frequency and severity. *Br J Anaesth* 1997; 78: 642–51
- 5 Aun CS. New i.v. agents for paediatric patients. *Br J Anaesth* 1999; 83: 29–41.
- 6 Bhana N, Goa KL, McClellan KJ. Dexmedetomidine. *Drugs* 2000;59:263–70.
- 7 Khan ZP, Ferguson CN, Jones RM. Alpha-2 and imidazoline receptor agonists. Their pharmacology and therapeutic role. *Anaesthesia* 1999;54:146–65.
- 8 Bekker A, Sturaitis MK. Dexmedetomidine for neurological surgery. *Neurosurgery* 2005;57(1 Suppl.):110.
- 9 Hall JE, Uhrich TD, Barney JA, Arain SR, Ebert TJ. Sedative, amnesic, and analgesic properties of small-dose dexmedetomidine infusions. *Anesth Analg* 2000;90:699–705.
- 10 UstunY, GunduzM, Erdogan O, BenlidayiME. Dexmedetomidine versus midazolam in outpatient third molar surgery. *J Oral Maxillofac Surg* 2006;64:1353–8.
- 11 Takayuki Kunisawa. Dexmedetomidine hydrochloride as a long-term Sedative. Review. *Therapeutics and Clinical Risk Management* 2011;7 291–299.
- 12 Koroglu A, Teksan H, Sagir O, et al. A comparison of the sedative, hemodynamic, and respiratory effects of dexmedetomidine and propofol in children undergoing magnetic resonance imaging. *Anesth Analg* 2006;103:63-67.

- 13 Uzümcügil F, Canbay O, Celebi N, Karagoz AH, Ozgen S. Comparison of dexmedetomidine-propofol vs. fentanyl-propofol for laryngeal mask insertion. *Eur J Anaesthesiol*. 2008;25(8):675-80.
- 14 Heard C, Burrows F, Johnson K, et al. A comparison of dexmedetomidine-midazolam with propofol for maintenance of anesthesia in children undergoing magnetic resonance imaging. *Anesth Analg* 2008;107:1832-1839.
- 15 Mahmoud M, Gunter J, Donnelly LF, et al. A comparison of dexmedetomidine with propofol for magnetic resonance imaging sleep studies in children. *Anesth Analg* 2009;109:745-753.
- 16 Koruk S, Mizrak A, Kaya Ugur B, Ilhan O, Baspinar O, Oner U. Propofol/dexmedetomidine and propofol/ketamine combinations for anesthesia in pediatric patients undergoing transcatheter atrial septal defect closure: a prospective randomized study. *Clin Ther*. 2010;32(4):701-9.
- 17 Venn RM, Grounds RM. Comparison between dexmedetomidine and propofol for sedation in the intensive care unit: patient and clinician perceptions. *Br J Anaesth*. 2001;87 (5):684-90.
- 18 Samia Elbaradie, Faten H. EL Mahalawy and Amira H. Solyman. Dexmedetomidine vs. Propofol for Short-Term Sedation of Postoperative Mechanically Ventilated Patients. *Journal of the Egyptian Nat. Cancer Inst*. 2004;16(3): 153-158.
- 19 Tsai CJ, Chu KS, Chen TI, Lu DV, Wang HM, Lu IC. A comparison of the effectiveness of dexmedetomidine versus propofol target-controlled infusion for sedation during fiberoptic nasotracheal intubation. *Anaesthesia*. 2010;65(3):254-9.
- 20 Yokota H, Yokoyama K, Noguchi H, Nishioka T, Umegaki O, Komatsu H, Sakaki T. Post-operative dexmedetomidine-based sedation after uneventful intracranial surgery for unruptured cerebral aneurysm: comparison with propofol-based sedation. *Neurocrit Care*. 2011;14(2):182-7.
- 21 Woon-Seok Kang, Sung-Yun Kim et al. The effect of dexmedetomidine on the adjuvant propofol requirement and intraoperative hemodynamics during remifentanyl-based anesthesia. *Korean J Anesthesiol* 2012; 62(2): 113-118.
- 22 Mason KP, Zgleszewski SE, Dearden JL, et al. Dexmedetomidine for pediatric sedation for CT imaging studies. *Anesth Analg*. 2006;103:57-62.
- 23 Jalonen J, Hynynen M, Kuitunen A, Heikkilä H, Perttälä J, Salmenperä M, Valtonen M, Aantaa R, Kallio A. Dexmedetomidine as an anesthetic adjunct in coronary artery bypass grafting. *Anesthesiology*. 1997;86:331–45.
- 24 Guler G, Akin A, Tosun Z, et al. Single-dose dexmedetomidine reduces agitation and provides smooth extubation after pediatric adenotonsillectomy. *Pediatr Anesth* 2005;15:762-6.
- 25 Erdil F, Demirbilek S, Begec Z, et al. The effects of dexmedetomidine and fentanyl on emergence characteristics after adenoidectomy in children. *Anaesth Intensive Care* 2009;37:571-6.
- 26 Ibacache ME, Munoz HR, Brandes V, Morales AL. Single-dose dexmedetomidine reduces agitation after sevoflurane anesthesia in children. *Anesth Analg* 2004;98:60-3.
- 27 Isik B, Arslan M, Tunga AD, Kurtipek O. Dexmedetomidine decreases emergence agitation in pediatric patients after sevoflurane anesthesia without surgery. *Pediatr Anesth* 2006;16:748-53.
- 28 Erdil F, Demirbilek S, Begec Z, et al. The effects of dexmedetomidine and fentanyl on emergence characteristics after adenoidectomy in children. *Anaesth Intensive Care* 2009;37:571-6.
- 29 Ibacache ME, Munoz HR, Brandes V, Morales AL. Single-dose dexmedetomidine reduces agitation after sevoflurane anesthesia in children. *Anesth Analg* 2004;98:60-3.
- 30 Tramer MR, Moore RA, McQuay HJ. Propofol and bradycardia: causation, frequency and severity. *Br J Anaesth* 1997; 78: 642–51
- 31 Aun CS. New i.v. agents for paediatric patients. *Br J Anaesth* 1999; 83: 29–41.
- 32 Rajashekhar Siddappa, Jessica Riggins, Shathabish Kariyanna, Paul Calkins and Alexandre T. Rotta. High-dose dexmedetomidine sedation for pediatric MRI. *Pediatric Anesthesia* 2011;21:153–158.
- 33 Takayuki Kunisawa et al. Dexmedetomidine can stabilize hemodynamics and spare anesthetics before cardiopulmonary bypass. *J Anesth* 2011; 25:818–822.
- 34 Woon-Seok Kang, Sung-Yun Kim et al. The effect of dexmedetomidine on the adjuvant propofol requirement and intraoperative hemodynamics during remifentanyl-based anesthesia. *Korean J Anesthesiol* 2012; 62(2): 113-118.
- 35 Cheung CW et al. Evaluation of the analgesic efficacy of local dexmedetomidine application. *Clin J Pain*. 2011;27(5):377-82.