

Craniomaxillofacial Changes Using High-Pull J-Hook Headgear and Mini-Implant Anchorage in Adolescents: A Structural Superimposition Method

Sunock Yun* / Jae Hyun Park**/ Na-Young Chang***/ Hye Young Seo****/ Jae-Hyun Sung*****/
Su-Jeong Hong***** / Jong-Moon Chae*****

Objective: The aim of this study was to compare the craniomaxillofacial changes when using high-pull J-hook headgear (HPJH) and mini-implants (MIs) as maxillary anchorage in adolescents. **Study Design:** 40 female adolescents with dentoalveolar protrusion were divided into 2 groups; the HPJH group (n=20) and the MI group (n=20). Lateral cephalograms taken before treatment (T0) and after anterior tooth retraction (T1) were superimposed on the stable structures and then craniomaxillofacial changes were evaluated. **Results:** The cranial base angle, SNB, and facial angle decreased in the HPJH group but increased in the MI group. ANB decreased more in the MI group than in the HPJH group. Mandibular plane angle increased in the HPJH group but decreased in the MI group. Facial height index increased in the MI group while it showed no change in the HPJH group. Mandibular true rotation occurred clockwise in the HPJH group and counterclockwise in the MI group. Maxillary central incisors were intruded and retracted more in the MI group than in the HPJH group. Maxillary first molars were extruded in the HPJH group and were intruded in the MI group. Maxillary first molars were protracted more in the HPJH group than in the MI group. Mandibular central incisors were retracted more in the HPJH group than the MI group. Mandibular first molars were extruded more in the MI group than in the HPJH group. **Conclusion:** More favorable craniomaxillofacial changes occurred in the MI group than in the HPJH group.

Keywords: Mini-implant, High-pull J-hook headgear, Anchorage, Structural superimposition

* Sunock Yun, DDS, MSD, PhD, Private practice, Beauty Line Dental Clinic, Jinju, Korea.

** Jae Hyun Park, DMD, MSD, MS, PhD, Professor and chair, Postgraduate Orthodontic Program, Arizona School of Dentistry & Oral Health, A.T. Still University, Mesa, Ariz; International Scholar, Graduate School of Dentistry, Kyung Hee University, Seoul, Korea.

*** Na-Young Chang, DDS, MSD, PhD, Associate Professor, Department of Orthodontics, School of Dentistry, University of Wonkwang, Wonkwang Dental Research Institute, Iksan, Korea.

**** Hye Young Seo, PhD, Visiting professor, School of Big Data and Financial Statistics, Wonkwang University College of Natural Sciences, Iksan, Korea.

***** Jae-Hyun Sung, DDS, MSD, PhD, Professor Emeritus, Department of Orthodontics, School of Dentistry, Kyungpook National University, Daegu, Korea.

***** Su-Jeong Hong, DDS, MSD, PhD, Private practice, Prime Hanvitt Dental Clinic, Daejeon, Korea.

***** Jong-Moon Chae, DDS, MSD, PhD, Professor, Department of Orthodontics, School of Dentistry, University of Wonkwang, Wonkwang Dental Research Institute, Iksan, Korea; Visiting Scholar, Postgraduate Orthodontic Program, Arizona School of Dentistry & Oral Health, A.T. Still University, Mesa, Ariz.

Corresponding Author; Jong-Moon Chae, Department of Orthodontics, School of Dentistry, Wonkwang University, Daejeon Dental Hospital, 77 Doosan-ro, Seo-Gu, Daejeon, 35233, Korea
Tel; +82-42-366-1103, Fax; +82-42-366-1115 / E-mail ; jongmoon@wku.ac.kr

INTRODUCTION

Tweed¹ emphasized that facial esthetics are one of the principal purposes of the orthodontic treatment. Merrifield² insisted that both the dental and skeletal vertical factors need to be controlled with a directional force system to impact the favorable mandibular growth vector. Buschang *et al*³ proposed that controlling the vertical position of the dentition could improve the facial profile by a true rotation of the mandible.

Traditionally, high-pull J-hook headgear (HPJH) has been used to enhance horizontal and vertical anchorage with Tweed-Merrifield directional force technology,^{2,4-8} but the therapeutic effect of HPJH required patient cooperation. Ever since Creekmore and Eklund⁹ introduced a surgical vitallium screw, many modalities have been reported using skeletal anchorage to overcome the patient-compliance limitation. Among them, mini-implants (MIs) had some advantages such as ease of placement and removal, low cost, immediate loading, and the potential for placement in alveolar bone areas. The wide application of MI has been reported to treat dentoalveolar protrusion requiring the vertical correction of the dentoalveolar complex.^{4,7,10-13}

Arat *et al*¹⁴ compared the validity of the several superimposition methods.¹⁵⁻¹⁹ They concluded that Steiner's and Ricketts' superimposition methods were not effective because they showed errors in

interpreting changes associated with growth and treatment.¹⁴ Otherwise, Björk²⁰ demonstrated that the facial bone undergoes extensive differential remodeling during the growth period. On the basis of his evidence, Björk and Skieller¹⁷⁻¹⁹ confirmed the existence of stable structures that were not affected by growth.

Melson²¹ confirmed that the cribriform plate, the inner surface of the frontal bone, and the anterior wall of the sella turcica were stable structures after 5 years of age. In the maxilla, Björk and Skieller¹⁸ proposed the anterior contour of the maxillary zygomatic process as a relatively stable bone structure during the growth which was verified by Nielsen.²² Buschang *et al*²³ concluded that natural reference markers should be considered for an accurate superimposition.

Some studies^{4,7,13} compared the treatment effects of headgear versus mini-implants. They concluded there are better treatment effects with MI such as less anchorage loss of the maxillary molars, greater retraction of the maxillary incisors, and better mandibular response than with headgear. However, these studies were performed in adult patients using the best fit superimposition method.

Therefore, the aim of this study was to evaluate and compare the effects of treatment and growth on craniomaxillofacial changes when using HPJH versus MI anchorage in adolescents using the structural superimposition method.

MATERIALS AND METHOD

Sample Size Calculation

A power analysis using G*Power (version 3.1.9.7; Franz Faul, Christian-Albrechts-Universität, Kiel, Germany) was performed to estimate the power of the analysis using a sample size of 40. With a one-tail design, the effect size of 0.9, and the total sample size of 40 produced an estimated α error probability of 0.07 and power (1- β error probability) of 0.90.

Participants and Eligibility Criteria

This study included 40 female adolescents (mean age, 14.3 \pm 1.4 years; range, 12 to 16 years) with dentoalveolar protrusion. All subjects were treated in the same private dental clinic from 2010 to 2019. The inclusion criteria were as follows: ANB greater than 3° (average, 6.2°; range, 3.5° to 8.8°), FMA greater than 23.0° (average, 29.1°; range, 23.0° to 35.4°), no degenerative joint disease, no developmental disorders, and no systemic diseases.

The common feature of all patients was a maxillary dentoalveolar protrusion that required premolar extraction and maximum anchorage. They were divided into 2 groups based on the type of the maxillary anchorage used. MI as an intraoral skeletal anchorage was used in 20 patients and HPJH was used as a traditional extraoral anchorage in 20 patients (Figure 1).

Institutional review board approval was granted by Wonkwang University Daejeon Dental Hospital (number WKD IRB W2007/001-001) in Daejeon, Korea, to conduct this study.

Study Design

Four premolars were extracted and a standard edgewise appliance (0.022 \times 0.028-inch) was used according to the Tweed-Merrifield edgewise system.^{2,12} Leveling was done with 0.017 \times 0.022-inch stainless-steel (SS) wire in the maxilla and 0.018 \times 0.022-inch SS wire in the mandible. During posterior movement of the maxillary canines, the HPJH group was prescribed to wear HPJH mesial to the

maxillary canine for at least 10 hours per day (Figure 2A). In the MI group, two self-drilling titanium MIs (diameter, 1.4 mm; length, 6.0 mm; implant type, Dual-Top Anchor System, Jeil Medical Co, Seoul, Korea) were placed in the buccal alveolar bone between the maxillary second premolars and first molars, bilaterally. The elastic chains were directly extended from the maxillary canines to the MIs (Figure 2B).

After leveling and canine retraction, 0.020 \times 0.025-inch and 0.019 \times 0.025-inch SS arch wires with closing loops were inserted in the maxillary and mandibular arches, respectively, for en-masse retraction of the four incisors. In the HPJH group, two hooks were attached between the maxillary central and lateral incisors and the patients were instructed to wear HPJH on the hooks for at least 10 hours per day (Figure 2C). In the MI group, one additional MI was placed between the maxillary central incisors and connected to the maxillary arch wire by an elastomer (Figure 2D).

Lateral cephalograms (focal size, 0.5 mm; tube voltage, 90 kVp; tube current, 10 mA; exposure time, 0.9 to 1.2 sec) were taken

Figure 1. Lateral cephalograms using high-pull J-hook headgear (HPJH) and mini-implants (MIs): A and B, canine retraction with HPJH and MIs; C and D, anterior tooth retraction with HPJH and MIs.

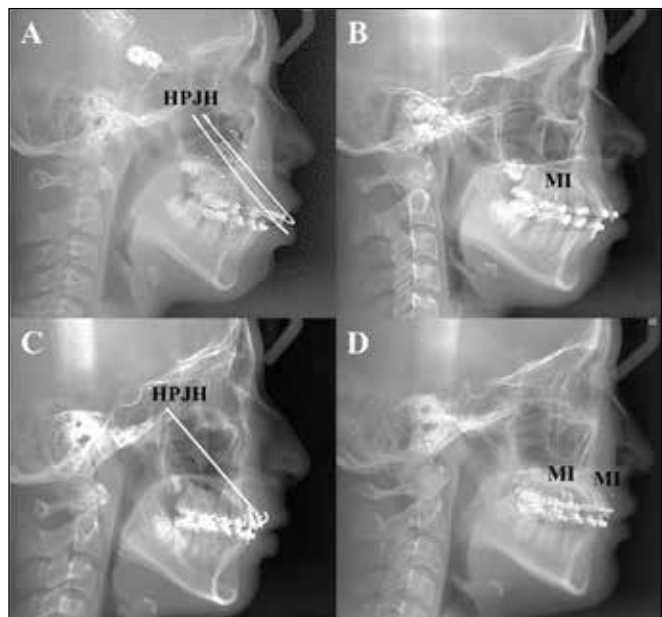
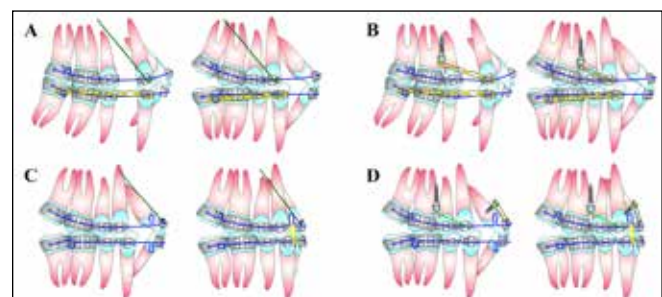


Figure 2. Schematic diagrams of treatment protocol with high-pull J-hook (HPJH) and mini-implants (MIs): A and B, leveling and canine retraction with HPJH and MIs; C and D, en masse anterior tooth retraction with HPJH and MIs.



before treatment (pretreatment, T0) and after the extracted space was closed in the maxillary dentition (after anterior tooth retraction, T1). The image information was saved as a digital imaging and communications in medicine (DICOM) file.

Lateral cephalograms were traced and superimposed using Adobe Photoshop CC (20.0.6 Release) according to the structural superimposition method.²⁴ The stable structures of the anterior cranial base, maxilla, and mandible were traced on the T0 lateral cephalogram (Figure 3A). Each template in which the implant line was closely related to the traced stable structures was prepared; the maxillary implant line (Maxilla^{lmp}) was traced perpendicular to the tangent line at the anterior edge of the zygomatic triangle by 4 cm length and the mandibular implant line (Mandible^{lmp}) was positioned by connecting the center of the symphysis and the mandibular canal by a 6 cm length (Figure 3B).

Templates of the anterior cranial base, the maxilla, and the mandible were projected onto the T1 lateral cephalogram according to the best fit of the stable structures. When positioning the maxillary template onto the T1 lateral cephalogram, the sagittal (horizontal) orientation was established by superimposition on the anterior contour of the zygomatic process, and the vertical orientation was established by maintaining the ratio of 3/5 to 2/5.²⁵ The remaining

parts of the T0 and T1 lateral cephalograms were traced. Lastly, the T0 and T1 lateral cephalograms were superimposed on the template of the anterior cranial base. Also, they were superimposed locally on the Maxilla^{lmp} and the Mandible^{lmp}, respectively (Figure 3C).

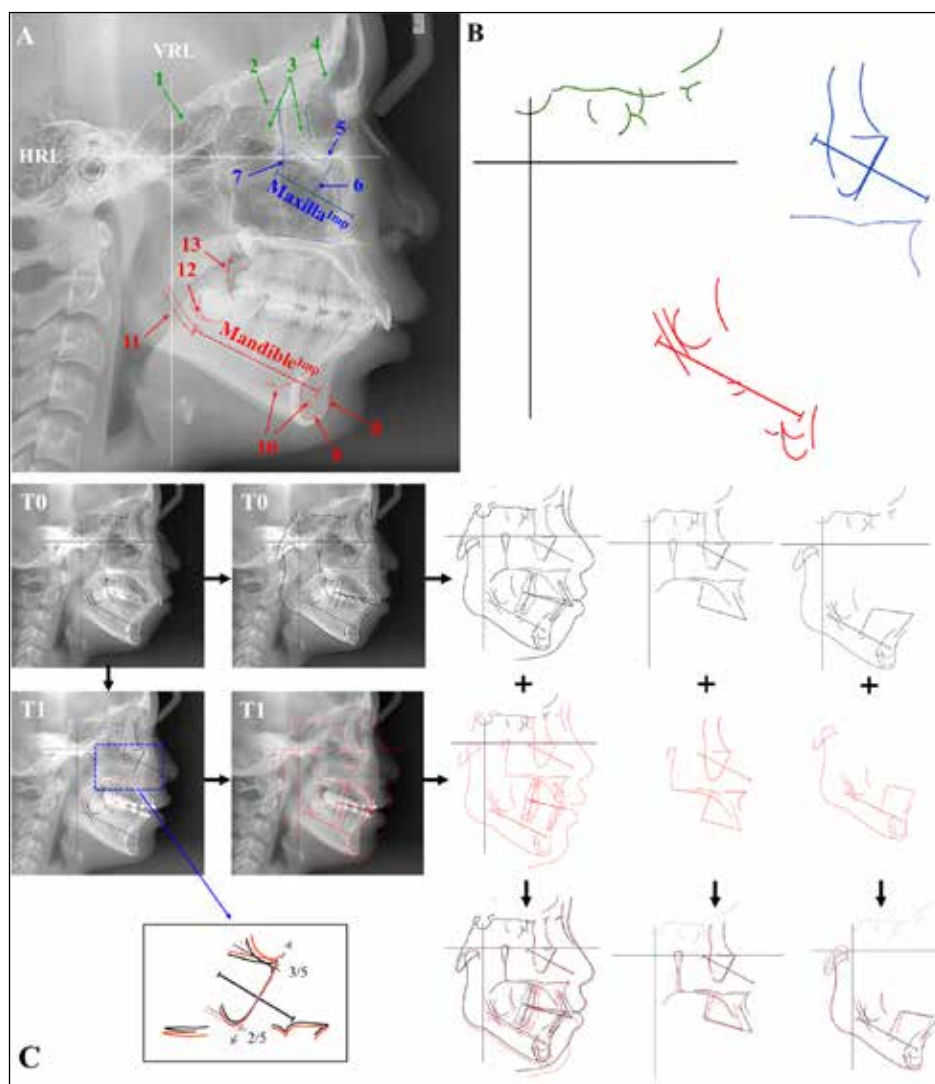
The Frankfort horizontal plane of T0 lateral cephalogram was set as the horizontal reference line (HRL), and a line perpendicular to HRL passing through the sella was set as the vertical reference line (VRL). The HRL and VRL of the T0 lateral cephalogram were projected on the T1 lateral cephalogram for measurement (Figures 4A to 4D). An orthodontic cephalometric analysis program (Orthovision v.2.0.11, Vatech, Korea) was used for the linear and angular measurements. The definitions of the cephalometric landmarks and measurements are described in Tables 1 and 2.

Statistical Analysis

To test the reliability of the measurements, 8 subjects were randomly selected for re-measurement at least two weeks after the initial measurement. The inter-class correlation coefficient (ICC) showed excellent test-retest reliability of the measurements, ICC = 0.812 ~ 0.999.

An independent sample t-test was performed to compare the craniomaxillofacial characteristics of two groups at T0 and craniomaxillofacial changes (T0-T1, Δ) between the HPJH and MI groups.

Figure 3. Structural superimposition method. A. Stable structures, vertical and horizontal references lines (VRL and HRL), and implant lines (Maxilla^{lmp}, and Mandible^{lmp}). Anterior cranial base is indicated in green: 1. anterior wall of the sella turcica, 2. cribriform plate, 3. ethmoidal cell walls, 4. cerebrial surface of the squamous part of the frontal bone. Maxilla is indicated in blue: 5. orbital floor, 6. anterior border of the zygomatic bone including the lower rim of the orbit and the key ridge, 7. the anterior surface of the temporal fossa. Mandible is indicated in red: 8. anterior contour of the symphysis, 2 to 3 mm down from point B to pogonion, 9. endosteal inner contour of the symphysis, 10. any trabecular pattern inside the symphysis or the corpus that is visible in all films, 11. mandibular canal, 12. fundus of the crypt of the third molar, 13. anterior contour of the coronoid process (secondary guideline, this contour was not a reference marker, but it did provide an extra control: With growth, this contour moves in a posterior direction, never forward). B. Template of anterior cranial base, maxilla, and mandible. C. Workflow of tracing and superimpositions.



SPSS software (version 26; IBM, Armonk, NY) was used for statistical analyses and statistical significance was based on a *P*-value of < 0.05.

RESULTS

Pretreatment (T0) craniomaxillofacial characteristics of two groups had no significant differences (Table 3). N-S-Ar, SNB and HRL/N-Pog decreased in the HPJH group but increased in the MI group (*P* < 0.05). ANB decreased more in the MI group than in the HPJH group (*P* < 0.01). HRL/MP increased in the HPJH group but decreased in the MI group (*P* < 0.01). Facial height index increased in the MI group while it showed no change in the HPJH group (*P* < 0.01). Mandibular true rotation occurred clockwise in the HPJH group and counterclockwise in the MI group (*P* < 0.01). Maxillary central incisors (U1s) were intruded (*P* < 0.01) and retracted (*P* < 0.05) more in the MI group than in the HPJH group. Maxillary first molars (U6s) were extruded in the HPJH group and were intruded in the MI group (*P* < 0.001). U6s were protracted more in the HPJH group than in the MI group (*P* < 0.01). Mandibular central incisors

Figure 4. Cephalometric measurements. Structural superimposition on the cranial base (A and B), maxilla (C), and mandible (D) (Table 2).

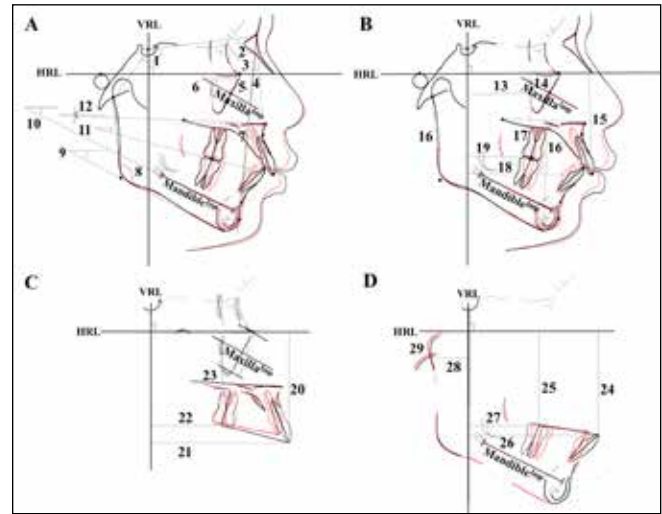


Table 1. Definitions of the cephalometric landmarks and reference lines used in this study

	Abbreviation	Definition
Skeletal landmarks		
Sella	S	Center of sella turcica
Nasion	N	Most anterior point of frontonasal suture in the median plane
Porion	Po	Uppermost point of the external auditory meatus
Orbitale	Or	Lowermost point of the orbit
Articulare	Ar	Point of intersection of the posterior margin of ascending ramus and the outer margin of the cranial base
Anterior nasal spine	ANS	Tip of the bony anterior nasal spine in the median plane
Posterior nasal spine	PNS	Intersection of continuation of anterior wall of pterygopalatine fossa and the floor of the nose
A point	A	Deepest point on the curvature outline of the upper labial alveolar process
B point	B	Deepest point on the bony curvature between the crest of alveolus and pogonion
Pogonion	Pog	Most anterior point of the mandibular symphysis
Menton	Me	Lowest point on the lower border of the mandibular symphysis
Gonion	Go	Constructed point formed by intersection of line tangent to the posterior border of the ramus and line tangent to the inferior border of the body of the mandible
Dental landmarks		
Maxillary central incisor	U1	Tip of the most prominent maxillary central incisor
Mandibular central incisor	L1	Tip of the most prominent mandibular central incisor
Maxillary first molar	U6	Centroid point of mesial and distal cusp of the maxillary first molar
Mandibular first molar	L6	Centroid point of mesial and distal cusp of the mandibular first molar
Maxillary central incisal axis	U1-axis	Long axis of the maxillary central incisor
Reference lines		
Horizontal reference line	HRL	Frankfort horizontal (FH) plane
Vertical reference line	VRL	Perpendicular line to HRL through sella
Maxillary implant line	Maxilla ^{imp}	A line created at right angles to a tangent to the anterior image of the zygomatic triangle with fixed relationship to the natural reference markers (a perpendicular line to the tangent line at the anterior edge of the zygomatic triangle by 4 cm length)
Mandibular implant line	Mandible ^{imp}	A line located beneath the root apices of the mandibular first molar and central incisor with fixed relationship to the natural reference markers (a line connecting the center of symphysis and the mandibular canal by 6 cm length)

Downloaded from http://meridian.allenpress.com/jcpd/article-pdf/45/6/433/3000327/1053-4628-45-6-433.pdf by guest on 18 June 2024

(L1s) were retracted more in the HPJH group than the MI group ($P < 0.05$). Mandibular first molars (L6s) were extruded more in the MI group than in the HPJH group ($P < 0.05$) (Table 4).

Table 2. Definitions of the cephalometric measurements used in this study

Measurement	Definition
Structural superimposition on the cranial base	
1. N-S-Ar (°)	Cranial base angle formed by sella, nasion, and articulare
2. SNA (°)	Angle formed by sella, nasion, and point A
3. SNB (°)	Angle formed by sella, nasion, and point B
4. ANB (°)	Angle formed by point A, nasion, and point B
5. HRL/N-Pog (°)	Angle between FH plane and facial plane connecting nasion and pogonion (facial angle)
6. Maxilla ^{imp} -rot (°)	Angle between Maxilla ^{imp} and HRL
7. U1-axisT (°)	Angle between U1-axis and HRL
8. Ar-Go-Me (°)	Gonial angle formed by articulare, gonion, and menton
9. HRL/MP (°)	Angle between FH plane and mandibular plane connecting menton and gonion (FMA, Frankfort mandibular plane angle)
10. Mandible ^{imp} -rot (°)	Angle between Mandible ^{imp} and HRL
11. HRL/OP (°)	Angle between FH plane and occlusal plane connecting the midpoint of the mesiobuccal cusp tips of the maxillary and mandibular first molars and midpoint of the incisal tips of the maxillary and mandibular central incisors (occlusal plane angle)
12. HRL/PP (°)	Angle between FH plane and palatal plane connecting the anterior nasal spine and posterior nasal spine (palatal plane angle)
13. Maxilla ^{imp} -hor (mm)	Linear distance from the midpoint of Maxilla ^{imp} to VRL
14. Maxilla ^{imp} -ver (mm)	Linear distance from the midpoint of Maxilla ^{imp} to HRL
15. U1-verT (mm)	Linear distance from U1 to HRL
16. FHI (facial height index)	Ratio of PFH (posterior facial height, articulare-gonion) to AFH (anterior facial height, perpendicular distance from the palatal plane to the menton)
17. U6-verT (mm)	Linear distance from U6 to HRL
18. U1-horT (mm)	Linear distance from U1 to VRL
19. U6-horT (mm)	Linear distance from U6 to VRL
Structural superimposition on the maxilla (Maxilla^{imp})	
20. U1-ver(mm)	Linear distance from U1 to HRL
21. U1-hor(mm)	Linear distance from U1 to VRL
22. U6-ver(mm)	Linear distance from U6 to HRL
23. U6-hor(mm)	Linear distance from U6 to VRL
Structural superimposition on the mandible (Mandible^{imp})	
24. L1-ver(mm)	Linear distance from L1 to HRL
25. L6-ver(mm)	Linear distance from L6 to HRL
26. L1-hor(mm)	Linear distance from L1 to VRL
27. L6-hor(mm)	Linear distance from L6 to VRL
28. Ar-hor(mm)	Linear distance from Ar to VRL
29. Ar-ver(mm)	Linear distance from Ar to HRL

DISCUSSION

In growing patients with dentoalveolar protrusion, the key to successful growth modification is to control the vertical dimension, which can induce a counterclockwise mandibular rotation, leading to facial improvement.^{5,6,26} When the skeletal pattern of the subjects in the present study was compared to that of 14.3-year-old Korean females with normal occlusions and good facial profiles,²⁷ the common feature of the subjects was a mandibular retrognathism with an increased mandibular plane which made it important to consider the vertical control with a reinforcement of the horizontal anchorage in the maxilla during treatment.

In this study, we tried to determine the amount of displacement and rotation of the maxilla in terms of the orthopedic effects by measuring the changes in the Maxilla^{imp} to HRL and VRL in structural superimposition on the anterior cranial base. As a result, HPJH group showed less of a restrictive effect of the downward and forward displacement of the maxilla than in the MI group. And in both groups, the horizontal and vertical displacement of the maxilla was within -0.39 mm ~ 0.20 mm, and the changes in maxillary true rotation was around -0.12° ~ -0.06°. These small changes might have been due to the limited amount of sutural growth during the treatment period of 20 months in the late growing patients and therefore a lesser effect on the total maxillary dimension.

In our study, U6s in the HPJH group showed a greater mesial movement than in the MI group. It demonstrated a greater horizontal anchorage loss in the HPJH group which was consistent with the previous studies conducted in adults.^{4,13} U6s were intruded in the MI group while U6s were extruded in the HPJH group, which were different results from a previous study⁷ that showed extrusion of U6s in both groups. This might be due to the use of a different method of superimposition or age range of the patients. Considering that the average eruption of U6s relative to the palatal plane was about 0.5 to 0.9 mm per year in the normal control group,²⁷ a slight intrusion of U6s in the MI group could be considered to be clinically meaningful.

In harmony with the present study, Deguchi et al⁷ reported that the miniscrew anchorage in the anterior alveolar bone more effectively intruded U1s in the MI group than in the HPJH group in adults. On the other hand, U1s were retracted more in the MI group than in the HPJH group in this study which was consistent with the previous studies.^{4,13} The maxillary incisal inclination to HRL (U1-axisT) decreased by 5.96° or 6.42° with no difference between the groups. This result was similar to some previous studies^{4,7} but was contrary to another study.¹³ It might be because the changes during treatment might be different depending on the initial inclination, and the amount of intrusion and torque control capacity using the edgewise appliance.

Since the lower border of the mandibular body remodels during growth,²⁰ it should be considered when evaluating the changes of the mandibular tooth position and the condylar growth. So, in our study, the vertical and horizontal changes of the mandibular dentition and condyle in the sagittal plane were measured from HVL and VRL in the local superimposition on the stable bony landmarks of the mandible (Mandible^{imp}). When comparing the vertical changes in the mandibular dentition, the mandibular incisors and first molars extruded more in the MI group than in the HPJH group. These differences between the two groups might be influenced by compensatory extrusion of the mandibular dentition following the intrusion of the maxillary dentition.²⁸⁻³⁰

Table 3. Comparison of pretreatment (T0) craniomaxillofacial characteristics between high pull J-hook headgear (HPJH) and mini-implant (MI) groups

Variables	Mean	Total (n = 40)		HPJH (n = 20)		MI (n = 20)		P value
		SD	Mean	SD	Mean	SD	Mean	
Cranial base angle	N-S-Ar (°)	124.60	5.01	125.22	4.75	123.97	5.30	0.438
	ANB (°)	6.08	1.45	5.74	1.50	6.42	1.34	0.137
Sagittal dimensions	SNA (°)	81.52	3.52	80.58	3.87	82.45	2.92	0.093
	SNB (°)	75.44	3.03	74.85	3.43	76.04	2.53	0.220(.256†)
	HRL/N-Pog (°)	85.87	2.09	85.85	2.11	85.88	2.13	0.967
	HRL/PP (°)	-0.24	2.39	0.19	2.32	-0.66	2.44	0.269
Vertical dimensions	HRL/OP (°)	10.17	3.19	10.43	3.40	9.91	3.02	0.613
	HRL/MP (°)	29.16	3.35	28.87	3.11	29.45	3.63	0.589
	FHI (ratio)	56.97	1.66	56.52	1.75	57.41	1.47	0.090
Mandibular form	Ar-Go-Me (°)	0.67	0.05	0.68	0.05	0.67	0.05	0.332

HPJH, high pull J-hook headgear; MI, mini-implant.

†: If normality was not satisfied, a nonparametric test (Mann-Whitney U) was performed.

Table 4. Comparison of craniomaxillofacial changes (T0-T1) between high-pull J-hook (HPJH) headgear and mini-implant (MI) groups

Variables	Mean	Total (n = 40)		HPJH (n = 20)		MI (n = 20)		P value
		SD	Mean	SD	Mean	SD	Mean	
Structural superimposition on the cranial base								
Cranial base angle	ΔN-S-Ar (°)	0.16	0.76	-0.14	0.75	0.46	0.66	0.011*
	ΔANB (°)	-1.02	0.83	-0.65	0.71	-1.40	0.78	0.003**
Sagittal dimensions	ΔSNA (°)	-0.87	0.85	-0.75	0.92	-0.99	0.78	0.372
	ΔSNB (°)	0.15	0.82	-0.10	0.75	0.41	0.82	0.048*
	ΔHRL/N-Pog (°)	0.26	0.75	-0.01	0.70	0.52	0.73	0.023*
	ΔHRL/PP (°)	0.11	0.74	0.31	0.61	-0.08	0.82	0.090
Vertical dimensions	ΔHRL/OP (°)	-0.03	3.03	0.15	3.55	-0.22	2.47	0.710
	ΔHRL/MP (°)	-0.21	1.18	0.36	1.15	-0.77	0.92	0.001**(.002**†)
	ΔFHI (ratio)	0.01	0.02	0.00	0.02	0.02	0.02	0.006**
Mandibular form	ΔAr-Go-Me (°)	0.13	0.81	0.09	0.74	0.16	0.89	0.782(.935†)
	ΔMaxilla ^{imp-ver} (mm)	0.17	0.37	0.14	0.35	0.20	0.40	0.610
Jaw rotation and displacement	ΔMaxilla ^{imp-hor} (mm)	-0.12	1.69	0.15	0.55	-0.39	2.33	0.324(.829†)
	ΔMaxilla ^{imp-rot} (°)	-0.09	0.92	-0.12	0.92	-0.06	0.94	0.854
	ΔMandible ^{imp-rot} (°)	-0.30	1.25	0.30	1.33	-0.90	0.84	0.002**
	ΔU1-verT (mm)	-1.64	1.65	-0.96	1.41	-2.31	1.63	0.008**
Maxillary dental changes	ΔU1-horT (mm)	-5.75	4.68	-4.47	2.78	-7.04	5.80	0.081(.034*†)
	ΔU1-axisT (°)	-6.19	6.87	-5.96	8.34	-6.42	5.22	0.836
	ΔU6-verT (mm)	0.16	1.28	0.97	0.95	-0.65	1.02	<.001***
	ΔU6-horT (mm)	1.51	3.47	2.87	1.37	0.14	4.34	0.011*

Variables Mean	Total (n = 40)		HPJH (n = 20)		MI (n = 20)		P value	
	SD	Mean	SD	Mean	SD			
Structural superimposition on the maxilla (Maxilla ^{lmp})								
	ΔU1-ver (mm)	-1.87	1.68	-1.13	1.34	-2.60	1.69	0.004**
Maxillary dental changes	ΔU1-hor (mm)	-5.56	2.17	-5.11	2.44	-6.00	1.81	0.201
	ΔU6-ver (mm)	-0.12	1.16	0.63	0.84	-0.86	0.94	<.001***
	ΔU6-hor (mm)	1.88	1.70	2.69	1.64	1.07	1.37	0.002**
Structural superimposition on the mandible (Mandible ^{lmp})								
	ΔL1-ver (mm)	-0.93	1.60	-0.50	1.88	-1.37	1.14	0.087
Mandibular dental changes	ΔL1-hor (mm)	-3.79	2.18	-2.96	2.23	-4.63	1.83	0.013*
	ΔL6-ver (mm)	-0.37	0.65	-0.15	0.63	-0.58	0.62	0.036*
	ΔL6-hor (mm)	2.61	1.40	2.56	1.44	2.67	1.40	0.797(.892†)
Condylar growth	ΔAr-ver (mm)	-1.34	1.47	-1.31	1.65	-1.37	1.30	0.902
	ΔAr-hor (mm)	0.32	0.90	0.41	1.14	0.24	0.61	0.562(.695†)

T0, pretreatment; T1, after anterior tooth retraction. *P < 0.05; **P < 0.01; ***P < 0.001.

†: If normality was not satisfied, a nonparametric test (Mann-Whitney U) was performed.

Buschang *et al*³¹ reported that vertical growth of the condyle was nine times greater than the horizontal condylar growth, which was similar to the results of our study. Considering this fact, when the vertical growth of the condyle is deficient, the mandible will rotate backward.³² The true rotation of the mandible (Mandible^{lmp}-rot) was also compared between the groups in the superimposition on the anterior cranial base in this study. The HPJH group and MI group showed clockwise and counterclockwise rotation of the mandible, respectively, which were similar to the previous studies^{4,13} and could determine the anteroposterior position of the mandible.

This study has a limitation that the comparison was performed only in female patients and without a control group. So further study might be recommended including male patients compared with an untreated control group having similar conditions. In the present study, the second lateral cephalograms (T1) were taken before Class II intermaxillary elastics were used in the completion stage,² and HPJH and MI were applied only to the maxillary dentition, so these effects to the mandibular dentition was excluded. Therefore, a future study might be necessary to compare the treatment outcomes following the vertical control of the mandibular dentition.

CONCLUSION

More favorable craniomaxillofacial changes occurred in the MI group than in the HPJH group. Thus, this information provides an evidence-based rationale for clinical usage of MI instead of the HPJH in adolescents.

ACKNOWLEDGEMENT

This paper was supported by Wonkwang University in 2021.

REFERENCES

1. Tweed CH. Indications for the extraction of teeth in orthodontic procedures. *Am J Orthod Oral Surg.* 1944;30:405-28.
2. Merrifield LL. The systems of directional force. *J Charles H Tweed Int Found.* 1982;10:15-29.
3. Buschang PH, Jacob HB. Mandibular rotation revisited: What makes it so important? *Semin Orthod.* 2014;20:299-315.
4. Park HS, Yoon DY, Park CS, Jeoung SH. Treatment effects and anchorage potential of sliding mechanics with titanium screws compared with the Tweed-Merrifield technique. *Am J Orthod Dentofacial Orthop.* 2008; 133:593-600.
5. Gebeck TR, Merrifield LL. Orthodontic diagnosis and treatment analysis-concepts and values, part I. *Am J Orthod Dentofacial Orthop.* 1995; 107:434-43.
6. Gebeck TR, Merrifield LL. Orthodontic diagnosis and treatment analysis-concepts and values, part II. *Am J Orthod Dentofacial Orthop.* 1995; 107:541-7.
7. Deguchi T, Murakami T, Kuroda S, Yabuuchi T, Kamioka H, Takano T. Comparison of the intrusion effects on the maxillary incisors between implant anchorage and J-hook headgear. *Am J Orthod Dentofacial Orthop.* 2008;133:615-24.
8. Merrifield LL, Cross JJ. Directional forces. *Am J Orthod.* 1970;57:435-64.
9. Creekmore TD, Eklund, MK. The possibility of skeletal anchorage. *J Clin Orthod.* 1983;17:266-9.
10. Kanomi R. Mini-implant for orthodontic anchorage. *J Clin Orthod.* 1997; 31:763-7.
11. Park HS, Kwon TG, Kwon OW. Treatment of open bite with microscrew implant anchorage. *Am J Orthod Dentofacial Orthop.* 2004;126:627-36.
12. Chae JM. A new protocol of Tweed-Merrifield directional force technology with microimplant anchorage. *Am J Orthod Dentofac Orthop.* 2006; 130:100-9.
13. Yao CC, Lai EH, Chang JZ, Chen I, Chen YJ. Comparison of treatment outcomes between skeletal anchorage in adults with maxillary dentoalveolar protrusion. *Am J Orthod Dentofacial Orthop.* 2008;134:615-24.
14. Arat ZM, Rübendüz M, Akgül AA. The displacement of craniofacial reference landmarks during puberty: A comparison of three superimposition methods. *Angle Orthod.* 2003;73:374-80.
15. Ricketts RM. A four-step method to distinguish orthodontic changes from natural growth. *J Clin Orthod.* 1975;9:208-15.
16. Steiner C. Cephalometrics in clinical practice. *Angle Orthod.* 1959;29:8-29.
17. Bjork A, Skieller V. Facial development and tooth eruption: An implant study at the age of puberty. *Am J Orthod.* 1972;62:339-83.

18. Bjork A, Skieller V. Postnatal growth of and development of the maxillary complex. In: McNamara JR JA (ed). *Factors Affecting the Growth of the Midface*, monograph 6, Craniofacial Growth Series. Ann Arbor, MI: University of Michigan, 61-99, 1976.
19. Bjork A, Skieller V. Normal and abnormal growth of the mandible. A synthesis of longitudinal cephalometric implant studies over a period of 25 years. *Eur J Orthod*. 1983;5:1-46.
20. Björk A. Facial growth in man, studied with the aid of metallic implants. *Acta Odontol Scand*. 1955;13:9-34.
21. Melsen B. The cranial base: The postnatal development of the cranial base studied histologically on human autopsy material. *Acta Odontol Scand*. 1974;Suppl 32:1-126.
22. Nielsen IL. Maxillary superimposition: A comparison of three methods for cephalometric evaluation of growth and treatment changes. *Am J Orthod Dentofac Orthop*. 1989;95:422-31.
23. Buschang PH, LaPalme L, Tanguay R, Demirjian A. The technical reliability of superimposition on cranial base and mandibular structures. *Eur J Orthod*. 1986;8:152-6.
24. Duterloo HS, Planché PG. *Handbook of cephalometric superimposition*. 1st Ed.: Quintessence; p. 115-9, 2011.
25. Doppel DM, Damon WM, Joondeph DR, Little RM. An investigation of maxillary superimposition techniques using metallic implants. *Am J Orthod Dentofacial Orthop*. 1994;105:161-8.
26. Yamaguchi K, Nanda RS. The effects of extraction and nonextraction treatment on the mandibular position. *Am J Orthod Dentofacial Orthop*. 1991;100:443-52.
27. Sung JH, Kwan OW, Kyung HM, Park KD. *Longitudinal data of craniofacial growth from lateral cephalometrics in Korean with normal occlusion*. 1st Ed.: Jung Won co. Inc.; 2001.
28. Betzenberger D, Ruf S, Pancherz H. The compensatory mechanism in high-angle malocclusions: a comparison of subjects in the mixed and permanent dentition. *Angle Orthod*. 1999;69:27-32.
29. Kim YE, Nanda RS, Sinha PK. Transition of molar relationships in different skeletal growth patterns. *Am J Orthod Dentofacial Orthop*. 2002;121:280-90.
30. Scheffler NR, Proffit WR, Phillips C. Outcomes and stability in patients with anterior open bite and long anterior face height treated with temporary anchorage devices and a maxillary intrusion splint. *Am J Orthod Dentofacial Orthop*. 2014;146:594-602.
31. Buschang PH, Ary SP. Condylar growth and glenoid fossa displacement during childhood and adolescence. *Am J Orthod Dentofacial Orthop*. 1998;113:437-42.
32. Buschang PH, Jacob HB. Mandibular rotation revisited: What makes it so important? *Semin Orthod*. 2014;20:299-315.