

Overstride-Induced Medial Knee Desmopathy: An Exploration Case Series

Reid Fisher, EdD, ATC, LAT*; Nathaniel S. Nye, MD†; Joanna Soles, DHSc, ATC*; Andy Waldhelm, PhD, PT‡; Ryan Gottfredson, DO, MPH†

*University of the Incarnate Word, San Antonio, TX; †Trainee Health Surveillance, Joint Base San Antonio (JBSA)–Lackland, TX; ‡University of South Alabama, Mobile

Nine runners with varied experience but similar running-gait forms presented with the insidious and progressive onset of medial knee pain. Functional tightness of the semimembranosus (SM) tendon appeared to be a concomitant factor in the pain presentation of these patients. When evaluating atraumatic medial knee pain in runners, clinicians must consider bone stress injuries and atypical conditions. A functionally tight SM may induce pain and desmopathy of the medial collateral

ligament through direct fiber entanglement or cause entrapment of infrapatellar branches of the saphenous nerve or both. Relieving SM tension resulted in short-term pain reduction while eliminating the overstride during the running gait over the long term appeared to prevent recurrence.

Key Words: noncontact knee injury, medial collateral ligament, semimembranosus tendon, running gait

Key Points

- Runners with unique insidious-onset medial knee pain presented with medial collateral ligament tenderness, palpable tightness of the semimembranosus (SM) tendon, and pain at initial contact while running.
- An SM-mediated traction desmopathy of the medial collateral ligament is hypothesized to originate from tibial external rotation that occurs during heel strike in an overstride gait.
- Resolving SM tightness relieved symptoms in 89% of patients; the addition of gait retraining prevented recurrence of symptoms in all patients.

Patients who present with acute medial knee pain after sudden trauma, such as falling or twisting, must be evaluated for acute injuries including medial collateral ligament (MCL) sprain, medial meniscal tear, and hamstrings strain or rupture. However, when no known mechanism of acute injury coincided with the onset of pain, then the evaluation shifts toward overuse and chronic injuries, with a much broader differential diagnosis than many clinicians often appreciate. Conditions that must be considered in insidious-onset medial knee pain include bursitis (pes anserine or MCL bursa), tendinopathy, bone stress injuries (BSIs), degenerative meniscal injuries (intra-substance degradation, tear, parameniscal cyst), nerve entrapment (infrapatellar branches of the saphenous nerve), friction syndromes (posteromedial and medial tibial crest), and bone tumors. Depending on the age of the patient, apophysitis of the medial femoral condyle or medial compartment osteoarthritis may need to be considered as well.

The incidence of BSI in basic military training (BMT) can be as high as 6.9% for males and 21% for females, resulting in approximately \$5 million in annual losses to the US Air Force alone.¹ Due to the relatively high frequency of BSIs diagnosed during BMT, our clinic follows the evidence-based guidelines of Nye et al^{1,2} as a proactive

approach to early diagnosis while limiting unnecessary radiation exposure, lost training time, bone scans, and costs associated with over-ordering magnetic resonance imaging (MRI). Occasionally, patients with the classic clinical signs and symptoms of a BSI of the medial tibial plateau (exertional pain and bony tenderness at the medial aspect of the proximal tibial metaphysis, a very common injury pattern during BMT) have negative results on radiographs and MRI; other diagnostic possibilities should then be addressed. Nogueira-Barbosa and Lacerda³ described a posteromedial friction syndrome; Simeone et al⁴ suggested that, due to its infrequency, BSI should be ruled out first. Similarly, Klontzas et al⁵ identified a medial tibial crest friction syndrome; standard anteroposterior and lateral tibia-fibula radiographs, as routinely obtained for BSI assessment, may be used to verify the angle of the tibial crest and support this infrequent diagnosis. Some investigators^{6,7} described a bursa within the superficial and deep layers of the MCL, which may become symptomatic and be associated with medial knee pain. Other authors⁸ cited saphenous nerve entrapment as a cause of medial knee pain. Despite the lower frequency of incidence, the insidious onset of medial knee pain requires consideration of a variety of unique possibilities.

Table 1. Patient Characteristics

Patient No.	Sex	Age, y	Civilian or Military	Running History	Current Training	Training Change?
1	F	15	Civilian	High school cross-country runner	~30 mi (48 km)/wk	N
2	M	30	Civilian	6 marathons	~35 mi (56 km)/wk	N
3	F	48	Civilian	Inconsistent; training for first half marathon	~20 mi (32 km)/wk	Y
4	M	19	Military	Regular exercise including running	~96 min/wk	Y
5	F	18	Military	Not active before BMT	~96 min/wk	Y
6	F	19	Military	Basketball player, no jogging	~96 min/wk	Y
7	M	20	Military	Not active before BMT	~96 min/wk	Y
8	F	20	Military	Not active before BMT	~96 min/wk	Y
9	F	26	Military	Not active before BMT	~96 min/wk	Y

Abbreviations: BMT, basic military training; F, female; M, male; N, no; Y, yes.

In this paper, we discuss 9 patients with similar presentations who did not fit these currently recognized causes of atraumatic medial knee pain. The lack of evidence supporting a known diagnosis suggests that their condition may not have been previously described. We seek to establish key common features seen in these patients, with the goal of enabling further research into the causes, contributing biomechanics, and optimal rehabilitation strategies for this condition.

PATIENTS

Characteristics

Patients in this case series were evaluated in civilian and military sports medicine clinics. All of the civilian patients were accomplished runners involved in endurance-run training who averaged 20 to 30 mi (32–48 km) per week, whereas the military patients consisted of basic military trainees who were essentially novice runners. Data on the military patients were obtained during a research project funded by the Congressionally Directed Medical Research Program (Protocol No. DM140461) for the University of the Incarnate Word and the US Air Force to assess the effectiveness of athletic trainers embedded within BMT. The US Air Force BMT recruits' weekly mileage varied, as the training was self-paced based on ability, but was likely

in the vicinity of 7 to 12 mi (11–19 km) per week. Overall cardiovascular fitness was the focal point of run training during these sessions. Patient demographics are outlined in Table 1.

Clinical Presentation

All 9 individuals presented with complaints of insidious-onset pain while running. Typically progressing over several days, the pain began to occur with lower degrees of exertion such as walking, ascending and descending stairs, and even sitting. Military patients further identified discomfort during facing movements (pivoting movements to change direction while standing at attention). Patients described a sharp, stabbing sensation at the medial knee joint line during running. At terminal swing, as the knee approached full extension, the moment of initial contact induced a sharp increase in discomfort. None mentioned locking, popping, clicking, or catching in their descriptions of symptoms, reducing the likelihood of meniscal involvement or posteromedial friction syndrome.

Clinician evaluation notes (Table 2) consistently reported a lack of ecchymosis, erythema, or edema. Palpation over the MCL at the joint line and the tibial plateau coinciding with the insertion of the distal semimembranosus (SM) tendon reproduced the pain. Movement and strength

Table 2. Patient Evaluation Findings

Finding	Patient								
	1	2	3	4	5	6	7	8	9
Initial pain (0–10)	6	5	7	8	8	7	7	3	7
Trauma	N	N	N	N	N	N	N	N	N
Ecchymosis, edema, erythema	N	N	N	N	N	N	N	N	N
Overstride running gait	Y	Y	Y	Y	Y	Y	Y	Y	Y
Heel-strike running gait	Y	Y	Y	Y	Y	Y	Y	Y	Y
Pain ↑ during swing phase as knee approached initial contact	Y	Y	Y	Y	Y	Y	Y	Y	Y
Sharp ↑ in pain at initial contact	Y	Y	Y	Y	Y	Y	Y	Y	Y
Valgus stress at 0° and 30°: pain	Y	Y	Y	Y	NA	Y	NA	Y	NA
Valgus stress at 0° and 30°: laxity	N	N	N	N	NA	N	NA	N	NA
Medial hamstrings tightness	Y	Y	Y	Y	Y	Y	Y	Y	Y
Medial hamstrings tender to palpation	N	N	N	N	N	N	N	N	N
+ Apley distraction test (medial collateral ligament pain)									
Tibial external rotation	Y	N	Y	Y	Y	N	Y	N	Y
Tibial internal rotation	N	N	N	N	N	N	N	N	N
+Apley compression test	N	N	N	N	N	N	N	N	N
Evidence of bone stress injury									
Radiographic	NA	NA	NA	Neg	Neg	Neg	NA	NA	Neg
Magnetic resonance imaging	NA	NA	NA	NA	Neg	Neg	NA	NA	NA

Abbreviations: N, no; NA, not applicable; neg, negative; Y, yes.



Figure 1. Targeted stretch of the semimembranosus.

profiles reflected full range of motion and full strength throughout each range except for patient 7, who presented with limited knee flexion on manual muscle testing of 4/5 on the involved side secondary to increased pain. Anterior drawer, McMurray, and patellofemoral apprehension tests were all negative, and the valgus stress tests reproduced the pain but were negative for laxity in all patients. A shared complaint of increased tension and subsequent discomfort along the medial hamstrings muscles during assessment of straight-leg raise hip flexion added SM involvement to the differential diagnosis.

Imaging

The US Air Force BSI evaluation protocol required any patient with lower extremity pain and focal bony tenderness to undergo plain radiographs. Of the 6 BMT patients, 4 met these criteria; all radiographs were negative for signs of BSI. Two patients (patients 5 and 6) had persistent pain 7 to 10 days later, and MRIs were obtained in accordance with the same protocol. Magnetic resonance images were interpreted by 2 radiologists and the sports medicine physician caring for the patients. Patient 5 showed an intact Baker cyst and mild infrapatellar fat pad edema, which may have been associated with patella alta, but neither condition reasonably explained her medial knee pain during running gait, facing movements, or prolonged sitting. The radiologists and chief of radiology noted signaling consistent with fluid tracking along the MCL and reported that a mechanism associated with an acute MCL sprain should be considered. However, the patient had insidious onset of pain. A coronal T1-weighted image of patient 6 showed no sign of BSI or other inflammation at the site of pain. Her final diagnosis from the provider was a proximal medial gastrocnemius strain, which failed to explain the point tenderness and chief complaint of pain along the MCL at the joint line. Neither patient 5 nor 6 had MRI findings consistent with MCL bursitis.⁷

Interventions

Many of our military trainees with insidious-onset pain, especially around the medial tibial plateau, were ultimately

Table 3. Gait-Training Exercise Progression

Core Engagement	
	Pelvic tilts/clocks
	Supine straight-leg raise on ground with hands under back for biofeedback x 2 min
	Straight-leg raise on 1/2 foam roller for balance x 5 min
	4-point stance on exercise ball x 5 min
	2-point stance on exercise ball x 5 min
Run Session 1	
	Jog in place at higher (172–180 steps/min) cadence
	Increase treadmill pace slowly while maintaining cadence
Hip Activation	
	Alternating lunges with visual biofeedback 2 x 15
	Trendelenburg hip hikes 2 x 15
	Glute bridges with elastic band (green)
Run Session 2	
	Jog in place at higher (172–180 steps/min) cadence
	Increase treadmill pace slowly while maintaining cadence
	Focus on hip extension to increase stride length and drive

found to have BSIs. This justifies close adherence to the BSI diagnostic protocol of activity restriction and early imaging. In cases of BSI, activity modification with impact restrictions typically results in symptom resolution while the osseous tissue heals. These guidelines were followed for the patients presented herein. The 2 principal findings that further guided specific treatment in the patients presented here included the palpably tight SM muscle and tendon and identification of an overstride, heel-strike running gait. Medial hamstrings muscle tension was addressed using a hold-relax technique. In a lower extremity, figure-4 stretch position, the involved leg was extended, and the provider instructed the patient to reach toward the instep of the foot with the ipsilateral hand (Figure 1). Patients repeated a 30-second hold, 10-second contraction 5 times and were advised to repeat the activity 3 to 5 times a day. Patients further stretched using a knee-flexion, hold-relax technique to elicit autogenic inhibition.

As part of the rehabilitation protocol in the military sports medicine clinic, providers assess the running gait of all trainees with lower extremity pain and, when appropriate during their rehabilitation, retrain their gait accordingly (Table 3). Because these patients complained of sharp pain while approaching terminal knee extension, gait retraining focused on increasing the cadence as a simple mechanism for increasing knee flexion at initial contact, resulting in a landing closer to the center of mass. The subsequent knee flexion at initial contact avoids the exacerbating knee position. Concurrent strengthening and activation of the hip and lumbopelvic core stabilizers (the gluteus medius muscles in particular) were intensively targeted in the reconditioning program. Symptoms did not return for any patient after gait retraining. Gait retraining was not included in the management of the civilian patients 1 through 3. Short-term management of SM tightness initially resolved symptoms. When contacted over time, these patients reported recurrence of symptoms upon return to running, but the pain was manageable with the stretching approach.

Table 4. Differential Diagnosis Symptoms Comparison

Diagnosis	Insidious Onset?	Sharp or Stabbing?	Aching?	Night or Resting Pain?	Pain With Walking Gait?	Swing Phase Approaching Full Knee Extension?	Popping, Clicking, Locking?	Pain With Valgus Stress?	Medial Hamstrings Tightness?
Bone stress injury	Y ^a	Y ^a	Y ^b	Y ^b	Y ^a	N ^b	N ^a	N ^c	N ^b
Posteromedial friction syndrome	Y ^a	Y ^a	N ^a	N ^a	Y ^a	N ^b	Y ^b	N ^c	N ^b
Tibial crest friction syndrome	Y ^a	Y ^a	N ^a	N ^a	Y ^a	Y ^a	N ^a	N ^c	N ^b
Saphenous nerve entrapment	Y ^a	Y ^a	N ^a	N ^a	? ^c	? ^c	N ^a	? ^c	? ^c
Medial meniscal tear	?	Y ^a	N ^a	N ^a	Y ^a	N ^b	Y ^b	N ^c	N ^b
Common complaints of current pts	Y ^a	Y ^a	N ^a	N ^a	Y ^a	Y ^a	N ^a	Most ^c	Y ^a

Abbreviations: ?, unknown association; N, no; pts, patients; Y, yes.

^a Same as current presentation.

^b Not aligning with current presentation.

^c Inconsistent or unknown connection.

Comparative Outcomes

Diagnosis. Identifying the correct diagnosis remains a necessity to better guide treatment and prevention. The differential diagnosis and common features attributed to each condition and the comparison with our presented patients, are provided in Table 4. Tenderness to palpation of the MCL over the joint line and not distally at the pes anserinus or the inferior angle of the tibial crest reasonably eliminates either pes anserine bursitis or tibial crest friction syndrome, and this is further supported by radiographic and MRI findings. The absence of mechanical symptoms and negative McMurray test reduced the likelihood of a meniscal tear. In patients who had MRI, no evidence of meniscal tear was noted; however, these were screening MRI studies designed to rule out BSI and were not optimized for imaging the menisci. Although some discomfort was reported along the SM tendon, the point of maximal tenderness was along the MCL anterior to the SM tendon, reducing the likelihood of an isolated SM muscle or tendon strain. A lack of tenderness along the posteromedial femur with associated popping, snapping, and clicking as the leg moved into extension deviated from published presentations of posteromedial friction syndrome.^{3,4} None of the patients demonstrated swelling along the anterior edge of the femoral portion of the MCL, which is characteristic of MCL bursitis, as outlined by Corten et al.⁷ The radiologists’ interpretations of the MRIs further excluded the possibility of any significant edema between the superficial and deep layers of the MCL, further supporting the elimination of MCL bursitis from consideration. Entrapment neuropathy of the infrapatellar branches of the saphenous nerve typically produces pain in the anterior or anteromedial knee, whereas the pain reported by these patients was medial or even slightly posteromedial; however, this may not be a reliable distinguishing feature. In summary, it is unlikely (but possible) that these patients’ pain was generated by saphenous nerve entrapment, MCL bursitis, low-grade meniscal tear, or BSI (the latter was definitively ruled out by MRI in 2 of 9 patients). A palpation guide for some of these less common conditions, including the distribution of pain for the condition currently being described, is illustrated in Figure 2.

Patient Outcomes. Addressing the muscular tightness in the SM reduced pain by more than 70%. In 6 patients, the pain rating decreased from an average of 7/10 to 2/10 within the first 48 hours, and all were able to return to running within 72 hours. Patients 3 and 5 reached symptom

resolution by 7 days into treatment, and both returned to running within 14 days.

Patient 6 did not initially respond to therapy. Despite resolution of the medial hamstrings tension gait retraining, she still had pain at initial contact during walking and marching. On reevaluation, we found increased skeletal external tibial torsion of the involved leg. Presuming that the mechanics of marching were similar to those of heel-strike running, we adapted a derotation anterior cruciate ligament knee-taping procedure using Elastikon (Johnson & Johnson, New Brunswick, NJ) in an attempt to limit the external rotation from the screw-home mechanism (Figure 3). The patient described an immediate reduction in symptoms while walking and marching with the tape in place. Her symptoms resolved within another 2 days. The taping procedure was then no longer needed, and she returned to training with unrestricted running.

All 3 civilian patients who were treated conservatively but did not receive gait retraining reported a recurrence of symptoms over time, whereas none of the trainee patients reported a recurrence. Beyond gait training, these 2 groups had no purposeful differences in interventions; all were treated with SM stretching and pelvic-strengthening and -activation exercises.

DISCUSSION

All of the patients in this case series presented with medial knee pain, MCL tenderness, a heel-strike running gait, and SM tightness. When we looked at these factors together, it seemed that the source of pain in these patients was likely a desmopathy of the MCL secondary to SM-mediated traction. The quick symptom resolution that followed the hold-relax technique supports the hypothesis that tension on the SM was a driving factor in the patients’ symptoms. The SM tendon intertwines with fibers of the MCL.⁹⁻¹¹ Semimembranosus tension at terminal knee extension could irritate the MCL by creating a posterior torque that counters the normal external tibial rotation during the screw-home mechanism. The 100% recurrence of symptoms in the 3 patients who did not receive gait training and the 0% recurrence in the 6 who did receive gait training strongly supports this biomechanical model. Removing the SM tension by decreasing tibial external-rotation moments thereby mitigates the source of irritation on the ligament during functional activities such as walking and running.

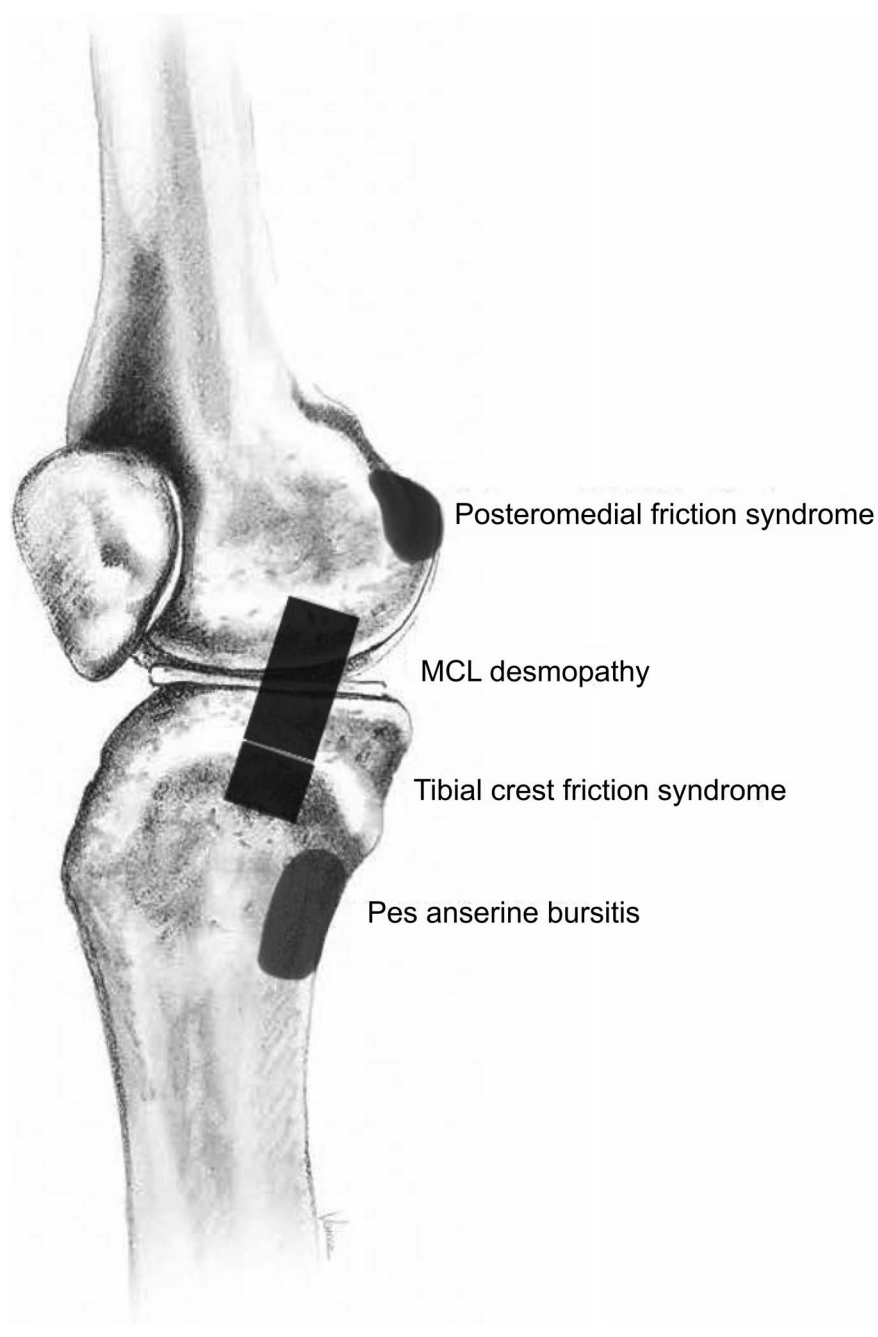


Figure 2. Palpation guide. Abbreviation: MCL, medial collateral ligament.

Another consideration related to a taut SM could be entrapment of the infrapatellar branches of the saphenous nerve. Saphenous nerve entrapments have been reported to mimic patellofemoral disorders, suprapatellar plica irritation, medial meniscal tears, tibial stress fractures, and pes anserine bursitis, among other conditions.^{12,13} Several of those conditions were in our initial differential diagnosis (Table 4). The infrapatellar branches form a subsartorial plexus that provides sensory innervation to the MCL and adjacent structures (including cutaneous sensation at the anteromedial knee). Case studies of possible saphenous nerve entrapment at the adductor canal described the use of manual neural-tensioning techniques for diagnosis as an

alternative to diagnostic nerve block injections.^{14,15} Both participants were runners and presented with pain when running and traversing stairs, similar to our patient population. The SM is not involved with the adductor canal, and so, it may be that some distal fibers of the infrapatellar branches of the saphenous nerve intermingle with the SM at the point of innervation of the MCL, creating a distal irritation that is localized to the ligament. This could explain the heightened symptoms when the SM was fully stretched and achieved peak activation during gait, approaching and at initial contact. The quick symptom resolution that followed the hold-relax technique supports

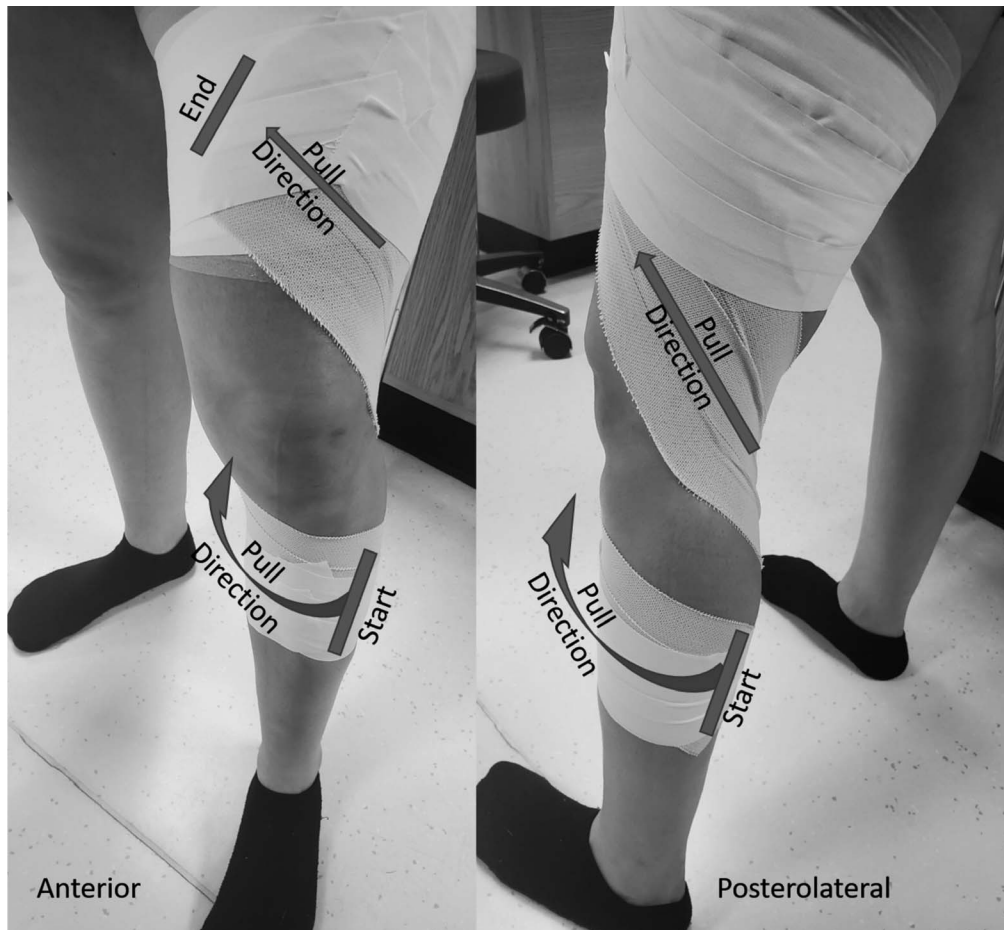


Figure 3. Derotation taping.

the hypothesis that tension on the SM was a driving factor in our patients' symptoms.

This case series should be considered in light of its limitations. A subset of 9 patients is a limitation; clearly, more cases need to be identified to validate the diagnosis. Only 2 of 9 patients had MRIs, 4 of 9 had radiographs, and 5 of 9 had no imaging at all. Further evaluation, such as electromyography and nerve conduction studies, would have been helpful in definitively evaluating possible nerve entrapments; however, these were not deemed clinically indicated by the physicians caring for these patients.

Targeted research on runners experiencing medial knee pain could further clarify the epidemiologic and mechanical trends associated with this hypothesized condition. Although the importance of the overstride component and the resultant SM tension are apparent from this clinical CASE report, we encourage others to explore these factors in runners to further refine the SM-overstride hypothesis. As this condition becomes better understood, additional intervention strategies should be evaluated, including the optimal approach to gait training.

Clinical Bottom Line

Many causes of insidious-onset medial knee pain have been described, yet an SM-mediated traction desmopathy of the MCL is a novel proposed cause of medial knee pain. Due to the tibial external rotation involved, an overstride

heel-strike running gait may be an underappreciated mechanism of injury to the MCL, particularly in patients with excessive traction of the SM on the MCL. Common features include running mechanics that lead to pain at initial contact localized to the medial knee and concurrent tightness in the SM. Releasing SM tightness is a temporary but effective solution. For long-term resolution, the overstride running form must be addressed. Although a description of the exact pathomechanics of the syndrome will require further research, we suggest that these 9 patients may represent a previously unreported cause of medial knee pain.

REFERENCES

1. Nye SN, Covey CJ, Sheldon L, et al. Improving diagnostic accuracy and efficiency of suspected bone stress injuries. *Sports Health*. 2016;8(3):278–283. doi:10.1177/1941738116635558
2. Nye SN, Pawlak MT, Webber BJ, Tchandja JN, Milner MR. Description and rate of musculoskeletal injuries in Air Force basic military trainees, 2012–2014. *J Athl Train*. 2016;51(11):858–865. doi:10.4085/1062-6050-51.10.10
3. Nogueira-Barbosa MH, Lacerda FM. Posteromedial snapping knee related to the sartorius muscle. *Radiol Bras*. 2011;44(3):195–197. doi:10.1590/S0100-39842011000300015
4. Simeone FJ, Huang AJ, Chang CY, et al. Posteromedial knee friction syndrome: an entity with medial knee pain and edema between the femoral condyle, sartorius and gracilis. *Skeletal Radiol*. 2015;44(4):557–563. doi:10.1007/s00256-014-2081-5

5. Klontzas ME, Akoumianakis ID, Vagios I, Karantanas AH. MR imaging findings of medial tibial crest friction. *Eur J Radiol.* 2013;82(11):e703–e706. doi:10.1016/j.ejrad.2013.07.024
6. De Maeseneer M, Shahabpour M, Van Roy F, et al. MR imaging of the medial collateral ligament bursa: findings in patients and anatomic data derived from cadavers. *AJR Am J Roentgenol.* 2001;177(4):911–917. doi:10.2214/ajr.177.4.1770911
7. Corten K, Vandenneucker H, Van Lauwe J, Bellemans J. Chronic posttraumatic bursitis of the medial collateral ligament: surgical treatment in 2 high-level professional athletes. *Am J Sports Med.* 2009;37(3):610–613. doi:10.1177/0363546508328116
8. Herman DC, Vincent KR. Saphenous neuropathy—a masquerading cause of anteromedial knee pain. *Curr Sports Med Rep.* 2018;17(6):177. doi:10.1249/JSR.0000000000000488
9. Flandry F, Hommel G. Normal anatomy and biomechanics of the knee. *Sports Med Arthrosc Rev.* 2011;19(2):82–92. doi:10.1097/JSA.0b013e318210c0aa
10. Gray H, Williams PL, Bannister LH, eds. *Gray's Anatomy: The Anatomical Basis of Medicine and Surgery.* 38th ed. New York, NY: Churchill Livingstone; 1995.
11. Dunaway DL, Steensen RN, Wiand W, Dopirak RM. The sartorial branch of the saphenous nerve: its anatomy at the joint line of the knee. *Arthroscopy.* 2005;21(5):547–551. doi:10.1016/j.arthro.2005.02.019
12. House JH, Ahmed K. Entrapment neuropathy of the infrapatellar branch of the saphenous nerve. *Am J Sports Med.* 1977;5(5):217–224. doi:10.1177/036354657700500509
13. Trescot AM, Karl HW, Brown MN, Pearce BS. Proximal saphenous nerve entrapment: thigh and knee. In: Trescot AM, ed. *Peripheral Nerve Entrapments: Clinical Diagnosis and Management.* Switzerland: Springer;2016:627–644.
14. Porr J, Chrobak K, Muir B. Entrapment of the saphenous nerve at the adductor canal affecting the infrapatellar branch—a report on two cases. *J Can Chiropr Assoc.* 2013;57(4):341–349.
15. Herman DC, Vincent KR. Saphenous nerve block for the assessment of knee pain refractory to conservative treatment. *Curr Sports Med Rep.* 2018;17(5):146–147. doi:10.1249/JSR.0000000000000480

Address correspondence to Reid Fisher, EdD, ATC, LAT, University of the Incarnate Word, 4301 Broadway, CPO 300, San Antonio, TX, 78209. Address e-mail to Reid_A_Fisher@hotmail.com.