

Current Clinical Concepts: Synthesizing the Available Evidence for Improved Clinical Outcomes in Iliotibial Band Impingement Syndrome

Paul R. Geisler, EdD, ATC

Exercise Science and Athletic Training, School of Health Sciences and Human Performance, Ithaca College, NY

The current paradigm of insidious lateral knee pain involving the iliotibial band (ITB) in repetitive knee-flexion activities has been termed *ITB friction syndrome* since 1975. The original model for ITB pain was based on a limited or incorrect understanding of the relevant anatomy, biomechanics, and tissue science, which gradually led to a plethora of frustrating and ineffective interventional strategies. Mounting evidence from arthroscopic, cadaveric, and biomechanical studies, as well as from diagnostic imaging and histologic reports, has helped deconstruct this

long-held paradigm for ITB-related pathology and treatment. By outlining the historical paradigm for our understanding of ITB pain and gathering newer evidence through extensive research, I will synthesize the available data in this clinical update to present an updated, more informed model for understanding insidious-onset ITB-related pathology and treating patients. The result is called *ITB impingement syndrome*.

Key Words: iliotibial band, impingement, pathology, running

The frequency and overall incidence of iliotibial band (ITB) pain syndrome (ITBPS) varies widely across patient populations and sports, reportedly occurring in 12% to 52% of habitual runners and 1% to 5% of military recruits and accounting for 1.6% to 52% of all knee injuries.^{1–4} Iliotibial band pain syndrome has also been described as the most common overuse injury of the lower extremity in female soccer, basketball, and field hockey athletes⁵; it affects up to 24% of road cyclists⁶ and is common in rowing athletes.⁷ Despite this relatively common and problematic ailment, effective treatment approaches for ITBPS have been elusive for sports medicine clinicians, largely because of the conceptual model used to explain its nature.⁸ In this clinical update, I will outline the historical paradigm used to inform our understanding of ITBPS to better characterize the poor clinical outcomes associated with the condition. I will also introduce practitioners to an updated, evidence-based paradigm for assessing and treating patients with ITBPS that leads to improved clinical outcomes.

FUNCTIONAL ANATOMY OF THE ITB

In 1843, Jacques Maissiat published an extensive monograph on the anatomy and function of the *ilio-trochantero-tibial bande*, in which he considered the unique muscle-fascia-tendon combination structure a ligament that connects the ilium and the knee to maintain balance during stance and motion.⁹ So extensive was this treatise on the peculiar ITB that it was at one point referred to as the *band of Maissiat*.⁹ In 1958, Kaplan⁹ described the ITB as connecting the ilia (pelvis) to the tibia (leg); running from the iliac crest, anterior ilium, and anterior-superior iliac spine; and fusing the tensor fascia latae and gluteus

maximus (GM) muscles into what he called the *deltoid of the hip*⁹ and inserting distally on the linea aspera and what he termed the *tubercle of Gerdy*.¹⁰ By classification, the ITB is part fascial thickening, part ligament, and part tendon. By architecture, it receives most of the GM muscle fibers and all of the tensor fascia latae fibers. By function, it is still an enigmatic structure to many clinicians.

Histologically, the ITB is dense, regular connective tissue that is largely avascular and composed almost exclusively of type I collagen with some elastin. Given that the ITB is largely fascial tissue, it demonstrates an enormous ability to adapt to and transfer mechanical stress, particularly repetitive forces. The ITB is also highly innervated and capable of transmitting sensation and tension.¹¹ We are the only animals to have ITBs, which are not present at birth in humans.¹² As we begin walking, the ITB develops slowly in response to the bipedal stresses of locomotion and weight bearing, providing hip stabilization for walking, running, and 1-legged landing and hopping. In other words, functionally, the ITB can be considered the aforementioned deltoid of the hip and lower extremity, as Kaplan⁹ described. Unlike the dominant open chain abduction of the humerus at the glenohumeral deltoid, Kaplan's deltoid of the hip is dominated by the closed chain, stabilizing, and force-absorption function of the lower extremity during weight bearing. Formed by the triangular union of the GM and tensor fascia latae muscles with the distally extending ITB, the hip's deltoid complex has a more critical and evident function during closed chain activities than simple open chain hip abduction reveals. The hip's deltoid complex more frequently acts to eccentrically stabilize the femur and tibiofemoral joints during the critical force absorption associated with walking and running stance and landing mechanics.¹³

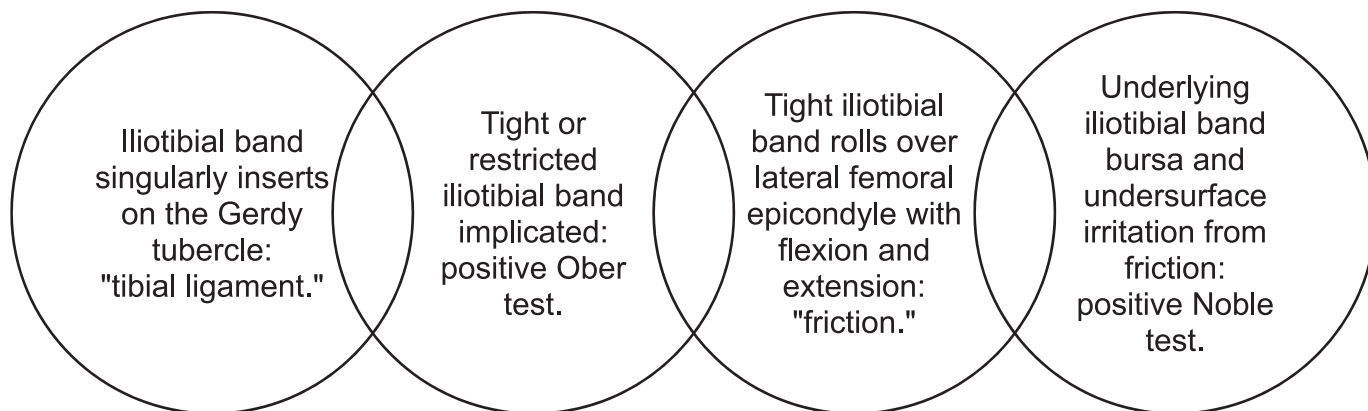


Figure 1. Original etiopathologic model for iliotibial band friction syndrome, 1974–1978.

HISTORICAL PARADIGM FOR ITB-RELATED LATERAL KNEE PAIN

Renne³ first described ITB friction syndrome (ITBFS) in 1975 after noting a preponderance of insidious-onset lateral knee pain in US Marines undergoing high-level physical training. The model was expanded in 1978 by Orava¹⁴ and further developed by Noble⁴ in 1979. The widely held and long-used friction-induced model for ITB-related pain constructed from the available knowledge of anatomy and lower extremity biomechanics is represented in Figure 1. The ITBFS model of Renne³ was founded on 4 suppositions: (1) the ITB has a simple unidimensional insertion on the Gerdy tubercle, (2) the ITB is restricted or “tight,” (3) an inflamed bursa or the ITB is the pain generator, and (4) inflammation is a result of the ITB “rolling over” the lateral femoral epicondyle (LFE) during repetitive knee-flexion motions.³ Renne³ hypothesized that the ITB rolls over the LFE and perhaps even the apex of the Gerdy tubercle with repetitive flexion and extension of the tibiofemoral joint. He reasoned that, with the knee in full extension, the ITB is anterior to the lateral epicondyle, and after the knee has passed 30° of flexion, the tendinous aspect of the band is positioned posterior to the bony femoral prominence. With repetition, this “slippage” creates unwanted and deleterious friction on the undersurface of the ITB and corresponding subtendinous bursa, resulting in inflammation and pain along the superior-lateral aspect of the knee.³ We can see that Renne³ obtained at least part of his model from Kaplan’s⁹ description of a “forward or backward fiber movement with flexion and extension of the knee.” The anatomic and biomechanical underpinnings of the ITB friction-restriction and pain model of Renne³ that has endured for the last 4 decades are summarized in Table 1.

Clinically, ITBFS is typically confirmed based on the patient’s activity and training volume and positive Ober and Noble tests after ruling out other potential diagnoses. Shortly after ITBFS was first described, the Noble test was developed for clinical diagnostic purposes. Increased pain with manual compression at the LFE with the knee flexed to 30° is diagnostic of ITBFS in runners. Indeed, the author⁴ noted that a positive Noble test indicated a “wounded IT band,” “bursal type tissue,” or “fascial tissue” as the nociceptive source. Over time, the etiopathologic description of ITBFS led to interventions designed to treat the symptoms and perceived cause, which consisted of

combinations of steroid injections, stretching of the ITB using various active soft tissue techniques and modalities, and compressive taping or strapping devices to prevent ITB rollover during knee flexion and extension. Despite the absence of compelling evidence to support the proposed anatomic or pathomechanical basis and the many highly ineffective interventional strategies used, numerous sources^{2,4–6,8,15,16} have contributed to the continued use of the friction model as the standard approach for clinical practice.

ADVANCING THE FRICTION MODEL

In 2 thought-provoking studies,^{17,18} Fairclough et al scrutinized the ITBFS model. Comparing gross anatomic dissection and histologic studies with magnetic resonance imaging (MRI) scans of healthy runners and runners with a diagnosis of ITBFS, they directly challenged the central premises of ITBFS: (1) the ITB does not roll over the femoral epicondyle because of firm fascia latae anchors, (2) changing tensions in the anterior and posterior fibers of the ITB during flexion and extension create an illusion of movement, and (3) instead of a subtendinous bursa, a highly innervated fat pad is located deep to the ITB.¹⁷ Their investigation revealed 2 distinct regions of the ITB that implicate a multifactorial tendinous part proximal to the LFE and a ligamentous portion between the epicondyle and its insertion at the Gerdy tubercle on the tibia. They also challenged the movement illusion first articulated by Kaplan⁹ and described as the “troublesome rollover mechanism” by Renne.³ Fairclough et al¹⁸ categorically refuted the notion that the ITB could roll over the LFE during flexion-extension motions for 2 interrelated reasons: (1) the ITB fibers are progressively tensioned from anterior to posterior during increasing flexion and (2) the numerous and dispersed fibrous connections of the ITB in the femur limit substantial movement over the femur.

In 2007 research, Viera et al¹³ investigated the finer details of the ITB’s anatomy and its functional relationship with other tissues and supported the conclusions of Fairclough et al.^{17,18} Ten detailed cadaveric dissections demonstrated 3 specific distal layers of the ITB, leading Viera et al¹³ to conclude that not only does the ITB have multiple intricate connections to the femur, the patella, and the lateral tibia, but it also plays a pivotal role in patellofemoral stability. They posited that the ITB’s

Table 1. Anatomical Components of the Historical and Updated Clinical Paradigms for Iliotibial Band Pathology

Iliotibial Band Paradigm	Origin	Insertion	Action or Implication
1974–1978 Combined model ^{3,4,14}	Fascial union of the tensor fascia latae and gluteus maximus muscles on the iliac crest and anterior-superior iliac spine	Broad to linea aspera Gerdy tubercle on tibia	Transmits force of tensor fascia latae muscle during hip activity (abduct from a flexed position) Acts as pelvic deltoid, stabilizing stance phase in lower extremity to allow contralateral swinging of knee and hip Restricts excessive hip adduction (if tight)
2007–2019 Updated synthesis model ^{15,16}	Fascial union of the tensor fascia latae and gluteus maximus muscles on the iliac crest and anterior-superior iliac spine (unchanged)	Broad to linea aspera Gerdy tubercle (3 layers) • Superficial • Deep • Capsulo-osseous Lateral femoral epicondyle Patella via lateral retinaculum or iliopatellar band Fibular head Kaplan fibers onto femur • Transversely on proximal Kaplan ridge • Longitudinally on distal Kaplan ridge	Passive stability of hip joint (via gluteus maximus tensioning in iliotibial band) during loading/deceleration in stance and monopodial gait Passively resists hip adduction and internal rotation during loading/deceleration in stance Passively limits anterior translation and internal rotation of tibia during loading/deceleration in stance

capsulo-osseous layer functions as an accessory anterolateral knee stabilizer, joining the anterior cruciate ligament and anterior longitudinal ligament in forming a functional “horseshoe system” that helps to control tibial rotation and anterior displacement under high external loads. Interestingly, Kaplan⁹ had already described this anatomic detail in 1958, yet the importance of these early findings seems to have been ignored by researchers and clinicians for more than 6 decades.

Additional examination of the role of the ITB in providing rotational stability offered further critique to the ITB friction model while highlighting older, somewhat forgotten details during the search for a new, more accurate model.¹⁹ In cadavers, Godin et al¹⁹ identified 2 discrete ligamentous bundles, known as *Kaplan fibers*, originating from the deep layers of the ITB and inserting on 2 distinct ridges (called *Kaplan ridges*) on the lateral aspect of the femur. Both the proximal (transversely oriented) and distal (longitudinally oriented) Kaplan fibers inserted on specific ridges on the lateral femur proximal to the lateral epicondyle between 31 (proximal) and 54 mm (distal) away from the rollover point, or the bony fulcrum of Renne.³ In addition to the specific reference to Kaplan fibers, Godin et al¹⁹ described how the capsulo-osseous layer of the distal ITB is intimately related to the lateral knee capsule and functionally integrated with both the lateral gastrocnemius muscle and lateral tibial tubercles. Although they focused on the ITB’s role in rotary stability of the tibiofemoral joint, their anatomic-biomechanical conclusions supported the more complex nature of the distal ITB as originally reported by Kaplan⁹ and later confirmed by both Fairclough et al¹⁷ and Vieira et al.¹³

PAIN GENERATORS

One potential pain generator in the ITB subspace has been described as a “lateral extension of the synovial pouch.”²⁰ Extrasynovial tissue or extensions or the

presence of fat pads, or both, have been reported to help maintain joint cavity spaces and distribute synovial fluid.²¹ The investigators²¹ identified a functional impingement zone in which maximum fat pad and synovial tissue impingement occurs when the knee-flexion angle approximates 30°. In other words, the potential impingement or compression zone occurs when the tibiofemoral joint is absorbing lower extremity ground reaction forces in the early to midstance phases of gait.

In another study, Ha et al²² discussed a rare but potential source of lateral knee pain—intra-articular fibromas within tendon sheaths. The authors reported MRI evidence of a thickened ITB, fatty abnormalities deep to the ITB, and an abnormal nodule in the space between the ITB and the LFE in a runner with ITBFS. Arthroscopic resection of the nodule revealed an inflamed lateral synovial recess and a white polypoid intra-articular nodule attached to the joint capsule. Although rare, tendon sheath fibromas in the knee are the most common location of intra-articular lesions in 20- to 50-year-old men and, therefore, must be ruled out as part of any thorough differential diagnosis. Clinically, fibromas can be differentiated in part because they present as painless masses in 31% of documented cases and are often accompanied by reports of a sense of fullness and mechanical symptoms.²²

Emerging research²³ emphasized the presence of a profound chemicophysical relationship between fat pads and tendon pain, adding further insight to the dispute surrounding the true nature of common tendinopathies (inflammation or degeneration debate) at the knee and ankle. Ward et al²³ suggested that fat pads share an anatomic and functional relationship as well as vascularization and innervation with adjacent tendons. Furthermore, they proposed that production of inflammatory cytokines by fat pads contributes to the development of clinical tendinopathies. Ward et al²³ linked the location of fat pads around the patellofemoral joint and Achilles tendon to inflammatory and vascular changes that effectively con-

tribute to the perception of tendon pain. For example, the Hoffa fat pad in the anterior knee and the Kager retrocalcaneal fat pad produce more inflammatory cytokines and possess a complex network of surface vessels. Functionally, these peritendinous fat pads located in the undersurfaces of the patellar and Achilles tendons are thought to serve similarly to bursa—help mitigate friction or compressive forces created by adjacent bony protuberances that come into contact with the tendons. Together, these interrelated fat pads provide an extrinsic blood supply that can become the root for tendon neovascularization, a characteristic of tendinopathy that has been termed *parainflammation*.²³ Parainflammation is considered chronic, low-grade inflammation that is associated with repetitive tissue stress and strain. Given these findings and in conjunction with the results of numerous researchers who were unable to identify a subtendinous bursa but described fat pads, it is perhaps practical to accept that fat pad parainflammation deep to the ITB is the actual source of pain.

A NEW, EVIDENCE-INFORMED MODEL EMERGES

Using an example of a recalcitrant case of ITBFS in an elite female runner as case evidence, Denegar²⁴ recounted how his initially futile clinical experience forced a fundamental reexamination of the paradigm he was using to assess and treat a high-performance athlete. This candid and introspective account of his unsuccessful attempts to treat the athlete, as well as the search for information and introspection required to approach the problem differently, were instrumental in the early construction of a new, updated model for ITBPS or ITBFS.²⁵

For years, clinicians have used the Ober test as a direct measure of ITB flexibility restrictions and to confirm a primary risk factor for ITBFS. Having a tight ITB (exemplified by a positive Ober test) was long thought to make a person more prone to rolling of the ITB over the LFE during flexion and extension of the knee, producing friction on the undersurface of the ITB or its underlying bursa. This idea led to numerous therapeutic interventions intended to stretch the ITB to alleviate the friction forces and thus the ITB or bursa-related pain. Diagnostic accuracy studies on the Ober test are lacking, at least in part because of the lack of a meaningful criterion standard measure (surgery or MRI) for comparison. However, Willett et al²⁶ improved our understanding of the function of the ITB and associated limitations of the Ober test. Using progressive transections of the ITB in cadaveric specimens, Willett et al²⁶ demonstrated that the ITB does not limit hip-adduction range of motion; rather, the gluteus medius and minimus muscles and joint capsule of the hip are responsible for limiting passive femoral-adduction motion. Given that neither the gluteus medius nor the gluteus minimus muscles insert into the ITB, the conclusion was that tight or restricted ITBs did not produce positive Ober tests.

Emerging fascial research informs us that the ITB cannot, in fact, be stretched to any appreciable level, even if it is tight.²⁷ In other words, if a positive Ober test finding resulted from regional restrictions in the hip or thigh, then the fascia latae, lateral intermuscular septum, and distal fibrous bands anchoring the ITB to the femur would all need to be stretched for the ITB to be functionally

lengthened and the Ober test to be negative. Chaudhry et al²⁸ used a 3-dimensional mathematical model to show that the force required to produce 1% shear and compression in the fascia latae was far beyond the physiological range induced by any known manual therapy. The authors determined that the fascia latae remains very stiff under any stretch-induced shearing and thus any anecdotal relaxation changes noted after massaging fascial tissue are likely due to mechanoreceptor stimulation in the fascia that induces tonus changes in the connected muscle fibers. Taken together, the findings on the anatomic nature and biomechanics of the Ober test and mechanical properties of the fascia latae support the notion that perceived ITB restrictions do not contribute to femoral range-of-motion limits or to increased friction during repeated flexion-extension movements.

BIOMECHANICS AND PATHOMECHANICS OF THE ITB

Given the extensive body of evidence indicating that the ITB cannot mechanically roll over the LFE during knee flexion because of its complex insertional anatomy, that it does not contribute to limited femoral motion (adduction) if it is deemed to be tight, and that it is unlikely the ITB can be stretched to any meaningful degree, the critical question for clinicians to ponder is, “Why do some people have ITB pain and yet others do not?” What is the precise etiopathology in those runners, cyclists, and rowers who have ITB pain due to repetitive knee flexion-extension motions? Why have standard and long-implemented treatment approaches, such as strapping, stretching, and massage, not worked for patients with ITB pain?²⁹

In their analysis, Fairclough et al¹⁸ asked if the pain indeed results from compression of a subtendinous fat pad and not from the ITB rolling over the LFE, what then is the actual mechanism responsible for fat pad irritation? Two earlier studies offered a plausible explanation for the conundrum.^{30,31} Fredericson et al³⁰ not only reported weaker hip-abduction strength in the affected legs of endurance runners diagnosed with ITBFS but also determined that the painful condition resolved and patients returned to preinjury training after documented improvements in hip-abductor strength. By aggregating their own findings with these previous results, Fairclough et al¹⁸ posited that ITBPS must be related to impaired function of the hip musculature and, thus, resolution can be achieved only by addressing the biomechanics associated with hip-muscle function.

In a prospective study, Noehren et al³² helped advance our understanding of ITBPS by finding that ITB-related pain was linked to peak hip-adduction and knee-internal-rotation moments during running. Based on these mechanical flaws, they suggested that treatment interventions for ITB-related pain should focus on controlling abnormal planar movements of the stance limb during the energy-absorption phase of gait. Given that these factors have similarly been noted to contribute to patellofemoral pain syndrome, proximal lower extremity changes that allow femoral drift from the sagittal plane into the frontal plane are known to result from hip-muscle latency or fatigue and have been associated with ITBPS in runners.^{1,33–35}

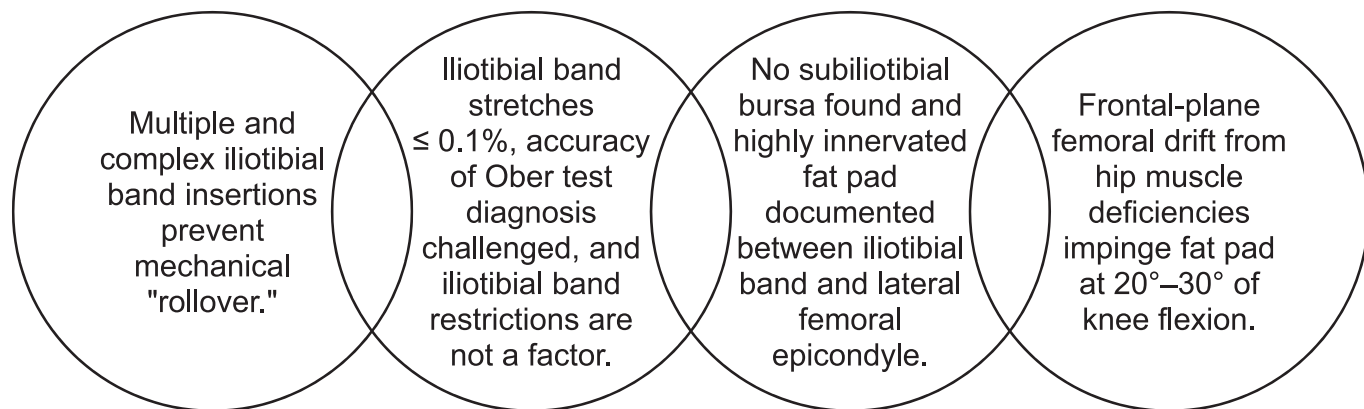


Figure 2. Updated, evidence-informed model for iliotibial band impingement syndrome, 2007–2019.

Biomechanical data on the ITB strain rate and pathogenesis of ITBPS by Hamill et al³⁶ have lent further objective support to the notion that stretching a tight ITB does not help reduce pain (due to compression or impingement) and that increased dynamic valgus mechanics in the knee joint during stance contribute to the development of ITBPS because of the speed at which they induce strain on the ITB. These findings have been corroborated in other systematic reviews and meta-analyses.^{37,38} The work of Hamill et al³⁶ is important to the new, emerging thesis for ITBPS, as the authors contended that it is not simply the absolute magnitude (length) of strain on the ITB but rather the strain rate that is problematic in people with pain. Strain rate is an indirect measure of tension in the collagen-based viscoelastic tissue, and the rate at which the relative strain is placed on the ITB is linked to pathomechanical deviation. Hamill et al³⁶ identified strain rate as the primary factor contributing to the development of pain because runners with ITBPS exhibited greater strain in their ITBs throughout the critical support phase of gait (20°–30° of knee flexion) compared with a control group. These experimental findings are clinical examples of the aforementioned impingement zone, which occurs with low to moderate levels of dynamic valgus collapse in certain individuals, placing them at greater risk for anterior cruciate ligament injury, patellofemoral pain syndrome, and ITBPS.³⁶

The functional utility of humans' 1-legged stance phase is to absorb body weight and ground reaction forces through decelerative muscle action (eccentric contractions). Exaggerated or excessive multiplanar joint motions in the lower extremity indicate that the ITB in some knees is in a potential impingement zone for a longer time, increasing the strain rate in the ITBs of femurs that drift out of the sagittal plane. Over an extended run, fatigue progresses and slowly decreases the ability of the proximal hip muscles to effectively absorb the high-energy loads produced in the ipsilateral lower extremity, leading to subtle and progressive degrees of dynamic valgus–rotational drift of the tibiofemoral joint. In concluding that ITBPS pathomechanics are related to lower extremity frontal- and transverse-plane drift during the absorptive phase of gait, numerous investigators^{28,32–39} have suggested that kinematic discriminators for the clinical assessment of ITBPS are supported.

As in patellofemoral pain syndrome, the proximal hip-abductor and external-rotator muscles need to be properly recruited and activated appropriately over time to eccentrically stabilize the femur (and, thus, the tibiofemoral joint) in the impingement zone (20°–30° of knee flexion) of 1-legged stance during walking and running.^{2,27,30,32,35,39} Quite simply, the deltoid of the lower extremity, or the proximal muscles that fuse into the ITB, along with the gluteus medius and minimus and piriformis muscles, need to work constantly to avert problematic degrees of femoral adduction and internal rotation to prevent ITB fat pad impingement from occurring every time the foot hits the ground.

Considerable evidence now exists to provide a more informed scientific paradigm for ITB-related conditions in running-based athletes. The various components of the newer, evidence-informed synthesis model for ITB impingement syndrome (ITBIS) are summarized and contrasted with the long-held model for ITBFS in Table 2. The core factors of ITBIS as a more apropos, evidence-informed paradigm for clinical practice are presented in Figure 2. The evidence-informed ITBIS model is predicated on consistently reproduced biomechanical data that implicate neuromuscular dysfunction or inhibition at the hip as the primary contributor to the mechanical forces that produce the painful syndrome.

CLINICAL ASSESSMENT RECOMMENDATIONS

Iliotibial band impingement syndrome can be assessed and confirmed by taking a thorough history that includes training volume, patient behaviors (eg, past treatment), pain behavior (eg, increases and decreases, pain levels, quality), specific palpation over the LFE, and a positive Noble test that reproduces the quality and location of the pain. The results of the Ober test should not be factored into the diagnostic process, as its role in predicting knee motion or restrictions has now been challenged. The most common findings in the histories of patients with ITBIS are sudden increases in training volume, hill running (especially downhill), and banked running. Patients with ITBIS might also have pain when squatting and descending stairs and a fear of permanent damage (indicating a possible psychological overlay). Noble⁴ found that 84% of his participants with confirmed ITB injury had such training errors in their histories and that sharp, focal lateral knee pain after a

Table 2. Summary of Historical and Updated Core Components of 2 Competing Paradigms for Iliotibial Band Pathologies and Pain

Syndrome Component	Iliotibial Band Friction (Slipping Band) ^{3,4,14}	Iliotibial Impingement or Compression ²
Etiopathology	Movable iliotibial band crosses or rolls over lateral femoral condyle with knee flexion and extension, especially at 20°–30° of flexion, during midstance phase of gait	Iliotibial band does not move across the lateral femoral epicondyle and thus cannot cause friction-related or mechanical rollover pathology. Dynamic valgus collapse due to proximal neuromuscular factors causes increased femoral adduction and internal rotation, impinging the iliotibial band against tissue during repetitive flexion and extension activities.
Tissue and anatomy	Inflamed subtendinous bursa Inflamed iliotibial band Iliotibial band inserts on linea aspera and Gerdy tubercle	Extrasynovial pouch/recess Benign tendon sheath fibroma Highly innervated fat pad (most common) Iliotibial band has multiple, complex, and layered insertions on femur, tibia, patella/lateral retinaculum, and lateral femoral epicondyle.
Clinical presentation	History concurrent with iliotibial band signs and symptoms, including pain over lateral femoral condyle, overuse, increased mileage, and other modifiable risk factors common in runners (+) Ober test (+) Noble test	History concurrent with iliotibial band signs and symptoms, including pain over lateral femoral condyle, overuse, increased mileage, and other modifiable risk factors common in runners Ober test deemed irrelevant (+) Noble test Increased dynamic valgus collapse at 20°–30° of knee flexion during absorptive phase of gait Decreased knee window; increased impingement zone Proximal hip musculature insufficiency or fatigue Excessive pes planus contributes
Treatment ^a	Corticosteroid injections Stretching iliotibial band Strapping iliotibial band Deep tissue friction massage Therapeutic modalities Activity modifications Surgery (recalcitrant cases)	Early recognition Activity and load modifications Proximal hip strengthening and neuromuscular training to reduce dynamic valgus during stance-absorption phase of gait Orthotic to modify hyperpronation

^a See Tables 4 and 5.

period of running was the most frequent chief symptom. Numerous authors^{30,32–35} documented the effect of running fatigue on lower extremity biomechanics in patients with ITBIS and reported that a 20- to 30-minute treadmill run was sufficient to induce hip-muscle fatigue that, in turn, can allow up to a 5° increase in femoral adduction, beyond the minimally detectable difference.

Clinicians should rule out other possibilities, such as patellofemoral pain syndrome and instability, lateral collateral ligament sprain, osteoarthritis of the lateral tibiofemoral joint, and even lateral meniscal pathology, as part of the differential diagnosis process. When ITBIS is suspected, functional and dynamic testing of the hip muscles and lower kinetic chain interdependence should be assessed in a progressive manner, using loading and endurance procedures, such as a treadmill or live run, to challenge and fatigue the hip abductors and external rotators. If patients are cyclists or rowers, comparable biomechanical flaws and pain reproduction should be assessed while the former cycle on their bicycles affixed to a stationary trainer or the latter use a rowing ergometer. Noting when the chief symptoms are reproduced in the fatiguing intervention will help to align these findings with the patient's history. Clinicians should also perform manual and dynamometer muscle testing of the hip-abductor and external-rotator muscles to evaluate gross muscle function, using multiple repetitions to induce fatigue if necessary.

Patients' walking and running gaits should be assessed for appreciable levels of dynamic valgus drift of the lower extremities into the frontal plane during absorption, with clinicians looking for the presence of the impingement window at the 20° to 30° of flexion position in the midstance to late stance of ambulation. This can also be done by identifying a Trendelenburg gait during walking or running; contralateral pelvic dipping may indicate a gait pattern that can cause ITB impingement. For cyclists or rowers, slow-motion video capture of their biomechanics might reveal femoral adduction toward the bicycle's top tube from the top to the bottom of the downstroke or femoral drift during the catch phase of rowing. Patients should be examined for poor pelvic and femoral control via both static and dynamic assessments (contralateral 1-legged standing and mini-squats; step-up and step-down demands; and finally under fatiguing conditions, such as running on a treadmill). Video and motion capture of these dynamic tasks can aid in evaluating the presence of small to moderate levels of femoral adduction–internal rotation during the loading phase of stance, when impingement of the fat pad can occur.

CLINICAL MANAGEMENT RECOMMENDATIONS

Although further prospective, randomized, and long-term follow-up studies are clearly needed to advance our understanding of best-practice prevention and treatment approaches for ITBIS, motion-based neuromuscular reed-

ucation and training of the proximal hip muscles as part of the intervention strategy are now widely recommended.^{38,40–42} In a recent systematic review and meta-analysis, Balachandar et al³⁸ found moderate level 1 evidence to support the use of nonsteroidal anti-inflammatory drugs, stretching, and hip-abduction training. In a level 3 investigation involving 2 patients with ITBIS, Shamus and Shamus⁴⁰ reported improvements in pain and function after neuromuscular reeducation. Van der Worp et al⁴¹ described the effectiveness of corticosteroid injections and hip-abduction training according to patient- and clinician-reported outcome measures in their 2012 systematic review. Finally, in a randomized controlled trial of 30 patients with ITBPS, Zemadani and Betsos⁴² observed less pain and improved function as a result of mobilization and movement-based treatments for the proximal hip muscles.

Authors^{30,31,38,43} of numerous intervention studies have reported positive short-term results using hip-muscle-based therapies that decreased pain and returned athletes to their preinjury running volume and performance. Fredericson et al³⁰ noted that improvements in hip-abductor strength from a neuromuscular-based intervention led to parallel decreases in pain and increases in preinjury training levels and that 22 of 24 patients with ITBIS returned to pain-free running within 6 weeks. Ford et al⁴⁴ published an extensive evidence-based review of hip-focused neuromuscular interventions for addressing dynamic femoral valgus motions. They assessed 100 papers focused on hip-muscle activation and inhibition and the presence of dynamic valgus drift in patients with patellofemoral pain syndrome and anterior cruciate ligament injuries. Based on the findings from numerous electromyographic, kinematic, and kinetic studies, their final analysis supported the use of targeted non-weight-bearing, controlled weight-bearing, functional, and dynamic hip exercises for reducing and controlling lower extremity dynamic valgus motions.⁴⁴

Using hip electromyography data, Lewis et al⁴⁵ demonstrated that side-walking or side-stepping exercises with resistance banding around the forefeet (as opposed to the ankles and knees) were superior for activating both the hip-abduction and external-rotation muscles during closed chain functional tasks. Their findings suggested that progressing patients from side walking or side lunging with resistance tubing around the knees, to the ankles, and finally to the forefeet would be an effective progression model for challenging the proximal hip muscles to control frontal-plane drift. The pertinent research findings for activating and training the relevant hip muscles are summarized in Table 3, which includes several clinical pearls for patients with ITBIS who display frontal-plane femoral drift during landing and absorption.

In contrast, researchers^{2,29,46} who studied traditionally used approaches to treatment advised against stretching, friction massage, or strapping the ITB; recommended limiting modality applications; and suggested using corticosteroid injections for patients whose symptoms lasted <14 days. In an examination of standard treatment options, Falvey et al²⁷ observed that ITB stretching and corticosteroid injections were ineffective and without scientific foundation.

Based on the Strength of Recommendation Taxonomy criteria, Tables 4 and 5 highlight the strength of evidence regarding various intervention strategies (both old and new)

and the strength of recommendation for treating patients with ITBIS using these strategies, respectively.⁴⁷ For pain and dysfunction in patients with ITBIS, level B evidence supports the use of neuromuscular control and strengthening of the hip abductors and external rotators but does not support using deep friction massage, injections, or stretching techniques.

Before initiating the active component of an intervention plan for patients with ITBIS, a calming period should be implemented to decrease pain and tissue sensitivity.⁴⁸ Activity reduction, load modification, pain-control measures, and cross-training to maintain fitness levels for elite, highly conditioned athletes should be the core components of the calming period. However, running-based patients with ITBIS should be cautioned not to use the stair-stepper, stationary bicycle, or rowing ergometer for cross-training to avoid further impingement forces. Swimming and flat-ground, level walking with shorter strides are suitable cross-training activities for running-based athletes to consider during this period.

Level I Management: Low-Load, Open Chain Phase

Evidence-supported exercises for activating and improving the endurance of the proximal hip muscles responsible for reducing femoral adduction and internal rotation during weight-bearing activities include side-lying, short-arc hip-abduction isotonic exercises and side-lying “clamshell” exercises (hips and knees flexed to 20°–30° in the side-lying position) that focus on eccentric control of the hip abductors, quadruped “mule kicks” with the knee flexed and extended during the hip-extension component and using resistance bands or cuff weights, supine single-legged (ipsilateral side) hip-extension bridges with the knee progressively flexed from 90° to 30°, and seated or supine hip external-rotation isotonic exercises using resistive tubing.⁴⁸ Lumbopelvic stability and high-quality motion control should be encouraged during all hip-based exercises to promote functional coordination, and purposeful ranges of motion should be used wherever possible. The volume and load should be progressively increased with patient tolerance, restoration of muscle activity, and continued pain reduction.

Level II Management: Moderate-Load, Closed Chain Phase

To progress to and within level II, patients’ pain levels should not exceed 3 of 10 at any point. Loads in this level are transitioned to weight bearing and are gradually intended to become more functional; endurance is increased gradually, and fatigue is evident in a loss of high-quality motion during exercises. Deliberate verbal cuing and mirrors for feedback, motion control, and high-quality execution are required to encourage and restore more desirable movement patterns in the sagittal plane for all weight-bearing exercises.^{44,48} Persistent or increasing pain levels are concerning and necessitate a reduction in the dynamic load placed on the injured knee. Suggested foci for level II include 1-legged ipsilateral standing hip hikes that require gluteal activity to prevent hip drop and Trendelenburg positioning, split-leg forward lunges, 2-legged mini-squats that progress to 1-legged mini-squats, progressive step-up and step-down exercises with gluteal focus that

Table 3. Rationale and Selected Evidence-Informed Exercises to Improve Control and Function of Proximal Hip Musculature According to the Literature

Authors (Year)	Rationale and Selected Exercises
Lewis et al (2018) ⁴⁸	<p>↑ Electromyographic gluteus maximus and medius activity with side-stepping exercises for both moving and stance limbs with resistance bands placed around feet versus ankles or knees</p> <p>↑ Tensor fascia latae electromyographic activity with band around ankles versus knees</p> <p>Clinical pearls</p> <ul style="list-style-type: none"> • Side stepping in the squat position with resistance bands around feet elicited greatest gluteal muscle activity without increasing tensor fascia latae activity. • Resistance band placement around forefoot during side-stepping exercise activated gluteal muscles that helped prevent femoral adduction and internal rotation (dynamic valgus), producing greatest combined effect. • Gluteus medius and tensor fascia latae activation, trunk inclination, hip-flexion angle, and hip-abduction excursion differed between sexes and were greater in women than men.
Ford et al (2015) ⁴⁴	<p>Gluteus medius, minimus, and maximus and piriformis muscles provided proximal stability for lower extremity motion during single-limb weight bearing and absorption. Via eccentric-isometric contractions, these muscles stabilized pelvis in frontal and transverse planes to maintain level pelvis and control rotation of femoroacetabular joint. Weakness, fatigue, or insufficiency of posterolateral hip musculature produced Trendelenburg posture, essentially due to femoral adduction and internal rotation during stance-absorption phase of gait and landing.</p> <p>Effective targeted exercises:</p> <ul style="list-style-type: none"> • Non-weight bearing <ul style="list-style-type: none"> ○ Side-lying hip abduction activated gluteus medius 16%–43% more than side-lying clamshell exercise. ○ Side-bridge (plank) exercise activated gluteus medius 35%–40% more than side-lying hip-abduction exercise. ○ Supine bridging with hip extension activated gluteus maximus, especially when performed unilaterally. • Controlled weight-bearing <ul style="list-style-type: none"> ○ In progressive order, hip hikes, lateral step-ups, and single-limb squats effectively activated gluteus medius. ○ In progressive order, lateral step-ups, single-limb dead lifts, single-limb squats, and forward step-ups and -downs effectively activated gluteus maximus. • Functional <ul style="list-style-type: none"> ○ In progressive order, forward lunges, side lunges, and lateral band walks effectively activated gluteus medius. ○ In progressive order, lateral band walks, side lunges, and forward lunges effectively activated gluteus maximus. ○ Maximum gluteus medius activation was achieved using single-limb sagittal-plane hurdle hops. Strong activation was achieved using double-limb sagittal-plane hurdle and split-squat jumps. ○ Maximum gluteus maximus activation was achieved using double- and single-limb sagittal-plane landings. <p>Clinical pearls</p> <ul style="list-style-type: none"> • Limb position and joint angles influence gluteal activation. • Femoral internal rotation during side-lying hip abduction increased gluteus medius activity. • Gluteus maximus activation was greater with hip in 30°–60° of flexion versus 90°. • Hip muscles were more active during jumping and running with more flexed trunk. • High-quality positioning and control are paramount: <ul style="list-style-type: none"> • First, focus on hip muscle strength and activation to control femoral adduction and internal rotation in eccentric fashion. • Second, integrate neuromuscular control of hip abductors, extensors, and external rotators. • Third, work on optimizing biomechanics for activity and sport in progressive, functional manner.

prevent Trendelenburg hip drop, contralateral open chain hip isotonic exercises to challenge the painful leg in various stability positions (ensuring proper sagittal-plane positioning), and side-stepping or lunging exercises with resistance bands (progressing from the band placed at the knee, to the ankle, and then the toes as tolerated). The latter stages of level II can begin to challenge the system using jog and stop-in-place exercises on the affected limb, followed by small, controlled mini-hops and hold exercises to assess proximal control and proper sagittal-plane motion and force absorption. Again, quality control of motion and patient tolerance should serve as the guiding principles for progression.

Level III Management: High Impact, Tolerance, and Ready Phase

To progress into and within level III, athletes should be able to tolerate higher volume and duration of loads used in level II and be pain free during and after exercise sessions. Clinicians should also ensure that the patient demonstrates quality sagittal-plane movements and control before

moving into higher-demand and -load level III activities. Patients also should be capable of walking for at least 30 minutes without lateral knee pain or jogging for 1 minute without pain, or both, before progressing into level III.⁴⁸ More dynamic exercises in this level include the deeper unilateral squats, mini-hops and stop in place, lateral hops and bounding, agility ladder drills, bilateral drop jumps from height that progress to single-legged drop jumps, and lateral stepping or lunging with resistance tubing around the toes to maximally target the gluteus medius and maximus muscles.⁴⁵ All landing drills should be performed in front of a mirror with oral cuing to encourage proper sagittal-plane landing and loading mechanics. To determine patient readiness and tolerance for greater running-based loads, the clinician can implement a run-walk interval program. On flat ground, the athlete can run for 1 minute, followed by 1 minute of walking, for a total of 30 minutes while the clinician assesses the running gait for a visible knee window during midstance. Hill running and running on uneven surfaces should only be gradually introduced as the increasing distance of the flat-ground interval-running program is tolerated.

Table 4. Review of Evidence for Iliotibial Band Impingement Syndrome Interventions

Authors (Year)	Design	Variable	Outcome(s)	Level of evidence (SORT ⁴⁷) ^a
Neuromuscular hip training and reeducation				
van der Worp et al (2012) ⁴¹	Systematic review: 7 studies with 5 on conservative care and 2 on surgical intervention	Mix of patient-reported (pain, return to activity) and clinician-reported (hip-abductor torque) outcomes	Some evidence for effectiveness of corticosteroid injections and hip-abductor strengthening	2
Shamus and Shamus (2015) ⁴⁰	Case series: 2 patients	Patient-reported outcomes: pain and function	Hip neuromuscular reeducation and strengthening as part of regional interdependence approach effective	3
Zemadanis and Betsos (2017) ⁴²	Randomized controlled trial: 30 patients	Patient-reported outcomes: pain and function	Mobilization with movement and automobilization improved pain and function	2
Balachandar et al (2019) ³⁸	Systematic review and meta-analysis: 11 studies	Patient-reported outcomes: pain and recurrence up to 6 mo	Moderate evidence for nonsteroidal anti-inflammatory drugs, iliotibial band stretching, and hip-abductor strengthening	1
Other techniques				
Schwellnus et al (1992) ⁴⁵	Randomized controlled trial: 17 patients Physiotherapy Evidence Database quality scale score: 5/10	Patient-reported outcomes: pain (total pain, % maximum pain when running, 24-h recall pain)	Deep transverse friction massage not recommended	2
Ellis et al (2007) ²	Systematic review: 4 randomized controlled trials	Patient-reported outcomes: pain	Limited evidence for nonsteroidal anti-inflammatory drugs; deep friction massage and phonophoresis beneficial	2
Loew et al (2014) ²⁹	Systematic review: 1 study with 17 patients	Patient-reported outcomes: pain (visual analog scale, pain while running, % maximum pain while running)	Deep transverse friction massage did not improve pain	2

Abbreviation: SORT, Strength of Recommendation Taxonomy.

^a Levels of evidence: 1, *good-quality patient-oriented evidence*; 2, *limited-quality patient-oriented evidence*; 3, *other evidence (consensus guidelines, usual practice, opinion, case series)*.

SUMMARY

Clinicians who treat athletes with ITB-related pain should confirm the diagnosis of ITBIS by ruling out other sources of lateral knee pain using a detailed patient history and basic physical examination in conjunction with a biomechanical assessment. If the condition is detected early (within 2 weeks), nonsteroidal anti-inflammatory medication can help lower the pain level but should be combined with a calming period during which activity and load are reduced to decrease fat pad and ITB irritation.²⁹ Stretching and deep friction massage of the distal ITB should not be included in the intervention plan. After pain levels are reduced to 3 of 10, a focused and progressive neuromuscular training program that starts with low-load, open chain, non-weight-bearing exercises should progress to more demanding, closed chain, weight-bearing exercises to

correct noted biomechanical flaws and increase muscular endurance.

Hip-muscle retraining and rehabilitation should first occur in open chain contexts to better activate the muscles, gradually progressing to weight-bearing and more functional closed chain demands with appropriate feedback and high-quality movement to control femoral adduction and internal rotation. Endurance is key for this approach, so loads should be gradually increased with caution and performance of high-quality, controlled movements using oral and visual cuing as needed. Finally, the patient’s readiness to run, cycle, or row should be assessed using higher load with more demands and a progressive, controlled return to activity based on tolerance and the absence of pain.

Table 5. Strength of Recommendations for Iliotibial Band Impingement Syndrome Therapeutic Interventions Based on SORT Criteria⁴⁷

Recommendation	Strength of Recommendation
Deep friction massage, injections, and stretching techniques not recommended for decreasing pain or increasing function	B: Recommendation based on inconsistent or limited-quality patient-oriented evidence
Improving neuromuscular control, endurance, and strength of hip-abductor and external-rotator muscles helpful for decreasing pain and improving function	B: Recommendation based on inconsistent or limited-quality patient-oriented evidence

Abbreviation: SORT, Strength of Recommendation Taxonomy.

REFERENCES

1. Baker RL, Fredericson M. Iliotibial band syndrome in runners: biomechanical implications and exercise interventions. *Phys Med Rehabil Clin N Am*. 2016;27(1):53–77. doi:10.1016/j.pmr.2015.08.001
2. Ellis R, Hing W, Reid D. Iliotibial band friction syndrome—a systematic review. *Man Ther*. 2007;12(3):200–208. doi:10.1016/j.math.2006.08.004
3. Renne JW. The iliotibial band friction syndrome. *J Bone Joint Surg Am*. 1975;57(8):1110–1111.
4. Noble CA. The treatment of iliotibial band friction syndrome. *Br J Sports Med*. 1979;13(2):51–54. doi:10.1136/bjism.13.2.51
5. Devan MR, Pescatello LS, Faghri P, Anderson J. A prospective study of overuse knee injuries among female athletes with muscle imbalances and structural abnormalities. *J Athl Train*. 2004;39(3):263–267.
6. Holmes JC, Pruitt AL, Whalen NJ. Iliotibial band syndrome in cyclists. *Am J Sport Med*. 1993;21(3):419–424. doi:10.1177/036354659302100316
7. Rumball JS, Lebrun CM, Di Ciaccia SR, Orlando K. Rowing injuries. *Sport Med*. 2005;35(6):537–555. doi:10.2165/00007256-200535060-00005
8. Beals C, Flanigan D. A review of treatments for iliotibial band syndrome in the athletic population. *J Sports Med (Hindawi Publ Corp)*. 2013;2013:367169. doi:10.1155/2013/367169
9. Kaplan EB. The iliotibial tract: clinical and morphological significance. *J Bone Joint Surg Am*. 1958;40(4):817–832.
10. Williams PL, Bannister LH, eds. *Gray's Anatomy: The Anatomical Basis of Medicine and Surgery*. 38th ed. Churchill Livingstone; 1995.
11. Klinger W. Physiology and biochemistry. In: Schleip R, Baker A, eds. *Fascia: In Sport and Movement*. Handspring Publishing; 2015:3–11.
12. Vesalius A, Lind LR, Asling CW, Clendening L. *The Epitome of Andreas Vesalius*. Macmillian; 1949.
13. Vieira EL, Vieira EA, da Silva RT, Berlefein PA, Abdalla RJ, Cohen M. An anatomic study of the iliotibial tract. *Arthroscopy*. 2007;23(3):269–274. doi:10.1016/j.arthro.2006.11.019
14. Orava S. Iliotibial tract friction syndrome in athletes—an uncommon exertion syndrome on the lateral side of the knee. *Br J Sports Med*. 1978;12(2):69–73. doi:10.1136/bjism.12.2.69
15. Lucas CA. Iliotibial band friction syndrome as exhibited in athletes. *J Athl Train*. 1992;27(3):250–252.
16. Franco V, Cerullo G, Gianni E, Puddu G. Iliotibial band friction syndrome. *Oper Tech Sports Med*. 1997;5(3):153–156. doi:10.1016/S1060-1872(97)80037-8
17. Fairclough J, Hayashi K, Toumi H, et al. The functional anatomy of the iliotibial band during flexion and extension of the knee: implications for understanding iliotibial band syndrome. *J Anat*. 2006;208(3):309–316. doi:10.1111/j.1469-7580.2006.00531.x
18. Fairclough J, Hayashi K, Toumi H, et al. Is iliotibial band syndrome really a friction syndrome? *J Sci Med Sport*. 2007;10(2):74–78. doi:10.1016/j.jsams.2006.05.017
19. Godin JA, Chahla J, Moatshe G, et al. A comprehensive reanalysis of the distal iliotibial band: quantitative anatomy, radiographic markers, and biomechanical properties. *Am J Sports Med*. 2017;45(11):2595–2603. doi:10.1177/0363546517707961
20. Nemeth WC, Sanders BL. The lateral synovial recess of the knee: anatomy and role in chronic iliotibial band friction syndrome. *Arthroscopy*. 1996;12(5):574–580. doi:10.1016/S0749-8063(96)90197-8
21. Grando H, Chang EY, Chen KC, Chung CB. MR imaging of extrasynovial inflammation and impingement about the knee. *Magn Reson Imaging Clin N Am*. 2014;22(4):725–741. doi:10.1016/j.mric.2014.07.011
22. Ha DH, Choi S, Kim SJ, Wang L. Intra-articular fibroma of tendon sheath in a knee joint associated with iliotibial band friction syndrome. *Korean J Radiol*. 2015;16(1):169–174. doi:10.3348/kjr.2015.16.1.169
23. Ward ER, Andersson G, Backman LJ, Gaida JE. Fat pads adjacent to tendinopathy: more than a coincidence? *Br J Sports Med*. 2016;50(24):1491–1492. doi:10.1136/bjsports-2016-096174
24. Denegar CR. Tendinopathy and iliotibial band syndrome: understanding pathology informs treatment. Presented at: Eastern Athletic Trainers' Association Annual Conference and Symposium; January 8–11, 2010; Boston, MA. Accessed December 17, 2020. <http://goeata.org/protected/EATACD10/downloads/pdf/presentation-denegar.pdf>
25. Geisler PR, Lazenby T. Iliotibial band impingement syndrome: an evidence-informed clinical paradigm change. *Int J Athl Ther Train*. 2017;22(3):1–11. doi:10.1123/ijatt.2016-0075
26. Willett GM, Keim SA, Shostrom VK, Lomneth CS. An anatomic investigation of the Ober test. *Am J Sport Med*. 2016;44(3):696–701. doi:10.1177/0363546515621762
27. Falvey EC, Clark RA, Franklyn-Miller A, Bryant AL, Briggs C, McCrory PR. Iliotibial band syndrome: an examination of the evidence behind a number of treatment options. *Scand J Med Sci Sport*. 2010;20(4):580–587. doi:10.1111/j.1600-0838.2009.00968.x
28. Chaudhry H, Schleip R, Ji Z, Bukiet B, Maney M, Findley T. Three-dimensional mathematical model for deformation of human fasciae in manual therapy. *J Am Osteopath Assoc*. 2008;108(8):379–390. doi:10.7556/jaoa.2008.108.8.379
29. Loew LM, Brosseau L, Tugwell P, et al. Deep transverse friction massage for treating lateral elbow or lateral knee tendinitis. *Cochrane Database Syst Rev*. 2014;2014(11):CD003528. doi:10.1002/14651858.CD003528.pub2
30. Fredericson M, Cookingham CL, Chaudhari AM, Dowdell BC, Oestreicher N, Sahrmann SA. Hip abductor weakness in distance runners with iliotibial band syndrome. *Clin J Sport Med*. 2000;10(3):169–175. doi:10.1097/00042752-200007000-00004
31. Fredericson M, Wolf C. Iliotibial band syndrome in runners: innovations in treatment. *Sports Med*. 2005;35(5):451–459. doi:10.2165/00007256-200535050-00006
32. Noehren B, Davis I, Hamill J. Prospective study of the biomechanical factors associated with iliotibial band syndrome. *Clin Biomech (Bristol, Avon)*. 2007;22(9):951–956. doi:10.1016/j.clinbiomech.2007.07.001
33. Baker RL, Souza RB, Fredericson M. Iliotibial band syndrome: soft tissue and biomechanical factors in evaluation and treatment. *PM R*. 2011;3(6):550–561. doi:10.1016/j.pmrj.2011.01.002
34. Miller RH, Lowry JL, Meardon SA, Gillette JC. Lower extremity mechanics of iliotibial band syndrome during an exhaustive run. *Gait Posture*. 2007;26(3):407–413. doi:10.1016/j.gaitpost.2006.10.007
35. Brown AM, Zifchock RA, Hillstrom HJ, Song J, Tucker CA. The effects of fatigue on lower extremity kinematics, kinetics and joint coupling in symptomatic female runners with iliotibial band syndrome. *Clin Biomech (Bristol, Avon)*. 2016;39:84–90. doi:10.1016/j.clinbiomech.2016.09.012
36. Hamill J, Miller R, Noehren B, Davis I. A prospective study of iliotibial band strain in runners. *Clin Biomech (Bristol, Avon)*. 2008;23(8):1018–1025. doi:10.1016/j.clinbiomech.2008.04.017
37. Aderem J, Louw QA. Biomechanical risk factors associated with iliotibial band syndrome in runners: a systematic review. *BMC Musculoskelet Disord*. 2015;16:356. doi:10.1186/s12891-015-0808-7
38. Balachandar V, Hampton H, Riaz O, Woods S. Iliotibial band friction syndrome: a systematic review and meta-analysis to evaluate lower-limb biomechanics and conservative treatment. *Muscles Ligaments Tendons J*. 2019;9(2):181–193. doi:10.32098/mltj.02.2019.05

39. Louw M, Deary C. The biomechanical variables involved in the aetiology of iliotibial band syndrome in distance runners—a systematic review of the literature. *Phys Ther Sport*. 2014;15(1):64–75. doi:10.1016/j.ptsp.2013.07.002
40. Shamus J, Shamus E. The management of iliotibial band syndrome with a multifaceted approach: a double case report. *Int J Sports Phys Ther*. 2015;10(3):378–390.
41. van der Worp MP, van der Horst N, de Wijer A, Backx F, Nijhuis-van der Sanden MW. Iliotibial band syndrome in runners: a systematic review. *Sports Med*. 2012;42(11):969–992. doi:10.2165/00007256-200535050-00006
42. Zemadani K, Betsos T. Short-term effects of mobilization-with-movement (MWM) and auto-MWM application in recreational runners with iliotibial band syndrome. *Int J Physiother*. 2017;4(6):327–334. doi:10.15621/ijphy/2017/v4i6/163919
43. Noehren B, Schmitz A, Hempel R, Westlake C, Black W. Assessment of strength, flexibility, and running mechanics in men with iliotibial band syndrome. *J Orthop Sport Phys Ther*. 2014;44(3): 217–222. doi:10.2519/jospt.2014.4991
44. Ford KR, Nguyen AD, Dischiavi SL, Hegedus EJ, Zuk EF, Taylor J. An evidence-based review of hip-focused neuromuscular exercise interventions to address dynamic lower extremity valgus. *Open Access J Sport Med*. 2015;6:291–303. doi:10.2147/OAJSM.S72432
45. Lewis CL, Foley HD, Lee TS, Berry JW. Hip-muscle activity in men and women during resisted side stepping with different band positions. *J Athl Train*. 2018;53(11):1071–1081. doi:10.4085/1062-6050-46-16
46. Schwellnus M, Mackintosh L, Mee J. Deep transverse frictions in the treatment of iliotibial band friction syndrome in athletes: a clinical trial. *Physiotherapy*. 1992;78(8):564–568. doi.org/10.1016/S0031-9406(10)61197-2
47. Ebell MH, Siwek J, Weiss BD, et al. Strength of Recommendation Taxonomy (SORT): a patient-centered approach to grading evidence in the medical literature. *J Am Board Fam Pract*. 2004;17(1):59–67. doi:10.3122/jabfm.17.1.59
48. Mellinger S, Neurohr GA. Evidence based treatment options for common knee injuries in runners. *Ann Transl Med*. 2019;7(suppl 7):S249. doi:10.21037/atm.2019.04.08

Address correspondence to Paul R. Geisler, EdD, Exercise Science and Athletic Training, School of Health Sciences and Human Performance, Ithaca College, Ithaca, NY 14850. Address email to pgeisler@ithaca.edu.