

Digitally Guided Lateral Sinus Floor Elevation With Simultaneous Implant Placement: 3 Case Reports With Technical Considerations

Priscila C. Meneghetti, DDS, MS^{1,2}
 Hamoun Sabri, DMD, PgC^{3,4}
 Ebrahim Dastouri, PgC³
 Rafael M. Pereira, DDS, MS³
 Wendel Teixeira, DDS, MS, PhD³
 Junying Li, DDS, MS, PhD²
 Hom-Lay Wang, DDS, MSc, PhD³
 Gustavo Mendonça, DDS, MS, PhD²
 Rafael Siqueira, DDS, MS, PhD^{5*}

A sinus floor elevation via lateral window (LSFE) is one of the most widely used bone augmentation procedures for implant therapy in the posterior area of the maxilla. Locating and preparing a correct opening window on the lateral sinus wall is a key step of this procedure. Conventionally, the surgeon designs and locates the window after the flap is reflected based on the information obtained from cone-beam computed tomography (CBCT) images or other diagnostic aids. Nevertheless, in spite of the advancements in CBCT imaging, clinicians may still experience hardships in situating and procuring meticulous access to the maxillary sinus by using CBCT alone. Therefore, in cases requiring an LSFE simultaneous to implant placement, a maxillary sinus surgical guide has been tested and reported to be the amiable method to be utilized as a adjunct to prevent unpredictable consequences according to its application in implying both the direction for the implant and the location of the lateral window. This article presents 3 clinical cases with a fully digital approach to guide the opening of the lateral wall of the maxillary sinus as well as the simultaneous placement of a single implant in an ideal 3D position. Based on the CBCT images and intraoral scan, a surgical guide was fabricated based on 3D software. During surgery, this teeth-supported template can be placed intraorally, guiding sinus window opening preparation. This technique makes the sinus window opening procedure simple and predictable, reduces surgical time and the risk of complications, and allows the placement of the implant in the ideal 3D position.

Key Words: digital workflow, sinus lift, sinus augmentation, surgical guide, dental implants, static computer-aided implant surgery (SCAIS), guided surgery, digital planning

INTRODUCTION

The implant placement procedure in the posterior maxillary can be challenging, especially in the atrophic alveolar ridge, because of tooth extraction and maxillary sinus pneumatization.^{1,2} Therefore, in some situations, sinus floor elevation via a lateral window (LSFE) is frequently performed with or without simultaneous implant placement.

Although LSFE is a predictable and well-documented technique, some complications are reported, including perforation of the Schneiderian membrane and bleeding, often influencing the results of the procedures.¹⁻³ In addition, several anatomical- and patient-related factors, such as the presence of sinus septa, location of the alveolar antral artery, membrane thickness, buccal wall thickness, and preoperative sinus pathology, must be considered during LSFE treatment planning.¹ Thus, to optimize the success rate during LSFE, cone-beam computed tomography (CBCT) has become a valuable planning tool that assists in evaluating sinus morphology, such as septa, residual bone height, and the presence of maxillary arterial branches.

Therefore, to promote an accurate surgical procedure and improve the surgical workflow with simultaneous implant placement, a 3D printed surgical guide was designed to incorporate the lower contour of the maxillary sinus access window and the ideal 3D position of the implant. Thus, this article aims to present and discuss technical considerations related to using this new maxillary sinus surgical guide to improve surgical outcomes.

¹ Postgraduate Program, Dental School, Pontifical University Catholic of Rio Grande do Sul, Porto Alegre, Brazil.

² Department of Biological and Materials Sciences and Prosthodontics, University of Michigan School of Dentistry, Ann Arbor, MI, USA.

³ Department of Periodontics and Oral Medicine, University of Michigan School of Dentistry, Ann Arbor, MI, USA.

⁴ Cranio-Maxillofacial Research Center, Shahid Beheshti University of Medical Sciences, Tehran, Iran.

⁵ Department of Periodontics, Virginia Commonwealth University, Richmond, VA, USA.

* Corresponding author, e-mail: siqueira@vcu.edu
<https://doi.org/10.1563/aaid-joi-D-22-00198R2>

TABLE 1

Characteristics of the subjects and the followed implant treatment

Patient Number	Age	Sex	Implant Site	Initial Ridge Width and Height	Implant Size	Graft Material	Implant System
1	61	F	#3	12.4 × 4.2 mm	4.7 × 11.5 mm	Puros Cortical Allograft + L-PRF	Zimmer
2	50	M	#3	14 × 5.34 mm	4.8 × 10 mm	Puros Cortical Allograft	Straumann
3	69	M	#3	10.7 × 4 mm	4.1 × 10 mm	Puros Cortical Allograft	Straumann

PATIENTS AND METHODS

Patients screening

This retrospective 3-case report was conducted from January to June 2021. Patients who were qualified for the LSFE with simultaneous implant placement were included in the study. The demographic data of each subject are presented in Table 1. The included patients should fulfill the following inclusion criteria: healthy systemic condition without any serious medical or dental problem affecting the quality of the implant surgery; a healed surgical site with at least 3 months postextraction; available CBCT scan, digital impressions, and clinical photographs; and follow-up appointments to document the treatment outcome. Informed consent was obtained from the patient prior to surgery. All surgical procedures were performed at the Graduate Periodontics Clinic, University of Michigan, School of Dentistry, by a single surgeon (R.S.).

Preoperative workup/fabrication of the surgical guide

CBCT scans (3D Accuitomo 170; J Morita, Kyoto, Japan) were acquired from all patients, and the images were saved in Digital Imaging and Communications in Medicine (DICOM) format. In addition, a digital impression of the arches and occlusal relations was obtained using an intraoral scanner (Trios 3; 3Shape, Copenhagen, Denmark), and the images were exported as stereolithographic (STL) format files. Following a thorough evaluation

and a careful diagnosis, treatment planning was performed based on the clinical and para-clinical findings.

Technique

A clinician with experience in digital dentistry designed the all-in-one LSFE and implant placement surgical guide. The technique that was used to delineate the guide is described below (Figures 1 through 7):

1. Import the DICOM and STL files of the maxilla into the implant planning software BlueSky Plan (Blue Sky Bio LLC). Then align and superimpose the maxillary digital model to the CBCT scan.
2. After evaluating sinus anatomy (Figure 1), plan an implant with a tube extending through the lateral sinus wall, using the tube as the reference to define the outline of the lateral window (Figure 2). This step allows the operator to evaluate the sinus anatomy and establish the location of the sinus window on the lateral wall.
3. Create a surface of the maxillary jaw and export it as an STL file—export data together with the tube extension.
4. Into Meshmixer software (Meshmixer; Autodesk Inc. San Francisco, Calif), import the STL file of the maxillary bone, the extension tube, and the patient’s maxilla scan. Next, the maxilla mesh should be transformed into a hollow model (Figure 3a and b) to create contact between the meshes. Next, the model and the bone must be aligned, cut at the

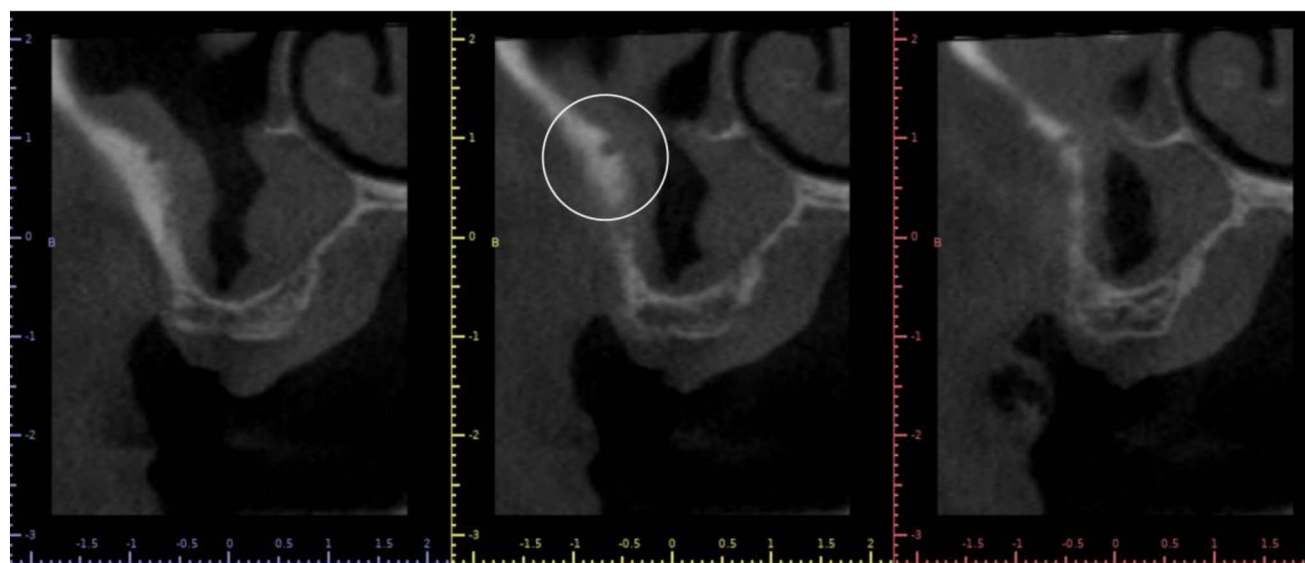


FIGURE 1. The coronal cut of a cone-beam computed tomography image indicating right-side sinus anatomy. Predicted location of the alveolar antral artery (lucency) within the bone structure of the lateral wall (white circle).

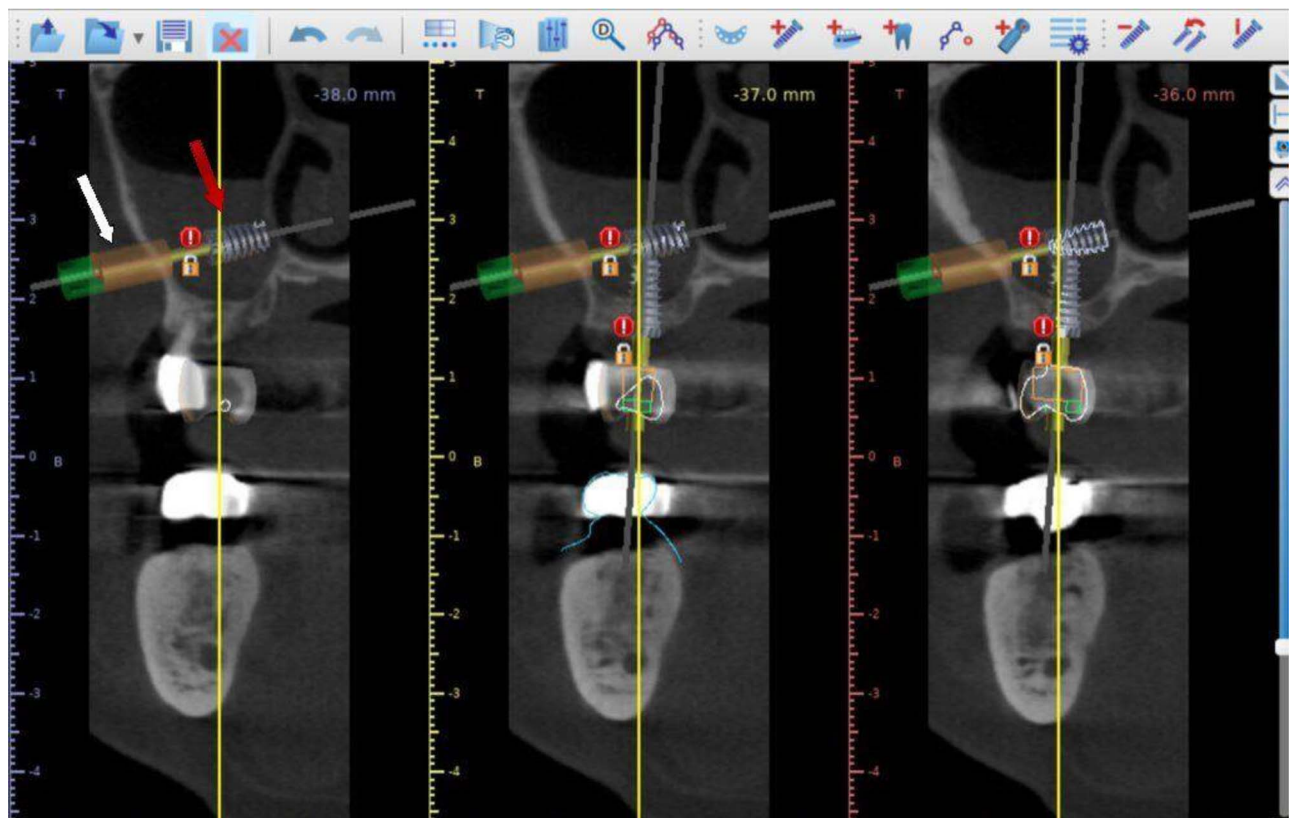


FIGURE 2. Following the evaluation of the anatomical structure and planning the location of the opening, a tube extension is created (white arrow) by an implant (red arrow) to approach the desired pathway to the lateral sinus wall.

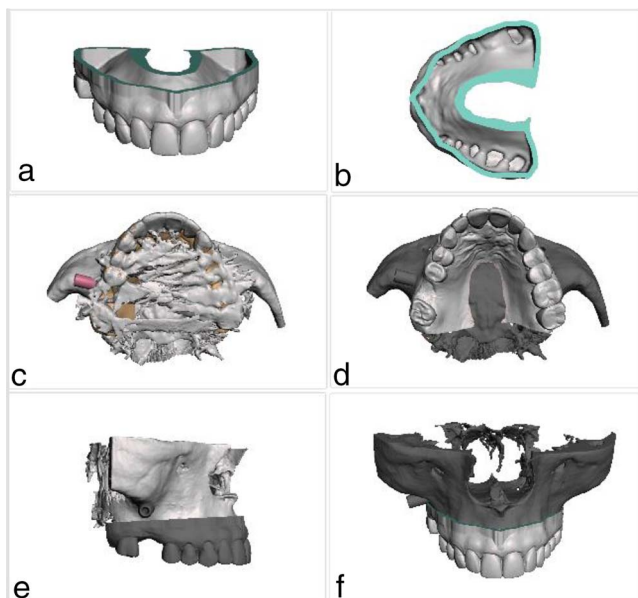


FIGURE 3. (a) and (b) The maxillary arch hollow model is created from the digital impression file. (c) The cone-beam computed tomography (CBCT) scan of the maxilla, with the imported tube extension for the sinus wall opening. (d) The model superimposed to the CBCT scan (occlusal view). (e) Lateral view of the scan, the model, and the extension tube. (f) Frontal view of the files combined.

same level, and combined (Figure 3c and d). This way, 1 STL file is created with the maxillary bone, teeth, and tube extension (Figure 3e and f).

- On 3Shape Implant Studio software (3Shape A/G, Copenhagen, Denmark), the surgical guide is designed for implant placement and LSFE. In addition, the planned lateral window antrostomy area is designed around the tube that goes through the buccal bone wall of the sinus (Figure 4).
- The guide is 3D printed (SprintRay Pro 95; SprintRay, Los Angeles, Calif) utilizing the Surgical Guide 3 resin (SprintRay) (Figure 5), and the post-printing process is performed following the manufacturer's guidelines.

Surgical procedures

In all cases, patients presented for implant surgery to replace the missing right maxillary first molar (#3) and LSFE under intravenous sedation. Treatment planning was conducted as described in the surgical technique section for the 3D printed guide fabrication. Following the local anesthesia, the crestal incision was made with a 15C blade extending to a vertical incision on the mesial of #4 and an intra-sulcular on #2, allowing access to the lateral window of the sinus. The window's dimensions were designed using the 3D printed surgical guide and a Thomson stick to outline the design of the antrostomy (Figures 6 through 8). The window osteotomy was started with an electric handpiece with a diamond bur

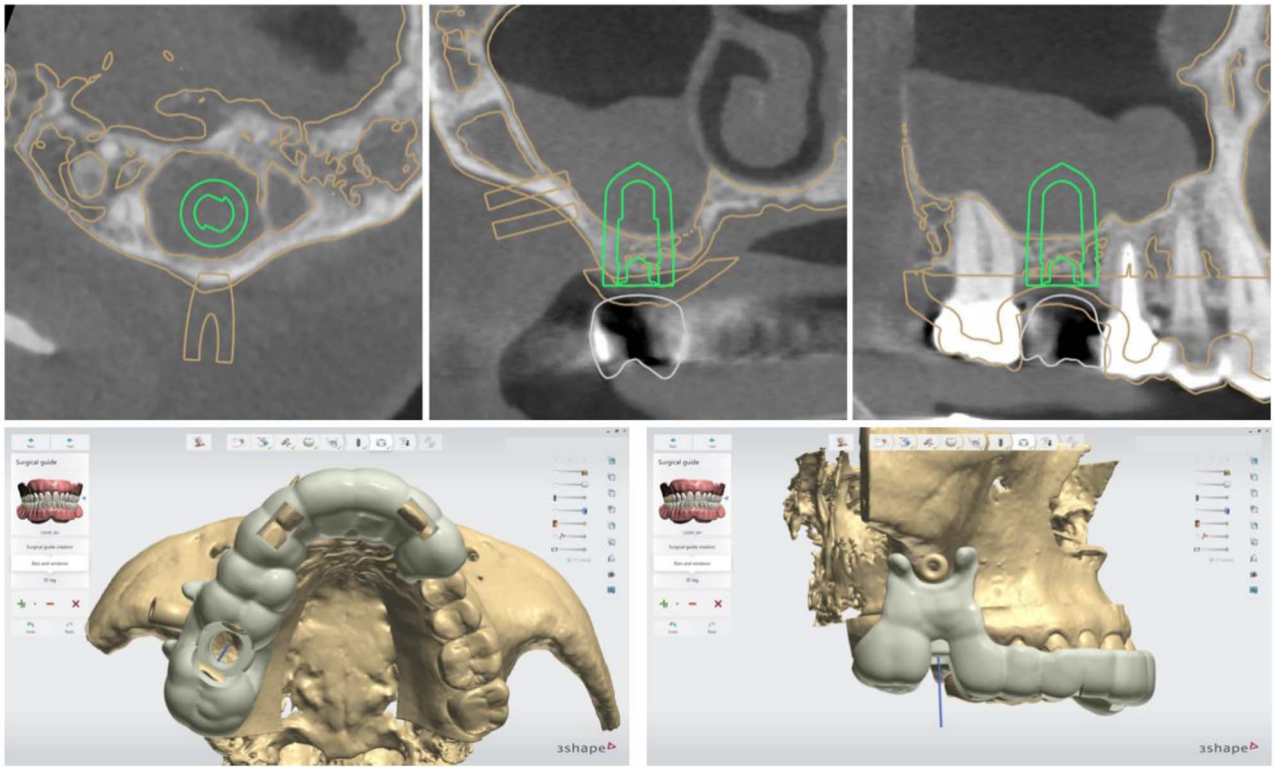


FIGURE 4. The designed sinus-lift-implant-placement surgical guide.

and a piezoelectric device until the sinus membrane was reached. Next, the membrane was elevated using sinus curette instruments until achieving complete elevation. Following the drill sequence of the implant, the sinus was grafted. An allograft bone substitute (Puros Cortical Bone Allograft; Zimmer Biomet Dental, Palm Beach Gardens, Fla) was used for all cases. Primary stability of the implant was achieved, the cover screw was installed, and the flaps were re-approximated with sutures.

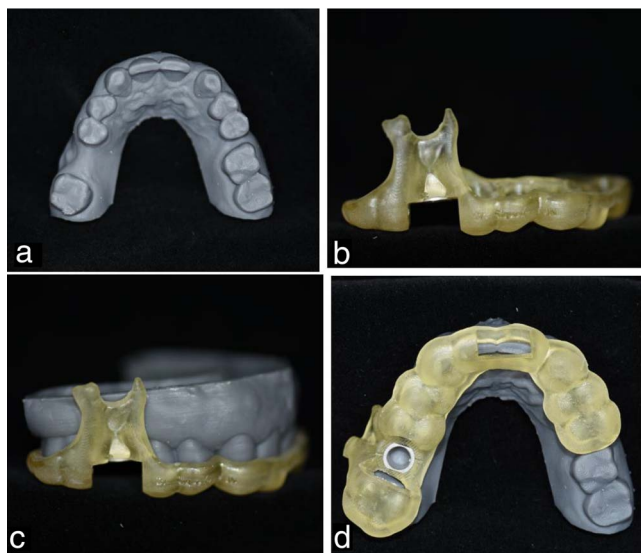


FIGURE 5. (a) The 3D printed maxillary model cast. (b) The 3D printed surgical guide. (c) The seated guide, lateral view. (d) The occlusal view.

Follow-up visits

After 2 weeks, participants presented for a postoperative visit for healing evaluation and suture removal. Subsequent recall

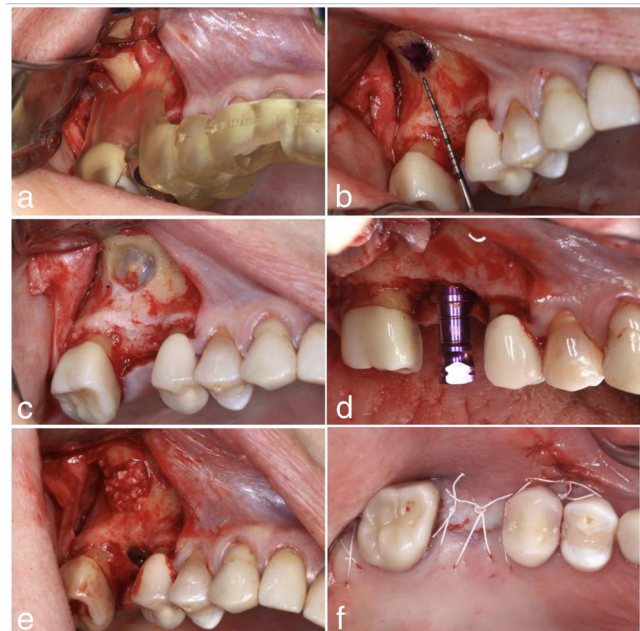


FIGURE 6. Intraoperative photos of case 1. (a) The 3D printed guide seating on the occlusal surface. (b) The sinus window is drawn using a brush. (c) Bone removal of sinus lateral window. (d) Implant placement. (e) Application of bone substitute. (f) Flap closure using polytetrafluoroethylene sutures.

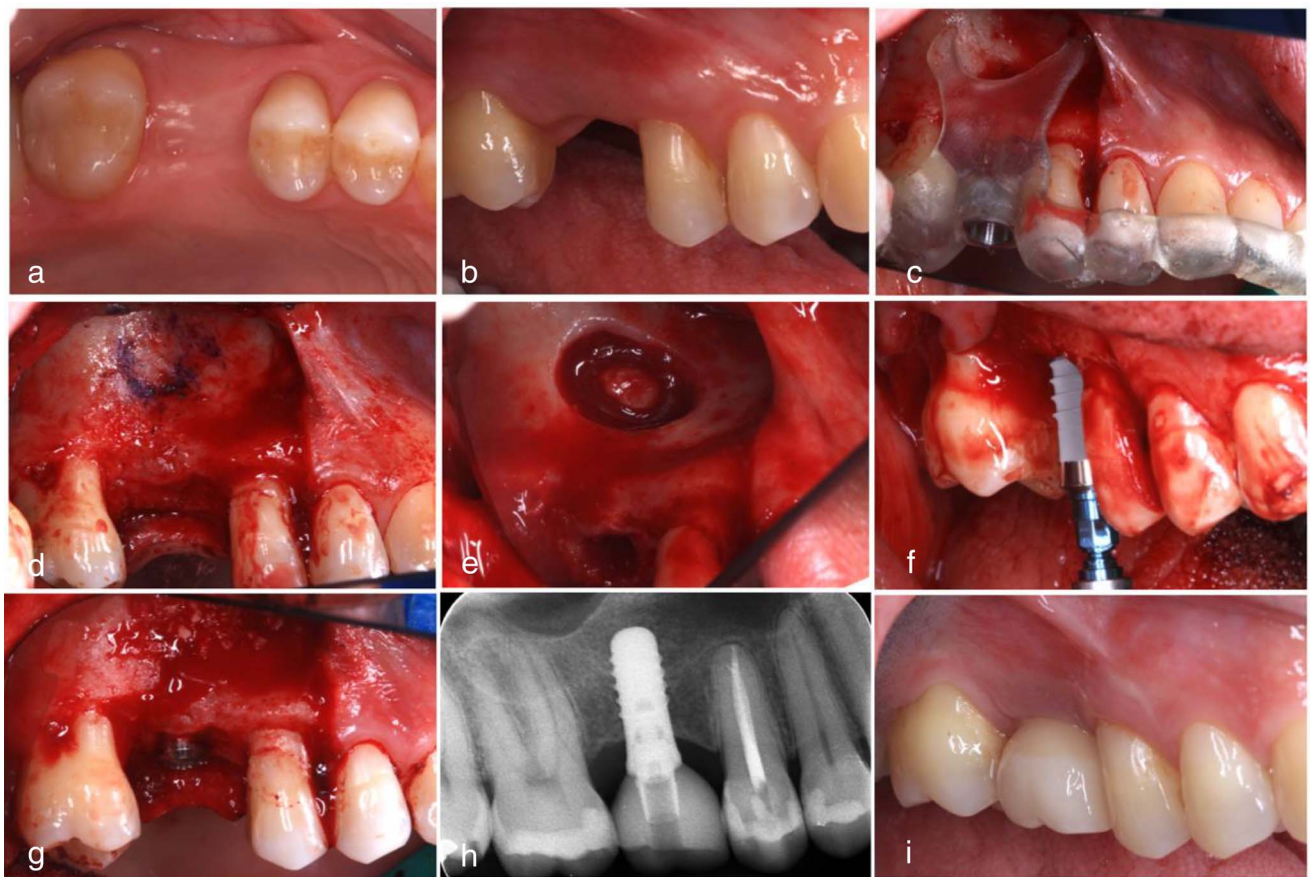


FIGURE 7. Case 2. (a) Occlusal view of maxillary posterior region. (b) Lateral view. (c) The 3D printed guide seating on the occlusal surface. (d) The lateral window is drawn using a brush. (e) Lateral window access. (f) Implant placement. (g) Bone grafting. (h) Final X ray. (i) Definitive screw-retained implant zirconia crown.

visits were at 4 weeks and 8 weeks and after 5 months. All 3 patients underwent LSFE and simultaneous implant placement using the all-in-one surgical guide. None of the patients experienced complications such as unmanageable pain, swelling, nausea, epistaxis, or early implant failure. The postoperative images revealed that all the implants were successfully placed in the planned position. The fixtures were inserted within the lateral sinus window's side borders, soundly covered by the bone.

DISCUSSION

The occurrence of complications during and after LSFE surgery, such as sinus membrane perforation and significant bleeding, can be minimized by adopting a new advancement in digital dentistry that improves treatment planning and surgery precision by utilizing surgical templates. This 3-case series technique note demonstrated a novel guided approach for simultaneous LSFE and implant placement using a 3D printed surgical guide. This is in support of Mandelaris and Rosenfeld's concept,⁴ who proposed using digital guides for LSFE, where they used a prototype cutting guide that was developed through the use of computerized tomographic imaging, computer software, and the stereolithographic process to position the lateral wall window to facilitate

LSFEField 4 precisely. Furthermore, Mangano et al⁵ applied a computer-aided design/computer-aided manufacturing (CAD/CAM) technique that calculates the size and shape of a bone graft and trims a bone block into the desired shape. In addition, a customized CAD/CAM osteotomy template was designed and manufactured before surgery and used during the operation.

In this study, we introduced the guided simultaneous LSFE and implant placement surgical guide based on the digital intra-oral scans and CBCT images, overcoming the limitations of the previous techniques comprising the higher fabrication cost and higher radiation dose to the patient. Furthermore, regarding the discrepancies between the planned and actual surgical guide outcomes, when a 1-piece surgical guide is designed, the anatomical morphology might compromise the ideal adaptation of the guide to the teeth and bone, which congruently attenuates the favorable result. Likewise, in 2 similar studies, the authors reported the fabrication of 2 separate guides, 1 for the LSFE and the other for implant placement.^{5,6} Another study by Goodacre et al⁷ also demonstrated the steps to design a surgical guide for the LSFE. The difference between the guide this group introduced was that it outlines the osteotomy borders, including the superior border. In contrast, the surgical guide designed by our team outlines primarily the lower limits only and secondarily

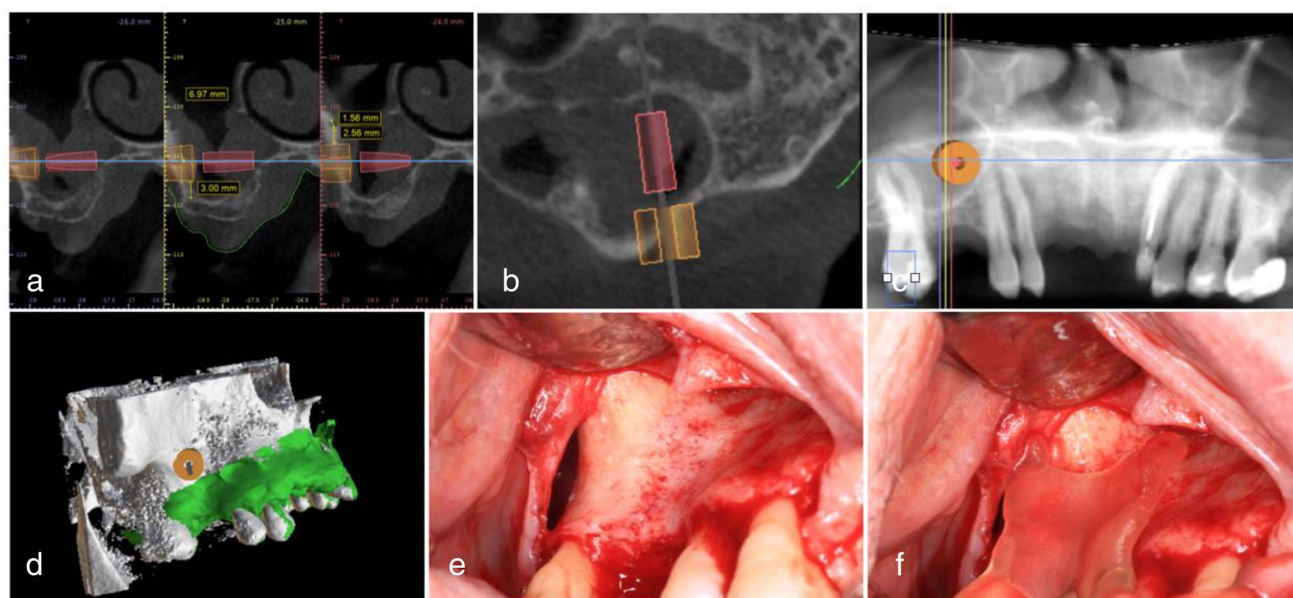


FIGURE 8. Case 3. (a) Digital planning on BlueskyBio software. (b) Sagittal view of the implant with respective tube extension. (c) Panoramic view of the tube on the sinus. (d) Digital model with the maxilla, intraoral scan, and extension tube altogether ready to be exported. (e) Lateral view of maxillary sinus area. (f) Surgical guide seated on the teeth/bone.

aims to interpret the anatomy and vital structures to maximize success. Furthermore, the limitations of the conventional surgical guides comprise the enormous size, which requires more extensive flap elevation and adequate intraoral space. Due to these limitations, prolonged operation time, increased risk of nerve damage, patient discomfort, and postoperative trauma would be expected. On the contrary, the novel surgical guide introduced in this article reduces the template size. It has easier intraoral handling, facilitating flap elevation, lessening intraoral complications, ameliorating the surgical procedure, and mitigating the patient modality field.^{8,9}

The anatomic structure of the maxillary sinus is utterly intricate. For example, the sinus septum is present in approximately 31% of patients. It has various shapes and sizes that increase the difficulty of the membrane elevation and the likelihood of Schneiderian membrane perforation.^{10,11} The most commonly reported intraoperative complications of LSFE include sinus membrane perforation and hemorrhagic events.^{12,13} Bleeding is often caused by accidental injury of associated arteries, such as the infraorbital artery, the more significant palatine artery, and the posterior superior alveolar artery, which surrounds the sinus cavity.^{14,15} Hence, achieving the accurate positioning of the lateral wall for LSFE using a surgical guide designed based on 3D images, such as CBCT, is highly recommended. By following the step-by-step digital design of the guide in this article, the occurrence of the mentioned complications can be significantly minimized. More specifically, in the third step of the presented guide-designing rubric, the anterior antral artery's location and the sinus walls' outer limits can be located. Next, the guide can be planned to preserve the vital structures in the desired position, thereby reducing iatrogenic complications. In a randomized clinical study, Osman et al¹⁶ reported a lower incidence of membrane perforations in guided LSFE vs the control group.

A combination of various computer programs aims to optimize the guide design and facilitate access to users. However, potential drawbacks to this proposed technique include the learning curve related to new technologies, including the software and devices applied, and the time required to lay out and fabricate the guide. Moreover, another limitation of our study was the nature of the case-series study. However, the demonstrated clinical scenarios substantiate the utilized techniques; further randomized case-control studies would ideally evaluate and compare the success rate of this method vs freehand augmentation. Finally, it needs to be determined if this approach would translate to multiple implant placements and sites that lack posterior teeth.

CONCLUSIONS

Within the limitations of this case-series report, a novel surgical guide allowing predictable digitally guided simultaneous LSFE and implant placement were demonstrated. The relevant digital workflow was described and supported by documentation of 3 clinical cases experiencing successful grafting and implant placement procedures. However, further studies must be performed to determine if this technique would be generalizable, as only 1 operator exists. Additionally, more investigation suggested if this method would translate to multiple implant placements and sites lacking posterior teeth.

NOTE

The authors declare no conflict of interest related to this study.

REFERENCES

1. Testori T, Tavelli L, Yu SH, et al. Maxillary sinus elevation difficulty score with lateral wall technique. *Int J Oral Maxillofac Implants.* 2020;35(3): 631–638. doi:10.11607/jomi.8034

2. Zheng X-F, Mo A-C, Zhu J-F, Wang S-P, Du Y-J, Yao Y-Z. Effect of anatomical parameters of maxillary sinus on the outcomes of transcrestal sinus lift [in Chinese]. *West China J Stomatol*. 2020;38(6):652–656.
3. Gargallo-Albiol J, Sinjab KH, Barootchi S, Chan HL, Wang HL. Microscope and micro-camera assessment of Schneiderian membrane perforation via transcrestal sinus floor elevation: a randomized ex vivo study. *Clin Oral Implants Res*. 2019;30(7):682–690.
4. Mandelaris GA, Rosenfeld AL. A novel approach to the antral sinus bone graft technique: the use of a prototype cutting guide for precise outlining of the lateral wall. A case report. *Int J Periodontics Restor Dent*. 2008;28(6):569–575.
5. Mangano F, Zecca P, Pozzi-Taubert S, et al. Maxillary sinus augmentation using computer-aided design/computer-aided manufacturing (CAD/CAM) technology. *Int J Med Robot*. 2013;9(3):331–338. doi:10.1002/rcs.1460
6. Strbac GD, Giannis K, Schnappauf A, Bertl K, Stavropoulos A, Ulm C. Guided lateral sinus lift procedure using 3-dimensionally printed templates for a safe surgical approach: a proof-of-concept case report. *J Oral Maxillofac Surg*. 2020;78(9):1529–1537. doi:10.1016/j.joms.2020.04.042
7. Goodacre BJ, Swamidass RS, Lozada J, Al-Ardah A, Sahl E. A 3D-printed guide for lateral approach sinus grafting: a dental technique. *J Prosthet Dent*. 2018;119(6):897–901. doi:10.1016/j.prosdent.2017.07.014
8. Cho SW, Yang BE, Cheon KJ, Jang WS, Kim JW, Byun SH. A simple and safe approach for maxillary sinus augmentation with the advanced surgical guide. *Int J Environ Res Public Health*. 2020;17(11):3785. doi:10.3390/ijerph17113785
9. Teixeira KN, Sakurada MA, Philippi AG, Gonçalves T. Use of a stackable surgical guide to improve the accuracy of the lateral wall approach for sinus grafting in the presence of a sinus septum. *Int J Oral Maxillofac Surg*. 2021;50(10):1383–1385. doi:10.1016/j.ijom.2021.02.023
10. Wen S-C, Chan H-L, Wang H-L. Classification and management of antral septa for maxillary sinus augmentation. *Int J Periodontics Restor Dent*. 2013;33(4):509–517.
11. Krennmair G, Ulm CW, Lugmayr H, Solar P. The incidence, location, and height of maxillary sinus septa in the edentulous and dentate maxilla. *J Oral Maxillofac Surg*. 1999;57(6):667–671.
12. Stacchi C, Andolsek F, Berton F, Perinetti G, Navarra CO, Di Lenarda R. Intraoperative complications during sinus floor elevation with lateral approach: a systematic review. *Int J Oral Maxillofac Implants*. 2017;32(3):e107–e118. doi:10.11607/jomi.4884
13. Sabri H, Sarkarat F, Mortezaagholi B, Aghajani D. Non-surgical management of oro-antral communication using platelet-rich fibrin: a review of the literature. *Oral Surg*. doi:10.1111/ors.12685
14. Yang DH, Lee NV. A simple method of managing the alveolar antral artery during sinus lift surgery. *Int J Otolaryngol Head Neck Surg*. 2021;10(3):131–146.
15. Kang SJ, Shin SI, Herr Y, Kwon YH, Kim GT, Chung JH. Anatomical structures in the maxillary sinus related to lateral sinus elevation: a cone beam computed tomographic analysis. *Clin Oral Implants Res*. 2013;24:75–81.
16. Osman AH, Mansour H, Atef M, Hakam M. Computer guided sinus floor elevation through lateral window approach with simultaneous implant placement. *Clin Implant Dent Relat Res*. 2018;20(2):137–143. doi:10.1111/cid.12559