

Choroidal Thickness in Diabetes and Diabetic Retinopathy: A Swept Source OCT Study

Wei Wang,¹ Sen Liu,² Zhihan Qiu,³ Miao He,⁴ Lanhua Wang,¹ Yuting Li,¹ and Wenyong Huang²

¹Zhongshan Ophthalmic Center, State Key Laboratory of Ophthalmology, Sun Yat-Sen University, Guangzhou, People's Republic of China

²School of Medicine, Sun Yat-sen University, Guangzhou, China

³Zhongshan School of Medicine, Sun Yat-sen University, Guangzhou, China

⁴Department of Ophthalmology, Guangdong General Hospital, Guangdong Academy of Medical Sciences, Guangzhou, People's Republic of China

Correspondence: Wenyong Huang, Department of Preventive Ophthalmology, Zhongshan Ophthalmic Center, State Key Laboratory of Ophthalmology, Sun Yat-sen University, 54S.Xianlie Road, Guangzhou, 510060, China; andyhwyz@aliyun.com.

WW and SL contributed equally and should be considered as co-first authors.

Received: October 13, 2019

Accepted: March 1, 2020

Published: April 23, 2020

Citation: Wang W, Liu S, Qiu Z, et al. Choroidal thickness in diabetes and diabetic retinopathy: a swept source OCT study. *Invest Ophthalmol Vis Sci.* 2020;61(4):29. <https://doi.org/10.1167/iovs.61.4.29>

PURPOSE. Previous studies on the association between choroidal thickness (CT) and severity of diabetic retinopathy (DR) gave conflicting results. The aim of this study was to evaluate the CT changes in diabetic patients and associated factors in a large sample of Chinese patients with diabetes.

METHODS. Type 2 diabetes mellitus patients without history of ocular treatment were recruited from the community health system in Guangzhou, China. The swept source OCT instrument was used to obtain high-definition retina and choroid images. The diabetic retinopathy (DR) status was graded based on the guidelines of the United Kingdom National Diabetic Eye Screening Programme. Univariate and multivariate linear regression analyses was used to explore the association of CT with DR severity, diabetic macular edema (DME), hemoglobin A1c, and vision function.

RESULTS. A total of 1347 patients were included in the final analysis. After adjusting for other factors, the patients with stage R3 DR had significantly thinner CT ($\beta = -29.1 \mu\text{m}$, 95% CI -53.8 to -4.4 , $P = 0.021$) in comparison in those with R0. After adjusting for other factors, the CTs were thicker than those in R0 patients with difference of $15.6 \mu\text{m}$ (95% CI 4.3 - 26.9 , $P = 0.007$) for outer nasal sector, $15.7 \mu\text{m}$ (95% CI 3.8 - 25.5 , $P = 0.008$) for outer inferior, and $12.2 \mu\text{m}$ (95% CI 0.4 - 24.0 , $P = 0.042$) for inner inferior sector. The presence of DME and hemoglobin A1c levels did not significantly affect average CT. Higher average CT was significantly associated with better best corrected visual acuity, with a -0.02 LogMAR unit per $100 \mu\text{m}$ increase in average CT (95% CI -0.03 to -0.01 , $P < 0.001$).

CONCLUSIONS. CT increased in the early stage of DR, and further decreased with DR progression. DME was not significantly associated with CT. These findings provide more clues to suggest that choroid alterations play a role in the pathogenesis of DR.

Keywords: diabetes mellitus, swept source optical coherence tomography, choroidal thickness, Chinese, community

Diabetic retinopathy (DR) is the leading cause of visual impairment in working-age adults in industrialized countries.¹ Globally, 145 million adults have DR and the number is estimated to reach 224 million by 2040.² With the popularization of the western lifestyle and population aging, DR is becoming a worldwide public health challenge as well as an economic burden. The pathogenesis of DR is not fully understood, and recent clinical and experimental studies suggested that the choroidal alteration might contribute to the presence and progression of DR.^{3,4}

Choroidal thickness (CT) has been an important index for the quantification of choroidal structure. With the introduction of enhanced depth imaging combined with spectral domain optical coherence tomography (EDI SD-OCT), it is possible to measure CT in vivo.^{5,6} A number of studies

have evaluated CT in DR using EDI SD-OCT, but the results have been controversial. Some studies reported higher CT in DR than in controls, whereas other studies reported a decrease in CT with increased DR severity or a lack of significant correlation between CT and DR.⁷⁻¹⁰ The influence of diabetic macular edema (DME) and hemoglobin A1c (HbA1c) on CT were also unclear.^{9,11-14} The discrepancies in the results of previous studies may be related to the limitations of EDI SD-OCT and/or the inclusion of heterogeneous patients in individual study.¹⁵ The EDI SD-OCT measured CT at single point manually or semiautomatically based on blurred choroid-scleral interface, which introduces measurement bias. Most of the aforementioned studies included both treated and treatment-naïve patients, but ocular and systemic interventions have been shown to affected CT significantly,



including retinal laser photocoagulation, anti-VEGF treatment, and hemodialysis.^{16–21}

Swept source OCT (SS-OCT) is a novel modality with higher resolution and speed than EDI SD-OCT for choroidal imaging.²² The dispersion caused by the retinal pigment epithelium is reduced by using a longer laser wavelength (1050 nm) in SS-OCT scans, which provides a clearer boundary of the choroid-scleral interface. In addition, the automatic measurement, high imaging speed (100,000 A scans/s), and three-dimensional (3D) reconstruction of regional imaging result in more reproducible and reliable measurements of CT. We are not aware of any study that investigated changes to CT in Chinese patients with diabetes mellitus (DM) using SS-OCT. Therefore, the objectives of this study were to evaluate the CT changes in diabetic patients with or without DR of varying severity, to determine the independent influence of DME and HbA1c on CT, and to investigate the relationship between CT and vision function in a large sample of Chinese patients with DM.

MATERIALS AND METHODS

Participants

This cross-sectional study was performed at the Zhongshan Ophthalmic Centre (ZOC), Sun Yat-sen University, Guangzhou, China. The study protocol was approved by the Institute Ethics Committee of ZOC. The study was performed according to the tenets of the Helsinki Declaration. All participants gave written informed consent before entering the study. Guangzhou is the largest city in Southern China and all patients with DM are required to register in the community health system. Patients with DM from communities near the ZOC were recruited for this study. The inclusion criteria for our study participants were as follows: (1) type 2 DM and aged 30 to 80 years, (2) no history of ocular treatment (ocular treatment naïve), (3) visual acuity of 0.1 or more and able to complete an eye examination, (4) spherical degree of >-6 diopters (D), astigmatism of <1.5 D, and axial length (AL) of <26 mm. Participants were excluded in the presence of any of the following conditions: (1) history of serious systemic diseases other than diabetes, such as uncontrolled hypertension, serious cardiovascular and cerebrovascular diseases, malignant tumor, or nephritis; (2) history of systemic surgery, thrombolysis therapy, or renal dialysis; (3) glaucoma, vitreous-macular diseases (vitreous hemorrhage and retinal detachment), or amblyopia; (5) history of retinal laser or intraocular injection, glaucoma surgery, cataract surgery, or corneal refractive surgery; and (6) poor quality of fundus or OCT images resulting from abnormal refractive media (such as moderate to severe cataract, corneal ulcer, or severe pterygium, signal strength index (SSI) for OCT imaging ≤ 50), poor fixation or other causes.

General Information and Laboratory Tests

General information including age, sex, duration of diabetes, medication compliance, other systemic chronic diseases, and lifestyle data was collected via standardized questionnaires. Height, waist circumference, systolic blood pressure (SBP), and diastolic blood pressure (DBP) were measured by an experienced nurse. Blood and urine samples were obtained from all participants, and the following laboratory parameters were determined by standardized methods: serum

creatinine, HbA1c, total cholesterol, high-density lipoprotein cholesterol, low-density lipoprotein cholesterol, triglyceride, C-reactive protein, and microalbuminuria.

Ocular Examination

Comprehensive ocular examinations were conducted for all participants. The anterior and posterior segments were evaluated by slit lamp biomicroscopy and ophthalmoscopy. The uncorrected and best corrected visual acuity (BCVA) was measured by Early Treatment Diabetic Retinopathy Study (ETDRS) LogMAR E charts (Precision Vision, Villa Park, IL). The visual impairment (VI) was stratified by World Health Organization criteria: no VI group for patients with BCVA better than 0.5 logMAR, mild VI group for patients with $0.3 \log\text{MAR} \leq \text{BCVA} \leq 0.5 \log\text{MAR}$, mild-to-severe VI group for patients with BCVA worse than 0.3 logMAR.²³ The intraocular pressure was measured by using a noncontact tonometer (Topcon CT-80A, Topcon, Tokyo, Japan). The ocular biometric parameters were obtained using optical low-coherence reflectometry (Lenstar LS900; Haag-Streit AG, Koeniz, Switzerland), including central corneal thickness, anterior chamber depth, lens thickness, and axial length (AL). Refractory errors were measured by an autorefractor (KR8800; Topcon) after pupil dilation. Standardized seven-field color retinal images adhering to ETDRS criteria were obtained by a digital fundus camera (Canon CR-2, Tokyo, Japan) after full pupil dilation. Three trained personnel independently graded the retinal images according to the guidelines of the United Kingdom National Diabetic Eye Screening Programme. For the disagreement among the graders, another retinal expert reviewed the images and made the final diagnosis. DR severity was graded as R0, R1, R2, or R3. DME was graded as M0 (no maculopathy) or M1 (exudate within one disc diameter of the fovea, or a collection of exudates within the macula) (Supplementary Table S1).²⁴

SS-OCT Imaging

The SS-OCT (DRI-OCT-2 Triton; Topcon) instrument was used to obtain high-definition retina and choroid images. This device has the speed of 100,000 A scans/s and yields an 8- μm axial resolution in tissue. The 3D imaging scans were obtained using the 7×7 mm raster scan protocol centered on the macula. The resultant images were analyzed by the automated layer segmentation software, which is built into the SS-OCT system. The CT in the nine subfields defined by the ETDRS were automatically calculated and displayed. The ETDRS grid divides the macula into two rings, inner and outer, at 1 to 3 mm and 3 to 6 mm, respectively. The individual grids are referred to as the central field, inner superior, inner nasal, inner inferior, inner temporal, outer superior, outer nasal, outer inferior, and outer temporal (Fig. 1). In addition, the average CT in all nine grids were calculated. All OCT scans were performed by the same experienced technician who was blind to the study protocol. Before the scan was conducted, it was verified that none of the patients had consumed drinks with caffeine or alcohol or had taken analgesic medications for at least 24 hours before the procedure. Only subjects with eligible images (i.e., image quality [SSI] >50 , without eye movement, without artefacts and without segmentation failure) were included in the study. Two experienced investigators reviewed each line of both RPE and the chorio-scleral border in all images of the 3D data set

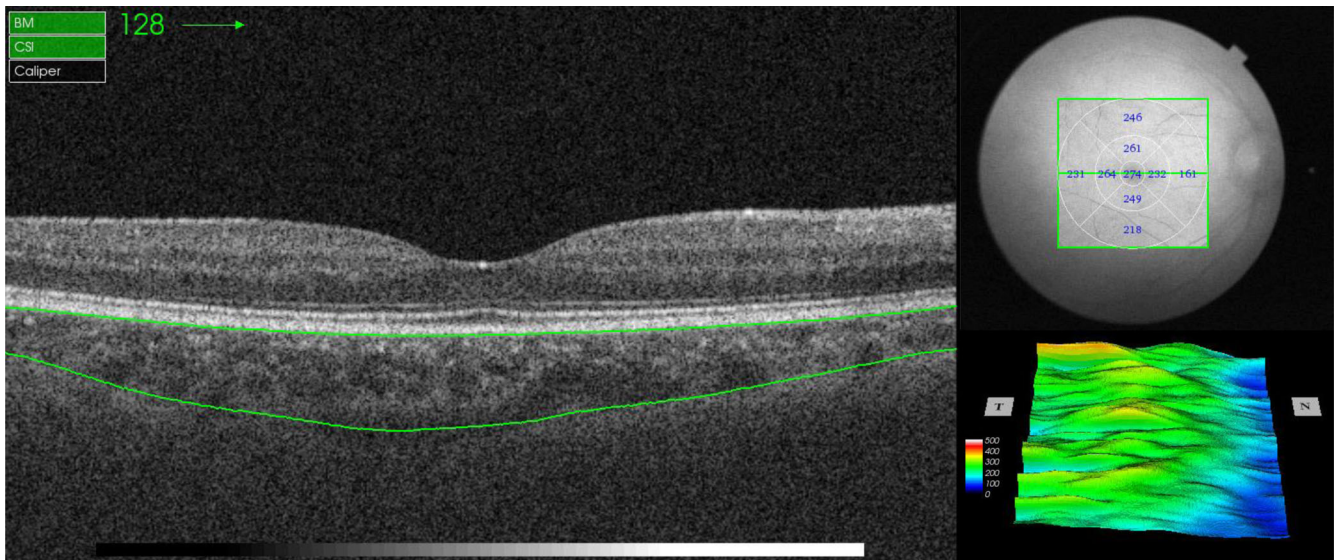


FIGURE 1. Illustration of choroidal thickness measurement in EDTRS 9 sectors by using SS-OCT. The individual grids are referred to as the central field, inner superior, inner nasal, inner inferior, inner temporal, outer superior, outer nasal, outer inferior, and outer temporal.

to confirm correct segmentation; otherwise, manual adjustments were performed.

Statistical Analyses

Only data of one eye were used for statistical analysis: the worse eye was adopted in patients with different DR gradings in both eyes, and the right eye was adopted in patients with the same DR gradings in both eyes. The Kolmogorov-Smirnov test was carried out to verify the normal distribution. When normality was confirmed, the *t* test was conducted to evaluate the inter-group difference of demographic, systemic, and ocular parameters. Fisher's exact test was used for categorical variables. Bivariate scatter plots were made to display the potential factors affecting CT. Linear regression analysis was performed to assess the association of CT with DR and other parameters, such as DME, BCVA, HbA1c, and so on. Our previous studies have confirmed that macular CT was significantly associated with age, sex, and AL.^{5,6,25} The univariate analysis showed that the predictive variables were significant, which were then entered in the multivariate equation. Thus, the multivariate model 1 investigated the relationship between CT, and DR, DME, and HbA1c after adjusting for age, sex, and AL. The multivariate model 2 further adjusted for diabetes duration, body mass index, SBP, DBP, cholesterol, and HbA1c levels. A *P* value of <0.05 was considered statistically significant. All analyses were performed using Stata Version 14.0 (Stata Corporation, College Station, TX).

RESULTS

Demographic and Clinical Features of the Participants

This study initially enrolled 1454 eligible patients, and 107 patients were excluded from the statistical analysis after reviewing the OCT scans due to the following reasons: 17 for SSI <50, 16 for severe artifacts, 18 for movement defect, 12 for segmentation failure, and 44 for segmentation errors

and impossible correction manually and accurately. Therefore, a total of 1347 (92.6%) patients were included in the final analysis. Table 1 shows the basic demographic and clinical features of the participants. Among of them, 785(58.28%) patients were female, the average age was 64.5 ± 7.8 years, the average duration of diabetes was 8.9 ± 7.1 years. Of the 1080 patients (80.18%) without DR, 651(60.28%) were female and the average age was 64.5 ± 7.8 years. Of the 267 patients (19.82%) with DR, 134 (50.19%) were female, and the average age was 64.3 ± 7.6 years. Participants with DR were more likely to be male, had longer diabetes duration, higher HbA1c, and greater SBP (all *P* < 0.05). In addition, patients with DR had higher serum creatinine, higher microalbuminuria, poor BCVA, and lower AL (all *P* < 0.05) compared to those without DR. The other parameters were similar between the DR patients and non-DR patients, including the age, body mass index, DBP, cholesterol, triglycerides, uric acid, C-reactive protein, intraocular pressure, and central corneal thickness (all *P* > 0.05).

Distribution of Choroidal and Retinal Thickness in Macula

Table 2 represents the CT and retinal thickness of participants. The average CT was 189.2 ± 72.6 μ m for all the participants, 187.6 ± 72.5 μ m for patients without DR, and 195.4 ± 72.9 μ m for DR patients (*P* = 0.115). Among of measurements in nine subregions, the CT showed a trend toward higher values in DR patients, but only CT in outer nasal region (*P* = 0.015) and outer inferior region (*P* = 0.029) achieved statistical significance. In terms of RT, the average RT of DR patients was significantly thicker than those without DR (280.1 ± 25.4 μ m vs 274.4 ± 17.3 μ m, *P* < 0.001). Patients with DR had significantly thicker retina in the outer superior, outer temporal, inner temporal, central field, inner inferior, and outer inferior regions compared with those without DR (all *P* < 0.05). Figure 2 shows the CT in different stages of DR and with or without DME. The average CT became thicker in patients in the early stage of DR, and then

TABLE 1. Demographic and Clinical Features of the Included Participants

Characteristics	Overall	Non-DR	Any-DR	P Value
No. of subjects	1347	1080 (80.18%)	267 (19.82%)	-
Female, %	785 (58.28%)	651 (60.28%)	134 (50.19%)	0.003
Mean age, year	64.5 ± 7.8	64.5 ± 7.8	64.3 ± 7.6	0.670
Duration of diabetes, year	8.9 ± 7.1	8.3 ± 6.8	11.4 ± 7.7	<0.001
HbA1c, %	6.9 ± 1.4	6.8 ± 1.3	7.6 ± 1.8	<0.001
Body mass index, kg/m ²	24.7 ± 3.3	24.8 ± 3.3	24.3 ± 3.2	0.037
Systolic blood pressure, mm Hg	134.8 ± 18.8	133.9 ± 18.5	138.5 ± 19.9	<0.001
Diastolic blood pressure, mm Hg	70.5 ± 10.5	70.6 ± 10.4	70.2 ± 11.0	0.601
Total cholesterol, mmol/L	4.8 ± 1.0	4.8 ± 1.0	4.8 ± 1.1	0.719
Serum creatinine, μmol/L	71.5 ± 21.8	70.3 ± 19.8	76.2 ± 27.8	<0.001
High-density lipoprotein cholesterol, mmol/L	1.3 ± 0.4	1.3 ± 0.4	1.3 ± 0.4	0.916
Low-density lipoprotein cholesterol, mmol/L	3.1 ± 0.9	3.1 ± 0.9	3.1 ± 0.9	0.833
Triglycerides, mmol/L	2.3 ± 1.7	2.3 ± 1.7	2.3 ± 1.7	0.608
Serum uric acid, μmol/L	366.3 ± 97.8	368.4 ± 96.0	357.7 ± 104.4	0.108
C-reactive protein, mg/L	2.6 ± 6.9	2.7 ± 7.3	2.5 ± 5.1	0.773
Microalbuminuria, mg/mL	5.4 ± 17.9	4.2 ± 15.1	10.3 ± 26.0	<0.001
BCVA, logMAR	0.22 ± 0.13	0.22 ± 0.13	0.24 ± 0.14	0.018
Intraocular pressure, mm Hg	16.2 ± 2.7	16.1 ± 2.7	16.2 ± 2.8	0.844
Central corneal thickness, μm	546.4 ± 31.2	545.8 ± 31.2	548.5 ± 31.0	0.211
Axial length, mm	23.4 ± 0.9	23.4 ± 0.9	23.3 ± 0.9	0.005

Data are expressed as the mean ± SD or %.
Bold indicates statistical significance.

TABLE 2. Distribution of Choroidal and Retinal Thickness by DR Status

Parameters	Overall	Non-DR	Any-DR	P Value
Choroidal thickness				
Outer superior, μm	196.1 ± 74.2	195.0 ± 73.8	200.8 ± 76.0	0.255
Inner superior, μm	206.3 ± 79.3	205.4 ± 79.5	209.7 ± 78.7	0.432
Outer temporal, μm	177.0 ± 64.5	176.1 ± 64.0	180.6 ± 66.3	0.318
Inner temporal, μm	199.4 ± 73.2	198.5 ± 73.3	203.2 ± 72.6	0.355
Central field, μm	207.1 ± 81.9	205.7 ± 82.7	212.6 ± 78.8	0.219
Inner nasal, μm	195.0 ± 84.6	193.3 ± 84.9	201.7 ± 83.6	0.146
Outer nasal, μm	155.9 ± 81.1	153.2 ± 79.3	166.7 ± 87.5	0.015
Inner inferior, μm	193.6 ± 83.9	191.4 ± 83.3	202.5 ± 85.9	0.053
Outer inferior, μm	171.7 ± 78.6	169.4 ± 77.8	181.1 ± 81.4	0.029
Average MCT, μm	189.2 ± 72.6	187.6 ± 72.5	195.4 ± 72.9	0.115
Retinal thickness				
Outer superior, μm	267.0 ± 20.5	266.0 ± 19.2	270.9 ± 24.9	<0.001
Inner superior, μm	302.3 ± 22.3	301.6 ± 20.6	304.8 ± 28.3	0.041
Outer temporal, μm	254.1 ± 21.8	251.4 ± 19.1	264.8 ± 28.1	<0.001
Inner temporal, μm	290.6 ± 25.0	288.8 ± 22.9	298.0 ± 30.8	<0.001
Central field, μm	230.5 ± 33.2	228.6 ± 29.6	238.3 ± 44.0	<0.001
Inner nasal, μm	300.5 ± 23.9	300.4 ± 21.3	301.1 ± 32.4	0.685
Outer nasal, μm	280.1 ± 21.1	280.3 ± 18.6	279.3 ± 29.1	0.472
Inner inferior, μm	298.3 ± 22.4	297.2 ± 20.1	302.9 ± 29.5	<0.001
Outer inferior, μm	257.0 ± 19.1	255.8 ± 17.3	261.7 ± 24.8	<0.001
Average RT, μm	275.6 ± 19.3	274.4 ± 17.3	280.1 ± 25.4	<0.001

Bold indicates statistically significant.

became thinner in patients with severe DR. DR patients at stage R3 had significantly thinner CT in comparison with non-DR patients, with or without DME.

Association of Choroidal Thickness and Diabetes-Related Parameters

Table 3 shows the relationship between CT and diabetes-related parameters. After adjusting for age, sex, and AL, the patients with stage R3 DR had significantly thinner CT ($\beta = -36.9 \mu\text{m}$, 95% CI -61.1 to -12.7 , $P = 0.003$) compared

with those with R0. Further adjusting for other factors gave persistent results, with thinning CT in R3 patients ($\beta = -29.1 \mu\text{m}$, 95% CI -53.8 to -4.4 , $P = 0.021$). The presence of DME did not significantly affect average CT. Similarly, the HbA1c levels did not influence average CT after adjusting for other factors.

Table 4 shows the correlations between CT in nine subregions and DR by DME status. The CT of patients with stage R3 DR decreased significantly in all subregions after adjusting for age, sex, and AL (all $P < 0.05$). When we further adjusted for other factors, the differences in CT remained

TABLE 3. Associations of Average Macular Choroidal Thickness with Diabetic-Related Parameters

Average MCT	Model 1*		Model 2†	
	β (95% CI)	P	β (95% CI)	P
Diabetic retinopathy				
R1 vs R0	6.2 (−3.4 to 15.9)	0.207	9.4 (−0.6 to 19.5)	0.066
R2 vs R0	−18.1 (−41.2 to 5.0)	0.124	−11.1 (−35.3 to 13.1)	0.368
R3 vs R0	−36.9 (−61.1 to −12.7)	0.003	−29.1 (−53.8 to −4.4)	0.021
Diabetic macular edema				
Present vs nonpresent	−7.3 (−23.1 to 8.4)	0.362	−3.7 (−19.7 to 12.2)	0.645
HbA1c				
Quartile 2 vs quartile 1	0.2 (−9.3 to 9.7)	0.966	2.0 (−7.8 to 11.7)	0.690
Quartile 3 vs quartile 1	1.9 (−7.9 to 11.7)	0.706	4.9 (−5.3 to 15.0)	0.348
Quartile 4 vs quartile 1	−8.5 (−18.2 to 1.2)	0.086	−6.5 (−16.9 to 3.8)	0.217

* Adjusted for age, sex, and axial length.

† Further adjusted for diabetes duration, body mass index, systolic blood pressure, diastolic blood pressure, cholesterol, and/or not HbA1c level.

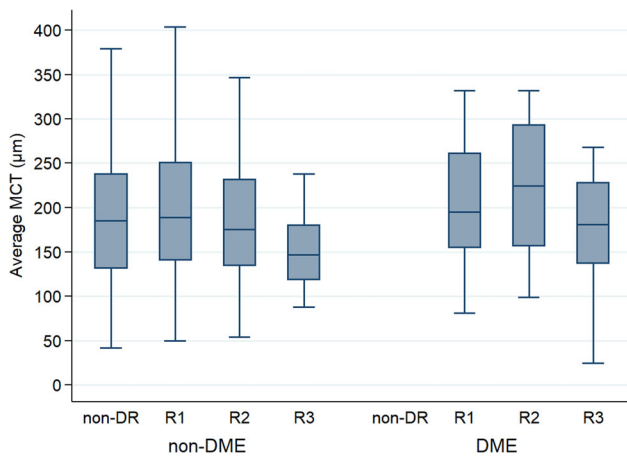


FIGURE 2. Box-plot showing the distribution of average MCT in diabetic patients with and without retinopathy by DME status. MCT, macular choroidal thickness.

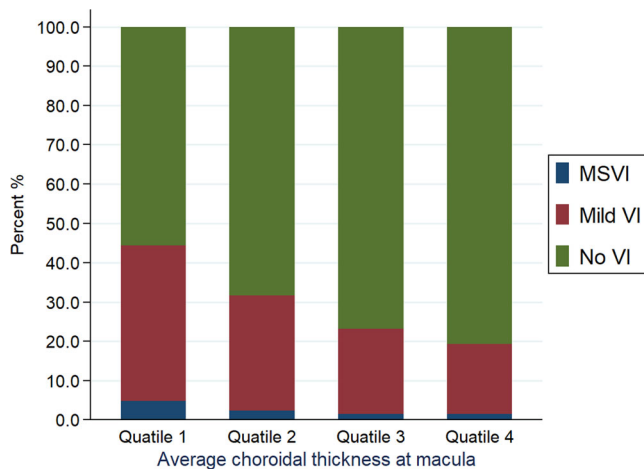


FIGURE 3. Percent bar graph showing the relationship between macular choroidal thickness and visual impairment.

significant in central field, outer superior, outer nasal, inner superior, inner nasal, and inner temporal regions. Compared with R0 patients, the R1 patients had a thicker CT in each EDTRS sector, and the difference in CT in the outer nasal,

outer inferior, and inner inferior sectors were statistically significant. After adjusting for other factors, the CT in outer nasal sector in R1 patients was 15.6 μm thicker than that in R0 patients (95% CI 4.3-26.9, $P = 0.007$). For outer inferior and inner inferior, the CTs in R1 patients were thicker than those in R0 patients, with differences of 15.7 μm (95% CI 3.8-25.5, $P = 0.008$) and 12.2 μm (95% CI 0.4-24.0, $P = 0.042$).

Association Between Choroidal Thickness and BCVA

Figure 3 shows the percentage of different VI stratified by CT quartile. The percentage of patients with no VI increased as the average CT thickened, whereas the percentage of patients with mild VI and mild-to-severe VI reduced as CT increased. Table 5 presents the results of univariate and multivariate regression analyses. Both higher average CT and central CT were significantly associated with better BCVA, with a -0.02 LogMAR unit per 100- μm increase in average CT (95% CI -0.03 to -0.01 , $P < 0.001$) and a -0.015 LogMAR unit per 100 μm increase in central CT (95% CI -0.024 to -0.006 , $P = 0.001$), respectively.

DISCUSSION

The choroid is one of the most metabolically active tissues in the human body. Abnormal CT has been implicated in glaucoma and many retinal diseases, but results for DR have been controversial.^{3,4} This study used the latest SS-OCT to investigate the association of CT with DR and diabetic-related parameters in a large community-based sample. The results revealed that the CT had a tendency to increase in the early stages of DR, and then to decrease as DR progressed. Both DME and HbA1c had mild impacts on CT. A larger CT was strongly associated with better BCVA independently of confounding factors such as age, sex, AL, and other factors.

Previous studies on the association between CT and DR severity gave conflicting results. Some studies reported that the CT in DR patients become thin. For example, Lains et al.¹⁰ demonstrated that CT in their proliferative DR group was thinner compared with controls. Horváth et al.²⁶ and Ambiya et al.²⁷ revealed that decreasing CT correlated with the severity of DR. However, other studies reported CT thickening or no change with presence of DR. For example, Tavares et al.⁹

TABLE 4. The Changes of Choroidal Thickness in each EDTRS Sector Among Patients with Different Severity of Diabetic Retinopathy

	Model 1*		Model 2†	
	OR (95% CI)	P	OR (95% CI)	P
Central field, μm				
R1 vs R0	4.6 (−6.5 to 15.7)	0.421	8.4 (−3.2 to 19.9)	0.154
R2 vs R0	−16.7 (−43.3 to 9.8)	0.216	−8.4 (−36.2 to 19.4)	0.554
R3 vs R0	−43.9 (−71.7 to −16.1)	0.002	−34.9 (−63.3 to −6.5)	0.016
DME vs non-DME	−11.8 (−29.9 to 6.3)	0.201	−7.5 (−25.9 to 10.8)	0.421
Outer superior, μm				
R1 vs R0	4.9 (−5.1 to 15.0)	0.335	7.9 (−2.5 to 18.4)	0.138
R2 vs R0	−18.1 (−42.1 to 5.9)	0.140	−12.9 (−38.1 to 12.4)	0.318
R3 vs R0	−37.0 (−62.1 to −11.8)	0.004	−30.6 (−56.3 to −4.8)	0.020
DME vs non-DME	−8.5 (−24.9 to 7.9)	0.307	−5.7 (−22.3 to 11.0)	0.504
Outer inferior, μm				
R1 vs R0	11.4 (1.0 to 21.9)	0.032	14.7 (3.8 to 25.5)	0.008
R2 vs R0	−22.3 (−47.3 to 2.7)	0.081	−14.8 (−41.0 to 11.3)	0.267
R3 vs R0	−26.9 (−53.1 to −0.8)	0.044	−18.5 (−45.2 to 8.2)	0.173
DME vs non-DME	−3.1 (−20.1 to 14.0)	0.725	0.04 (−17.2 to 17.3)	0.997
Outer nasal, μm				
R1 vs R0	12.3 (1.5-23.1)	0.026	15.6 (4.3-26.9)	0.007
R2 vs R0	−16.3 (−42.2 to 9.6)	0.217	−7.0 (−34.1 to 20.2)	0.614
R3 vs R0	−36.2 (−63.3 to −9.0)	0.009	−28.1 (−55.8 to −0.3)	0.047
DME vs non-DME	6.4 (−11.3 to 24.1)	0.479	10.0 (−7.9 to 28.0)	0.272
Outer temporal, μm				
R1 vs R0	3.4 (−5.4 to 12.3)	0.448	5.9 (−3.4 to 15.1)	0.216
R2 vs R0	−17.2 (−38.4 to 4.1)	0.113	−13.8 (−36.1 to 8.5)	0.226
R3 vs R0	−28.5 (−50.8 to −6.2)	0.012	−22.8 (−45.6 to 0.03)	0.050
DME vs non-DME	−14.5 (−28.9 to 0.03)	0.050	−12.1 (−26.8 to 2.6)	0.106
Inner superior, μm				
R1 vs R0	2.8 (−8.0 to 13.6)	0.615	5.8 (−5.4 to 17.1)	0.309
R2 vs R0	−18.8 (−44.6 to 7.0)	0.153	−13.4 (−40.6 to 13.7)	0.332
R3 vs R0	−46.7 (−73.8 to −19.7)	0.001	−39.1 (−66.8 to −11.4)	0.006
DME vs non-DME	−11.5 (−29.1 to 6.2)	0.203	−7.5 (−25.4 to 10.4)	0.412
Inner inferior, μm				
R1 vs R0	9.1 (−2.1 to 20.4)	0.112	12.2 (0.4 to 24.0)	0.042
R2 vs R0	−20.9 (−47.8 to 6.1)	0.129	−12.6 (−41.0 to 15.7)	0.381
R3 vs R0	−35.4 (−63.7 to −7.2)	0.014	−27.0 (−55.9 to 1.9)	0.067
DME vs non-DME	−4.1 (−22.4 to 14.3)	0.666	−0.3 (−19.0 to 18.3)	0.972
Inner nasal, μm				
R1 vs R0	6.0 (−5.3 to 17.3)	0.301	9.8 (−1.9 to 21.6)	0.102
R2 vs R0	−19.0 (−46.0 to 8.1)	0.170	−9.7 (−38.1 to 18.6)	0.501
R3 vs R0	−43.6 (−71.9 to −15.2)	0.003	−34.2 (−63.1 to −5.2)	0.021
DME vs non-DME	−6.0 (−24.5 to 12.4)	0.521	−1.4 (−20.1 to 17.4)	0.887
Inner temporal, μm				
R1 vs R0	1.6 (−8.5 to 11.6)	0.760	4.7 (−5.7 to 15.2)	0.377
R2 vs R0	−12.8 (−36.9 to 11.2)	0.297	−6.3 (−31.5 to 18.9)	0.625
R3 vs R0	−34.0 (−59.2 to −8.8)	0.008	−26.2 (−51.9 to −0.5)	0.046
DME vs non-DME	−12.4 (−28.8 to 3.9)	0.136	−8.8 (−25.4 to 7.7)	0.296

* Adjusted for age, sex, and axial length.

† Further adjusted for diabetes duration, body mass index, systolic blood pressure, diastolic blood pressure, cholesterol, and HbA1c levels. Bold indicates statistically significant.

reported a thickening CT in diabetic patients without DR. The population-based Beijing Eye Study found that the DM was independently associated with a thicker CT, while the DR was not related to the CT.⁷ Our present study found that a thicker CT in stage R1, but a thinner CT in stage R3, relative to stage R0, which may partly explain the aforementioned discrepancies. Our investigation of different stages of DR could explain the mixed results in previous studies. DM may act as an independent factor leading to choroid thickening, and subsequent DR progression may lead to the reduction of CT, which may appear as a thicker CT at the initial stage of DR and thinning with DR progression.

The CT did not differ between patients with or without DME. Using EDI SD-OCT, Querques et al.¹⁴ and Regatieri et al.²⁸ reported that the CT was significantly reduced in patients with DME. Kim et al.¹³ demonstrated that the subfoveal CT increased significantly in patients with type 2 DM. However, Vujosevic et al.²⁹ found no association between CT and DME, which is consistent with our results. Our study adopted SS-OCT, a more novel and accurate method, which supports the conclusion. However, the majority of the participants in our study were patients without DR (80.18%), and thus the sample size of DME is small. Further studies with more DME are needed to confirm our findings.

TABLE 5. The Relationship Between Average Macular Choroidal Thickness and Best-Corrected Visual Acuity in Diabetic Patients

MCT and BCVA (logMAR)	β (95% CI)			P Value
	Estimate	Lower	Upper	
Univariable model				
Average MCT (per 100- μ m increase)	-0.04	-0.05	-0.03	<0.001
Central field MCT (per 100- μ m increase)	-0.03	-0.04	-0.02	<0.001
Age, sex, and AL adjusted model				
Average MCT (per 100- μ m increase)	-0.02	-0.03	-0.01	0.001
Central field MCT (per 100- μ m increase)	-0.01	-0.02	-0.004	0.005
Multivariable adjusted model*				
Average MCT (per 100- μ m increase)	-0.02	-0.03	-0.01	<0.001
Central field MCT (per 100- μ m increase)	-0.015	-0.024	-0.006	0.001

* Adjusted for age, sex, AL, diabetes duration, body mass index, systolic blood pressure, diastolic blood pressure, cholesterol, and HbA1c levels.

Bold indicates statistically significant.

The influence of HbA1c on CT is still in discussion, which has not been adjusted in most previous CT studies. Unsal et al.³⁰ and Kim et al.¹³ found a significant correlation between HbA1c and CT, indicating that HbA1c may be a confounding parameter. The Beijing Eye Study reported that the glucose level did not affect subfoveal CT, but HbA1c was not determined in that study. Sahinoglu-Keskek et al.³¹ found no correlation between HbA1c and subfoveal CT. Our study confirmed that macular CT was not independently associated with HbA1c. Jonas et al.³² reported that subfoveal CT was significantly associated with BCVA after adjusting for age, sex, AL, and corneal curvature in the normal population. This study further demonstrated that thicker CT was independently associated with better BCVA in diabetic patients. Therefore, the CT may be a biomarker for visual function in DM patients.

The choroid provides the outer layer of retina and the retinal pigment epithelium with oxygen and nutrients. Thus, CT might indirectly reflect the metabolic state of the retina and choroidal circulation. The mechanism of CT alterations in DR remains unclear. Multiple mechanisms may contribute to choroidal thickening in the early stage of DR. First, the thickening of the choroid in the early stage may be related to choroidal swelling secondary to DM, which implies the beginning of diabetic choroidopathy. Diabetic choroidopathy may result in RPE dysfunction, and affect vascular permeability.³³ The increased choriocapillaris permeability leads to choroidal thickening. Second, the overexpression of cytokines activated by inflammation, oxidative stress, angiogenesis in early DR may contribute to the thickening of the choroidal layer, such as monocyte chemoattractant protein-1, platelet-derived growth factor, VEGF, insulin-like growth factor 1, pigment epithelium-derived factor, and cxc motif chemokine ligand 13.³⁴ It was reported that these cytokines were significantly associated with choroidal thickening.³⁴⁻³⁸ Third, the choroid accounts for 85% of ocular blood flow, autonomic nervous system was considered to be important for autoregulation of choroidal blood flow. In early stage of DR, the sympathetic innervation was activated and led to higher choroidal circulation, which subsequently increased the choroidal thickness. Savage et al. reported that the pulsatile ocular blood flow increased in DR eyes compared with controls using a computerized pneumotonometer. However, hypoxia plays a dominant role with the DR progression to late stage.¹⁴ Thinning of the choroid suggests a decrease in blood flow, and thus thinning of the

choroid may be associated with hypoxia in the retinal tissue. However, further experimental studies are needed to determine whether choroidal thinning was primary or secondary to retinal ischemia.

This study has several important strengths. First, a large sample of DM patients with no history of ocular treatment were included in this study. Second, the latest available technology, SS-OCT, was adopted, which has higher resolution and more accuracy for CT measurement than EDI SD-OCT.³⁹ Finally, we adjusted for a variety of confounding factors, including serum creatine, which has been broadly neglected before. This study has some limitations. First, the nature of the cross-sectional design prevents cause-and-effect inference. Further longitudinal cohort studies are warranted. Second, the patients consist of Chinese patients with type 2 diabetes, and the generalization of the results to other ethnicities and to type 1 diabetes should be taken with caution. Third, a well-defined choroid-scleral junction is a prerequisite for accurate CT measurements. Several posterior boundaries of CT were proposed, and CT measurements can be substantially affected by the visibility of choroid-scleral interface (CSI).⁴⁰⁻⁴⁴ It was reported that automated outer choroidal boundary segmentation tends to identify the posterior limit of the choroidal vessel by SS-OCT.⁴⁰ Two investigators reviewed all the OCT scans, made correction when needed, and excluded images without clear choroid-scleral junction. However, the systematic errors could not be completely excluded due the wave length of the SS-OCT.

CONCLUSIONS

In summary, this study demonstrated that CT increased in the early stage of DR, and further decreased with DR progression. DME was not significantly associated with CT. A thicker CT was independently related to better BCVA. These findings provide more clues to suggest that choroid alterations may be a potential pathway in the pathogenesis of DR. Further studies are warranted to elucidate the possible mechanism behind our findings.

Acknowledgments

Supported by the National Natural Science Foundation of China (81570843; 81530028; 81721003) and the Guangdong Province Science & Technology Plan (2014B020228002).

The funding organizations had no role in the design or conduct of the study; collection, management, analysis, and interpretation of the data; preparation, review, or approval of the manuscript; and decision to submit the manuscript for publication.

Disclosure: **W. Weng**, None; **S. Liu**, None; **Z. Qiu**, None; **M. He**, None; **L. Wang**, None; **Y. Li**, None; **W. Huang**, None

References

- Leasher JL, Bourne RR, Flaxman SR, et al. Global estimates on the number of people blind or visually impaired by diabetic retinopathy: a meta-analysis from 1990 to 2010. *Diabetes Care*. 2016;39:1643–1649.
- Yau JW, Rogers SL, Kawasaki R, et al. Global prevalence and major risk factors of diabetic retinopathy. *Diabetes Care*. 2012;35:556–564.
- Campos A, Campos EJ, Martins J, Ambrosio AF, Silva R. Viewing the choroid: Where we stand, challenges and contradictions in diabetic retinopathy and diabetic macular oedema. *Acta Ophthalmol*. 2017;95:446–459.
- Melancia D, Vicente A, Cunha JP, Abegao PL, Ferreira J. Diabetic choroidopathy: a review of the current literature. *Graefes Arch Clin Exp Ophthalmol*. 2016;254:1453–1461.
- Wang W, Zhang X. Choroidal thickness and primary open-angle glaucoma: a cross-sectional study and meta-analysis. *Invest Ophthalmol Vis Sci*. 2014;55:6007–6014.
- Wang W, Zhou M, Huang W, Chen S, Ding X, Zhang X. Does acute primary angle-closure cause an increased choroidal thickness? *Invest Ophthalmol Vis Sci*. 2013;54:3538–3545.
- Xu J, Xu L, Du KF, et al. Subfoveal choroidal thickness in diabetes and diabetic retinopathy. *Ophthalmology*. 2013;120:2023–2028.
- Tavares FJ, Proenca R, Alves M, et al. Retina and choroid of diabetic patients without observed retinal vascular changes: a longitudinal study. *Am J Ophthalmol*. 2017;176:15–25.
- Tavares FJ, Vicente A, Proenca R, et al. Choroidal thickness in diabetic patients without diabetic retinopathy. *Retina*. 2018;38:795–804.
- Lains I, Talcott KE, Santos AR, et al. Choroidal thickness in diabetic retinopathy assessed with swept-source optical coherence tomography. *Retina*. 2018;38:173–182.
- Wei WB, Xu L, Jonas JB, et al. Subfoveal choroidal thickness: the Beijing Eye Study. *Ophthalmology*. 2012;120:175–180.
- Gerendas BS, Waldstein SM, Simader C, et al. Three-dimensional automated choroidal volume assessment on standard spectral-domain optical coherence tomography and correlation with the level of diabetic macular edema. *Am J Ophthalmol*. 2014;158:1039–1048.
- Kim JT, Lee DH, Joe SG, Kim JG, Yoon YH. Changes in choroidal thickness in relation to the severity of retinopathy and macular edema in type 2 diabetic patients. *Invest Ophthalmol Vis Sci*. 2013;54:3378–3384.
- Querques G, Lattanzio R, Querques L, et al. Enhanced depth imaging optical coherence tomography in type 2 diabetes. *Invest Ophthalmol Vis Sci*. 2012;53:6017–6024.
- Singh SR, Vupparaboina KK, Goud A, Dansingani KK, Chhablani J. Choroidal imaging biomarkers. *Surv Ophthalmol*. 2019;64:312–333.
- Yiu G, Manjunath V, Chiu SJ, Farsiu S, Mahmoud TH. Effect of anti-vascular endothelial growth factor therapy on choroidal thickness in diabetic macular edema. *Am J Ophthalmol*. 2014;158:745–751.
- Rayess N, Rahimy E, Ying GS, et al. Baseline choroidal thickness as a predictor for response to anti-vascular endothelial growth factor therapy in diabetic macular edema. *Am J Ophthalmol*. 2015;159:85–91.
- Okamoto M, Matsuura T, Ogata N. Effects of panretinal photocoagulation on choroidal thickness and choroidal blood flow in patients with severe nonproliferative diabetic retinopathy. *Retina*. 2016;36:805–811.
- Zhu Y, Zhang T, Wang K, Xu G, Huang X. Changes in choroidal thickness after panretinal photocoagulation in patients with type 2 diabetes. *Retina*. 2015;35:695–703.
- Hwang H, Chae JB, Kim JY, Moon BG, Kim DY. Changes in optical coherence tomography findings in patients with chronic renal failure undergoing dialysis for the first time. *Retina*. 2019;39:2360–2368.
- Chang IB, Lee JH, Kim JS. Changes in choroidal thickness in and outside the macula after hemodialysis in patients with end-stage renal disease. *Retina*. 2017;37:896–905.
- Mule G, Vadala M, La Blasca T, et al. Association between early-stage chronic kidney disease and reduced choroidal thickness in essential hypertensive patients. *Hypertens Res*. 2019;42:990–1000.
- Tang Y, Wang X, Wang J, et al. Prevalence and causes of visual impairment in a chinese adult population: the Taizhou Eye Study. *Ophthalmology*. 2015;122:1480–1488.
- Jin G, Xiao W, Ding X, et al. Prevalence of and risk factors for diabetic retinopathy in a rural chinese population: the Yangxi Eye Study. *Invest Ophthalmol Vis Sci*. 2018;59:5067–5073.
- Wang W, He M, Zhong X. Sex-dependent choroidal thickness differences in healthy adults: a study based on original and synthesized data. *Curr Eye Res*. 2018;43:796–803.
- Horvath H, Kovacs I, Sandor GL, et al. Choroidal thickness changes in non-treated eyes of patients with diabetes: swept-source optical coherence tomography study. *Acta Diabetol*. 2018;55:927–934.
- Ambiya V, Kumar A, Baranwal VK, et al. Change in subfoveal choroidal thickness in diabetes and in various grades of diabetic retinopathy. *Int J Retina Vitreous*. 2018;4:34.
- Regatieri CV, Branchini L, Carmody J, Fujimoto JG, Duker JS. Choroidal thickness in patients with diabetic retinopathy analyzed by spectral-domain optical coherence tomography. *Retina*. 2012;32:563–568.
- Vujosevic S, Martini F, Cavarzeran F, Pilotto E, Midena E. Macular and peripapillary choroidal thickness in diabetic patients. *Retina*. 2012;32:1781–1790.
- Unsal E, Eltutar K, Zirtiloglu S, Dincer N, Ozdogan ES, Gungel H. Choroidal thickness in patients with diabetic retinopathy. *Clin Ophthalmol*. 2014;8:637–642.
- Sahinoglu-Keskek N, Altan-Yaycioglu R, Canan H, Coban-Karatas M. Influence of glycosylated hemoglobin on the choroidal thickness. *Int Ophthalmol*. 2018;38:1863–1869.
- Shao L, Xu L, Wei WB, et al. Visual acuity and subfoveal choroidal thickness: the Beijing Eye Study. *Am J Ophthalmol*. 2014;158:702–709.
- Wang JC, Lains I, Providencia J, et al. Diabetic choroidopathy: choroidal vascular density and volume in diabetic retinopathy with swept-source optical coherence tomography. *Am J Ophthalmol*. 2017;184:75–83.
- Zhang X, Ma J, Wang Y, et al. Elevated serum IGF-1 level enhances retinal and choroidal thickness in untreated acromegaly patients. *Endocrine*. 2018;59:634–642.
- Nomura Y, Takahashi H, Fujino Y, Kawashima H, Yanagi Y. Association between aqueous humor cxc motif chemokine ligand 13 levels and subfoveal choroidal thickness in normal older subjects. *Retina*. 2016;36:192–8.
- Yokouchi H, Baba T, Misawa S, et al. Correlation between serum level of vascular endothelial growth factor and subfoveal choroidal thickness in patients with

- POEMS syndrome. *Graefes Arch Clin Exp Ophthalmol*. 2015;253:1641–1646.
37. Strobbe E, Cellini M, Campos EC. Aqueous flare and choroidal thickness in patients with chronic hepatitis C virus infection: a pilot study. *Ophthalmology*. 2013;120:2258–2263.
 38. Kim M, Kim Y, Lee SJ. Comparison of aqueous concentrations of angiogenic and inflammatory cytokines based on optical coherence tomography patterns of diabetic macular edema. *Indian J Ophthalmol*. 2015;63:312–317.
 39. Ferrara D, Waheed NK, Duker JS. Investigating the choriocapillaris and choroidal vasculature with new optical coherence tomography technologies. *Prog Retin Eye Res*. 2016;52:130–155.
 40. Chandrasekera E, Wong EN, Sampson DM, Alonso-Caneiro D, Chen FK. Posterior choroidal stroma reduces accuracy of automated segmentation of outer choroidal boundary in swept source optical coherence tomography. *Invest Ophthalmol Vis Sci*. 2018;59:4404–4412.
 41. Vuong VS, Moisseiev E, Cunefare D, Farsiu S, Moshiri A, Yiu G. Repeatability of choroidal thickness measurements on enhanced depth imaging OCT using different posterior boundaries. *Am J Ophthalmol*. 2016;169:104–112.
 42. Michalewska Z, Michalewski J, Nawrocka Z, Dulciewska-Cichecka K, Nawrocki J. Suprachoroidal layer and suprachoroidal space delineating the outer margin of the choroid in swept-source optical coherence tomography. *Retina*. 2015;35:244–249.
 43. Yiu G, Pecun P, Sarin N, et al. Characterization of the choroid-scleral junction and suprachoroidal layer in healthy individuals on enhanced-depth imaging optical coherence tomography. *JAMA Ophthalmol*. 2014;132:174–181.
 44. Gupta P, Cheng CY, Cheung CM, et al. Relationship of ocular and systemic factors to the visibility of choroidal-scleral interface using spectral domain optical coherence tomography. *Acta Ophthalmol*. 2016;94:e142–e149.