

# Evolution of Outer Retinal Folds Occurring after Vitrectomy for Retinal Detachment Repair

Roberto dell'Omo,\* H. Stevie Tan, Reinier O. Schlingemann, Heico M. Bijl, Sarit Y. Lesnik Oberstein, Francesco Barca, and Marco Mura

**PURPOSE.** To assess the evolution of outer retinal folds (ORFs) occurring after repair of rhegmatogenous retinal detachment (RRD) using spectral domain-optical coherence tomography (sd-OCT) and fundus autofluorescence (FAF), and to discuss their pathogenesis.

**METHODS.** Twenty patients were operated on with 25-gauge pars plana vitrectomy and 20% sulfur hexafluoride gas injection for primary macula-off RRD repair and were followed prospectively. Sd-OCT and FAF images were recorded at 1, 3 and 6 months postoperatively.

**RESULTS.** ORFs appeared on sd-OCT as hyperreflective lesions consisting of folded inner segment/outer segment of photoreceptors band and external limiting membrane band. Corresponding lines of increased or decreased autofluorescence were observed on FAF. Over the follow-up, the thick hypoautofluorescent lines progressively evolved to thick hyperautofluorescent lines and to thin hyperautofluorescent lines and eventually disappeared. Concomitantly, OCT scans revealed that the corresponding hyperreflective lesions decreased in number, height, and size. In six cases FAF assessment at month 6 was precluded by cataract development.

**CONCLUSIONS.** ORFs tend to resolve spontaneously within a few months from operation leaving no or subtle abnormalities at the level of the outer retinal layers. OCT is superior to FAF to follow the evolution of ORFs in phakic eyes. The following factors might be involved in ORFs pathogenesis: structural changes occurring in the detached retina, residual pockets of subretinal fluid after retinal reattachment, intravitreal gas, unintentional retinal translocation, and intraoperative or perioperative hypotony. (*Invest Ophthalmol Vis Sci.* 2012; 53:7928-7935) DOI:10.1167/iovs.12-10322

From the Department of Ophthalmology, Academic Medical Center, University of Amsterdam, The Netherlands.

Presented in part at the annual meeting of the Association for Research in Vision and Ophthalmology, Fort Lauderdale, Florida, May 2012.

The authors alone are responsible for the content and writing of the paper.

Submitted for publication June 3, 2012; revised September 1 and 28, 2012; accepted October 21, 2012.

Disclosure: **R. dell'Omo**, None; **H.S. Tan**, None; **R.O. Schlingemann**, None; **H.M. Bijl**, None; **S.Y. Lesnik Oberstein**, None; **F. Barca**, None; **M. Mura**, None

Current affiliation: \*Department of Medicine and Health Sciences, University of Molise, Campobasso, Campobasso, Italy.

Corresponding author: Roberto dell'Omo, Department of Medicine and Health Sciences, University of Molise, Campobasso, Via Francesco de Sanctis, 86100, Campobasso, Italy; roberto.dellomo@unimol.it.

Until a few years ago, our understanding of the cellular events that occur when the retina and the retinal pigment epithelium (RPE) are detached or reattached derived solely from the study of experimental animal models<sup>1-3</sup> and from limited histopathologic reports of retinal detachments in humans.<sup>4,5</sup>

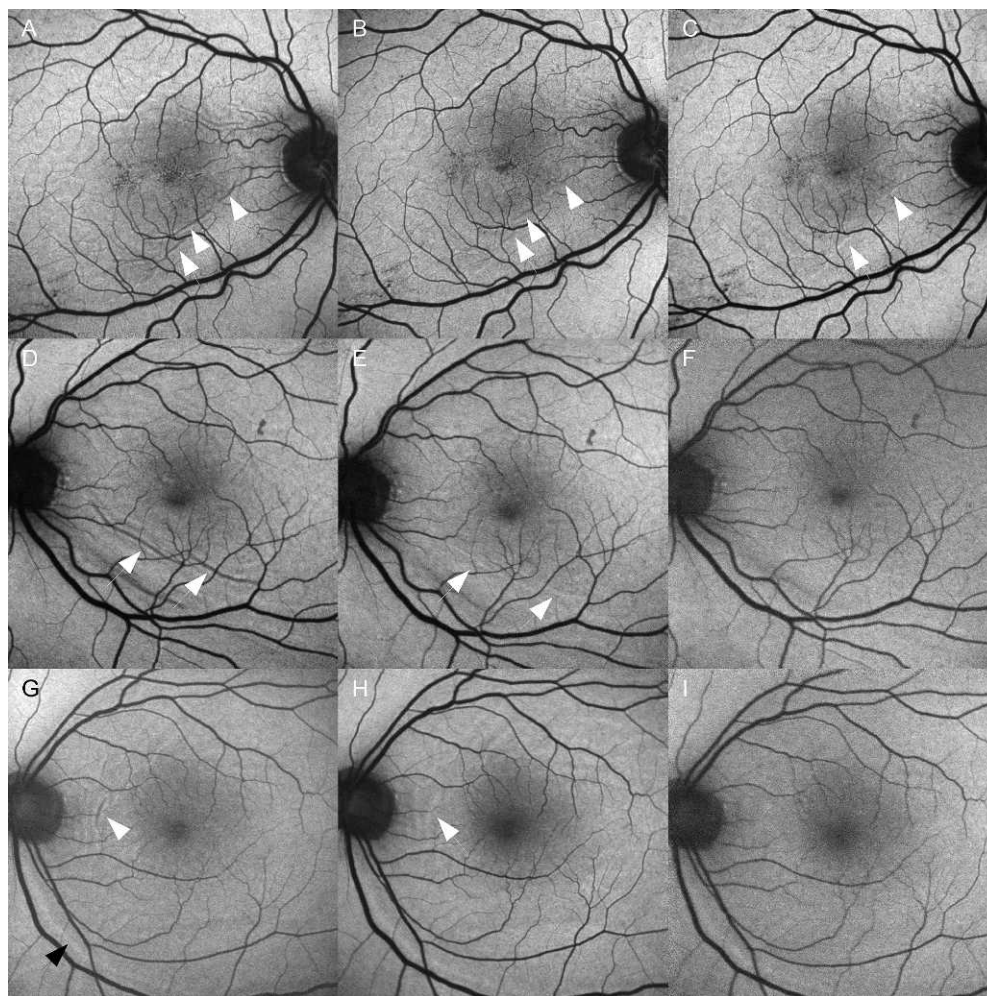
The advent of spectral domain-optical coherence tomography (sd-OCT) has permitted, without invasive intervention, to acquire pathologic data in vivo showing that persistent foveal detachment, distortion, and disruption of outer retinal layers (ORLs) and macular folds are common findings following successful surgery for retinal detachment (RD).<sup>6-14</sup>

More recently, fundus autofluorescence (FAF), an imaging modality that relies primarily on the fluorescence generated from the bisretinoids of lipofuscin in retinal pigment epithelial cells, also has been used to investigate the morphologic and functional changes occurring after RD repair. Shiragami et al<sup>13</sup> showed that in patients with large, bullous RDs, shifting of the retina from its original position can frequently be observed after vitrectomy and is elegantly depicted by FAF. The mark of the displacement consists of lines of increased autofluorescence that closely reflect the calibre and orientation of the adjacent retinal vessels to which the lines are related (Fig. 1). These hyperautofluorescent lines would originate from increased metabolic activity of the RPE that was preoperatively located under the retinal vessels and is postoperatively exposed to light because of displacement of the retina.<sup>13</sup> We proposed to call these lines "retinal vessels printings" (RVPs) because they closely resemble the retinal vessels they are related to.<sup>14</sup> OCT sections of these lines do not reveal characteristic features.<sup>14</sup>

Differently from RVPs, other lines of abnormal autofluorescence, showing no relationships with the adjacent retinal vessels and having characteristic counterparts on OCT, can also commonly occur after RD repair (Figs. 1, 2).

Some of these lines, showing either increased or decreased autofluorescence, correspond on OCT to hyperreflective lesions at the level of the ORLs.<sup>14</sup> The pathogenesis of these lines is uncertain. They might be due to:

1. Accumulation of subretinal material in the context of pockets of subretinal fluid formed after retinal reattachment. However, accumulation of subretinal material normally produces an increased autofluorescence signal, so this hypothesis could be applied only to hyperautofluorescent lines and not to hypoautofluorescent lines.
2. Clumping of misaligned and damaged distal ends of photoreceptors disinserted from the RPE apical processes. However, OCT findings suggest that the hyperreflective lesions may extend well beyond the photoreceptors tips, getting involved the line corresponding to the external limiting membrane and, therefore, the junctional complexes of the Muller cells



**FIGURE 1.** Evolution of the lines showing abnormal FAF after retinal detachment repair. (A) Thick, hypoautofluorescent lines are visible 1-month postoperatively (*arrows*). (B) Three months after operation the lines are still hypoautofluorescent but look thinner. (C) Six months after operation, thin hyperautofluorescent lines are visible. (D) Thick hypoautofluorescent lines observed at month 1 postoperatively (*arrows*) turn into thick hyperautofluorescent lines at 3 months (E) and are no longer visible 6 months after operation (F). (G) A thick hypoautofluorescent line 1-month postoperatively (*white arrow*), becomes hyperautofluorescent at month 3 (H) and is no longer visible 6 months after operation (I). Also note the retinal vessel printing, that is, the hyperautofluorescent line (IG, *black arrow*) parallel to a retinal vessel, not changing its characteristics on FAF through the follow-up.

(Fig. 2). In fact, prominent hyperreflective lesions may protrude in the outer nuclear layer and cause full-thickness distortion of the architecture and contour of the retina. If the hyperreflective lesions visible on OCT were simply a clumping of misaligned photoreceptor tips, one would not expect such significant repercussions on the contour of the retinal surface.

3. Partial-thickness folds involving the outer layers of the retina.

On the basis of previous OCT reports<sup>15</sup> and our observations,<sup>14</sup> we believe that hypothesis 3 is the most likely.

For such reason, in a previous paper<sup>14</sup> we deemed appropriate to refer to these abnormalities as “outer retinal folds” (ORFs). ORFs must be differentiated from full-thickness retinal folds, which involve all retinal layers and may also occur after successful repair of RD.<sup>16</sup>

Another interesting feature observed in our previous study<sup>14</sup> consisted of sharply demarcated skip changes in reflectivity of the inner segment/outer segment (IS/OS) line on OCT corresponding to thin lines of increased autofluorescence on FAF (Fig. 2). We termed these lines “IS/OS skip

reflectivity abnormalities” (IS/OS skip RAs). We speculated that they might reflect subtle damage of photoreceptors secondary to RD with consequent changes of the reflectivity of the IS/OS junction.

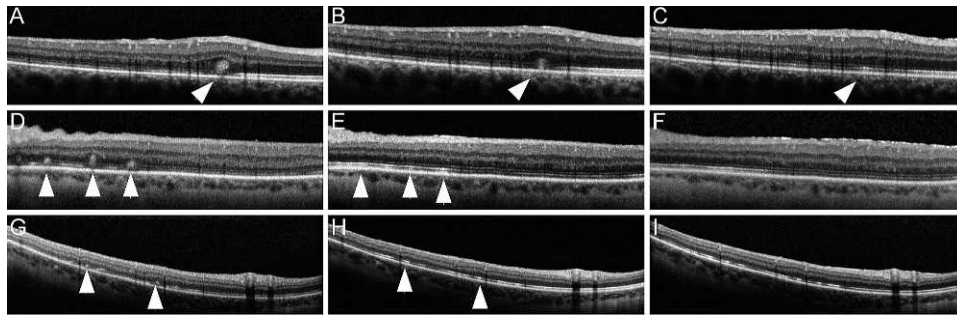
The aim of the present study was to analyze prospectively the evolution of ORFs through a follow-up period of six months and to discuss their pathogenesis.

## METHODS

All the patients presenting at the Academic Medical Center, University of Amsterdam, between October 1, 2010 and March 1, 2011 with primary macula-off rhegmatogenous RD uncomplicated by proliferative vitreo-retinopathy (PVR) grade C or greater<sup>17</sup> were consecutively asked to participate in this prospective observational study.

Preoperative data collection included a complete medical and ophthalmic history, logarithm of the minimum angle of resolution (logMAR) best-corrected visual acuity (BCVA) tested on the Early Treatment Diabetic Retinopathy Study (ETDRS) chart at 4 meters, characteristics of detachment, lens status, type of surgery, and time from the onset of symptoms suggestive of RD to surgery. VA of





**FIGURE 2.** Evolution of ORFs studied with sd-OCT. (A) An ORF (arrow) appears as an hyperreflective abnormality consisting of folded external limiting membrane (ELM) band and photoreceptor IS/OS band on OCT scan. Note the distortion of the profile of the overlying retinal layers. (B) Three months after operation the ORF appears less prominent (arrow) and the profile of the overlying retinal layers is also less distorted. (C) Six months after operation the ORF is no longer visible, substituted by IS/OS skip RAs (arrow). (D) ORFs (arrows) are associated to undulations of the inner retinal surface at month 1. (E) Three months after operation the inner retinal undulations are less prominent and the ORFs have been overtaken by IS/OS skip RAs (arrows). (F) Six-months postoperatively, the IS/OS skip RAs are barely visible. (G) ORFs (arrows) at month 1 turn into IS/OS skip RAs (arrows) at month 3 (H) which persist 6 months after operation (I).

counting fingers, hand movements, and light perception were converted to 1.4, 2.1, and 2.7 logMAR, respectively.

One month after operation, all the patients underwent comprehensive ophthalmologic examination, and sd-OCT and FAF imaging. When ORFs or IS/OS skip RAs were detected on FAF and/or OCT scans, the patients were invited to continue participating in the study and were again examined at 3 and 6 months after operation.

All subjects were treated in accordance with the Declaration of Helsinki. This study was approved by the Institutional Review Board of the University of Amsterdam. Informed consent was obtained from all the participants.

The main outcome measures for data analysis were the results of FAF and OCT imaging of the macular area and changes of BCVA.

### Surgical Technique

The series analyzed in this study includes the eyes that were operated on from October 1, 2010 and March 1, 2011 by a team of four experienced vitreo-retinal surgeons at the Academic Medical Center, University of Amsterdam. Local anesthesia was induced by subtenon injection of a mixture of 4% lidocaine and bupivacaine. Twenty-five gauge pars plana vitrectomy was performed in all cases using a vitrectomy system (Constellation; Alcon Labs, Fort Worth, TX). Central and peripheral vitrectomy with release of vitreous tractions, shaving of the vitreous base, and cutting of the flaps of the breaks were carried out in all cases.

After careful inspection of the periphery over 360 degrees and transscleral cryopexy around retinal breaks, fluid-air exchange with drainage of the subretinal fluid through original breaks using active aspiration (600 mm Hg) through a backflush instrument (1281.BTD05; DORC, Zuidland, The Netherlands), followed by 20% sulfur hexafluoride gas injection, was performed in all cases. Additional scleral buckling was not performed. Patients were asked to maintain a prone position for 2 hours after the operation and to sit up or stay supine thereafter for 4 days in case of superior or inferior breaks, respectively.

### Imaging

Images were acquired with HRA+OCT (Spectralis; Heidelberg Engineering, Heidelberg, Germany), which combines a sd-OCT with a confocal scanning laser ophthalmoscope that provides a reference fundus image. The sd-OCT records up to 40,000 A-scans per second with an axial digital resolution of approximately 4  $\mu$ m and a transversal digital resolution of approximately 15  $\mu$ m in the high-resolution mode. The "Automatic Real-Time" function incorporated in the software permits performing of multiple frames at the same scanning location,

which reduces noise and increases image quality. Using an active eye-tracking technology, the system automatically follows eye movements relating OCT B-scan to the selected fundus image. The "Follow-up" function identifies previous scan locations and automatically guides the OCT instrument to scan the same area for subsequent visits. For the purpose of this study, the first scan acquired at the 1-month postoperative visit was set as the reference scan.

OCT recording protocol consisted of a sequence of 97 horizontal sections, covering an area of 30 or 20 degrees horizontally x 20 degrees vertically recorded in the high-resolution mode (1536 and 1024 A-scans, respectively) with a distance of approximately 60  $\mu$ m between individual sections.

FAF (excitation wavelength at 488 nm and barrier filter at 500 nm), infra-red (IR), and red-free (RF) pictures (50 and 35 degrees) were obtained at each follow-up examination.

For the analysis of the FAF findings, lines of increased or decreased autofluorescence were divided in two groups: thick lines (transverse diameter  $\geq$  100  $\mu$ m) and thin lines (transverse diameter < 100  $\mu$ m). Measurements were manually taken by a single observer taking advantage of the integrated software of the machine.

### Statistical Analysis

Statistical analysis was performed using statistical software (MedCalc version 11.5.1; MedCalc Software bvba, Mariakerke, Belgium).

## RESULTS

### Demographics

Among the 43 patients with macula-off detachment without PVR grade C or greater operated on between October 1, 2010 and March 1, 2011, 23 were subsequently excluded for the following reasons: 12 did not show ORFs or IS/OS skip RAs on FAF-OCT examination at the 1-month visit, eight were not able to attend the follow-up visits, and three experienced re-detachment after primary surgery. Results for the remaining 20 patients followed up for 6 months are reported. Mean age was 61  $\pm$  7.8 years (range 45-78 years). At enrollment, 12 eyes were phakic and eight were pseudophakic, and during the follow-up four patients underwent cataract extraction. Median duration (confidence interval) of retinal detachment, on the basis of symptoms reported by the patients, was 5.5 (4.2-7.8) days. Mean ( $\pm$ SD) of detached quadrants was 3.1  $\pm$  0.8.

At least part of the macula (the area centered on the umbo, composed of umbo, foveola, fovea, parafovea, and perifovea,

and measuring 5.5 mm in total diameter) and the whole fovea (the area centered on the umbo and measuring 0.5 mm in total diameter) were detached in all cases as ascertained by ophthalmoscopy and preoperative OCT in those cases in which involvement of the fovea was doubtful on clinical examination. In all but two cases the main break, deemed causative of the detachment, was located in the upper quadrants.

### Fundus Autofluorescence Findings

One month postoperatively 11 eyes showed thick lines of decreased FAF, six eyes showed thick lines of increased FAF, and three eyes showed thin lines of increased FAF (Fig. 1).

At the 3-month visit the thick hypofluorescent lines had remained hypofluorescent in three eyes, had evolved to thick hyperfluorescent lines in four eyes, and had evolved to thin hyperfluorescent lines in four eyes. The thick hyperfluorescent lines had evolved to thin hyperfluorescent lines in four eyes and had resolved without leaving abnormalities in one eye. The thin lines of increased hyperfluorescence seen at month 1 did not change at month 3. Development of cataract precluded accurate assessment of FAF abnormalities in the remaining eye showing hyperfluorescent thick lines at month 1.

At the 6-month visit, thick hypofluorescent lines were not observed in any cases, thick hyperfluorescent lines were seen in four eyes, and thin hyperfluorescent lines were seen in eight eyes. No FAF abnormalities were observed in two cases. In six cases accurate assessment was precluded by development of cataract. In all the eyes that showed thin hyperfluorescent lines at 3 months except one, these lines were still visible at the 6-month visit. The data are summarized in the Table.

RVPs were observed in five eyes at month 1 and did not substantially change in size or in position relative to the retinal vessels they were related to, during the follow-up period.

### Spectral-Domain Optical Coherence Tomography Findings

Details of OCT findings are reported (see Supplementary Material and Supplementary Table S1, <http://www.iovs.org/lookup/suppl/doi:10.1167/iovs.12-10322/-/DCSupplemental>). At 1 month, ORLs disruption was the most common abnormality (19 eyes) followed by ORFs (17 eyes), and IS/OS skip reflectivity abnormalities (16 eyes). During the follow-up all the changes, except for epiretinal membranes (ERMs), showed a tendency to resolve. The number of eyes with ORFs and ORLs disruption decreased progressively through months 3 and 6 whereas the number of eyes with IS/OS skip RAs remained unchanged over the first 3 months. Width, height, and number of ORFs decreased during the follow-up (Fig. 2), and at the 6-month visit ORFs were detectable only in 2 eyes.

In several cases ORFs turned into IS/OS skip RAs (Fig. 2). Photoreceptor IS/OS skip RAs persisted for the entire duration of the follow-up in seven eyes and were generally found in nine eyes at last visit, being the most common OCT abnormality at 6 months along with ERMs (17 eyes).

In two eyes, pockets of subretinal fluid were observed in areas where ORFs were also detected, nevertheless in no cases did evolution of these pockets result in ORFs formation or vice versa (Fig. 3). Subretinal pockets of fluid disappeared leaving changes reminiscent of IS/OS skip RAs or leaving no abnormalities.

Four patients presented with subretinal/intraretinal fluid at the fovea 1-month postoperatively. At the 6-month follow-up visit the fluid was reabsorbed in all cases. One patient developed macular edema 6 months after operation.

TABLE. Evolution of Fundus Autofluorescence Findings Observed over the 6-Month Follow-Up

	Month 1	Month 3	Month 6
Thick lines of ↓ FAF	11	3	0
Thick lines of ↑ FAF	6	4	4
Thin lines of ↑ FAF	3	11	8
No lines visible	0	1	2
Cataract precluding assessment of lines on FAF (eyes)	0	1	6

↑ = increased; ↓ = decreased.

### Visual Acuity

Mean (SD) preoperative logMAR VA was  $1.16 \pm 0.93$  and improved to  $0.39 \pm 0.30$ ,  $0.32 \pm 0.34$ , and  $0.21 \pm 0.20$  at 1-, 3-, and 6-month follow-up, respectively. The improvement was statistically significant at month 1 in comparison to preoperative VA and at month 3 in comparison to month 1 (Friedman test,  $P < 0.001$ ). No further significant improvement was seen at month 6.

### DISCUSSION

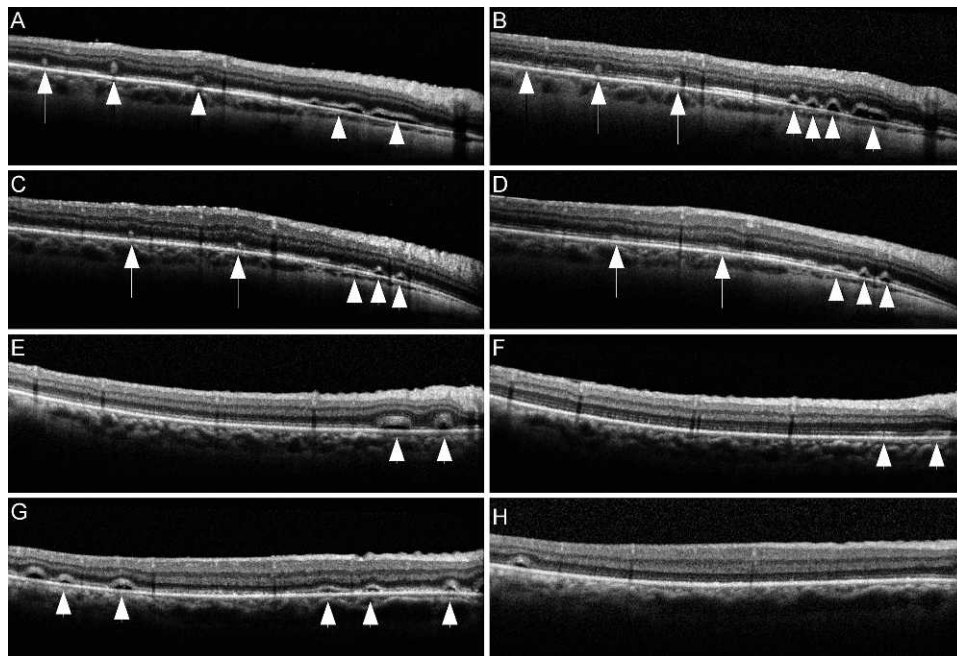
In this study we prospectively followed the evolution of ORFs and demonstrated that they tend to resolve spontaneously within a few months from operation leaving behind only subtle retinal abnormalities. Therefore, ORFs must be differentiated from full-thickness retinal folds, which may become fixed, may require further surgical intervention,<sup>16,18,19</sup> and are associated with apoptosis and thinning of the photoreceptor layer within the fold.<sup>20</sup> ORFs should also be differentiated from residual subretinal fluid, which can take years to be reabsorbed,<sup>21-24</sup> and from RVPs, which do not substantially change during follow-up.<sup>13</sup>

Both FAF and OCT were found to be sensitive in detecting the presence of ORFs shortly after operation, but OCT was superior to FAF to follow their evolution in phakic eyes because recording of good-quality FAF images was impaired by development of cataract. This is not unexpected because vitrectomy induces cataract and the blue excitation light of FAF is absorbed to a large extent by nuclear sclerosis or advanced yellowing of the lens. In contrast, OCT is based on near-infrared interferometry and is much less affected by media opacities.

In our study, the typical observed sequence of evolution of prominent ORFs on FAF imaging was: thick hypofluorescent lines → thick hyperautofluorescent lines → thin hyperautofluorescent lines → residual subtle or no abnormalities. Concomitantly, OCT scans revealed that the corresponding hyperreflective lesions decreased in number, height and size.

The hypofluorescence associated with prominent ORFs is probably due to a masking effect on RPE autofluorescence by the overlying misaligned photoreceptors or by a reduced shedding of fluorophores to the RPE from damaged and shortened photoreceptors. The evolution of hypofluorescent lines into hyperautofluorescent lines may be due to several factors:

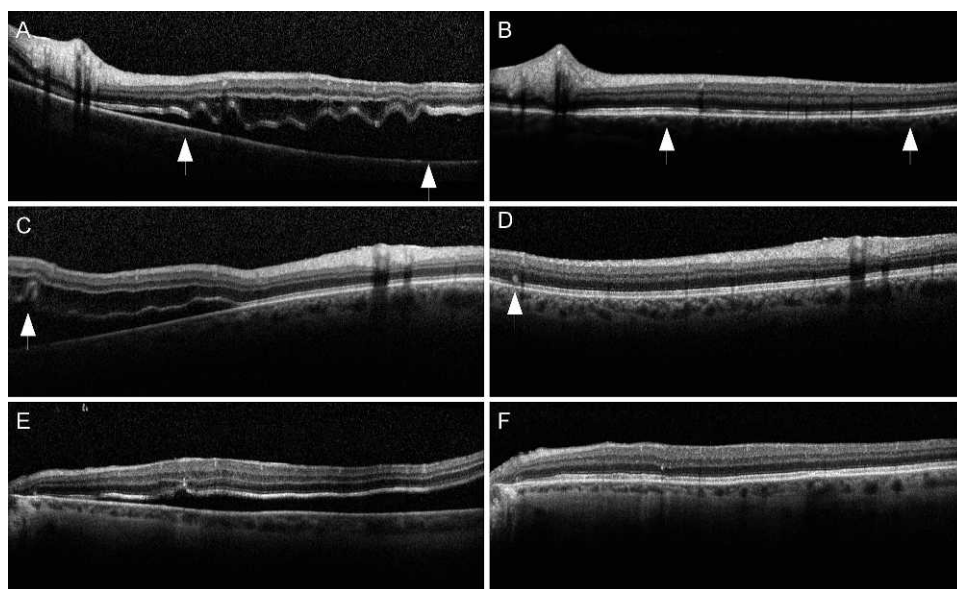
1. Accumulation of hyperautofluorescent material originating from degenerating photoreceptors' outer segments in the subretinal space. This accumulation would occur because the folded distal ends of the photoreceptors are separated from the apical surface of the RPE cells, which, under normal circumstances, phagocytose the



**FIGURE 3.** Evolution of pockets of subretinal fluid and ORFs on sd-OCT. (A) One month after retinal detachment repair, ORFs (*arrows*) and pockets of subretinal fluid (*arrowheads*) are visible. (B) Twenty days later the ORFs are less prominent whereas the pockets of subretinal fluid have collapsed giving rise to smaller but more numerous pockets (*arrowheads*). (C) ORFs (*arrows*) and pockets of subretinal fluid (*arrowheads*) seen 1-month postoperatively, respectively resolve, leaving IS/OS skip RAs, (D), *arrows*) and persist (D), *arrowheads*) at the 3-month visit. (E) Pockets of subretinal fluid seen 1 month after operation, disappear 2 months later leaving IS/OS skip RAs (F), *arrowheads*). (G) Pockets of subretinal fluid (*arrowheads*) resolving without leaving abnormalities (H).

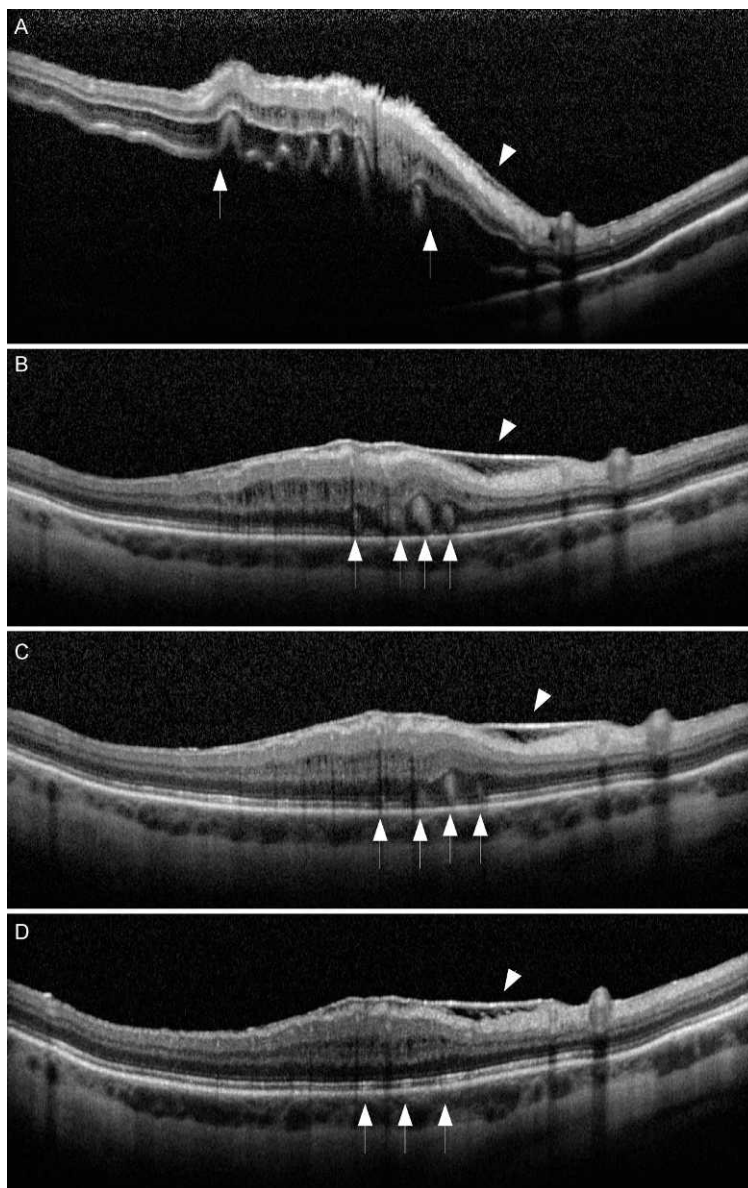
wasting material shed by photoreceptors. Subsequent reabsorption of this material would make the hyper-autofluorescent lines thinner and thinner until they become no longer visible.

2. A phenomenon similar to that described for the RVPs, that is, the prominent ORFs would shadow the underlying RPE inducing on it metabolic changes responsible for an increased autofluorescence visible



**FIGURE 4.** sd-OCT sequence showing the relationship between preoperative and postoperative profiles of the outer retina in patients who have undergone vitrectomy and gas injection for macula-off retinal detachment repair. (A) Undulations of the profile of the detached outer retina preoperatively (*between the arrows*). (B) One-month postoperatively IS/OS skip RAs are detected at the same area (*between the arrows*). (C) A discrete outer retinal undulation is observed preoperatively (*arrow*). (D) One-month postoperatively an ORF (*arrow*) has replaced the undulation. (E) Retinal detachment presenting with a relatively flat contour of the outer layers. (F) One-month postoperatively no obvious morphologic or reflectivity abnormalities of the ORLs are visible.





**FIGURE 5.** Relation between ERM and ORFs. (A) sd-OCT recorded preoperatively shows multiple undulations of the detached outer retina (*between the arrows*) and an ERM (*arrowhead*). (B) One month after operation, prominent ORFs are visible (*arrows*). Some seem to have replaced the preoperative undulations of the outer retina. The ERM looks thicker in comparison to preoperative assessment. (C) Three months after operation, the ORFs (*arrows*) are less prominent and the ERM is unchanged (*arrowhead*). (D) Six months after operation, the ORFs have completely resolved turning into IS/OS skip RAs. The ERM looks unchanged.

once the ORF has resolved. Differently from the RVPs, such increased autofluorescence is transient presumably in relation to the short period of shadowing of the RPE by the ORF.

During the follow-up, flattening of the ORFs left behind areas of abnormal reflectivity of the IS/OS band, that we previously named IS/OS skip RAs.<sup>14</sup> It is possible that IS/OS skip RAs reflect morphologic changes and/or very subtle misalignment affecting the distal end of photoreceptors. As such, IS/OS skip RAs might be not necessarily related to resolved ORFs but could be observed in association to other abnormalities causing misalignment of the ORFs. Indeed, we also found changes reminiscent of IS/OS skip RAs in areas previously occupied by pockets of subretinal fluid (Fig. 3).

At the end of follow-up, IS/OS skip RAs were still visible in almost 50% of the examined eyes, indicating they tend to

persist longer than ORFs after operation. Further studies that include more patients are needed to elucidate if these subtle changes can influence visual acuity or be responsible for metamorphopsia in the long term.

Regarding the pathogenesis of ORFs, we previously proposed<sup>14</sup> that sequestration of subretinal fluid and concomitant use of intravitreal gas, classically considered the causes of full-thickness retinal folds,<sup>16,18,19</sup> may be implicated in ORFs formation as well. In particular a relationship could exist between pockets of subretinal fluid and ORFs because they share some characteristics in that both abnormalities may be multiple, with various orientations and lengths.

The formation of pockets of subretinal fluid may in turn be favored by the undulations of the detached retina, which histology reports<sup>25</sup> and OCT studies<sup>26,27</sup> have shown to be common findings in macula-off detachments. Undulations

might be secondary to cystoid degeneration of the retina, modifications in the cytoskeleton of photoreceptors,<sup>28</sup> and intraretinal proliferation of nonneural cell types occurring within hours of the detachment.<sup>29,30</sup>

A complete flattening of these undulations either intraoperatively or in the immediate postoperative period may be impeded by the fact that they are secondary to structural changes probably requiring several weeks to resolve. Therefore, it is possible that persisting undulations play a role in the formation of pockets of subretinal fluid, later evolving into ORFs. In support of this hypothesis we found a correspondence between location of outer retinal undulations seen preoperatively and location of ORFs and IS/OS skip RAs seen postoperatively (Figs. 4, 5).

However, we observed that in no case, the evolution of pockets of subretinal fluid led to the formation of ORFs in the absence of intravitreal gas, that is, from the time we started to record images (Fig. 3). Therefore, if a relationship exists between pockets of subretinal fluid and ORFs, the intraocular gas tamponade must be a key element, that is, the pockets of subretinal fluid could not transform into ORFs without an internal tamponade.

Another factor which might play a role in the development of ORFs is unintentional retinal translocation occurring during RD repair. Such retinal displacement is caused by the mobility and elasticity of the detached retina and by the presence of subretinal fluid, which stretches the retina increasing its surface.<sup>16</sup> When an intraocular gas is injected, it can force the detached retina back to the RPE and choroid, producing a fold at the edge between the attached and detached retina. However, because ORFs are normally multiple and with variable orientations not related to the edge of the detachment, this hypothesis looks unlikely.

Transient hypotony at the time of surgery or in the postoperative period might also potentially favor ORFs formation.<sup>15</sup>

We cannot exclude that short-duration decreases in IOP might have occurred during surgical manipulations even if the machine we used for all surgical procedures included an integrated infusion pressure and an IOP control system, which should be able to prevent unwanted intraoperative hypotony. IOP < 8 mm Hg was not recorded in any of the patients either the day after the operation or at the follow-up appointments when images were taken, but it is possible that a transient hypotony developed for a few hours after the operation. Moreover, images were taken weeks after operation so we could not rule out that some subtle alterations suggestive of low IOP on OCT and visible only for a few days after operation, may have been missed.

Epiretinal traction could be another factor potentially favoring the formation of ORFs. In fact it could be hypothesized that an ERM altered the physiologic elasticity of the retina and conferred some rigidity, which potentially hindered the flattening of corrugated ORFs once they had been reapposed to the RPE. For this reason, we carefully scanned the areas presenting with ERMs noting that ERMs did not prevent or slow down the resolution of underlying ORFs when compared to areas devoid of epiretinal traction (Fig. 5). Therefore, the influence of ERMs on the formation or evolution of ORFs seems to be negligible.

In conclusion, we report on the evolution of ORFs, a common finding occurring after vitrectomy and injection of gas for RD repair. The pathogenesis of ORFs is probably multifactorial with several variables concurring to their formation.

Differently from full-thickness retinal folds, which may require a surgical intervention to resolve, ORFs resolve spontaneously, normally disappearing within 6 months or less

from the operation. The residual abnormalities left at the level of the outer retina, in the form of IS/OS skip RAs may persist longer, and their repercussions on postoperative visual acuity and metamorphopsia should be further investigated.

## References

1. Anderson DH, Guerin CJ, Erickson PA, Stern WH, Fisher SK. Morphological recovery in the reattached retina. *Invest Ophthalmol Vis Sci.* 1986;27:168-183.
2. Barr CC. The histopathology of successful retinal reattachment. *Retina.* 1990;10:189-194.
3. Erickson PA, Fisher SK, Anderson DH, Stern WH, Borgula GA. Retinal detachment in the cat: the outer nuclear and outer plexiform layers. *Invest Ophthalmol Vis Sci.* 1983;24:927-942.
4. Nork TM, Millecchia LL, Strickland BD, Linberg JV, Chao GM. Selective loss of blue cones and rods in human retinal detachment. *Arch Ophthalmol.* 1995;113:1066-1073.
5. Wilson DJ, Green WR. Histopathologic study of the effect of retinal detachment surgery on 49 eyes obtained post mortem. *Am J Ophthalmol.* 1987;103:167-179.
6. Schocket LS, Witkin AJ, Fujimoto JG, et al. Ultrahigh-resolution optical coherence tomography in patients with decreased visual acuity after retinal detachment repair. *Ophthalmology.* 2006;113:666-672.
7. Smith AJ, Telander DG, Zawadzki RJ, et al. High-resolution Fourier-domain optical coherence tomography and microperimetric findings after macula-off retinal detachment repair. *Ophthalmology.* 2008;115:1923-1929.
8. Wakabayashi T, Oshima Y, Fujimoto H, et al. Foveal microstructure and visual acuity after retinal detachment repair: imaging analysis by Fourier-domain optical coherence tomography. *Ophthalmology.* 2009;116:519-528.
9. Sheth S, Dabir S, Natarajan S, Mhatre A, Labauri N. Spectral domain-optical coherence tomography study of retinas with a normal foveal contour and thickness after retinal detachment surgery. *Retina.* 2010;30:724-732.
10. Gharbiya M, Grandinetti F, Scavella V, et al. Correlation between spectral-domain optical coherence tomography findings and visual outcome after primary rhegmatogenous retinal detachment repair. *Retina.* 2012;32:43-53.
11. Lai WW, Leung GY, Chan CW, Yeung IY, Wong D. Simultaneous spectral domain OCT and fundus autofluorescence imaging of the macula and microperimetric correspondence after successful repair of rhegmatogenous retinal detachment. *Br J Ophthalmol.* 2010;94:311-318.
12. Wong R. Longitudinal study of macular folds by spectral-domain optical coherence tomography. *Am J Ophthalmol.* 2012;153:88-92.
13. Shiragami C, Shiraga F, Yamaji H, et al. Unintentional displacement of the retina after standard vitrectomy for rhegmatogenous retinal detachment. *Ophthalmology.* 2010;117:86-92.
14. dell'Omo R, Mura M, Lesnik Oberstein SY, Bijl HM, Tan. HS. Early simultaneous fundus autofluorescence and optical coherence tomography features after pars plana vitrectomy for primary rhegmatogenous retinal detachment. *Retina.* 2012;32:719-728.
15. Benson SE, Schlottmann PG, Bunce C, Xing W, Charteris DG. Optical coherence tomography analysis of the macula after vitrectomy surgery for retinal detachment. *Ophthalmology.* 2006;113:1179-1183.
16. Heimann H, Bopp S. Retinal folds after retinal detachment surgery. *Ophthalmologica.* 2011;226:18-26.
17. Machemer R, Aaberg TM, Freeman HM, Irvine AR, Lean JS, Michels RM. An updated classification of retinal detachment

- with proliferative vitreoretinopathy. *Am J Ophthalmol*. 1991;112:159-165.
18. Pavan PR. Retinal fold in macula following intraocular gas. An avoidable complication of retinal detachment surgery. *Arch Ophthalmol*. 1984;102:83-84.
  19. Larrison WI, Frederick AR Jr, Peterson TJ, Topping TM. Posterior retinal folds following vitreoretinal surgery. *Arch Ophthalmol*. 1993;111:621-625.
  20. Hayashi A, Usui S, Kawaguchi K, et al. Retinal changes after retinal translocation surgery with scleral imbrication in dog eyes. *Invest Ophthalmol Vis Sci*. 2000;41:4288-4292.
  21. Wolfensberger TJ. Foveal reattachment after macula-off retinal detachment occurs faster after vitrectomy than after buckle surgery. *Ophthalmology*. 2004;111:1340-1343.
  22. Seo JH, Woo SJ, Park KH, Yu YS, Chung H. Influence of persistent submacular fluid on visual outcome after successful scleral buckle surgery for macula-off retinal detachment. *Am J Ophthalmol*. 2008;145:915-922.
  23. Kim YK, Woo SJ, Park KH, Yu YS, Chung H. Comparison of persistent submacular fluid in vitrectomy and scleral buckle surgery for macula-involving retinal detachment. *Am J Ophthalmol*. 2010;149:623-629.
  24. Ricker LJAG, Noordzij LJ, Goezinne F, et al. Persistent subfoveal fluid and increased preoperative foveal thickness impair visual outcome after macula-off retinal detachment repair. *Retina*. 2011;31:1505-1512.
  25. Machemer M. Experimental retinal detachment in the owl monkey. II. Histology of retina and pigment epithelium. *Am J Ophthalmol*. 1968;66:396-410.
  26. Lee SY, Joe SG, Kim JG, Chung H, Yoon YH. Optical coherence tomography evaluation of detached macula from rhegmatogenous retinal detachment and central serous chorioretinopathy. *Am J Ophthalmol*. 2008;145:1071-1076.
  27. Nakanishi H, Hangai M, Unoki N, et al. Spectral-domain optical coherence tomography imaging of the detached macula in rhegmatogenous retinal detachment. *Retina*. 2009;29:233-42.
  28. Lewis GP, Matsumoto B, Fisher SK. Changes in the organization and expression of cytoskeletal proteins during retinal degeneration induced by retinal detachment. *Invest Ophthalmol Vis Sci*. 1995;36:2404-2416.
  29. Fisher SK, Erickson PA, Lewis GP, Anderson DH. Intraretinal proliferation induced by retinal detachment. *Invest Ophthalmol Vis Sci*. 1991;32:1739-1748.
  30. Geller SF, Lewis GP, Anderson DH, Fisher SK. Use of the MIB-1 antibody for detecting proliferating cells in the retina. *Invest Ophthalmol Vis Sci*. 1995;36:737-744.