

Correlations between Spectral-Domain OCT Measurements and Visual Acuity in Cystoid Macular Edema Associated with Retinitis Pigmentosa

Yoon Jeon Kim, Soo Geun Joe, Dong-Hoon Lee, Joo Yong Lee, June-Gone Kim, and Young Hee Yoon

PURPOSE. To evaluate the characteristics of spectral-domain optical coherence tomography (SD-OCT) findings associated with visual outcome and compare OCT measurements according to presence of cystoid macular edema (CME) in retinitis pigmentosa (RP) patients.

METHODS. Patients with typical RP who underwent SD-OCT were included. We compared OCT measurements such as central retinal thickness (CRT), photoreceptor thickness, and photoreceptor inner segment/outer segment (IS/OS) junctional status at the fovea between the CME and non-CME groups. Also, correlations between best-corrected visual acuity (BCVA) and each parameter were determined.

RESULTS. Among a total of 220 eyes in 128 RP patients, 46 eyes of 30 patients (20.9%) had CME. CRT was $303.1 \pm 81.8 \mu\text{m}$ and $209.2 \pm 46.8 \mu\text{m}$ in the CME and non-CME groups, respectively ($P < 0.001$). BCVA did not differ between the two groups ($P = 0.690$). However, among a subgroup with unilateral CME, BCVA was significantly worse in CME eyes than in the fellow eyes ($P = 0.046$). In the CME group, eyes with increased CRT showed worse BCVA ($P = 0.010$). Among 12 eyes with severe CME, defined as $350 \mu\text{m}$ or more CRT, 10 (83.3%) showed an absent IS/OS junction. In the non-CME group, in contrast, eyes with decreased CRT showed worse BCVA ($P < 0.001$). In both groups, severe IS/OS disruption was correlated with worse BCVA ($P < 0.001$). The risk of IS/OS disruption was higher in the CME group ($P = 0.016$).

CONCLUSIONS. The presence of CME in RP patients was not necessarily correlated with loss of visual acuity. In eyes with CME, however, severe CME was strongly correlated with IS/OS disruption and visual impairment. Thus, severe CME seemed to be a predictor of poor visual outcome in RP patients. (*Invest Ophthalmol Vis Sci.* 2013;54:1303-1309) DOI:10.1167/iov.12-10149

In patients with retinitis pigmentosa (RP), particularly those in whom the disease is moderately advanced, cystoid macular edema (CME) may markedly reduce central vision and can cause severe further visual loss in individuals who are

already visually impaired.¹ The prevalence of CME in RP patients varied in previous studies, ranging from 11% to 49%.²⁻⁷ Because of a lack of fluorescein dye leakage in RP patients with CME, optical coherence tomography (OCT) has been useful for diagnosing macular edema and evaluating the effectiveness of treatment.^{2-6,8}

Many researchers have made efforts to find out the relationship between OCT structural findings and visual function in inherited retinal disease. Both retinal thinning caused by photoreceptor cell loss and retinal thickening due to macular edema appeared to be associated with reduced visual acuity in typical RP patients.⁹⁻¹² In a previous study, the status of the photoreceptor inner segment/outer segment (IS/OS) junction was correlated with visual function in RP patients.¹³ Retinal thinning is also known to be associated with elevation of the thresholds of both rods and cones.^{14,15}

The advent of spectral-domain (SD) OCT enabled the observation of microstructural changes within individual retinal layers, including the IS and the OS of the photoreceptor and outer nuclear layers.^{8,16} The present study investigated the correlation between SD-OCT, especially with respect to photoreceptor integrity status, and best-corrected visual acuity (BCVA) in RP patients with CME. For comparison, the association between photoreceptor integrity status and BCVA was assessed in RP patients without CME.

METHODS

Subjects

A total of 133 consecutive patients diagnosed with typical RP between April 2009 and December 2010 at the Asan Medical Center, Seoul, Korea, were investigated. Informed consent was obtained from all participants, and Institutional Review Board approval was obtained from the Asan Medical Center. The design of this study adhered to the principles of the Declaration of Helsinki.

RP was diagnosed on the basis of a history of night blindness and ophthalmologic findings. To diagnose RP, each participant was subjected to a complete ophthalmologic examination, including a review of the participant's medical and clinical history, measurement of BCVA, slit-lamp biomicroscopy, dilated fundoscopic examination, visual field testing, and full-field electroretinography (ERG) recorded under International Society for Clinical Electrophysiology of Vision (ISCEV)-standardized conditions. BCVA was evaluated by examiners who were masked to the information obtained during previous determinations using the same Snellen projection chart. Some patients additionally underwent fluorescein angiography to assess vascular leakage from the macula. Static automated perimetry was conducted using the central 30-2 Swedish interactive threshold algorithm (SITA) standard on a visual field analyzer (Humphrey Visual Field Analyzer II; Carl Zeiss Meditec, Dublin, CA) with a Goldmann size III stimulation on

From the Department of Ophthalmology, University of Ulsan, College of Medicine, Asan Medical Center, Seoul, Korea.

Submitted for publication May 7, 2012; revised September 5, 2012 and January 3, 2013; accepted January 5, 2013.

Disclosure: **Y.J. Kim**, None; **S.G. Joe**, None; **D.-H. Lee**, None; **J.Y. Lee**, None; **J.-G. Kim**, None; **Y.H. Yoon**, None

Corresponding author: Young Hee Yoon, Department of Ophthalmology, University of Ulsan, College of Medicine, Asan Medical Center, 88, Olympic-ro 43-gil, Songpa-gu, Seoul, Korea 138-736; yhyoon@amc.seoul.kr.

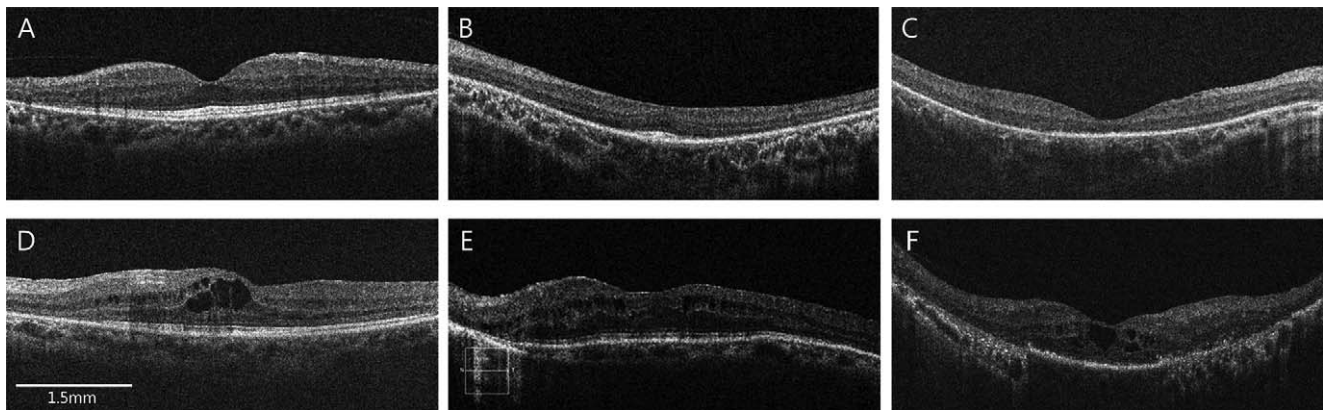


FIGURE 1. Evaluation of the inner segment/outer segment (IS/OS) of photoreceptor integrity just beneath the fovea in patients with retinitis pigmentosa without (A–C) and with (D–F) cystoid macular edema. (A, D) Grade 1: distinct; (B, E) grade 2: discontinuous; (C, F) grade 3: absent. *White bar in (D)* indicates 1.5 mm.

a 31.5-apostilb background. The mean deviation (MD) from the central 30° of the visual field and the central visual field sensitivity were used in the analysis. Central visual field sensitivity was calculated by averaging the visual sensitivity value at four central test points, representing the central 6° from the fovea. All patients had varying degrees of peripheral field restriction, characteristic fundus changes such as bone spicule-like pigmentations, and either nonrecordable or markedly reduced a- and b-wave amplitudes as determined by ERG. Full-field ERG findings were analyzed after excluding eyes in which the interval between the baseline examination and ERG recordings was longer than 6 months. No patient had a history of ocular or systemic disease that could have resulted in significant retinal pigmentary changes. Eyes with concomitant ocular diseases other than cataracts, that is, with preexisting macular disease, glaucoma, or diabetic retinopathy, and eyes showing poor fixation because of extremely low visual acuity (less than hand movement) were excluded.

Assessment of SD-OCT Images

All patients were imaged via spectral-domain OCT (SD-OCT) using a Cirrus HD-OCT (Carl Zeiss Meditec). Our Cirrus HD-OCT platform is calibrated on a regular basis by a technician employed by the manufacturer. Pupil dilatation was performed if necessary. All accepted images exhibited a centered fixation point, were well focused, with even and adequate illumination, and had a signal strength ≥ 7 . Grayscale images were employed to permit precise identification of retinal layers and the conduct of thickness measurements thereon.

Three-dimensional macular cube OCT data were obtained using the Macular Cube 512 \times 128 scan mode. The protocol performs 128 horizontal B-scans, comprising 512 A-scans per B-scan, 1024 times, within a cube measuring 6 \times 6 \times 2 mm, and is designed to allow analysis of retinal topography. Several OCT parameters were obtained using the cube average thickness data yielded by use of the conventional macular cube algorithm; these were central retinal thickness (CRT), the retinal thickness of each AREDS (Age-Related Eye Disease Study) subfield, and macular volume.

Two observers (YJK, SGJ) masked to visual acuity data evaluated vertical and horizontal OCT images from each patient. Since RP is associated with underlying retinal atrophy, the measured retinal thickness may not fully reflect the degree of retinal edema.^{2–6} Thus, we did not include retinal thickness as a diagnostic criterion. Instead, we defined macular edema associated with RP on the basis of the presence of visible intraretinal cystoid spaces situated at the central macula (1.5 mm in diameter) on horizontal and/or vertical scan OCT images.

The presence of any vitreomacular interface abnormality such as an epiretinal membrane or the presence of vitreomacular traction was also carefully evaluated. In addition, the status of the foveal IS/OS

junction was examined in SD-OCT images via evaluation of junctional status over a region 1.5 mm in width encompassing the fovea (Fig. 1). Junctional status was classified according to three categories (grade 1, distinct = present and >1.5 mm; grade 2, discontinuous = present but <1.5 mm; and grade 3, absent) previously described in eyes without CME¹³ and in eyes with CME.¹⁷ As shown in the representative OCT images (Figs. 1B, 1E), the IS/OS disruption pattern in the two eyes may differ. If the opinions of the two observers differed, a third examiner (YHY), who was also masked to the clinical information of the patients, was asked to make a final decision.

Three examiners (YJK, SGJ, YHY) measured thickness of the entire photoreceptor layer at the foveal center manually for each patient, using the program built into the Cirrus OCT software (Carl Zeiss Meditec), to assess retinal photoreceptor atrophy. Commencing at the inner surface of the retinal pigment epithelium (RPE), photoreceptor thickness (PR) was calculated up to a border delimited by the inner surface of the outer nuclear layer (ONL) in eyes without CME, or the outer surface of the cystoid space in eyes with CME (Fig. 2).^{17–19} Another parameter of photoreceptor atrophy, thickness of the outer segment of photoreceptor (OS+), was defined as the distance between the outer border of the RPE and the inner border of the IS/OS junction

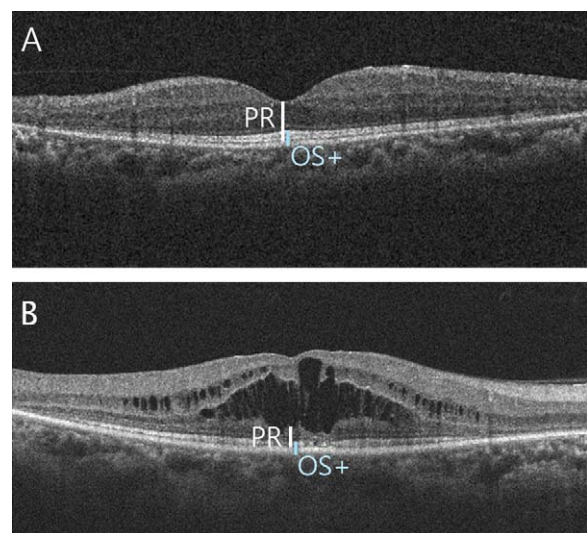


FIGURE 2. Thickness of the entire photoreceptor (PR) layer, estimated via SD-OCT scanning, of the fovea of patients with retinitis pigmentosa (A) without and (B) with cystoid macular edema. When the cystoid space extended to the outer nuclear layer, the anterior margin of the PR was the posterior border of the cystoid space.

TABLE 1. Baseline Patient Characteristics: Comparison between Eyes with and without CME Associated with Retinitis Pigmentosa

	CME, 46 Eyes, 20.9%	No CME, 174 Eyes, 79.1%	Overall, 220 Eyes	P Value
Age, y*	52.4 ± 16.9	46.2 ± 17.2	47.5 ± 18.1	0.102
Male:female, number of eyes (%)†	20:26 (43.5:56.5)	90:84 (51.7:48.3)	110:110 (50.0:50.0)	0.320
BCVA, LogMAR*	0.54 ± 0.43	0.53 ± 0.60	0.53 ± 0.65	0.690
Phakic:pseudophakic, number of eyes (%)†	28:18 (54.3:39.1)	116:58 (66.7:33.3)	144:76 (65.5:34.5)	0.462
VMIA, number of eyes (%)†	30 (64.2)	64 (36.8)	94 (42.7)	<0.001
FA leakage, number of eyes (%)‡	3/12 (25.0)	1/16 (6.2)	5/28 (17.8)	0.161
Nonrecordable ERG, number of eyes (%)†	15/35 (42.9)	49/161 (30.4)	64/196 (32.7)	0.112
MD, dB*	-23.6 ± 7.1	-22.8 ± 8.1	-23.0 ± 8.2	0.257
Central visual field sensitivity, dB*§	19.7 ± 8.3	19.3 ± 9.4	19.4 ± 9.6	0.799

FA, fluorescein angiography.

* Values are the mean ± standard deviation and were analyzed using the independent samples *t*-test.

† Values were analyzed with the χ^2 test.

‡ Values were analyzed with Fisher's exact test.

§ Central visual field sensitivity was calculated by averaging visual sensitivity values at four central test points, corresponding to fovea.

of the fovea.^{20,21} The average of three measurements for each parameter was used in the analysis. After assessment of these OCT parameters, correlations between BCVA data and measurements of each parameter were calculated.

Statistical Analysis

Descriptive statistics (number and percentage for categorical variables and mean ± standard deviation [SD] for continuous variables) were evaluated to compare baseline patient characteristics between eyes with and without CME associated with RP. The Wilk-Shapiro test was used to explore the distribution of the numerical data. Normally distributed data were compared between the two groups using the independent samples *t*-test. Nonnormally distributed data were compared using the Mann-Whitney test. In three-group comparison, one-way ANOVA followed by application of the Bonferroni test was used for normally distributed data and Kruskal-Wallis test for nonnormally distributed data. To compare the categorical data, the significance of differences between groups was tested using χ^2 test and Fisher's exact test as appropriate on the basis of data distribution. In three-group comparison for the categorical data, Bonferroni post hoc test was performed. Intraindividual comparison was performed using Wilcoxon signed rank test. Possible correlations between visual acuity data and each OCT parameter in patients with macular edema were explored using Pearson's correlation test. To assess the intraclass repeatability of the PR and OS+ measurements, the intraclass correlation coefficient (ICC) was calculated. For the ICC calculation, the two-way random model for measuring the absolute agreement and the single ratings was used. A *P* value less than 0.05 was considered to be statistically significant. All statistical analyses were performed using SPSS version 17.0 (SPSS Inc., Chicago, IL).

RESULTS

A total of 266 eyes of 133 consecutive RP patients were examined. Of these eyes, 46 were excluded because vision was extremely poor (hand motion or worse, 26 eyes), or because of coexisting advanced glaucoma (2 eyes), a macular hole (2 eyes), or low OCT signal strength (16 eyes); 220 eyes of 128 patients (65 men, 63 women) thus remained for evaluation. The mean ± SD patient age was 47.5 ± 18.1 years (range, 16–80 years), and the mean ± SD logarithm of the minimum angle of resolution (logMAR) BCVA was 0.53 ± 0.6, which is the mean BCVA 0.3 using Snellen.

Among the 220 eyes, CME was identified in 46 eyes (20.9%) of 30 RP patients; 32 eyes (69.6%) of 16 patients had bilateral macular edema, and 14 eyes (30.4%) of 14 patients had macular edema in only one eye. There was no difference in logMAR

BCVA or CRT between bilateral CME and unilateral CME. No significant difference was observed in patient age, sex, BCVA value, or pseudophakic status when comparisons were made between eyes with CME and those without CME (Table 1).

Among 14 patients with unilateral CME, 11 were selected for intraindividual comparison between the eye with CME and the fellow eye without CME. Three patients were excluded because their fellow eyes had either ineligible BCVA or OCT signals. As expected, the eyes with CME had a significantly greater CRT (308.7 ± 73.2 μ m vs. 231.7 ± 43.1 μ m; *P* = 0.005) and macular volume (9.4 ± 0.8 mm³ vs. 9.2 ± 0.6 mm³; *P* = 0.016) than the control fellow eyes without CME. Compared to the fellow eyes, eyes with CME had significantly worse BCVA (Snellen BCVA; 0.32 vs. 0.50; *P* = 0.046). Regarding photoreceptor integrity, eyes with CME showed greater photoreceptor IS/OS disruption (*P* = 0.008); 11 eyes with CME were classified as grade 1 (4 eyes), grade 2 (4 eyes), and grade 3 (3 eyes), while their non-CME fellow eyes were classified as grade 1 (8 eyes), grade 2 (3 eyes), and grade 3 (0 eyes).

Vitreomacular interface abnormalities (VMIA), including epiretinal membrane development or vitreomacular traction, were evident in over 40% of patients. The presence of VMIA was significantly higher in eyes with CME than in eyes without CME (64.2% vs. 36.8%, *P* < 0.001, χ^2 test). Low-level fluorescein leakage was evident in the macula of only 25.0% of macular edema patients (Table 1).

The extent of overall retinal degeneration did not differ between the eyes with CME and the eyes without CME. The proportion of nonrecordable, full-field ERGs did not differ between the two groups. Regarding the visual field parameters, neither MD nor central visual field sensitivity showed differences between the two groups (Table 1).

As expected, the average CRT was significantly higher in eyes with CME than in eyes without CME; mean CRT was 303.1 ± 81.8 μ m (range, 187–516 μ m) in the CME group and 209.2 ± 46.8 μ m (range, 128–312 μ m) in the non-CME group (*P* < 0.001, independent samples *t*-test). When AREDS subfield thickness values were compared, the average thickness values were greater in inner subfields, but not in outer subfields, among eyes with CME (*P* = 0.001, *P* = 0.095, respectively). Macular volume did not differ significantly between these two groups (*P* = 0.105). In terms of photoreceptor integrity, the IS/OS junction was better preserved in patients without CME, thus relatively more disrupted in those with CME (*P* = 0.016, χ^2 test and Bonferroni post hoc test). Eyes without CME were grade 2 since the degeneration encroached within 0.75 mm of the fovea (Fig. 1B), whereas eyes with CME were more likely to be grade 2 based on the presence of a discontinuous, interrupted IS/OS line within 0.75 mm of the fovea (Fig. 1E).

TABLE 2. Comparison of SD-OCT Parameters between Eyes with and without CME in Patients with Retinitis Pigmentosa

	CME, 46 Eyes, 20.9%	No CME, 174 Eyes, 79.1%	Overall, 220 Eyes	P Value
CRT, μm^*	303.1 \pm 81.8	209.2 \pm 46.8	229.9 \pm 68.6	<0.001
AREDS subfield retinal thickness, μm^*				
Inner subfield average	325.5 \pm 90.6	263.1 \pm 51.5	277.4 \pm 70.2	0.001
Outer subfield average	270.2 \pm 96.8	254.8 \pm 50.1	259.2 \pm 79.6	0.095
Macular volume, mm^3^*	9.2 \pm 1.3	8.7 \pm 1.4	8.8 \pm 2.2	0.105
IS/OS junctional status (%) [†]				
Grade 1, number of eyes	11 (23.9)	82 (47.1)	93 (42.3)	0.016
Grade 2, number of eyes	15 (32.6)	36 (20.7)	51 (23.2)	
Grade 3, number of eyes	20 (43.5)	56 (32.2)	76 (34.5)	
PR thickness, μm^*	103.6 \pm 38.4	96.8 \pm 43.7	97.4 \pm 42.1	0.121
OS+, μm^*	40.5 \pm 15.8	47.0 \pm 19.0	45.7 \pm 20.1	0.035

IS/OS junction status: grade 1: distinct, >1.5 mm; grade 2: discontinuous, <1.5 mm; grade 3: absent.

* Values are the mean \pm standard deviation and were analyzed with the independent samples *t*-test.

[†] Values were analyzed with a χ^2 test and the Bonferroni post hoc test.

With respect to photoreceptor atrophy, while PR did not significantly differ between the two groups ($P = 0.121$), the mean OS+ was significantly thinner in eyes with CME ($P = 0.035$) (Table 2).

Overall, no association was evident between BCVA values and CRT ($P = 0.072$, Pearson's correlation test). However, when the eyes were divided into two groups, those with and without CME, a significant association was observed between BCVA value and CRT within each group. When BCVA and CRT were compared, whereas eyes with thinner macula showed worse BCVA in eyes without CME (Pearson's coefficient: -0.690 [$P < 0.001$]), eyes with thicker macula showed worse

BCVA in eyes with CME (Pearson's coefficient: $+0.382$ [$P = 0.010$]) (Figs. 3B, 3A, respectively). In other words, among eyes with CME, a significantly worse BCVA was found in those with an increase in CRT. By contrast, among eyes without CME, a significantly worse BCVA was found in those with a decrease in CRT. The absence of an IS/OS junction (i.e., with junctions that were either discontinuous or absent) was observed more frequently in eyes with CME, in which photoreceptor segments were thinner and BCVA values significantly poorer than in eyes in which an IS/OS junction was apparent ($P < 0.001$) (Table 3). The ICC values for PR and OS+ were 0.95 (95% confidence interval [CI] 0.91–0.98) and 0.94 (95% CI 0.89–0.97), respectively, which showed strong reliability.

In eyes with CME, when a correlation was sought between logMAR BCVA and PR, eyes with decreased PR had worse BCVA (Pearson's coefficient: -0.221 [$P = 0.050$]). Also, as mentioned above, BCVA tended to become worse as CRT increased (Fig. 3A). Among 12 eyes with significant CME (CRT ≥ 350 μm), no eye had an intact IS/OS junction, and 10 (83.3%) showed an absent IS/OS junction (Fig. 4A). Regarding photoreceptor atrophy according to photoreceptor integrity in the CME group, OS+ significantly correlated with IS/OS integrity ($P = 0.010$) but CRT and PR did not ($P = 0.073$, $P = 0.264$, respectively) (Table 3).

However, among eyes without CME, eyes with thinner CRT had worse BCVA (Fig. 3B). A correlation between PR and BCVA showed the same tendency, as eyes with decreased PR had worse BCVA (Pearson's coefficient: -0.588 [$P < 0.001$]). In other words, both photoreceptor integrity and BCVA were poorer in eyes with a thinner macula. Among 71 eyes with significant atrophic thinning (CRT ≤ 200 μm), while only 5 (7.0%) had an intact IS/OS junction, 24 (33.8%) and 42 (59.2%) showed junctional disruption and an absent IS/OS junction, respectively (Fig. 4B). In terms of photoreceptor atrophy, eyes with disrupted IS/OS junctions also appeared to have thinner photoreceptor layers, contributing to poorer visual acuity (Table 3).

DISCUSSION

In the present study, we measured SD-OCT parameters in the macula of RP patients and attempted to explain the observed correlations between BCVA and each of several parameters in RP patients developing CME. Diagnosis of macular edema in RP patients was difficult before the era of OCT because of a lack of fluorescein dye leakage in such patients. Even after the advent

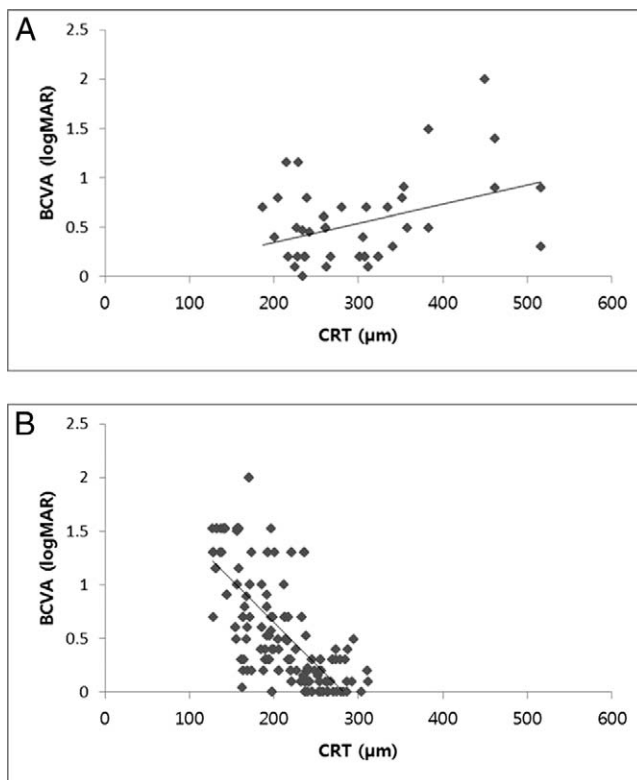


FIGURE 3. Correlations between BCVA (logMAR) values and central retinal thickness (CRT) in patients with retinitis pigmentosa with (A) and without (B) cystoid macular edema.

TABLE 3. BCVA and SD-OCT Measurements Classified in Terms of IS/OS Junctional Status in Patients with Retinitis Pigmentosa with and without CME

	CME				No CME			
	Grade 1, n = 11	Grade 2, n = 15	Grade 3, n = 20	P Value	Grade 1, n = 82	Grade 2, n = 36	Grade 3, n = 55	P Value
BCVA, logMAR	0.16 ± 0.07	0.45 ± 0.29	0.82 ± 0.42	<0.0001*†‡	0.18 ± 0.18	0.59 ± 0.41	1.14 ± 0.41	<0.0001*†‡
CRT, μm	260.7 ± 36.3	289.9 ± 66.9	336.3 ± 98.1	0.073‡	245.1 ± 27.0	190.6 ± 39.0	169.1 ± 32.1	<0.0001*†‡
PR, μm	109.3 ± 40.0	113.0 ± 35.5	92.7 ± 33.5	0.264	113.6 ± 31.2	94.2 ± 30.8	74.0 ± 32.5	<0.0001*†‡
OS+, μm	60.2 ± 10.2	43.8 ± 15.3	27.2 ± 13.9	0.010*†‡	61.9 ± 18.2	44.2 ± 15.3	27.6 ± 14.6	<0.0001*†‡
Nonrecordable ERG, number of eyes (%)	1/8 (12.5)	4/12 (33.3)	10/15 (66.7)	0.001*†‡	8/79 (10.1)	15/32 (46.9)	26/50 (52.0)	0.023*‡

All values are the mean ± standard deviation and were analyzed using a one-way ANOVA and Bonferroni post hoc test except for nonrecordable ERG. The latter was analyzed with Fisher's exact test and a χ^2 test with Bonferroni post hoc analysis for the CME group and non-CME group, respectively.

* Statistically significant differences between grade 1 and grade 2.

† Statistically significant differences between grade 2 and grade 3.

‡ Statistically significant differences between grade 1 and grade 3.

of time-domain OCT, it was not easy either to detect a small cyst in CME patients or to evaluate finer microstructural changes in photoreceptor thickness and IS/OS integrity.^{6,7,22}

We diagnosed macular edema in RP patients in whom cysts were clearly evident. Considering that RP is a degenerative retinal disease, it is appropriate to diagnose macular edema detected by SD-OCT with reference to normal retinal contours rather than employing measured retinal thicknesses. Using such diagnostic criteria, macular edema was detected by SD-OCT in 25.9% of our patients. The presence of CME in eyes with RP was not necessarily associated with loss of visual

acuity, and either an abnormally thin CRT or an abnormally thick CRT was associated with a worse BCVA. In a previous study, Oishi et al.¹⁷ failed to find any correlation between BCVA values and total retinal or photoreceptor thickness among 25 RP patients with CME. Rather, these authors emphasized that IS/OS integrity status was an important predictor of visual acuity. Interestingly, eyes with disrupted IS/OS junctions exhibited greater total retinal thickness and thinner photoreceptor thickness compared to eyes with distinct IS/OS junctions. Such findings are consistent with our report of a correlation between BCVA values and CRT, as well as with the positive correlation noted between BCVA value and IS/OS integrity in RP patients with CME.

In our present study, we included RP eyes without CME and analyzed relationships between BCVA and various OCT-derived parameters. RP eyes without CME had an abnormally thin CRT (mean ± SD; 209.2 ± 46.8 μm), suggesting that a significant number of eyes had atrophic maculae. Although the precise pathogenesis is still unknown, a subgroup of chronic patients might have had cystoid macular change before they developed atrophic thinning. In RP eyes without CME, significant correlations were evident, as expected, when the values of many parameters were compared in a pairwise manner. This was true of comparisons between BCVA and CRT, between BVCA and IS/OS integrity status, between BCVA and photoreceptor thickness, between photoreceptor thickness and IS/OS integrity status, and between CRT and IS/OS integrity status. In brief, in RP eyes without CME, as the macula became increasingly thin with the development of atrophy, the BCVA progressively decreased, in conjunction with the loss of IS/OS integrity and thinning of the photoreceptor layer. This observation was in line with those of previous qualitative studies.^{9,11,21}

In contrast to the findings in RP eyes without CME, in RP eyes with CME, photoreceptor thickness correlated only weakly with IS/OS integrity, and there was no correlation between CRT and IS/OS integrity. A tendency toward a worse BCVA with increasing CRT was noted in RP patients with CME involving the fovea, which might be explained by the higher risk of IS/OS disruption in eyes with significant macular edema. In RP patients, either an abnormally thin CRT due to atrophy or an abnormally thick CRT due to CME was associated with a worse BCVA. Together, the data allow us to hypothesize that once CME develops in RP patients, persistent macular thickening may lead to a disruption of photoreceptor IS/OS integrity, thinning of the photoreceptor layer, and a subsequent fall in visual acuity. Although the natural course of

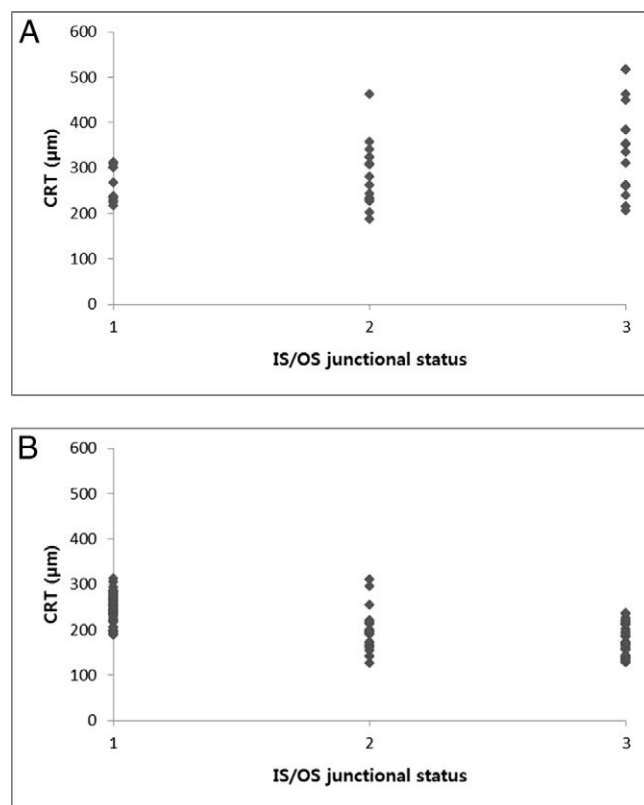


FIGURE 4. Central retinal thickness (CRT) distribution as a function of inner segment/outer segment (IS/OS) junctional status in patients with retinitis pigmentosa with (A) and without (B) cystoid macular edema.

CME associated with RP is not known, and, more importantly, not all RP patients suffer macular edema, it can be speculated that an edematous macula, once developed, may gradually become atrophic, with disruption of the photoreceptor IS/OS junction. In fact, Murakami et al.²³ recently proposed that a disrupted IS/OS line beneath the cystoid spaces is an additional mechanism of photoreceptor degeneration. A possible explanation for the lack of any significant correlation between CRT and IS/OS integrity status in our present study may be that some of the 46 eyes with CME were undergoing such a collapsing course.

VMIA became more readily identifiable in many retinal disease patients, including those with RP, after the introduction of high-resolution SD-OCT imaging.¹⁶ According to previous histopathologic and clinical studies, these VMIA have been frequently shown to contain proliferation of fibrous astrocytes that are located on the surface of the optic nerve and that progress to more peripheral areas.^{12,24} Among our patients, the prevalence of VMIA was greater (42.7%) than the prevalence of an epiretinal membrane (ERM) in normal individuals (2.2%–18.5%).^{25–28} Further, VMIA were more often found in eyes with CME than in those without CME. This may suggest that VMIA have a role to play in development of macular edema in RP patients. Improvement in BCVA has been observed after spontaneous resolution of CME following posterior vitreous detachment.²⁹ In the same context, vitreoretinal surgery that includes removal of a limiting membrane may effectively manage macular edema in such patients.³⁰

The present study had several limitations. First, because the data were derived from the interpretation of SD-OCT images, factors that interfere with reflectivity-based segmentation, such as fluid accumulation, may have adversely affected our results. Second, there was a possibility of overestimating PR with use of the posterior surface of the cystoid space as the reference plane in case the CME did not extend posteriorly to the ONL. To minimize this error in affected eyes, PR was measured at the central fovea, where the outer plexiform layer is very thin. An additional measurement of the photoreceptor parameter, OS+, was also performed. Third, this study was conducted on RP patients in a university hospital-based population; our patients differed from those of other cohorts in that most had advanced-stage disease. Compared with those in other OCT studies, our patients also exhibited significantly worse BCVA values and an elevated level of photoreceptor disruption.^{2,6,9,10} Furthermore, all patients were Asian (Korean), and our data may thus not be automatically generalizable to other races. Finally, the present study was cross sectional and thus could not yield accurate time-course information. Because the duration of macular edema can affect visual prognosis, the possibility of visual function impairment caused by longstanding edema should also be considered. A longitudinal investigation would be required to examine the association between duration of CME and foveal dysfunction.

Although several previous studies have determined a correlation between OCT morphology and visual acuity among RP patients with CME, the present work adds further convincing information in that it included a larger number of patients and made use of higher-resolution SD-OCT for all cases. In addition, this comparative study between RP eyes with CME and those without CME focused on the effect of photoreceptor integrity on visual acuity. To the best of our knowledge, this is the first such comparison to be reported in the literature.

In summary, CME in eyes with RP was not necessarily associated with loss of visual acuity. However, CME appeared to be associated with disruption of the PR IS/OS junction, resulting in foveal dysfunction and visual loss in RP patients.

References

1. Fishman GA, Fishman M, Maggiano J. Macular lesions associated with retinitis pigmentosa. *Arch Ophthalmol*. 1977;95:798–803.
2. Adackapara CA, Sunness JS, Dibernardo CW, Melia BM, Dagnelie G. Prevalence of cystoid macular edema and stability in oct retinal thickness in eyes with retinitis pigmentosa during a 48-week lutein trial. *Retina*. 2008;28:103–110.
3. Apushkin MA, Fishman GA, Janowicz MJ. Monitoring cystoid macular edema by optical coherence tomography in patients with retinitis pigmentosa. *Ophthalmology*. 2004;111:1899–1904.
4. Chung H, Hwang JU, Kim JG, Yoon YH. Optical coherence tomography in the diagnosis and monitoring of cystoid macular edema in patients with retinitis pigmentosa. *Retina*. 2006;26:922–927.
5. Hajali M, Fishman GA. The prevalence of cystoid macular oedema on optical coherence tomography in retinitis pigmentosa patients without cystic changes on fundus examination. *Eye (Lond)*. 2009;23:915–919.
6. Hirakawa H, Iijima H, Gohdo T, Tsukahara S. Optical coherence tomography of cystoid macular edema associated with retinitis pigmentosa. *Am J Ophthalmol*. 1999;128:185–191.
7. Hajali M, Fishman GA, Anderson RJ. The prevalence of cystoid macular oedema in retinitis pigmentosa patients determined by optical coherence tomography. *Br J Ophthalmol*. 2008;92:1065–1068.
8. Catier A, Tadayoni R, Paques M, et al. Characterization of macular edema from various etiologies by optical coherence tomography. *Am J Ophthalmol*. 2005;140:200–206.
9. Sandberg MA, Brockhurst RJ, Gaudio AR, Berson EL. The association between visual acuity and central retinal thickness in retinitis pigmentosa. *Invest Ophthalmol Vis Sci*. 2005;46:3349–3354.
10. Sandberg MA, Brockhurst RJ, Gaudio AR, Berson EL. Visual acuity is related to parafoveal retinal thickness in patients with retinitis pigmentosa and macular cysts. *Invest Ophthalmol Vis Sci*. 2008;49:4568–4572.
11. Grigoropoulos VG, Emfietzoglou J, Nikolaidis P, et al. Optical coherence tomography findings in patients with retinitis pigmentosa and low visual acuity. *Ophthalmic Surg Lasers Imaging*. 2010;41:35–39.
12. Vamos R, Tatrai E, Nemeth J, Holder GE, DeBuc DC, Somfai GM. The structure and function of the macula in patients with advanced retinitis pigmentosa. *Invest Ophthalmol Vis Sci*. 2011;52:8425–8432.
13. Aizawa S, Mitamura Y, Baba T, Hagiwara A, Ogata K, Yamamoto S. Correlation between visual function and photoreceptor inner/outer segment junction in patients with retinitis pigmentosa. *Eye (Lond)*. 2009;23:304–308.
14. Apushkin MA, Fishman GA, Alexander KR, Shahidi M. Retinal thickness and visual thresholds measured in patients with retinitis pigmentosa. *Retina*. 2007;27:349–357.
15. Rangaswamy NV, Patel HM, Locke KG, Hood DC, Birch DG. A comparison of visual field sensitivity to photoreceptor thickness in retinitis pigmentosa. *Invest Ophthalmol Vis Sci*. 2010;51:4213–4219.
16. Wolf S, Wolf-Schnurrbusch U. Spectral-domain optical coherence tomography use in macular diseases: a review. *Ophthalmologica*. 2010;224:333–340.
17. Oishi A, Otani A, Sasahara M, et al. Photoreceptor integrity and visual acuity in cystoid macular oedema associated with retinitis pigmentosa. *Eye (Lond)*. 2009;23:1411–1416.
18. Wolsley CJ, Silvestri G, O'Neill J, Saunders KJ, Anderson RS. The association between multifocal electroretinograms and

- OCT retinal thickness in retinitis pigmentosa patients with good visual acuity. *Eye (Lond)*. 2009;23:1524-1531.
19. Oishi A, Nakamura H, Tatsumi I, et al. Optical coherence tomographic pattern and focal electroretinogram in patients with retinitis pigmentosa. *Eye (Lond)*. 2009;23:299-303.
 20. Witkin AJ, Ko TH, Fujimoto JG, et al. Ultra-high resolution optical coherence tomography assessment of photoreceptors in retinitis pigmentosa and related diseases. *Am J Ophthalmol*. 2006;142:945-952.
 21. Rangaswamy NV, Patel HM, Locke KG, Hood DC, Birch DG. A comparison of visual field sensitivity to photoreceptor thickness in retinitis pigmentosa. *Invest Ophthalmol Vis Sci*. 2010;51:4213-4219.
 22. Hamada S, Yoshida K, Chihara E. Optical coherence tomography images of retinitis pigmentosa. *Ophthalmic Surg Lasers*. 2000;31:253-256.
 23. Murakami T, Nishijima K, Akagi T, et al. Optical coherence tomographic reflectivity of photoreceptors beneath cystoid spaces in diabetic macular edema. *Invest Ophthalmol Vis Sci*. 2012;53:1506-1511.
 24. Milam AH, Li ZY, Fariss RN. Histopathology of the human retina in retinitis pigmentosa. *Prog Retin Eye Res*. 1998;17:175-205.
 25. Fraser-Bell S, Ying-Lai M, Klein R, Varma R. Prevalence and associations of epiretinal membranes in latinos: the Los Angeles Latino Eye Study. *Invest Ophthalmol Vis Sci*. 2004;45:1732-1736.
 26. Kawasaki R, Wang JJ, Sato H, et al. Prevalence and associations of epiretinal membranes in an adult Japanese population: the Funagata study. *Eye (Lond)*. 2009;23:1045-1051.
 27. Duan XR, Liang YB, Friedman DS, et al. Prevalence and associations of epiretinal membranes in a rural Chinese adult population: the Handan Eye Study. *Invest Ophthalmol Vis Sci*. 2009;50:2018-2023.
 28. You Q, Xu L, Jonas JB. Prevalence and associations of epiretinal membranes in adult Chinese: the Beijing eye study. *Eye (Lond)*. 2008;22:874-879.
 29. Takezawa M, Tetsuka S, Kakehashi A. Tangential vitreous traction: a possible mechanism of development of cystoid macular edema in retinitis pigmentosa. *Clin Ophthalmol*. 2011;5:245-248.
 30. Garcia-Arumi J, Martinez V, Sararols L, Corcostegui B. Vitreoretinal surgery for cystoid macular edema associated with retinitis pigmentosa. *Ophthalmology*. 2003;110:1164-1169.