

Retinal and Choroidal Thickness in Myopic Anisometropia

Stephen J. Vincent, Michael J. Collins, Scott A. Read, and Leo G. Carney

Contact Lens and Visual Optics Laboratory, School of Optometry and Vision Science, Queensland University of Technology, Brisbane, Queensland, Australia

Correspondence: Stephen J. Vincent, Contact Lens and Visual Optics Laboratory, School of Optometry and Vision Science, Queensland University of Technology, Room B556, O Block, Victoria Park Road, Kelvin Grove 4059, Brisbane, QLD, Australia; sj.vincent@qut.edu.au.

Submitted: December 4, 2012

Accepted: March 3, 2013

Citation: Vincent SJ, Collins MJ, Read SA, Carney LG. Retinal and choroidal thickness in myopic anisometropia. *Invest Ophthalmol Vis Sci*. 2013;54:2445-2456. DOI:10.1167/iov.12-11434

PURPOSE. We compared the retinal thickness (RT) and choroidal thickness (ChT) between the fellow eyes of nonamblyopic myopic anisometropes.

METHODS. The eyes of 22 nonamblyopic myopic anisometropes (≥ 1 diopter [D] spherical equivalent refraction [SER] anisometropia) were examined using spectral domain optical coherence tomography (SD-OCT). Customized software was used to register, align, and average multiple foveal OCT B-scan images from each subject to enhance image quality. Two independent masked observers manually determined the RT and ChT from each SD-OCT image up to 2.5 mm nasal and temporal to the fovea. Axial length (AXL) was measured using optical low coherence biometry during relaxed accommodation.

RESULTS. The mean SER anisometropia was 1.74 ± 0.95 D and the mean interocular AXL difference was 0.58 ± 0.41 mm. There was no significant difference in foveal RT between the fellow eyes ($P > 0.05$). Mean subfoveal ChT was significantly thinner in the more myopic eye ($252 \pm 46 \mu\text{m}$) compared to the fellow, less myopic eye ($286 \pm 58 \mu\text{m}$) ($P < 0.001$). There was a moderate correlation between the interocular difference in subfoveal ChT and the interocular difference in AXL ($r = -0.50$, $P < 0.01$). Asian anisometropes displayed more regionally symmetrical (nasal-temporal) interocular differences in ChT profile compared to Caucasians.

CONCLUSIONS. RT was similar between the fellow eyes of myopic anisometropes; however, the subfoveal choroid was significantly thinner in the more myopic (longer) eye of this anisometric cohort. The interocular asymmetry in ChT correlated with the interocular difference in AXL.

Keywords: anisometropia, choroid, OCT, myopia, retina

The ocular response to manipulation of the visual environment in various animal species suggests that retinal image quality influences eye growth and refractive error development. Previous research, in which myopic or hyperopic defocus has been imposed using spectacle or contact lenses, has shown that various animal species rapidly modulate choroidal thickness (ChT) to adjust the position of the retina (axial length [AXL]) to optimize image quality.¹⁻⁵ In animal models of refractive error development, initial changes in choroidal thickness are followed by longer term changes in AXL due to scleral remodeling. Recently, compensatory changes and alterations in the normal diurnal rhythms of ChT and AXL also have been observed in human subjects in response to imposed defocus.^{6,7} These studies suggest that the choroid may have a role in human eye growth and refractive error development.

In humans, recent studies have established that ChT is influenced by a number of variables, including the time of day,^{8,9} retinal location,^{10,11} and age,^{11,12} while the influence of ethnicity is less clear.^{13,14} Retinal thickness (RT) also is influenced by the same variables (diurnal variation,¹⁵ retinal location,¹⁶ and age^{17,18}); however, different ethnic groups exhibit varying retinal thickness profiles primarily relating to foveal pit morphology.^{19,20} Refractive error and AXL also influence RT and ChT. Central (foveal) RT typically increases with increasing AXL and myopia,^{21,22} whereas the distribution of peripapillary retinal nerve fiber layer (RNFL) thickness varies with increasing myopia (generally a thinning in the RNFL).^{23,24}

Conversely, subfoveal ChT is correlated negatively with AXL, decreasing with increasing levels of myopia.²⁵⁻²⁷ The majority of these studies^{8,10-15,17-27} have used optical coherence tomography (OCT), an imaging technique that allows high resolution, in vivo visualization of the retina and choroid.

Anisometropia is a condition characterized by a difference in the refractive error between fellow eyes, typically due to an interocular difference in AXLs,²⁸ in particular the vitreous chamber depth (VCD).²⁹ It may be used as an experimental paradigm in refractive error research, since comparing the fellow eyes of the same anisometric subject allows for control of potential confounding intersubject variables (e.g., age, sex) and improved sensitivity in detecting a difference in the variable of interest with respect to refractive error or AXL. A number of studies have examined the interocular symmetry of RT in amblyopic anisometropes, with conflicting results.³⁰⁻⁴¹ However, to our knowledge only two studies have reported on between eye differences in nonamblyopic anisometropes, with comparisons limited to the macula³⁰ or RNFL surrounding the optic nerve head.^{30,40}

To date, ChT in myopic anisometropia has not been investigated in detail to our knowledge. Given the potential role or association of the choroid in the regulation of refractive state and emmetropization in humans, it is of interest to examine the interocular symmetry of ChT in anisometric eyes. Animal models of refractive error development often impose unilateral hyperopic defocus (i.e., an anisometric

stimulus), which results in an ocular response involving choroidal thinning, axial elongation, and the development of myopia in the experimental eye, proportional to the magnitude of imposed blur. Consequently, we wanted to determine whether such interocular asymmetries in ChT also were evident in human eyes with myopic anisometropia. In this experiment, we examined the RT and ChT in the more and less myopic eyes of nonamblyopic myopic anisometropes using high-resolution spectral domain optical coherence tomography (SD-OCT).

METHODS

Participants

We recruited total of 22 healthy adults (mean age 23 ± 5 years, 4 male and female) from the staff and students of Queensland University of Technology, Brisbane, Australia (QUT). The subjects had varied ethnic backgrounds, including East Asian ($n = 11$), Caucasian ($n = 10$), and Indian ($n = 1$). All subjects were nonamblyopic myopic anisometropes (minimum difference of 1.00 diopters [D] spherical-equivalent refraction [SER] between eyes) with best corrected visual acuity of 0.00 LogMAR or better in each eye, and an interocular difference in visual acuity of less than 0.10 LogMAR.

Screening

Before testing, subjects underwent a screening examination to determine subjective refraction, binocular vision, and ocular health status. All subjects were free of ocular and systemic disease, and had no history of ocular surgery or trauma. We included 15 soft contact lens wearers, but contact lens wear was ceased for 24 hours before participation. Rigid contact lens wearers were not included. Approval from the QUT Human Research Ethics Committee was obtained before commencement of the study and subjects gave written informed consent to participate. All subjects were treated in accordance with the tenets of the declaration of Helsinki.

Data Collection Procedures

Ocular biometrics were measured using a noncontact optical biometer (Lenstar LS 900; Haag Streit AG, Koeniz, Switzerland). This instrument is based on the principle of low coherence reflectometry and provides precise results⁴² for a range of axial biometric parameters, including central corneal thickness (CCT), anterior chamber depth (ACD), lens thickness (LT), and AXL (distance from the anterior cornea to the Retinal Pigment Epithelium [RPE]). The VCD also can be calculated using the Lenstar (Lenstar LS 900; Haag Streit AG) data. Five repeated biometric measurements were performed on each eye of all subjects.

Since AXL measurements may be influenced by accommodation,^{43,44} we used a Badal system (+12 D lens) viewed through a beamsplitter to ensure biometric measurements were captured during relaxed accommodation. The fixation target consisted of a back illuminated high-contrast target (n8 print, luminance 237 cd/m^2). Astigmatic refractive errors greater than 0.5 D were corrected using an auxiliary cylindrical lens placed between the Badal lens and the moveable target, correcting for vertex distance. Before measurements were performed, care was taken to align a letter from the target (viewed through the beamsplitter) to be coincident with the instrument's measurement beam. The target distance was altered to correct for the spherical ametropia and subjects were instructed to keep the target in sharp focus throughout the measurement procedures. The fellow eye was occluded.

Cross-sectional chorioretinal images of both eyes of each subject were obtained using a SD-OCT instrument (Copernicus SOCT-HR; Optopol Technology SA, Zawiercie, Poland). We used the "animation" scan; with each OCT measurement consisting of a 5 mm horizontal line scan (visual angle of approximately 16.3°) comprising of 50 B-scans (with each B-scan consisting of 1200 A-scans) centered on the fovea. The "chorioretinal" scanning mode was selected, which focuses the scan more posteriorly to improve choroidal imaging. Four OCT measurements were captured for each eye. The instrument (Copernicus SOCT-HR; Optopol Technology SA) was realigned and refocused between each measurement, and the internal fixation target was adjusted to compensate for the spherical equivalent refraction of each eye. Only OCT measurements with a quality index of greater than 4 were included for analysis (mean quality index of included scans 6.50 ± 1.22).

Data Analysis

Ocular biometric data obtained from the Lenstar (Lenstar LS 900, Haag Streit AG; CCT, ACD, LT, and AXL) were averaged for the more and less myopic eye of each subject. VCD was calculated as $AXL - (CCT + ACD + LT)$. Since three subjects did not exhibit a consistent visible peak from the posterior crystalline lens surface in the Lenstar A-scan output, the results presented for LT and VCD are for 19 subjects.

Custom written software was used to improve the signal-to-noise ratio of each OCT image using a technique described previously.^{15,45} This technique involves the registration and alignment of the 50 individual B-scans from each OCT measurement followed by the removal of outliers. The final averaged OCT image has significantly reduced speckle noise, which increases the visibility of the retinal layers and choroid. Of the four images captured for each eye, the single averaged image that gave the best visualization of the choroidal-scleral interface for each eye of each subject was selected for analysis.

Two independent, experienced observers, who were masked to the refractive error of each eye, performed the image analysis to determine RT and ChT using a manual procedure. Each observer selected a number of points along a series of defined boundaries (16 points for the outer boundary of the RPE, 16 points for the inner boundary of the inner limiting membrane [ILM], and 16 points for the boundary of the choroidal-scleral interface) within each average OCT image. The software then fits a smooth function (spline fit) along each of the boundaries (Fig. 1). Based on this manual segmentation, values were obtained for RT (ILM to RPE) and ChT (RPE to choroid). Each observer also placed a vertical reference line on each average OCT image to mark the center of the fovea. The reference line was positioned to dissect the deepest point in the center of the foveal pit that coincided with the peak in the inner/outer segment junction of the photoreceptors. This foveal line position was used as a reference point to average and compare RT and ChT data between the two observers. Measures of foveal pit morphology (depth and diameter) also were calculated.⁴⁶

Given that the transverse resolution of OCT images can be influenced by changes in the AXL of the eye,⁴⁷ we used the AXL measurements obtained with the Lenstar (Lenstar LS 900; Haag Streit AG) to adjust the transverse scale of the scans, using the approach outlined by Wagner-Schuman et al.²⁰ after calculating the reference AXL of the Copernicus SOCT-HR (Optopol Technology SA). Although it is known that the transverse scan length of the Cirrus high definition OCT (HD-OCT; Carl Zeiss Meditec, Dublin, CA) is calibrated to a model eye with an AXL of 24.46 mm ,^{20,47} to our knowledge there is no published value for the assumed AXL of the model eye used

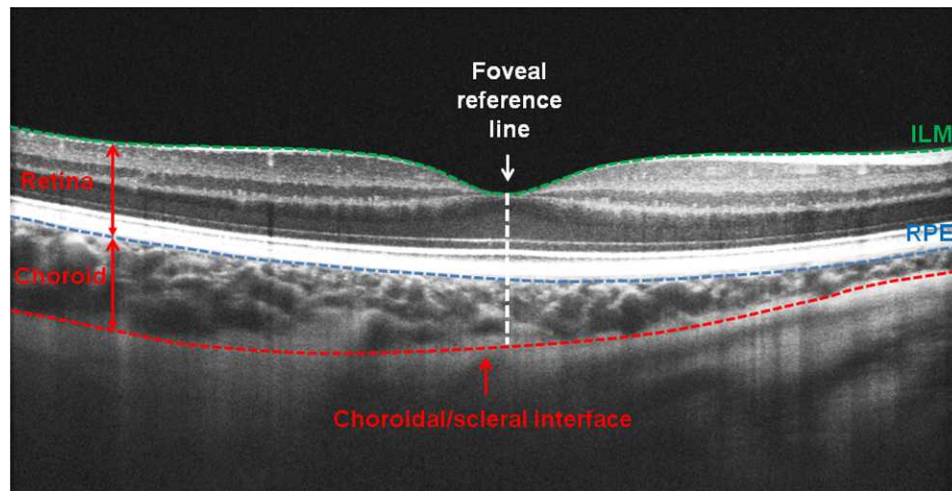


FIGURE 1. Example SD-OCT averaged B-scan of a right eye. Green dashed line: ILM. Blue dashed line: RPE. Red dashed line: choroidal/scleral interface. White dashed line: foveal reference line.

by the Copernicus SOCT-HR (Optopol Technology SA) for calibration of scan length. To determine the assumed AXL of the Copernicus SOCT-HR (Optopol Technology SA), we conducted a pilot study that included 20 healthy young adults with a wide range of refractive errors (and AXL ranging from 21.76–26.50 mm). For each subject, the transverse distance between common features in OCT images (e.g., retinal blood vessels) from the Copernicus SOCT-HR (Optopol Technology SA) and the Cirrus HD-OCT (Carl Zeiss Meditec), were compared. The distance between retinal features from the two instruments correlated closely ($r = 0.99$, slope = 1.03), however the mean transverse between feature distance was significantly shorter ($P < 0.001$) in the Copernicus SOCT-HR (Optopol Technology SA) images compared to the Cirrus HD-OCT (Carl Zeiss Meditec) by 0.035 ± 0.03 mm. Assuming that the difference in retinal feature distance between the two instruments is related solely to differences in the instrument calibration for AXL, this 0.035 mm difference corresponds to an assumed AXL used by the Copernicus SOCT-HR (Optopol Technology SA) instrument of 24.00 mm.

The RT and ChT values obtained by each observer were averaged at 0.25 mm intervals up to 2.50 mm nasal and temporal to the fovea for each eye. However, since the RPE or choroidal-scleral interface was indistinguishable in some subjects at the extreme periphery of the OCT image (2.50 mm nasal and temporal from the fovea) the data presented only extends up to 2.25 mm eccentricity (i.e., a 4.5 mm horizontal scan or visual angle of approximately 14.6°). The mean interobserver correlation was calculated for measures of RT and ChT at each 0.25 mm interval. To provide an estimate of the intraobserver repeatability of the RT and ChT measurements obtained from the averaged OCT images, additional analysis was conducted using a similar approach to that of Rahman et al.⁴⁸ Observers performed the manual analysis twice on the optimum averaged OCT scans of 5 randomly selected subjects (5 right and 5 left eyes) and were masked to the refractive error of the eye, and the RT and ChT values obtained from the first analysis of the OCT image. For each observer, the mean intraobserver difference (measurement 1 – measurement 2) and the standard deviation were calculated for each of the retinal locations. A two-tailed paired t -test was used to assess the statistical significance of the difference between measurements 1 and 2, and Pearson's correlation coefficient was used to describe the intraobserver agreement for the pairs of measurements.

Statistical Analysis

Paired t -tests were used to assess the interocular difference between the fellow eyes for measurements obtained from the Lenstar (Lenstar LS 900; Haag Streit AG), and Pearson's correlation was used to calculate the degree and statistical significance of associations between variables where appropriate. For the RT and ChT data obtained from the OCT, a repeated measures ANOVA was performed to examine the between eye differences of RT and ChT (a within subject factor of more/less myopic eye to retain the paired nature of the fellow eyes) with respect to retinal location (a within subject factor of eccentricity) when including all subjects. A repeated measures ANOVA (within subject factors of eye and eccentricity) also was performed after the removal of the one Indian subject, to examine the influence of ethnicity (Asian compared to Caucasian eyes, a between subject factor). A Bonferroni adjustment for multiple comparisons was applied to all post hoc pairwise comparisons.

RESULTS

The characteristics of the more and less myopic eyes of the anisometropic subjects are summarized in Table 1. VCD and AXL were significantly longer in the more myopic eye (VCD 17.77 ± 0.62 mm and AXL 25.11 ± 0.73 mm) compared to the fellow less myopic eye (VCD 17.23 ± 0.70 mm and AXL 24.53 ± 0.89 mm, both $P < 0.001$). The interocular differences in VCD ($n = 19$, $r = -0.89$) and AXL ($n = 22$, $r = -0.90$) were highly correlated with the magnitude of SER anisometropia (both $P < 0.0001$).

Interobserver and Intraobserver Agreement

Estimates of RT and ChT from the two independent observers correlated closely, with correlation coefficients ranging from 0.89 to 0.98 for RT and 0.87 to 0.97 for ChT for each of the 0.25 mm horizontal locations assessed. Measures of foveal RT and subfoveal ChT showed the greatest correlation between the two observers ($r = 0.99$ and 0.97 , respectively) and showed close agreement (mean interobserver difference: RT 1.3 ± 2.2 μ m, ChT 1.5 ± 13.7 μ m). There were no significant differences between the measurements obtained from the repeated analyses for both observers at all retinal locations measured for RT and ChT (paired t -test, $P > 0.05$). For foveal RT, the

TABLE 1. Characteristics of the More and Less Myopic Eyes of Anisometric Subjects

| | All, <i>n</i> = 22 | Asian, <i>n</i> = 11 | Caucasian, <i>n</i> = 10 |
|------------------------|--------------------|----------------------|--------------------------|
| Age, y | 23 ± 5 | 23 ± 4 | 24 ± 7 |
| Sex, M:F | 4:18 | 2:9 | 2:8 |
| More myopic eye, R:L | 11:11 | 7:4 | 4:6 |
| SER, D | | | |
| More myopic eye | -4.74 ± 2.39 | -4.45 ± 1.90 | -5.06 ± 3.02 |
| Less myopic eye | -3.00 ± 2.37 | -2.36 ± 1.94 | -3.64 ± 2.83 |
| Anisometropia | -1.74 ± 0.95 | -2.09 ± 1.18 | -1.43 ± 0.50 |
| CCT, mm | | | |
| More myopic eye | 0.528 ± 0.028 | 0.535 ± 0.031 | 0.520 ± 0.026 |
| Less myopic eye | 0.529 ± 0.027 | 0.534 ± 0.030 | 0.521 ± 0.023 |
| Interocular difference | -0.001 ± 0.006 | 0.000 ± 0.006 | -0.001 ± 0.006 |
| ACD, mm | | | |
| More myopic eye | 3.29 ± 0.33 | 3.32 ± 0.32 | 3.33 ± 0.27 |
| Less myopic eye | 3.29 ± 0.31 | 3.29 ± 0.32 | 3.36 ± 0.24 |
| Interocular difference | 0.00 ± 0.10 | 0.03 ± 0.10 | -0.03 ± 0.10 |
| LT, mm | | | |
| More myopic eye | 3.50 ± 0.23 | 3.46 ± 0.24 | 3.53 ± 0.25 |
| Less myopic eye | 3.50 ± 0.26 | 3.49 ± 0.23 | 3.51 ± 0.32 |
| Interocular difference | 0.00 ± 0.09 | -0.03 ± 0.08 | 0.02 ± 0.10 |
| VCD, mm | | | |
| More myopic eye | 17.77 ± 0.62 | 17.79 ± 0.54 | 17.76 ± 0.78 |
| Less myopic eye | 17.23 ± 0.70 | 17.12 ± 0.60 | 17.35 ± 0.87 |
| Interocular difference | 0.54 ± 0.30 | 0.67 ± 0.31 | 0.42 ± 0.22 |
| AXL, mm | | | |
| More myopic eye | 25.11 ± 0.73 | 25.07 ± 0.66 | 25.25 ± 0.81 |
| Less myopic eye | 24.53 ± 0.89 | 24.30 ± 0.92 | 24.83 ± 0.85 |
| Interocular difference | 0.58 ± 0.41 | 0.77 ± 0.47 | 0.42 ± 0.21 |

SER, CCT, ACD, LT, VCD, and AXL presented as mean ± SD. Interocular difference and anisometropia calculated as more – less myopic eye. Note: for LT and VCD measurements, all subjects *n* = 19, Asian subjects *n* = 10, Caucasian subjects *n* = 8.

mean intraobserver difference was $-0.43 \pm 3.27 \mu\text{m}$ for observer 1 ($r = 0.94$) and $-0.68 \pm 2.54 \mu\text{m}$ for observer 2 ($r = 0.93$). For subfoveal ChT, the mean intraobserver difference was $-0.71 \pm 5.52 \mu\text{m}$ for observer 1 ($r = 0.99$) and $-0.14 \pm 9.47 \mu\text{m}$ for observer 2 ($r = 0.98$). For all retinal locations, the average intraobserver standard deviation was $3.29 \mu\text{m}$ for RT and $7.38 \mu\text{m}$ for ChT, while intraobserver correlations ranged from 0.83 to 0.99 for RT and 0.94 to 0.99 for ChT.

Retinal Thickness

There were no significant differences between the more and less myopic eyes for measures of RT at any of the retinal locations measured when including all subjects in the analysis (repeated measures ANOVA, between eye $P = 0.65$ and eye by eccentricity $P = 0.45$). Figure 2A highlights the symmetry between fellow eyes for RT at the fovea, and up to 2.25 mm nasal and temporal to the fovea. There were no significant differences between the fellow eyes for measures of foveal pit depth (more myopic $123 \pm 20 \mu\text{m}$ and less myopic $126 \pm 20 \mu\text{m}$, $P = 0.66$) or diameter (more myopic $2253 \pm 260 \mu\text{m}$ and less myopic $2267 \pm 208 \mu\text{m}$, $P = 0.67$).

Choroidal Thickness

Choroidal thickness was significantly thinner in the more myopic eyes over a range of eccentricities (repeated measures ANOVA, eye by eccentricity $P = 0.01$). The interocular difference was greatest at the fovea (more myopic eyes $253 \pm 46 \mu\text{m}$ and less myopic eyes $286 \pm 59 \mu\text{m}$, $P = 0.002$),

and was statistically different between the fellow eyes from 0.25 mm temporal to 0.75 mm nasal to the fovea (Fig. 3A). The interocular difference in subfoveal ChT was moderately correlated with the degree of axial anisometropia ($r = -0.50$, $P = 0.02$) and the interocular difference in VCD ($r = -0.72$, $P = 0.0005$, Table 2). When the degree of axial anisometropia exceeded approximately 0.5 mm (~1.5 D SER) the more myopic eye always had a thinner subfoveal ChT compared to the fellow eye (range, 25–100 μm thinner). When the interocular AXL difference was less than 0.5 mm, the interocular subfoveal ChT difference ranged from approximately 20 μm thinner to 40 μm thicker in the more myopic eye.

Ethnicity

Ethnic differences were observed in the RT (repeated measures ANOVA, ethnicity by eccentricity $P = 0.005$, Figs. 2B, 2C) and ChT (repeated measures ANOVA, ethnicity by eccentricity $P = 0.008$) profiles (Figs. 3B, 3C). The mean SER anisometropia (and interocular AXL difference) was $1.43 \pm 0.50 \text{ D}$ ($0.42 \pm 0.21 \text{ mm}$) and $2.09 \pm 1.18 \text{ D}$ ($0.77 \pm 0.47 \text{ mm}$) for the Caucasian and Asian subjects, respectively (Table 1). For the Caucasian anisometropes no significant between eye differences in RT were observed at any retinal locations measured. Asian eyes, however, had a slightly thicker mean RT in the more myopic eyes at the fovea (more myopic $213 \pm 20 \mu\text{m}$, less myopic $209 \pm 19 \mu\text{m}$) and 0.25 mm nasal to the fovea (more myopic $240 \pm 20 \mu\text{m}$, less myopic $235 \pm 21 \mu\text{m}$, $P = 0.01$ and $P = 0.02$, respectively). However, the more myopic

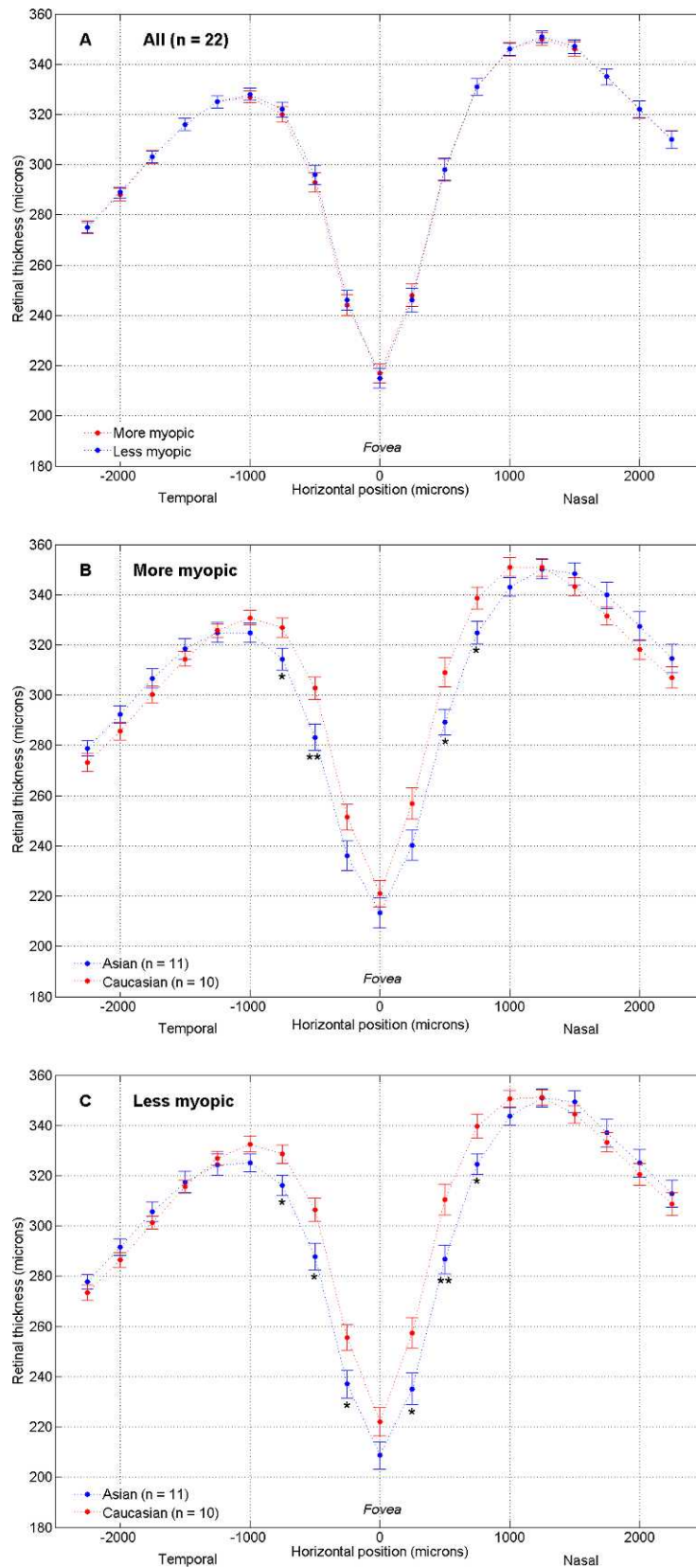


FIGURE 2. Mean retinal thickness as a function of eccentricity relative to the fovea for the more and less myopic eyes of all anisometropes (A), and retinal thickness of the more (B) and less (C) myopic eyes for the Asian and Caucasian anisometropes. *Significant difference between ethnic groups, $P < 0.05$. ** $P \leq 0.01$ (P values of post hoc comparisons with Bonferroni adjustment from repeated measures ANOVA). Error bars represent 1 SEM.

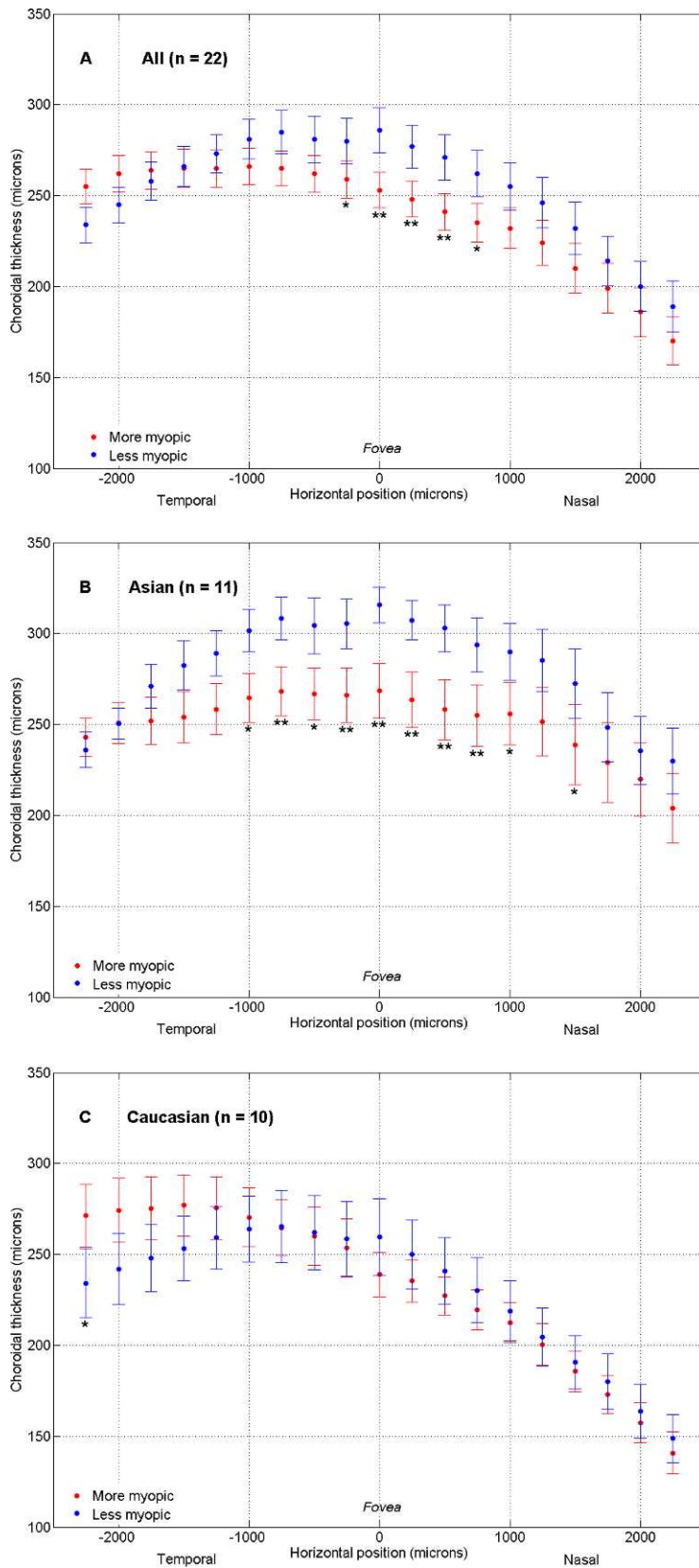


FIGURE 3. Mean choroidal thickness as a function of eccentricity relative to the fovea for the more and less myopic eyes of all anisometropes (A), Asian anisometropes (B), and Caucasian anisometropes (C). *Significant interocular difference $P < 0.05$. ** $P \leq 0.01$ (P values of post hoc comparisons with Bonferroni adjustment from repeated measures ANOVA). Error bars represent 1 SEM.

TABLE 2. Correlations Between the Interocular Difference in Foveal RT and Subfoveal ChT With the Interocular Difference in VCD, AXL, and SER for all Anisometric Subjects, and Asian and Caucasian Subgroups

| Correlation | All | | | Asian | | | Caucasian | | |
|-------------|----------|----------|----------|----------|----------|----------|-----------|----------|----------|
| | <i>n</i> | <i>r</i> | <i>P</i> | <i>n</i> | <i>r</i> | <i>P</i> | <i>n</i> | <i>r</i> | <i>P</i> |
| RT | | | | | | | | | |
| VCD | 19 | 0.40 | 0.09 | 10 | 0.32 | 0.37 | 8 | 0.34 | 0.41 |
| AXL | 22 | 0.35 | 0.11 | 11 | 0.12 | 0.73 | 10 | 0.31 | 0.38 |
| SER | 22 | -0.29 | 0.19 | 11 | -0.01 | 0.98 | 10 | -0.43 | 0.21 |
| ChT | | | | | | | | | |
| VCD | 19 | -0.72 | <0.001* | 10 | -0.68 | 0.03* | 8 | -0.69 | 0.06 |
| AXL | 22 | -0.50 | 0.02* | 11 | -0.31 | 0.35 | 10 | -0.75 | 0.01* |
| SER | 22 | 0.35 | 0.11 | 11 | 0.25 | 0.46 | 10 | 0.35 | 0.32 |

* *P* < 0.05.

eyes displayed a slightly thicker RT (5 μ m) 0.50 mm temporal to the fovea (*P* = 0.04). Apart from these retinal locations, Asian eyes displayed similar RT between the fellow eyes. Ethnic differences in RT profile are highlighted in Figures 2B and 2C. Asian eyes displayed significantly thinner parafoveal (250–750 μ m nasal and temporal from the fovea) RT compared to Caucasian eyes (i.e., a deeper and wider foveal pit). Foveal pit depth was not significantly different between the Asian (more myopic 126 \pm 22 μ m, less myopic 131 \pm 21 μ m) and Caucasian (more myopic 121 \pm 20 μ m, less myopic 122 \pm 19 μ m) anisometropes, but the foveal pit diameter was significantly greater in the more and less myopic eyes of the Asian anisometropes compared to the Caucasians (more myopic 2422 \pm 221 μ m and 2079 \pm 184 μ m, *P* = 0.001, less myopic 2430 \pm 208 μ m and 2094 \pm 258 μ m, *P* = 0.004).

Although the Asian and Caucasian subgroups had similar AXL for the more and less myopic eyes (Table 1), on average the Asian eyes had thicker choroids compared to Caucasian eyes, most noticeably in the region nasal to the fovea (repeated measures ANOVA, ethnicity by eccentricity *P* = 0.008, Figs. 3B, 3C). The more myopic eyes of the Asian cohort had a significantly thicker ChT (range, 44–63 μ m thicker) from 1 to 2.25 mm nasal to the fovea, compared to the more myopic eyes of the Caucasians (*P* < 0.05). Similarly, the ChT of the less myopic eyes of the Asian subjects was significantly thicker than the less myopic eyes of the Caucasians (range, 68–81 μ m thicker) from the fovea extending to 2.25 mm nasal to the fovea (*P* \leq 0.01).

Caucasian subjects displayed a high degree of ChT symmetry between the more and less myopic eyes at all of the retinal locations measured (interocular difference in ChT ranging from 37 μ m thicker to 20 μ m thinner in the more myopic eye), except for 2.25 mm temporal to the fovea where the choroid of the less myopic eye was significantly thinner (*P* = 0.04, Fig. 3C). Conversely, Asian subjects displayed a significantly thinner ChT in the more myopic eye over a larger range of retinal locations, extending from 1 mm temporal to the fovea to 1 mm nasal of the fovea (Fig. 3B). Therefore, the interocular differences observed in the analysis including all anisometric subjects primarily was due to the interocular ChT asymmetry in the Asian subjects.

In the Asian anisometropes, the interocular difference in ChT was relatively symmetrical at corresponding nasal and temporal locations (e.g., 1000 μ m nasal vs. 1000 μ m temporal) compared to the Caucasian subjects (Figs. 3B, 3C). Figure 4 highlights the degree of symmetry for the interocular difference in ChT at corresponding nasal and temporal locations for the two ethnic groups. The slope of the Caucasian data (-2.25), determined using simple linear regression, was

significantly different from a slope of 1 (i.e., slope of 1 would indicate a perfect symmetry in the interocular difference in ChT between corresponding nasal and temporal locations, *P* = 0.02), while the Asian data (slope of 1.28) was not significantly different from a slope of 1 (*P* = 0.30).

DISCUSSION

In our study we used the refractive condition of anisometropia to control for potential confounding variables (e.g., age, sex, diurnal variation) to examine the relation between RT and ChT, and the magnitude of refractive error and AXL. Anisometric subjects displayed highly symmetric anterior segment parameters between the fellow eyes (Table 1), including CCT, ACD, and IT, which is consistent with previous studies that have reported that asymmetric axial elongation of the vitreous chamber is the primary cause of myopic anisometropia in populations with and without ocular abnormalities (i.e., pathology and amblyopia).^{28,29,49–52}

Retinal Thickness

A high degree of foveal RT symmetry between fellow eyes has been observed in pediatric⁵³ (mean interocular difference approximately 1 μ m) and adult⁵⁴ populations (mean interocular difference 3.5 \pm 14.5 μ m), and also up to 3 mm parafoveally.²⁰ However, none of these studies reported in detail on the refractive status of the populations examined. It has been suggested that functional differences observed between amblyopic and fellow nonamblyopic eyes also may manifest as a structural interocular asymmetry at a lower level of the visual pathway (e.g., the RNFL). Consequently, several studies have compared the interocular symmetry of peripapillary and macular retinal thickness between the fellow eyes of amblyopic anisometropes,^{30–41} with conflicting results, but few studies have examined the between eye difference in nonamblyopic anisometropes.^{30,40} We observed no significant difference in RT between the fellow eyes of nonamblyopic myopic anisometropes at the fovea or retinal locations up to 2.25 mm nasal and temporal to the foveal center (mean foveal interocular difference 2 μ m). There was no correlation between the interocular difference in VCD, AXL, or SER and the interocular difference in RT (all *P* > 0.05, Table 2).

Yen et al. found no significant difference in peripapillary RNFL thickness between the fellow eyes of myopic anisometropes (mean interocular difference 0.4 \pm 0.8 μ m, mean SER anisometropia 3.1 D).⁴⁰ Similarly, Al-Haddad et al. also only observed a small difference between the fellow eyes of nonamblyopic anisometropes for central macular thickness

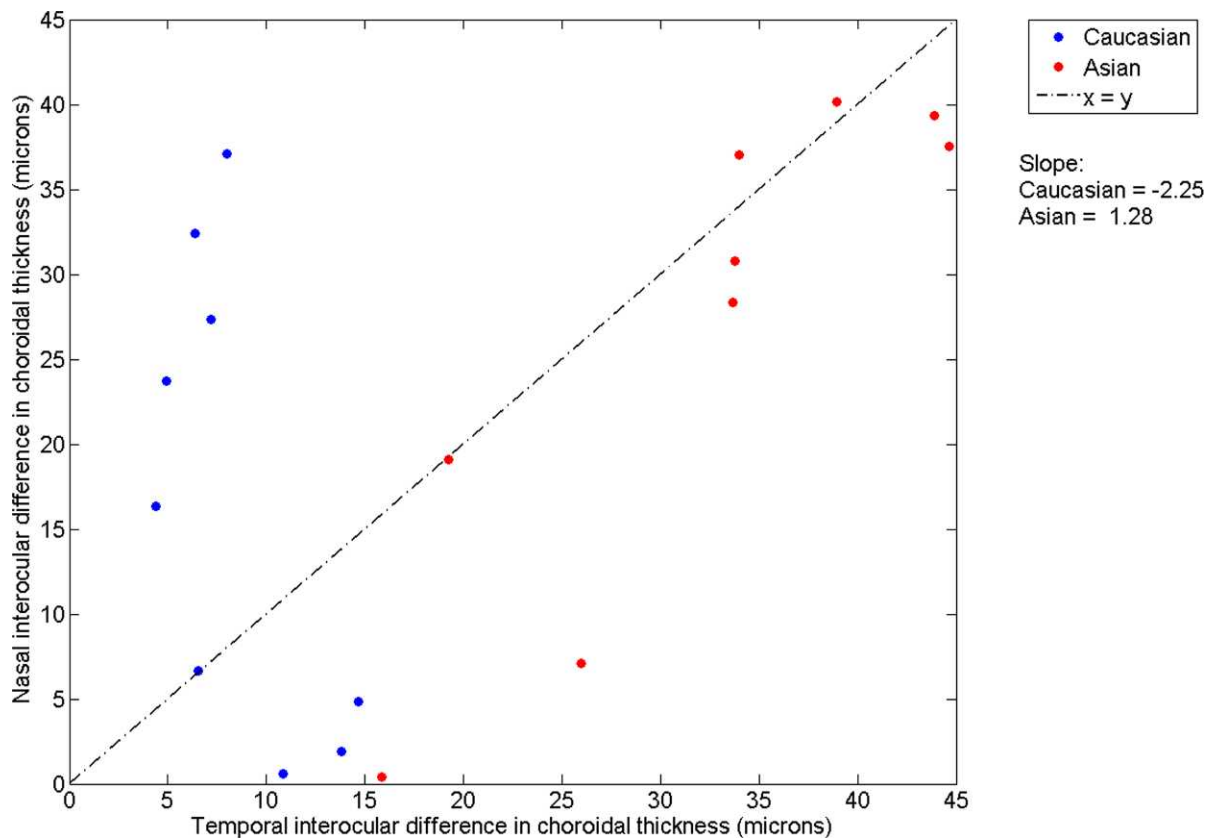


FIGURE 4. Scatter plot of the absolute interocular difference (more – less myopic eye) in choroidal thickness at corresponding nasal and temporal retinal locations. The *dashed line* ($x = y$) represents perfect symmetry between corresponding nasal and temporal locations for interocular differences in choroidal thickness.

(8.6 μm , mean anisometropia 1.62 D), which did not reach statistical significance.³⁰ Based on the spread (standard deviation) of the SER, the cohort reported by Al-Haddad et al. may have contained hyperopic and myopic anisometropes.³⁰ Our findings suggested that there is a high degree of interocular symmetry for measures of foveal and parafoveal RT in relatively low levels of myopic anisometropia. However, in larger magnitude cases of myopic anisometropia in which the more myopic eye is likely to have undergone more substantial structural change (excessive axial elongation), interocular differences in RT may be more apparent.⁵⁵

Examination of the Asian anisometric subjects separately revealed a significantly greater RT in the more myopic eye at the fovea and 0.25 mm nasally (4 and 5 μm thicker, respectively), while the Caucasian subjects showed no interocular difference in RT at any of the retinal locations measured. Ethnic differences in RT profile, primarily foveal pit diameter, were observed in the more and less myopic eyes. Asian eyes typically had wider and deeper foveal pits compared to Caucasian eyes (i.e., Caucasians had a thicker foveal RT, which increased at a faster rate with increasing horizontal eccentricity), but the ethnic difference only reached statistical significance for foveal pit diameter. Similarly, Wagner-Schuman et al. observed wider and deeper foveal pits in African-Americans compared to Caucasians.²⁰ In general, the ethnic trend observed in our subjects for measures of RT was similar to the findings of Nolan et al., who compared the retinal profile in Caucasians and non-Caucasians, but failed to account for the influence of AXL upon transverse magnification.¹⁹

Choroidal Thickness

The subfoveal choroid was significantly thinner in the more myopic eye of anisometric subjects compared to the fellow less myopic eye. The interocular difference in subfoveal ChT correlated with the interocular difference in AXL and the interocular difference in VCD. Chen et al. examined the right-left eye symmetry of ChT in a population of predominantly isometric adults (mean axial anisometropia 0.17 \pm 0.27 mm; range, 0-1.57 mm).⁵⁶ ChT was similar between fellow eyes (mean relative subfoveal interocular difference 1.0 \pm 42 μm [right – left eye]). Greater interocular differences in ChT were observed at more peripheral locations 3 mm parafoveally (nasal 13.6 \pm 43 μm , temporal –2.9 \pm 61 μm). Similar to our findings, they observed a moderate negative correlation between the interocular difference in subfoveal ChT and the interocular difference in AXL. However, they attributed this relationship to two extreme outliers in the data set (i.e., anisometropes). Spaide et al. also examined the interocular symmetry of ChT in a small adult cohort with subfoveal ChT moderately correlated between the fellow eyes ($r = 0.82$); however, the refractive error and AXL were not reported.⁵⁷

While to our knowledge no studies have measured ChT directly in anisometric eyes, the interocular symmetry of measurements associated with choroidal blood flow has been investigated. Shih et al. measured the ocular pulse amplitude (OPA) in anisometric subjects, and when the magnitude of anisometropia was greater than 3 D, there was a small but significant interocular difference in OPA.⁵⁸ Similarly, Lam et al. measured the OPA and pulsatile ocular blood flow (POBF) in axial anisometropes (>2.0 D SER anisometropia), and found

these measures were significantly lower in the more myopic eye.⁵⁹ These studies suggest that increasing myopia or AXL is associated with reduced choroidal blood flow, and that interocular differences can be detected between anisometric eyes.^{58,59} However, OPA and POBF may be influenced by artefacts associated with various factors, including AXL⁶⁰ and IOP,⁶¹ and are considered estimates of choroidal blood flow circulation rather than a direct measure of ChT. Our finding of reduced ChT in the more myopic eyes of anisometropes using high resolution SD-OCT is consistent with the predictions of choroidal thickness from these previous studies.

The primary role of the choroid is nourishment and thermoregulation of the retina; however, it also is thought to have a role in emmetropization and refractive error development in animals and humans.⁶² It is well established that a variety of young animal species undergo rapid changes in choroidal thickness in response to imposed defocus (via spectacles or contact lenses), which in turn adjusts the position of the retina to maintain clear vision. Given the cross-sectional nature of our study, we cannot be sure if the relative thinning of the choroid in the more myopic eye of our anisometric subjects is a cause or consequence of asymmetric refractive development; that is, whether the choroid of the more myopic eye has passively thinned (relative to the less myopic eye) due to expansion of the vitreous chamber during myopia development or if the choroid has thinned asymmetrically in response to different optical signals between the eyes to move the retina to optimize retinal image quality for each eye independently.

Using the approach described by Troilo et al.,⁶³ we modeled the choroid as an isovolumetric shell of a sphere to calculate the expected interocular difference in subfoveal ChT due to a simple passive stretch associated with expansion of the globe. By using the mean AXL of the more and less myopic eyes, and the mean subfoveal ChT of the less myopic eyes, we calculated the predicted ChT of the more myopic eye (assuming a constant choroidal volume). Based on these calculations we found that the predicted interocular difference in subfoveal ChT accounted for only approximately 40% of the measured interocular difference in ChT for all anisometropes (predicted 13 μ m, observed 33 μ m), Asian anisometropes (predicted 18 μ m, observed 48 μ m), and Caucasian anisometropes (predicted 8 μ m, observed 21 μ m). While this analysis makes a number of assumptions (e.g., a spherical globe with equal expansion in all directions), this finding suggests that the interocular differences in ChT between the fellow eyes of anisometropes are not fully accounted for by a simple passive stretch associated with the interocular difference in eye size alone.

Read et al. imposed short-term (60 minutes) monocular diffuse blur and hyperopic defocus (3 D) in adult humans, and observed compensatory axial elongation associated with choroidal thinning in the defocused eye.⁶ They proposed that chronic, low level hyperopic blur or degradation in retinal image quality may promote short-term changes in ChT and longer term changes in AXL, resulting in myopia development. If the difference in the ChT between the fellow eyes of anisometropes is the result of an active response to different visual inputs, then one might expect to find significant differences in the optical characteristics between the more and less myopic eyes. However, contrary to this expectation, several cross-sectional studies of myopic anisometropes have shown similar levels of higher order aberrations between fellow eyes^{51,64} or better optical quality in the more myopic eye.⁶⁵

The ciliary muscle transmits tension to the choroid during accommodation,⁶⁶ and this has been proposed as a possible mechanical stimulus contributing to myopia development. Since ciliary body thickness is greater in myopic compared to

nonmyopic children⁶⁷ and increases with increasing AXL in adults,⁶⁸ it has been hypothesized that a thickened, poorly contracting ciliary muscle could lead to accommodative dysfunction and a lag of accommodation (i.e., hyperopic retinal defocus during near work), which subsequently stimulates axial elongation and choroidal thinning. In the case of anisometropia, this would require an asymmetry in ciliary body thickness or function to produce unequal hyperopic blur between the eyes, given the assumed consensual nature of accommodation. Muftuoglu et al. examined ciliary body thickness in unilateral high myopic anisometropes (mean anisometropia approximately 8 D), and observed significant ciliary body thickening in the more myopic eye compared to the fellow near emmetropic eye.⁶⁹ However, the interocular difference in ciliary body biometrics did not correlate with the degree of anisometropia. Alternatively, a thicker ciliary muscle potentially could act as a restrictive force, which accentuates axial elongation of the globe (rather than eye growth in all directions), resulting in choroidal thinning posteriorly in the more myopic eye.⁶⁷

In the more and less myopic eyes, the choroid was thinnest in the nasal region and thickest in the foveal-temporal region, which is in general agreement with previous studies examining ChT in healthy eyes.^{11,12,56,57} It has been suggested that this region of thinner choroid nasal to the fovea (i.e., between the fovea and optic nerve) is most susceptible to change during myopia development. A temporal crescent adjacent to the optic nerve head (peripapillary atrophy) is often seen in myopic patients and is thought to be chorioretinal stretching during axial elongation exposing the underlying sclera.⁷⁰ The magnitude of myopia progression in young Korean children has been shown to correlate with changes in the optic nerve head and an increase in temporal peripapillary atrophy.⁷¹ However, in our anisometric subjects, while the interocular difference in ChT varied with eccentricity, the largest interocular differences were at the fovea and within 1 mm parafoveally, not in the region closest to the temporal aspect of the optic nerve head (nasal to the fovea).

Singh et al. used magnetic resonance imaging to measure ocular volume and AXL, and characterize the 3-D shape of the globe in a small group of subjects.⁷² They observed a large variation in globe shape (sphericity) between subjects and regional asymmetries within subjects (i.e., nasal and temporal). While ChT was not measured, they postulated that ocular volume and regional variations in the posterior segment contour may influence choroidal blood flow. The interocular differences in subfoveal and parafoveal ChT observed in our study could be explained potentially by regional variations in vitreous chamber expansion (i.e., axial but not transverse expansion) during myopia development.

Interestingly, we observed significant interocular differences in ChT profiles of Asian anisometropes, while Caucasians showed little difference in ChT between the fellow eyes. To date, the influence of ethnicity upon ChT remains unclear. Mwanza et al. found no significant difference in ChT between Caucasian, African, Hispanic, and Asian subjects; however, this analysis only included two subjects of Asian descent.¹³ Branchini et al. observed a similar trend, but was limited to five Asian participants.¹⁴ Logan et al. used peripheral refraction data to calculate the posterior retinal contour in Asian and Caucasian myopic anisometropes (mean interocular AXL difference 1.39 mm).²⁹ Caucasians exhibited a nasal-temporal asymmetry in the posterior retinal contour difference between the fellow eyes (i.e., the interocular difference in AXL was greater nasally compared to temporally). However, in Asian anisometropes, the interocular difference in AXL was similar between corresponding nasal and temporal locations. Our ChT results are consistent with these earlier findings, since we

observed relatively symmetrical interocular differences in ChT at corresponding nasal and temporal locations in Asians, while in Caucasians the choroidal thinning in the more myopic eye was restricted to a region nasal to the fovea, although this difference did not reach statistical significance. There are various speculative hypotheses that could explain such ethnic differences in interocular ChT profiles observed between Asian and Caucasian eyes, such as differences in scleral composition, anatomic differences driving the direction of globe expansion during refractive development, or asymmetries in the optics relative to the line of sight.

In our cohort of myopic anisometropes, both eyes within the one visual system had undergone abnormal emmetropization to different extents. While this approach of examining fellow myopic eyes is not an ideal contralateral “test-control” experiment, it allows a highly controlled, relative comparison within the spectrum of myopic refractive errors. Examination of unilateral myopic anisometropes (i.e., when one eye is emmetropic and the fellow eye myopic) may provide further insight into structural differences between myopic and emmetropic eyes, or mechanisms involved in the regulation of eye growth. In addition to the body of work conducted on various animal species, our study has identified that adult human myopic anisometropes (in particular, Asian anisometropes) also exhibit interocular differences in choroidal thickness proportional to the interocular difference in AXL. Further longitudinal research during the period of myopia development examining the association between eye shape, central and peripheral ChT, and retinal image quality is required to determine the causal nature of this relationship.

CONCLUSIONS

To our knowledge, this is the first study to measure ChT directly in a population of nonamblyopic myopic anisometropes. We observed only small differences in RT between the fellow eyes; however, subfoveal and nasal parafoveal ChT was significantly thinner in the more myopic (longer) eye of our anisometropic cohort. The interocular difference in subfoveal ChT correlated with the magnitude of axial anisometropia and the interocular difference in VCD. Asian eyes exhibited small but significant differences in RT (wider and deeper foveal pits) and ChT (more symmetric interocular differences in ChT at corresponding nasal and temporal locations) profiles compared to Caucasian eyes. These findings highlight that relatively low degrees of asymmetric myopia development in the absence of amblyopia are associated with asymmetric choroidal thinning. Future studies to determine accurately peripheral AXL in anisometropic eyes, and investigate the causality of the relationship between ChT and vitreous chamber elongation will help to improve the understanding of these factors in relation to myopia development.

Acknowledgments

The authors thank Payel Chatterjee and Katie Dwyer for assistance with data analysis.

Supported by an Australian Research Council Discovery Early Career Researcher Award (DE1201434; SAR).

Disclosure: **S.J. Vincent**, None; **M.J. Collins**, None; **S.A. Read**, None; **L.G. Carney**, None

References

- Hung LE, Wallman J, Smith EL III. Vision-dependent changes in the choroidal thickness of macaque monkeys. *Invest Ophthalmol Vis Sci.* 2000;41:1259-1269.
- Nickla DL, Wildsoet C, Wallman J. Compensation for spectacle lenses involves changes in proteoglycan synthesis in the sclera and choroid. *Curr Eye Res.* 1997;16:320-326.
- Wallman J, Wildsoet C, Xu A, et al. Moving the retina: choroidal modulation of refractive state. *Vision Res.* 1995;35:37-50.
- Wildsoet C, Wallman J. Choroidal and scleral mechanisms of compensation for spectacle lenses in chicks. *Vision Res.* 1995; 35:1175-1194.
- Wildsoet CF. Active emmetropization—evidence for its existence and ramifications for clinical practice. *Ophthalmic Physiol Opt.* 1997;17:279-290.
- Read SA, Collins MJ, Sander BP. Human optical axial length and defocus. *Invest Ophthalmol Vis Sci.* 2010;51:6262-6269.
- Chakraborty R, Read SA, Collins MJ. Monocular myopic defocus and daily changes in axial length and choroidal thickness of human eyes. *Exp Eye Res.* 2012;103:47-54.
- Tan CS, Ouyang Y, Ruiz H, Sadda SR. Diurnal variation of choroidal thickness in normal, healthy subjects measured by spectral domain optical coherence tomography. *Invest Ophthalmol Vis Sci.* 2012;53:261-266.
- Chakraborty R, Read SA, Collins MJ. Diurnal variations in axial length, choroidal thickness, intraocular pressure, and ocular biometrics. *Invest Ophthalmol Vis Sci.* 2011;52:5121-5129.
- Ikuno Y, Maruko I, Yasuno Y, et al. Reproducibility of retinal and choroidal thickness measurements in enhanced depth imaging and high-penetration optical coherence tomography. *Invest Ophthalmol Vis Sci.* 2011;52:5536-5540.
- Margolis R, Spaide RF. A pilot study of enhanced depth imaging optical coherence tomography of the choroid in normal eyes. *Am J Ophthalmol.* 2009;147:811-815.
- Manjunath V, Taha M, Fujimoto JG, Duker JS. Choroidal thickness in normal eyes measured using Cirrus HD optical coherence tomography. *Am J Ophthalmol.* 2010;150:325-329.
- Mwanza JC, Hochberg JT, Banitt MR, Feuer WJ, Budenz DL. Lack of association between glaucoma and macular choroidal thickness measured with enhanced depth-imaging optical coherence tomography. *Invest Ophthalmol Vis Sci.* 2011;52: 3430-3435.
- Branchini L, Regatieri CV, Flores-Moreno I, Baumann B, Fujimoto JG, Duker JS. Reproducibility of choroidal thickness measurements across three spectral domain optical coherence tomography systems. *Ophthalmology.* 2012;119:119-123.
- Read SA, Collins MJ, Alonso-Caneiro D. Diurnal variation of retinal thickness with spectral domain OCT. *Optom Vis Sci.* 2012;89:611-619.
- Shahidi M, Zeimer RC, Mori M. Topography of the retinal thickness in normal subjects. *Ophthalmology.* 1990;97:1120-1124.
- Alamouti B, Funk J. Retinal thickness decreases with age: an OCT study. *Br J Ophthalmol.* 2003;87:899-901.
- Eriksson U, Alm A. Macular thickness decreases with age in normal eyes: a study on the macular thickness map protocol in the Stratus OCT. *Br J Ophthalmol.* 2009;93:1448-1452.
- Nolan JM, Stringham JM, Beatty S, Snodderly DM. Spatial profile of macular pigment and its relationship to foveal architecture. *Invest Ophthalmol Vis Sci.* 2008;49:2134-2142.
- Wagner-Schuman M, Dubis AM, Nordgren RN, et al. Race- and sex-related differences in retinal thickness and foveal pit morphology. *Invest Ophthalmol Vis Sci.* 2011;52:625-634.
- Wong AC, Chan CW, Hui SP. Relationship of sex, body mass index, and axial length with central retinal thickness using optical coherence tomography. *Eye (Lond).* 2005;19:292-297.
- Lim MC, Hoh ST, Foster PJ, et al. Use of optical coherence tomography to assess variations in macular retinal thickness in myopia. *Invest Ophthalmol Vis Sci.* 2005;46:974-978.

23. Kim MJ, Lee EJ, Kim TW. Peripapillary retinal nerve fiber layer thickness profile in subjects with myopia measured using the Stratus optical coherence tomography. *Br J Ophthalmol*. 2010;94:115-120.
24. Kang SH, Hong SW, Im SK, Lee SH, Ahn MD. Effect of myopia on the thickness of the retinal nerve fiber layer measured by Cirrus HD optical coherence tomography. *Invest Ophthalmol Vis Sci*. 2010;51:4075-4083.
25. Hirata M, Tsujikawa A, Matsumoto A, et al. Macular choroidal thickness and volume in normal subjects measured by swept-source optical coherence tomography. *Invest Ophthalmol Vis Sci*. 2011;52:4971-4978.
26. Agawa T, Miura M, Ikuno Y, et al. Choroidal thickness measurement in healthy Japanese subjects by three-dimensional high-penetration optical coherence tomography. *Graefes Arch Clin Exp Ophthalmol*. 2011;249:1485-1492.
27. Esmaelpour M, Povazay B, Hermann B, et al. Three-dimensional 1060-nm OCT: choroidal thickness maps in normal subjects and improved posterior segment visualization in cataract patients. *Invest Ophthalmol Vis Sci*. 2010;51:5260-5266.
28. Sorsby A, Leary G, Richards M. The optical components in anisometropia. *Vision Res*. 1962;2:43-51.
29. Logan NS, Gilmartin B, Wildsoet CF, Dunne MC. Posterior retinal contour in adult human anisomyopia. *Invest Ophthalmol Vis Sci*. 2004;45:2152-2162.
30. Al-Haddad CE, Mollayess GM, Cherfan CG, Jaafar DF, Bashshur ZF. Retinal nerve fiber layer and macular thickness in amblyopia as measured by spectral-domain optical coherence tomography. *Br J Ophthalmol*. 2011;95:1696-1699.
31. Altintas O, Yuksel N, Ozkan B, Caglar Y. Thickness of the retinal nerve fiber layer, macular thickness, and macular volume in patients with strabismic amblyopia. *J Pediatr Ophthalmol Strabismus*. 2005;42:216-221.
32. Bozkurt B, Irkec M, Orhan M, Karaagaoglu E. Thickness of the retinal nerve fiber layer in patients with anisometropic and strabismic amblyopia. *Strabismus*. 2003;11:1-7.
33. Dickmann A, Petroni S, Salerni A, Dell'Omo R, Balestrazzi E. Unilateral amblyopia: an optical coherence tomography study. *J AAPOS*. 2009;13:148-150.
34. Duranoglu Y. Optic nerve head topographic analysis and retinal nerve fiber layer thickness in strabismic and anisometropic amblyopia. *Ann Ophthalmol (Skokie)*. 2007;39:291-295.
35. Huynh SC, Samarawickrama C, Wang XY, et al. Macular and nerve fiber layer thickness in amblyopia: the Sydney Childhood Eye Study. *Ophthalmology*. 2009;116:1604-1609.
36. Quoc EB, Delepine B, Tran TH. [Thickness of retinal nerve fiber layer and macular volume in children and adults with strabismic and anisometropic amblyopia]. *J Fr Ophthalmol*. 2009;32:488-495.
37. Repka MX, Goldenberg-Cohen N, Edwards AR. Retinal nerve fiber layer thickness in amblyopic eyes. *Am J Ophthalmol*. 2006;142:247-251.
38. Repka MX, Kraker RT, Tamkins SM, Suh DW, Sala NA, Beck RW. Retinal nerve fiber layer thickness in amblyopic eyes. *Am J Ophthalmol*. 2009;148:143-147.
39. Walker RA, Rubab S, Voll AR, Erraguntla V, Murphy PH. Macular and peripapillary retinal nerve fiber layer thickness in adults with amblyopia. *Can J Ophthalmol*. 2011;46:425-427.
40. Yen MY, Cheng CY, Wang AG. Retinal nerve fiber layer thickness in unilateral amblyopia. *Invest Ophthalmol Vis Sci*. 2004;45:2224-2230.
41. Yoon SW, Park WH, Baek SH, Kong SM. Thicknesses of macular retinal layer and peripapillary retinal nerve fiber layer in patients with hyperopic anisometropic amblyopia. *Korean J Ophthalmol*. 2005;19:62-67.
42. Buckhurst PJ, Wolffsohn JS, Shah S, Naroo SA, Davies LN, Berrow EJ. A new optical low coherence reflectometry device for ocular biometry in cataract patients. *Br J Ophthalmol*. 2009;93:949-953.
43. Atchison DA, Smith G. Possible errors in determining axial length changes during accommodation with the IOLMaster. *Optom Vis Sci*. 2004;81:283-286.
44. Read SA, Collins MJ, Woodman EC, Cheong SH. Axial length changes during accommodation in myopes and emmetropes. *Optom Vis Sci*. 2010;87:656-662.
45. Alonso-Caneiro D, Read SA, Collins MJ. Speckle reduction in optical coherence tomography imaging by affine-motion image registration. *J Biomed Opt*. 2011;16:116027.
46. Tick S, Rossant F, Ghorbel I, et al. Foveal shape and structure in a normal population. *Invest Ophthalmol Vis Sci*. 2011;52:5105-5110.
47. Odell D, Dubis AM, Lever JF, Stepien KE, Carroll J. Assessing errors inherent in OCT-derived macular thickness maps. *J Ophthalmol*. 2011;2011:692574.
48. Rahman W, Chen FK, Yeoh J, Patel P, Tufail A, Da Cruz L. Repeatability of manual subfoveal choroidal thickness measurements in healthy subjects using the technique of enhanced depth imaging optical coherence tomography. *Invest Ophthalmol Vis Sci*. 2011;52:2267-2271.
49. Cass K, Tromans C. A biometric investigation of ocular components in amblyopia. *Ophthalmic Physiol Opt*. 2008;28:429-440.
50. Vincent SJ, Collins MJ, Read SA, Carney LG. Monocular amblyopia and higher order aberrations. *Vision Res*. 2012;66:39-48.
51. Vincent SJ, Collins MJ, Read SA, Carney LG, Yap MK. Interocular symmetry in myopic anisometropia. *Optom Vis Sci*. 2011;88:1454-1462.
52. Weiss AH. Unilateral high myopia: optical components, associated factors, and visual outcomes. *Br J Ophthalmol*. 2003;87:1025-1031.
53. Huynh SC, Wang XY, Burlutsky G, Mitchell P. Symmetry of optical coherence tomography retinal measurements in young children. *Am J Ophthalmol*. 2007;143:518-520.
54. El-Ashry M, Hegde V, James P, Pagliarini S. Analysis of macular thickness in British population using optical coherence tomography (OCT): an emphasis on interocular symmetry. *Curr Eye Res*. 2008;33:693-699.
55. Pang Y, Goodfellow GW, Allison C, Block S, Frantz KA. A prospective study of macular thickness in amblyopic children with unilateral high myopia. *Invest Ophthalmol Vis Sci*. 2011;52:2444-2449.
56. Chen FK, Yeoh J, Rahman W, Patel PJ, Tufail A, Da Cruz L. Topographic variation and interocular symmetry of macular choroidal thickness using enhanced depth imaging optical coherence tomography. *Invest Ophthalmol Vis Sci*. 2012;53:975-985.
57. Spaide RF, Koizumi H, Pozzoni MC. Enhanced depth imaging spectral-domain optical coherence tomography. *Am J Ophthalmol*. 2008;146:496-500.
58. Shih YF, Horng IH, Yang CH, Lin LL, Peng Y, Hung PT. Ocular pulse amplitude in myopia. *J Ocul Pharmacol*. 1991;7:83-87.
59. Lam AK, Chan ST, Chan B, Chan H. The effect of axial length on ocular blood flow assessment in anisometropes. *Ophthalmic Physiol Optics*. 2003;23:315-320.
60. James CB, Trew DR, Clark K, Smith SE. Factors influencing the ocular pulse-axial length. *Graefes Arch Clin Exp Ophthalmol*. 1991;229:341-344.
61. Kaufmann C, Bachmann LM, Robert YC, Thiel MA. Ocular pulse amplitude in healthy subjects as measured by dynamic contour tonometry. *Arch Ophthalmol*. 2006;124:1104-1108.

62. Nickla DL, Wallman J. The multifunctional choroid. *Prog Retin Eye Res.* 2010;29:144-168.
63. Troilo D, Nickla DL, Wildsoet CF. Choroidal thickness changes during altered eye growth and refractive state in a primate. *Invest Ophthalmol Vis Sci.* 2000;41:1249-1258.
64. Tian Y, Tarrant J, Wildsoet CF. Optical and biometric characteristics of anisomyopia in human adults. *Ophthalmic Physiol Opt.* 2011;31:540-549.
65. Kwan WC, Yip SP, Yap MK. Monochromatic aberrations of the human eye and myopia. *Clin Exp Optom.* 2009;92:304-312.
66. Van Alphen GWHM. Choroidal stress and emmetropization. *Vision Res.* 1986;26:723-734.
67. Bailey MD, Sinnott LT, Mutti DO. Ciliary body thickness and refractive error in children. *Invest Ophthalmol Vis Sci.* 2008;49:4353-4360.
68. Oliveira C, Tello C, Liebmann JM, Ritch R. Ciliary body thickness increases with increasing axial myopia. *Am J Ophthalmol.* 2005;140:324-325.
69. Muftuoglu O, Hosal BM, Zilelioglu G. Ciliary body thickness in unilateral high axial myopia. *Eye (Lond).* 2009;23:1176-1181.
70. Chui TY, Zhong Z, Burns SA. The relationship between peripapillary crescent and axial length: implications for differential eye growth. *Vision Res.* 2011;51:2132-2138.
71. Kim TW, Kim M, Weinreb RN, Woo SJ, Park KH, Hwang JM. Optic disc change with incipient myopia of childhood. *Ophthalmology.* 2012;119:21-26.
72. Singh KD, Logan NS, Gilmartin B. Three-dimensional modeling of the human eye based on magnetic resonance imaging. *Invest Ophthalmol Vis Sci.* 2006;47:2272-2279.