

# Changes in Choroidal Thickness in Relation to the Severity of Retinopathy and Macular Edema in Type 2 Diabetic Patients

Jee Taek Kim, Dong Hoon Lee, Soo Geun Joe, June-Gone Kim, and Young Hee Yoon

Department of Ophthalmology, Asan Medical Center, University of Ulsan, Seoul, Republic of Korea

Correspondence: Young Hee Yoon, Department of Ophthalmology, Asan Medical Center, University of Ulsan College of Medicine, #388-1, Pungnap-Dong, Songpa-Gu, Seoul 138-736, Korea; yhyoon@amc.seoul.kr.

Submitted: December 15, 2012

Accepted: April 1, 2013

Citation: Kim JT, Lee DH, Joe SG, Kim J-G, Yoon YH. Changes in choroidal thickness in relation to the severity of retinopathy and macular edema in type 2 diabetic patients. *Invest Ophthalmol Vis Sci.* 2013;54:3378–3384. DOI:10.1167/iovs.12-11503

**PURPOSE.** To assess changes in choroidal thickness in type 2 diabetic patients with diabetic retinopathy (DR) and diabetic macular edema (DME) using enhanced-depth imaging spectral domain optical coherence tomography (EDI-OCT).

**METHODS.** Among 235 eyes from 145 patients, 195 treatment-naïve eyes were divided into no DR, mild/moderate nonproliferative DR (NPDR), severe NPDR, proliferative DR (PDR), and 40 eyes having a history of laser panretinal photocoagulation (PRP) were classified as PRP-treated DR. Eyes with no ocular treatment (195 eyes) were divided according to the presence of and to the subtypes of DME. Subfoveal choroidal thickness (SFChT) and parafoveal choroidal thickness (PFChT) at 1500  $\mu\text{m}$  were measured using EDI-OCT.

**RESULTS.** Mean age was  $62.6 \pm 12.4$  years, and mean duration of DM was  $15.1 \pm 7.2$  years. Mean SFChT in groups with no DR (40 eyes), mild/moderate NPDR (47 eyes), severe NPDR (72 eyes), PDR (36 eyes), and PRP-treated DR (40 eyes) was  $262.3 \pm 68.4 \mu\text{m}$ ,  $244.6 \pm 77.0 \mu\text{m}$ ,  $291.1 \pm 107.7 \mu\text{m}$ ,  $363.5 \pm 74.9 \mu\text{m}$ , and  $239.9 \pm 57.4 \mu\text{m}$ , respectively. Mean SFChT was significantly greater in eyes with PDR than in those with no DR ( $P < 0.01$ ), mild/moderate NPDR ( $P < 0.01$ ), or severe NPDR ( $P < 0.05$ ). Mean SFChT decreased significantly in PRP-treated DR compared with PDR ( $P < 0.01$ ). Eyes with DME (67 eyes) had a thicker subfoveal choroid than eyes without DME (128 eyes;  $P < 0.05$ ) and, compared with cystoid or diffuse types, SFChT was thickest in subretinal detachment (SRD)-type DME ( $P < 0.05$ ).

**CONCLUSIONS.** Choroidal thickness increased significantly as the severity worsened from mild/moderate/NPDR to PDR, and decreased in PRP-treated eyes. The subfoveal choroid was thicker in eyes with DME than in those without, and was thickest in eyes with SRD-type DME.

**Keywords:** choroidal thickness, diabetic retinopathy, diabetic macular edema

Diabetic retinopathy (DR) and diabetic macular edema (DME) are common sight-threatening retinopathies caused by abnormalities in retinal vessels and capillaries of diabetes patients. The choroid is an important vascular tissue that supplies blood to the outer retina, including the RPE and photoreceptors,<sup>1</sup> and it plays a vital role in the pathophysiology of many retinal diseases, including DR. Several studies of eyes with DR have shown definitive changes in the choroid. A histopathologic study showed vascular abnormalities in the choroidal layer in patients with diabetes.<sup>2</sup> In addition, studies using indocyanine green angiography in patients with diabetes show that hyperfluorescent spots are a sign of intrachoroidal vascular abnormalities or dilation of the choroidal vessels.<sup>3,4</sup> Changes in choroidal blood flow in diabetes have also been reported; pulsatile ocular blood flow is increased in nonproliferative retinopathy (NPDR) and decreased in treated proliferative retinopathy (PDR).<sup>5</sup>

Enhanced depth imaging with spectral domain optical coherence tomography (EDI-OCT), which is unique in having foveal tracking capability, was recently described as a novel way to measure the thickness of the choroid in normal and pathologic states.<sup>6–11</sup> Although a few recent studies reported changes in choroidal thickness (ChT) in patients with the early stages of DR or DME,<sup>12,13</sup> the relationship between the changes

in ChT and the severity of DR or the DME subtype has not been systematically investigated using EDI-OCT. The present study was designed to investigate how ChT changes according to DR severity, and whether the ChT varies according to DME subtype.

## PATIENTS AND METHODS

### Patient Eligibility

A retrospective review was performed on all diabetic patients who were examined at the Diabetes Center of Asan Medical Center, Seoul, Korea, between March and December 2011. This review was approved by the institutional review board of Asan Medical Center and was conducted in adherence with the tenets of the Declaration of Helsinki.

All patients had a complete ophthalmic examination, including manifest refraction, best-corrected visual acuity measurement, slit-lamp biomicroscopy, and a detailed fundus examination. Among them, only patients who had undergone color fundus photography/fluorescein angiography (FA) and spectral domain optical coherence tomography (SD-OCT) (Spectralis; Heidelberg Engineering, Heidelberg, Germany), both within a span of 2 weeks, were selected for this study.

TABLE 1. Baseline Characteristics

	Healthy Control	No DR	Mild or Moderate NPDR	Severe NPDR	PDR	PRP-Treated DR
No. patients	32	32	24	45	20	26
No. eyes	36	40	47	72	36	40
Age, y	59.8 ± 8.8	62.0 ± 12.4	66.7 ± 8.6	56.3 ± 12.8	57.0 ± 10.9	61.8 ± 11.4
DM duration, y		8.6 ± 5.2	14.6 ± 6.4	15.3 ± 6.9	15.3 ± 6.4	16.7 ± 7.8
HTN, no. of patients		2	7	3	3	3
SBP		130.3 ± 12.9	130.1 ± 14.0	127.8 ± 18.7	130.3 ± 14.9	127.6 ± 22.1
DBP		71.6 ± 10.5	70.3 ± 9.4	73.2 ± 11.7	76.1 ± 8.2	72.7 ± 13.2
BMI		24.5 ± 3.1	24.6 ± 3.7	23.4 ± 2.6	24.7 ± 4.0	23.4 ± 4.1
BCVA, logMAR	0.04 ± 0.06	0.03 ± 0.05	0.1 ± 0.13	0.14 ± 0.28	0.33 ± 0.27	0.37 ± 0.44
HbA1c, %*		6.5 ± 1.2*	7.4 ± 0.9*	8.6 ± 1.7*	10.3 ± 2.5*	8.1 ± 1.4*
CST, μm	262 ± 21.8	281 ± 27.9	273.7 ± 43.6	303.8 ± 77.8	362.2 ± 90.0	352.5 ± 137.1

BCVA, best-corrected visual acuity; HTN, hypertension; logMAR, logarithm of the minimum angle of resolution.

\*  $P < 0.05$ .

Exclusion criteria included the presence of refractive errors of more than  $\pm 3.0$  diopters and other retinal diseases (except DR), including drusen, AMD, or retinal vein occlusion. Eyes with a history of glaucoma, ocular trauma, ocular inflammation, or a history of any type of intraocular surgery (except cataract surgery) were also excluded. In addition, eyes were excluded when the fellow eyes had conditions that were reported to have abnormal choroidal thickness, such as central serous chorioretinopathy, AMD, or polypoidal choroidal vasculopathy.<sup>9-11</sup> To avoid the effects of pharmacologic agents on the retinal or choroidal vasculature, eyes with a history of any previous treatment, including intravitreal or subtenon injections of triamcinolone or anti-VEGF, were excluded. In addition, eyes that had previously received focal or grid laser photocoagulation at anytime were excluded. To evaluate the effect of panretinal photocoagulation (PRP) on the choroidal thickness, eyes with a history of PRP were separately collected, but those treated within 1 year were excluded to avoid the possible error by laser-induced choroidal swelling.

### DR Grading and Classification of DME

Only eyes with no history of intraocular injections or PRP were included for DR grading. The DR grade was classified as no DR, mild/moderate, or severe NPDR, or PDR, according to the modified Early Treatment Diabetic Retinopathy Study (ETDRS) retinopathy severity scale.<sup>14</sup> Eyes that were treated with PRP for at least 1 year before the study were classified as the PRP-treated DR group.

DME was diagnosed by stereoscopic biomicroscopy according to the criteria reported by ETDRS,<sup>15</sup> and confirmed on SD-OCT. DME was classified into three subtypes<sup>16</sup>: type 1, thickening of the fovea with intraretinal cystoid change (cystoid type); type 2, spongelike diffuse retinal thickening (diffuse type); and type 3, thickening of the fovea with serous retinal detachment (SRD-type). DME with apparent epiretinal membrane or vitreomacular traction was excluded.

### Choroidal Thickness Measurement Using EDI-OCT

All patients had undergone SD-OCT examination including EDI. Measurement of ChT was performed by an investigator masked to the DR grading and DME subtypes. To measure subfoveal choroidal thickness (SFChT), the vertical distance was measured manually at the fovea using the caliper tool in the OCT Heidelberg Eye Explorer software (Heidelberg Engineering), from the hyperreflective line of Bruch's membrane to the hyperreflective line of the chorio-scleral interface. Parafoveal choroidal thickness (PFChT) was measured at the nasal, superior, temporal, and inferior choroid quadrants (at a

manually measured distance of 1500 μm from the foveal center) using the same method. Normal control data were obtained from normal eyes of age-matched patients who underwent vitreoretinal surgery for idiopathic epiretinal membrane or macular hole.

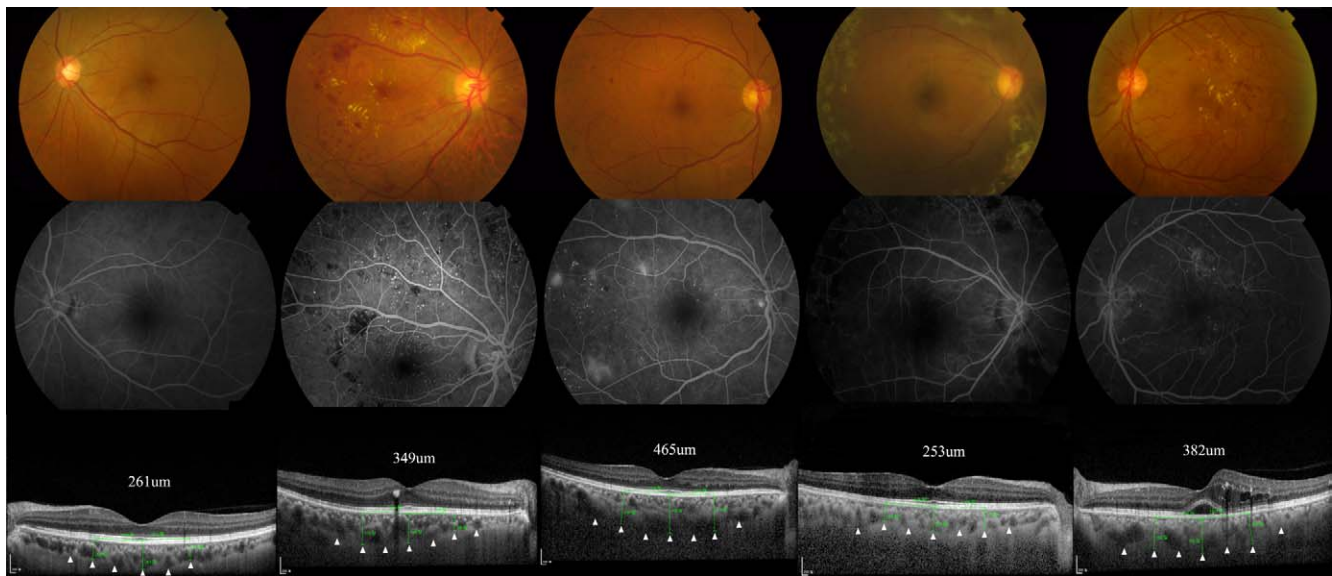
### Statistical Analysis

All data are expressed as the mean  $\pm$  SEM. Statistical analysis was performed using SPSS for Windows version 16.0 (SPSS Inc., Chicago, IL). The variation of SFChT according to DR grading and DME type was assessed using two-way ANOVA. Pair-wise comparisons between individual groups were made using Tukey's test. The difference in ChT between untreated PDR and PRP-treated DR was compared using the Mann-Whitney  $U$  test. An independent  $t$ -test was used to compare the difference of SFChT of eyes with DME and those without DME. The Pearson correlation coefficient was used to evaluate the correlation between SFChT and central subfield thickness (CST), in treatment-naïve DME patients. A  $P$  value of less than 0.05 was considered statistically significant.

## RESULTS

### Baseline Characteristics

During the period of March to December 2011, a total of 5229 diabetic patients were examined at the Diabetic Retinopathy Clinic. Among them, 595 patients who had undergone FA and SD-OCT, both within a span of 2 weeks, were identified. FA and OCT of patients with no DR or mild DR were obtained only in special cases; for example, when other concomitant diseases, such as retinal vein occlusion or epiretinal membrane, needed to be evaluated in a nonstudy eye. After sorting out all eyes that fit the exclusion criteria, 235 eyes from 145 type 2 diabetes patients, 70 men and 75 women, with a mean age of  $52.6 \pm 12.4$  years were included for this study. The mean duration of diabetes mellitus (DM) was  $15.1 \pm 7.2$  years. The eyes were grouped according to DR status: no DR, mild/moderate NPDR, severe NPDR, PDR, and PRP-treated DR. The number of eyes and patients, and the characteristics of the patients (age, DM duration, number with hypertension, systolic blood pressure [SBP], diastolic blood pressure [DBP], body mass index [BMI], best corrected visual acuity, central subfield thickness, and hemoglobin A1c [HbA1c] level) in each group are summarized in Table 1. The study groups did not differ in terms of age or DM duration. The difference in HbA1c levels was statistically significant between each DR group (ANOVA,  $P < 0.05$ ).



**FIGURE 1.** Fundus photograph (first row), FA (second row), and EDI-OCT (bottom row). First column: no DR. Second column: severe NPDR. Third column: untreated PDR. Fourth column: PRP-treated DR. Fifth column: severe NPDR with DME of SRD-type. SFChT is indicated in the figure of EDI-OCT. Arrowheads indicate hyperreflective line of the chorio-scleral interface on EDI-OCT. Green markings indicate ChT measured with the caliper program of the Heidelberg Eye Explorer software of EDI-OCT.

Fundus photograph, FA, and EDI-OCT images of representative cases are shown in Figure 1. Findings are shown from a case with no DR (first column), a case with severe NPDR (second column), PDR (third column), PRP-treated DR (fourth column), and severe NPDR with SRD-type DME (fifth column).

### Choroidal Thickness According to Systemic Factors

Because the number of patients with hypertension or kidney dysfunction was too small, statistical analysis could not be conducted. Whereas neither SBP, DBP, nor BMI showed any association with SFChT (SBP:  $r = 0.007$ ,  $P = 0.959$ ; DBP:  $r = 0.187$ ,  $P = 0.155$ ; BMI  $r = 0.204$ ,  $P = 0.12$ ), HbA1c was significantly correlated with SFChT ( $r = 0.252$ ,  $P < 0.05$ ).

### Choroidal Thickness According to DR Grading

Compared with healthy controls, SFChT was slightly decreased in DM eyes with no DR or with earlier stage DR. SFChT increased, however, as retinopathy progressed to severe NPDR or PDR (Table 2). The subfoveal choroid in PDR eyes was significantly thicker than that in eyes with no DR ( $P < 0.01$ ), eyes with mild/moderate NPDR ( $P < 0.01$ ), and eyes with severe NPDR ( $P < 0.05$ ; Fig. 2). PRP-treated DR eyes showed significant thinning in comparison with PDR eyes ( $P < 0.01$ ).

Measurements of PFChT at each of the four quadrants are presented in Table 2 and Figure 3. These measurements revealed a consistent pattern among all groups with a different DR grade; the choroid was thinnest nasally, thickest in the subfoveal region, and thinner again temporally, whereas the choroid showed a similar thickness at the superior and inferior quadrants. This pattern was consistent with previous studies of ChT in normal eyes.<sup>6,7</sup>

### Mean SFChT According to DME Severity and Subtype

Of the 235 eyes considered for the study, 40 with a history of laser PRP were excluded. Eyes with DME were divided into three groups according to morphologic type (Table 3).

Eyes with DME ( $n = 67$ ) had a mean SFChT of  $311.6 \pm 99.7$   $\mu\text{m}$ , and in those without DME ( $n = 128$ ), the mean SFChT was  $274.4 \pm 79.8$   $\mu\text{m}$ . The difference in SFChT between the two groups was statistically significant (independent  $t$ -test: two side,  $P < 0.05$ ; Fig. 4A). Plotting changes in CST against changes in SFChT in patients with naïve (i.e., untreated) DME revealed a positive correlation (Pearson correlation coefficient =  $0.184$ ,  $P = 0.034$ ; Fig. 4B).

The DME morphologic groups (cystoid, diffuse, and SRD types) had a mean SFChT of  $292.4 \pm 63.5$   $\mu\text{m}$ ,  $329.2 \pm 91.9$   $\mu\text{m}$ , and  $351.5 \pm 85.6$   $\mu\text{m}$ , respectively (Fig. 5). The SFChT of eyes with the SRD-type was greatest among these groups. The

**TABLE 2.** Mean SFChT and PFChT at Each of the Five Locations in Diabetic Patients

	SFChT, $\mu\text{m}$	Nasal PFChT, $\mu\text{m}$	Temporal PFChT, $\mu\text{m}$	Inferior PFChT, $\mu\text{m}$	Superior PFChT, $\mu\text{m}$
Healthy control	$276.0 \pm 58.1$	$222.64 \pm 67.8$	$240.62 \pm 63.5$	$248.8 \pm 70.8$	$255.1 \pm 45.6$
No DR	$262.3 \pm 68.4$	$215.4 \pm 72.1$	$240.6 \pm 72.0$	$235.1 \pm 65.6$	$232.8 \pm 66.2$
Mild-Mod NPDR	$244.6 \pm 77.0$	$192.0 \pm 74.8$	$224.7 \pm 67.4$	$219.7 \pm 62.8$	$221.0 \pm 71.9$
Severe NPDR	$291.1 \pm 107.7$	$247.4 \pm 97.6$	$269.4 \pm 89.4$	$262.9 \pm 89.5$	$277.6 \pm 99.0$
PDR	$363.6 \pm 74.9$	$295.4 \pm 86.0$	$339.5 \pm 74.0$	$324.7 \pm 84.8$	$316.0 \pm 64.0$
PDR-treated DR	$239.8 \pm 57.4$	$186.7 \pm 65.5$	$233.1 \pm 70.6$	$212.4 \pm 75.6$	$242.3 \pm 78.0$

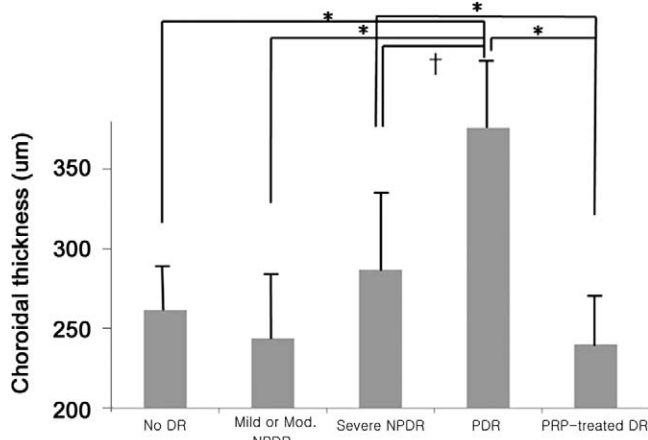


FIGURE 2. Graph showing the mean SFChT of diabetic patients according to DR grading. The mean SFChT was significantly greater in the untreated PDR group than in the no DR and mild/moderate (Mod) NPDR groups (ANOVA;  $P < 0.01$ ), and severe NPDR group (ANOVA;  $P < 0.05$ ). The mean SFChT was significantly less in the PRP-treated DR group compared with the untreated PDR group (ANOVA;  $P < 0.01$ ). \* $P < 0.01$ , † $P < 0.05$ .

mean SFChT of eyes with SRD-type DME was significantly greater than that of eyes with no DME ( $P < 0.01$ ) or eyes with cystoid-type DME ( $P < 0.05$ ; ANOVA).

### DISCUSSION

The findings of the present study revealed that SFChT increased with increasing severity of DR (from no DR to proliferative DR), and with the presence of DME, especially in eyes with serous retinal detachment (SRD-type). Diabetes is a metabolic disease affecting the systemic vasculature. Although the principal changes in diabetic eyes occur in the retinal vasculature, additional changes are also observed in the choroidal layer, an important vascular tissue that supplies blood to the outer retina.<sup>1</sup> Histologic studies of diabetic eyes show increased tortuosity, focal vascular dilation or narrowing,

and the formation of sinuslike structures between the choroidal lobules, and also, in some advanced cases, luminal narrowing of the capillaries, capillary dropout, and focal scarring.<sup>2</sup> In addition, studies using indocyanine green angiography show filling delay or defects in the choriocapillaris, saccular dilatations, microaneurysms in the choriocapillaris, and choroidal neovascularization.<sup>3,4</sup>

Until recently, examination of the choroidal layer morphology in vivo has been hindered by the limitations of the first-generation OCT. Using the Cirrus high definition (HD)-OCT (Carl Zeiss Meditec, Inc., Dublin, CA), Regatieri et al.<sup>13</sup> reported in 2012 that ChT decreases in eyes with DME and in eyes treated with scatter PRP. These authors, however, did not examine the changes in eyes with various stages of NPDR or eyes with untreated PDR. Consistent with the results of their study, we also found choroidal thinning in PRP-treated eyes, but our finding that eyes with DME had a thicker choroid than those without was different. In addition, we observed progressive thickening of the choroid layer with increasing severity of DR from mild/moderate NPDR to severe NPDR, or from severe NPDR to PDR. Our findings revealed some degree of reduced choroidal thickness among eyes with no DR or early NPDR. Although previous studies reported similar findings,<sup>12,13</sup> the mechanism of choroidal thinning in eyes with early DR has remained unknown. We speculate that thinning of the choroidal layer resulted from vascular constriction or choriocapillaris loss secondary to hypoxia in association with early diabetic choroidopathy.<sup>13,17,18</sup>

The mechanism of choroidal thickening in eyes with advanced stages of retinopathy is unknown. Using a computerized pneumotonometer, Savage et al.<sup>5</sup> investigated pulsatile ocular blood flow as a reflection of choroidal circulation in eyes with DR. Compared with nondiabetic controls, choroidal blood flow increased in severe NPDR and PDR, and decreased in treated DR.<sup>5</sup> The similarity between the results of a hemodynamic study and our morphologic OCT study in eyes with various stages of DR is interesting. These findings might reflect an increased production of VEGF or other cytokines mediating choroidal vasodilation and elevation in choroidal blood flow, which subsequently increase the thickness of the choroidal vascular layer, especially in patients with severe NPDR or PDR. It is noteworthy that there was a further

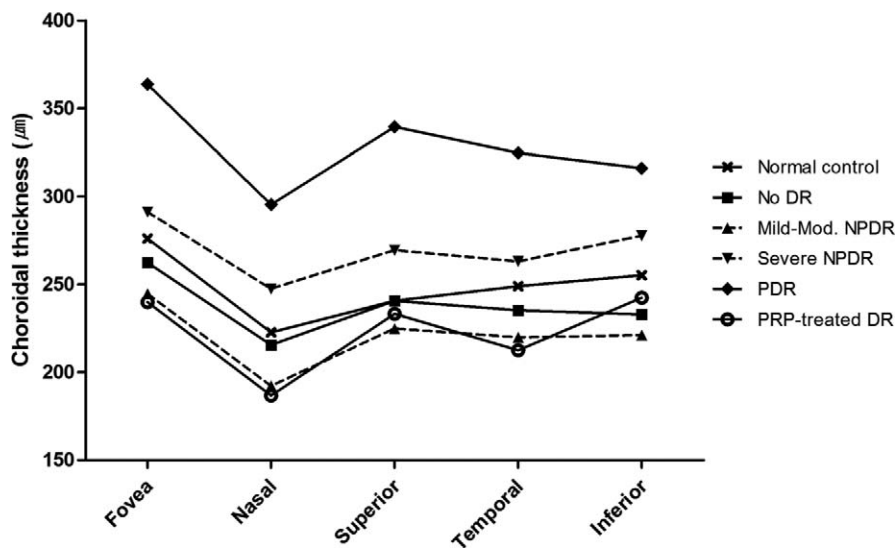


FIGURE 3. Graph showing mean SFChT and PFChT in diabetic patients. The SFChT and PFChT were measured at the fovea, and in the nasal, superior, temporal, and inferior quadrants at a distance of 1500 µm from the foveal center. Similar trends in SFChT throughout the four parafoveal quadrants were observed for each DR grading (No DR, Mild-Mod NPDR, Severe NPDR, PDR, and PRP-treated DR).

TABLE 3. Mean SFChT of Eyes Without or With DME

	No DME	Cystoid-Type DME	Diffuse-Type DME	SRD-Type DME
SFChT, $\mu\text{m}$	274.4 $\pm$ 79.8	292.4 $\pm$ 63.5	329.2 $\pm$ 91.9	351.5 $\pm$ 85.6
CST, $\mu\text{m}$	274.1 $\pm$ 30.2	300.8 $\pm$ 40.7	296.7 $\pm$ 31.8	484.2 $\pm$ 143.5
BCVA, logMAR	0.07 $\pm$ 0.09	0.16 $\pm$ 0.23	0.26 $\pm$ 0.31	0.42 $\pm$ 0.45
DR grading, no. of eyes (%)				
No DR	40 (31.2)			
Mild-Mod NPDR	42 (32.8)	3 (8.3)	1 (7.1)	1 (5.5)
Severe NPDR	34 (26.6)	25 (69.4)	8 (61.5)	5 (27.8)
PDR	12 (9.3)	8 (22.2)	4 (30.7)	12 (66.7)
Total	128 (100)	36 (100)	13 (100)	18 (100)

significant change from severe NPDR to PDR. Clinically, the stage of PDR is associated with greater risk of systemic vascular complications, such as ischemic heart disease.<sup>19</sup> This close association suggests that increased ChT could be interpreted as a marker of compromised systemic vasculature.

Previous studies demonstrated that choroidal blood flow markedly decreases after laser PRP, possibly due to the downregulation of VEGF.<sup>20,21</sup> It is thought that the choroidal layer becomes significantly thinner after PRP due to decreased

blood flow and subsequent ischemic atrophic change. Our results clearly showed that the choroidal layer of PRP-treated DR eyes was significantly thinner than that of eyes with untreated PDR or severe NPDR, and almost equivalent to ChT in eyes with mild/moderate NPDR. Our observation of significant choroidal thinning in the PRP-treated eyes compared with treatment-naïve PDR eyes might explain the discrepancy in choroidal thickness in PDR eyes between in this study and in some previous studies.<sup>13,17,18</sup> In such studies,

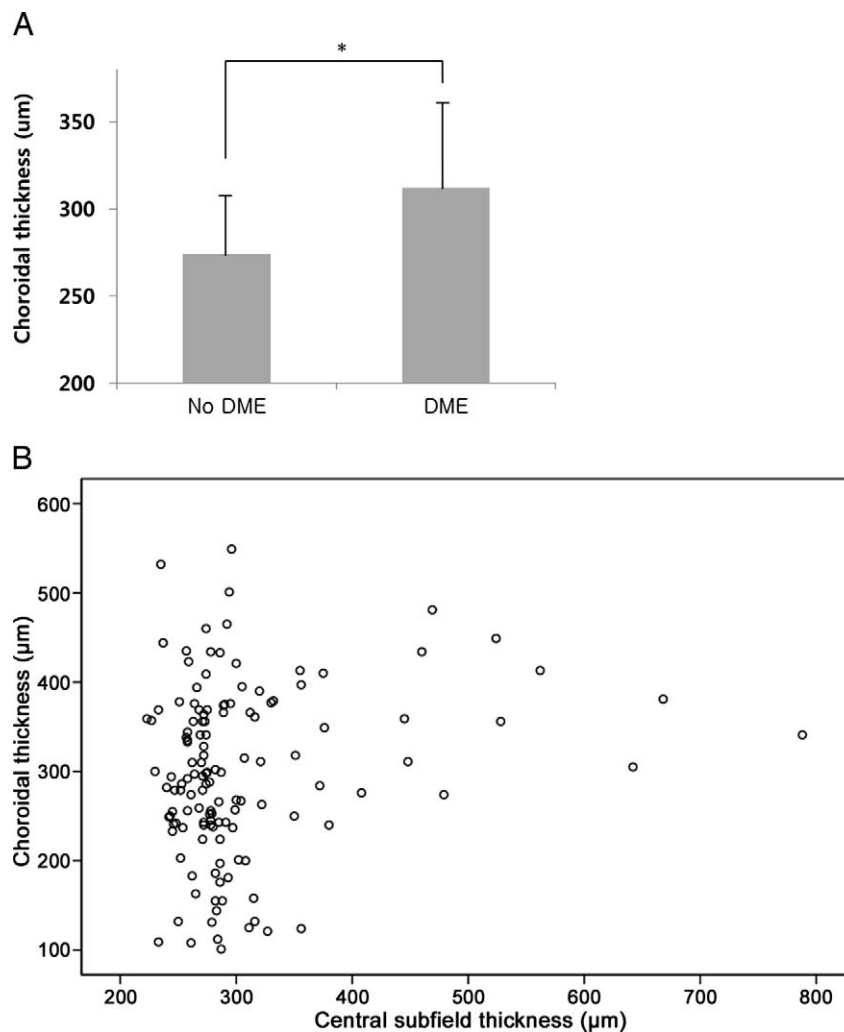


FIGURE 4. (A) Comparison of the mean SFChT in treatment-naïve eyes, with and without DME. Eyes with DME had increased SFChT compared with eyes without DME (independent *t*-test: two side, \**P* < 0.05). (B) Scattergram showing changes in central subfield thickness of the retina (*x*-axis) against changes in SFChT (*y*-axis). The Pearson correlation coefficient was 0.184 between CST and SFChT (*P* = 0.034).

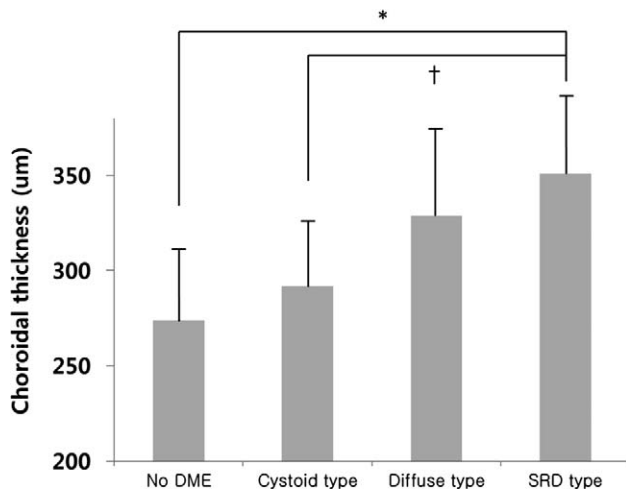


FIGURE 5. Graph showing the mean SFChT in treatment-naïve eyes with DME according to subtype. Eyes with DME showed increased SFChT compared with eyes in the no-DME group. The SFChT in the SRD-type was greater than that in the cystoid type and no-DME groups (ANOVA;  $P < 0.05$  and  $P < 0.01$ , respectively). \* $P < 0.01$ , † $P < 0.05$ .

investigators have reported that PDR eyes had the decreased choroidal thickness, but they included all PDR eyes regardless of a history of PRP treatment.

Interestingly, the PRP-treated group had a noticeably lower HbA1c. Therefore, the reduced SFChT among PRP-treated eyes could be due, in part, to an intensive systemic control in this group. It is conceivable that diabetic patients who had experienced any therapeutic measures, such as PRP, became more aware of the seriousness of the disease and were more likely to maintain strict blood sugar control. Nevertheless, we believe that the reduction of VEGF following PRP played a significant role in reducing the choroidal thickness. A longitudinal study should be performed to confirm the direct effect of PRP on choroidal thickness.

Whereas previous investigators reported a decrease in ChT in eyes with DME,<sup>12,13</sup> the results of the present study indicated that the choroidal layer was significantly thicker in eyes with DME than in eyes without. This discrepancy might be due to differences in patient profiles. Although our study included a relatively large number of patients with advanced retinopathy (excluding patients with a history of PRP), previous reports included eyes only with early NPDR or PRP-treated advanced DR eyes. In each of these conditions, mean ChT was significantly thinner regardless of the presence of DME (Fig. 2). The positive correlation between CST and ChT shown by a scattergram (Fig. 4B) also supports our hypothesis that eyes with more severe DME produce more VEGF or other cytokines, resulting in a thickening of the choroidal layer. The finding that the mean ChT differed according to the DME type is intriguing. Eyes with the SRD-type DME had a thicker choroid than eyes with the other DME types. This could be partly due to the higher incidence of SRD-type DME in the severe NPDR and PDR groups, and the thicker choroid in these groups than in the other groups. The increased ChT in this study, however, indicates that SRD-type eyes had increased choriocapillaris permeability, resulting in thickening of the choroid. SRD-type DME may appear very early in the evolution of DME<sup>22</sup> or may precede cystoid changes,<sup>23</sup> and the pathogenesis of serous retinal fluid in diabetes could result from hyperpermeability<sup>23</sup> or RPE dysfunction.<sup>24,25</sup> Diabetic choroidopathy may directly induce choroidal ischemia, leading to RPE dysfunction, or it may indirectly impair the ability of RPE to pump fluid due to factors affecting vascular permeabil-

ity. Thus, it is speculated that the SRD-type DME is the result of increased ChT, which implies diabetic ischemic choroidopathy.

Although the present study was limited by its cross-sectional retrospective design and relatively small number of samples in each category, it has advantages over similar previous studies,<sup>12,13</sup> namely (1) the use of EDI-OCT with eye-tracking software for more accurate measurement of SFChT; (2) patients with all stages of DR (from no DR to untreated PDR); (3) eyes with prior PRP were separately evaluated; and (4) analysis of DME patients who had no history of laser treatment or intraocular injection.

In conclusion, this study demonstrates that ChT is closely correlated with the stage of DR, and with the degree or type of DME. Progressive thickening of the choroidal layer with the progression of DR, or the development of DME, may reflect the concurrent progression of diabetic choroidopathy. Likewise, choroidal thinning was observed as the regression of advanced DR following PRP. EDI-OCT is a noninvasive technology that enables accurate assessment of choroidal vascular changes in diabetic patients.

### Acknowledgments

Presented as a poster at the 2012 Joint Meeting of the American Academy of Ophthalmology and the Asia-Pacific Academy of Ophthalmology, Chicago, Illinois, November 2012.

Disclosure: **J.T. Kim**, None; **D.H. Lee**, None; **S.G. Joe**, None; **J.-G. Kim**, None; **Y.H. Yoon**, Allergan (F, C, R), Bayer (C, R), Alcon (C)

### References

- Nickla DL, Wallman J. The multifunctional choroid. *Prog Retin Eye Res.* 2010;29:144-168.
- Hidayat AA, Fine BS. Diabetic choroidopathy. Light and electron microscopic observations of seven cases. *Ophthalmology.* 1985;92:512-522.
- Weinberger D, Kramer M, Priel E, et al. Indocyanine green angiographic findings in nonproliferative diabetic retinopathy. *Am J Ophthalmol.* 1998;126:238-247.
- Shiragami C, Shiraga F, Matsuo T, et al. Risk factors for diabetic choroidopathy in patients with diabetic retinopathy. *Graefes Arch Clin Exp Ophthalmol.* 2002;240:436-442.
- Savage HI, Hendrix JW, Peterson DC, et al. Differences in pulsatile ocular blood flow among three classifications of diabetic retinopathy. *Invest Ophthalmol Vis Sci.* 2004;45:4504-4509.
- Spaide RF, Koizumi H, Pozzoni MC. Enhanced depth imaging spectral-domain optical coherence tomography. *Am J Ophthalmol.* 2008;146:496-500.
- Margolis R, Spaide RF. A pilot study of enhanced depth imaging optical coherence tomography of the choroid in normal eyes. *Am J Ophthalmol.* 2009;147:811-815.
- Fujiwara T, Imamura Y, Margolis R, et al. Enhanced depth imaging optical coherence tomography of the choroid in highly myopic eyes. *Am J Ophthalmol.* 2009;148:445-450.
- Imamura Y, Fujiwara T, Margolis R, Spaide RF. Enhanced depth imaging optical coherence tomography of the choroid in central serous chorioretinopathy. *Retina.* 2009;29:1469-1473.
- Spaide RF. Age-related choroidal atrophy. *Am J Ophthalmol.* 2009;147:801-810.
- Spaide RF. Enhanced depth imaging optical coherence tomography of retinal pigment epithelial detachment in age-related macular degeneration. *Am J Ophthalmol.* 2009;147:644-652.
- Esmacelpour M, Považay B, Hermann B, et al. Mapping choroidal and retinal thickness variation in type 2 diabetes

- using three-dimensional 1060-nm optical coherence tomography. *Invest Ophthalmol Vis Sci.* 2011;52:5311-5316.
13. Regatieri CV, Branchini L, Carmody J, et al. Choroidal thickness in patients with diabetic retinopathy analyzed by spectral-domain optical coherence tomography. *Retina.* 2012;32:563-568.
  14. Grading diabetic retinopathy from stereoscopic color fundus photographs—an extension of the modified Airlie House classification. ETDRS report number 10. Early Treatment Diabetic Retinopathy Study Research Group. *Ophthalmology.* 1991;98:786-806.
  15. Photocoagulation for diabetic macular edema. Early Treatment Diabetic Retinopathy Study report number 1. Early Treatment Diabetic Retinopathy Study Research Group. *Arch Ophthalmol.* 1985;103:1796-1806.
  16. Otani T, Kishi S, Maruyama Y. Patterns of diabetic macular edema with optical coherence tomography. *Am J Ophthalmol.* 1999;127:688-693.
  17. Querques G, Lattanzio R, Querques L, et al. Enhanced depth imaging optical coherence tomography in type 2 diabetes. *Invest Ophthalmol Vis Sci.* 2012;53:6017-6024.
  18. Esmacelpour M, Brunner S, Ansari-Shahrezaei S, et al. Choroidal thinning in diabetes type 1 detected by 3-dimensional 1060 nm optical coherence tomography. *Invest Ophthalmol Vis Sci.* 2012;53:6803-6809.
  19. Tryniszewski W, Kuśmierczyk J, Maziarz Z, et al. Correlation of the severity of diabetic retinopathy and the heart muscle perfusion in patients with type 2 diabetes. *J Diabetes Complications.* 2011;25:253-257.
  20. Bressler NM, Beck RW, Ferris FL. Panretinal photocoagulation for proliferative diabetic retinopathy. *N Engl J Med.* 2011;365:1520-1526.
  21. Geyer O, Neudorfer M, Snir T, et al. Pulsatile ocular blood flow in diabetic retinopathy. *Acta Ophthalmol Scand.* 1999;77:522-525.
  22. Gaucher D, Sebah C, Erginay A, et al. Optical coherence tomography features during the evolution of serous retinal detachment in patients with diabetic macular edema. *Am J Ophthalmol.* 2008;145:289-296.
  23. Kang SW, Park CY, Ham DI. The correlation between fluorescein angiographic and optical coherence tomographic features in clinically significant diabetic macular edema. *Am J Ophthalmol.* 2004;137:313-322.
  24. Ravalico G, Battaglia Parodi M. Exudative retinal detachment subsequent to retinal vein occlusion. *Ophthalmologica.* 1992;205:77-82.
  25. Marmor MF, Wolfensberger TJ. Manifestations and pathophysiology of serous detachment of the retinal pigment epithelium and retina. In: Marmor M, Wolfensberger T, eds. *The Retinal Pigment Epithelium: Function and Disease.* New York: Oxford University Press; 1998:439-458.