

Influence of Incisional Vitreous Incarceration in Sclerotomy Closure Competency After Transconjunctival Sutureless Vitrectomy

Javier Benitez-Herreros,¹ Lorenzo Lopez-Guajardo,^{1,2} Cristina Camara-Gonzalez,¹ Aurora Perez-Crespo,¹ Agustin Silva-Mato,³ Alejandro Alvaro-Meca,⁴ and Miguel A. Teus^{1,2}

¹Department of Ophthalmology, University Hospital Principe de Asturias, Alcalá de Henares (Madrid), Spain

²Department of Ophthalmology, Faculty of Medicine, Alcalá University, Madrid, Spain

³Department of Health and Sociomedical Sciences, Biostatistics Unit, Faculty of Medicine, Alcalá University, Madrid, Spain

⁴Department of Preventive Medicine and Public Health, Faculty of Medicine, Rey Juan Carlos University, Alcorcón, Madrid, Spain

Correspondence: Lorenzo Lopez-Guajardo, Department of Ophthalmology, University Hospital Principe de Asturias, Carretera Alcalá-Meco s/n 28805 Alcalá de Henares, Madrid, Spain; lguajardo@icam.es.

Submitted: March 10, 2013

Accepted: April 28, 2013

Citation: Benitez-Herreros J, Lopez-Guajardo L, Camara-Gonzalez C, et al. Influence of incisional vitreous incarceration in sclerotomy closure competency after transconjunctival sutureless vitrectomy. *Invest Ophthalmol Vis Sci.* 2013;54:4366-4371. DOI:10.1167/iov.13-12008

PURPOSE. To evaluate the influence that vitreous incarceration may exert on the presence of postoperative conjunctival blebs over sclerotomies after transconjunctival sutureless vitrectomy (TSV). Blebs are formed by incisional leakage due to incompetent closure.

METHODS. Experimental study in which 23-gauge TSV was performed in 146 cadaveric pig eyes. Once the vitrectomy was finished, triamcinolone was injected inside the vitreous cavity for staining residual vitreous, one of the superior cannulas was extracted over the light probe, and the other cannula was removed with the plug inserted. Postoperative conjunctival blebs in superior sclerotomies were assessed by anterior-segment optical coherence tomography (AS-OCT) in a masked fashion; nondetectable blebs were classified as grade 0 (B0), thin bleb (\leq half scleral thickness) as grade 1 (B1), and thick bleb ($>$ half scleral thickness) as grade 2 (B2). Postoperative incisional vitreous entrapment was evaluated by slit-lamp photographs in a masked way; no incarceration was classified as grade 0 (V0), thin incarceration as grade 1 (V1), and thick incarceration as grade 2 (V2).

RESULTS. Conjunctival blebs were found in 13.7% of the sclerotomies (11.3% bleb-B1, 2.4% bleb-B2). Vitreous incarceration was found in 96.5% of the sclerotomies without bleb (B0), 81.8% of the incisions with bleb-B1, and 14.3% of the wounds with bleb-B2. Vitreous incarceration was significantly associated with the absence of conjunctival bleb ($P < 0.001$).

CONCLUSIONS. Vitreous incarceration in sclerotomies is related to less incisional leakage in our experimental model. Maneuvers that reduce vitreous entrapment, such as the interposition of a nonhollow probe during the cannula extraction, could decrease the sclerotomy closure competency.

Keywords: vitrectomy, vitreous incarceration, conjunctival bleb, sclerotomy closure, experimental model

During the last decade, 23- and 25-gauge transconjunctival sutureless vitrectomies (TSV) have gained popularity and acceptance.^{1,2} In contrast to conventional 20-gauge sclerotomies, 23- and 25-gauge incisions allow minimally invasive vitreoretinal surgery using smaller sutureless incisions, as compared with conventional pars plana vitrectomy^{3,4}; however, they have been related to higher rates of endophthalmitis and hypotony, due to the occasional lack of incisional closure.⁵⁻⁷

Recently, some authors have studied the conjunctival bleb formation over sutureless sclerotomies after vitrectomy, resulting from sclerotomy occlusion incompetency.⁸⁻¹⁵ These studies have identified parameters related to the sclerotomy architecture^{11,14} and the surgery⁹ as factors involved in the postoperative sclerotomy leakage. However, other factors may influence the sclerotomy closure competency, such as the presence of vitreous incarceration, which may work as an incisional plug.

We, thus, decided to evaluate the influence that the presence of vitreous incarceration may exert on incisional closure competency after vitrectomy. Due to the invasive nature of our procedure, we used an experimental animal model. Previously, in another animal sample, we analyzed the effect of the cannula extraction technique on vitreous incarceration, concluding that interposing the illumination pipe through the cannula during its removal reduces the amount of postoperative vitreous incarceration as compared with the cannula extraction with the plug inserted.¹⁶ Therefore, with the aim of obtaining different grades of vitreous incarceration in our study, we resolved to remove the scleral cannulas with the light probe or the cannula plug inserted. We used anterior segment-optical coherence tomography (AS-OCT) for the evaluation of conjunctival blebs over the sclerotomies, and direct visualization for the analysis of incisional vitreous incarceration, given that these techniques are highly sensitive imaging methods for those ends.¹⁷⁻¹⁹

MATERIALS AND METHODS

This experimental and observer-masked study included 146 pig eyes (*Sus scrofa domestica* species). Exclusion criteria were presence of refractive media opacities, scleral alterations, and intraoperative complications. All eyes were obtained 3 hours after pigs were killed and were kept in cold storage at 4°C before use, with the aim of preserving the properties of all ocular tissues.²⁰ Given that the globes were obtained from pigs killed for human consumption from a regulated slaughterhouse, no statements for the use of animals in ophthalmic research were applicable.

The 23-gauge sclerotomies (23-gauge TSV system; Alcon Laboratories, Fort Worth, TX) were performed using an oblique incisional technique 4 mm from the limbus.¹³ The first step in this technique was to laterally displace the conjunctiva with the aid of forceps; after that, the globe was penetrated tangentially with the trocar-cannula at an angle of approximately 30°, parallel to the corneal limbus, all the way of the beveled trocar up to the beginning of the cannula; finally, the penetrating direction was modified to a perpendicular orientation (pointing to the center of the globe) for the rest of the trocar up to the collar of the microcannula. Core vitrectomy was carried out by one of the authors (LLG) with the infusion pressure set at 40 mm Hg, using the Accurus vitrectomy system (Alcon Laboratories). Vitrectomy was also performed all around each perisclerotomy area by inserting the vitrectomy probe through both superior cannulas. After checking that balanced salt solution (BSS; Alcon Laboratories) flowed freely through both superior cannulas, the infusion line was clamped and 1 mL of triamcinolone acetonide 40 mg/mL (TrigonDepot; Bristol-Myers-Squibb, New York, NY) was slowly injected through the cannula used by the vitreous cutter, with the aim of staining intraocular residual vitreous. The infusion line was then opened and all the free triamcinolone that was not adhered to residual vitreous was exchanged for BSS. After that, infusion pressure was lowered to 10 mm Hg and superior cannulas were extracted following their oblique incisional pathways. In 73 randomly chosen eyes, the cannula used by the vitreous cutter during the vitrectomy was removed with the light pipe introduced through it, and the cannula used by the illumination probe was taken out with the cannula plug inserted (Fig. 1). In the other 73 eyes, the cannula used by the illumination probe during the vitrectomy was removed with the light pipe introduced, and the one used by the vitreous cutter was extracted with the cannula plug inserted. In this way, we avoided any possible effect that the different manipulations exerted on the sclerotomies by the vitreous cutter or the illumination probe could have on postoperative vitreous incarceration. Finally, the infusion line was clamped and the infusion cannula was taken out.

Sclerotomies were then evaluated by AS-OCT (Visante OCT 3.0; Carl Zeiss Meditec, Inc., Dublin, CA) using the high-resolution mode that performs 512 A-scans per line. The scan, placed parallel to the limbus, followed the entire incision pathway. Later, eyes were cut and divided in two portions through the posterior third coronal plane of the globe. To that end, we first performed a penetrating incision parallel to the limbus with a scalpel and then we completed the cut 360° around the globe with Wescott scissors (Antioch, TN). Finally, slit-lamp photographs of the internal side of the sclerotomies were taken.

The image sequences obtained were reviewed, and one snapshot from each sclerotomy was selected for presentation in a masked fashion to one of the authors (JB-H) who classified the sclerotomies according to the grade of conjunctival bleb over the wound. Bleb Grade 0 (*B0*) was defined as absence of subconjunctival leakage over the sclerotomy site; grade 1 (*B1*)

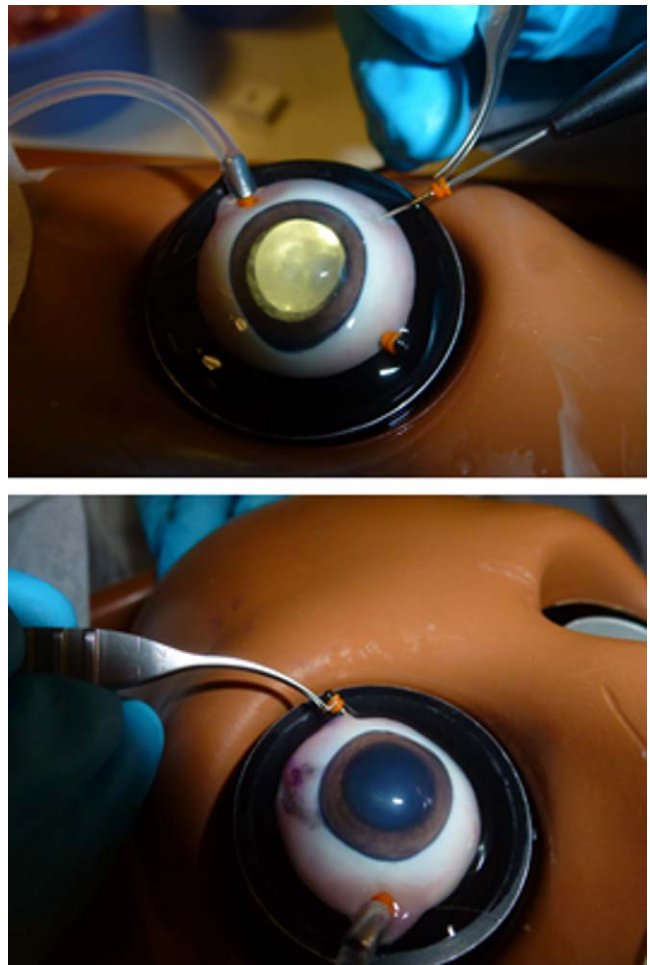


FIGURE 1. Scleral cannulas were extracted with the light pipe (upper) or the cannula plug (lower) inserted through them.

was defined as the presence of a small conjunctival bleb over the incision with thickness equal or less than half of the scleral thickness (checked by the AS-OCT caliper); and grade 2 (*B2*) was classified as the existence of a thick conjunctival bleb over the sclerotomy with thickness greater than half of the scleral thickness (Fig. 2). In turn, vitreous incarceration was classified by direct visualization according to the amount of vitreous entrapped. Grade 0 (*V0*) was defined as the absence of vitreous incarceration at the sclerotomy site, grade 1 (*V1*) was considered as the presence of delicate vitreous strands directed toward the inner hole of the incision, and grade 2 (*V2*) was classified as the existence of thick vitreous strands aimed toward the sclerotomy (Fig. 3). The injection of triamcinolone acetonide that stained the intraocular residual vitreous allowed us to visualize the incisional vitreous strands clearly.

For all statistical tests, 5% was considered the significance level ($P < 0.05$). To compare the rate of vitreous incarceration observed in the sclerotomies without considering the amount of residual vitreous in grades (*V0* or *V1+V2*), according to the absence or presence of a conjunctival bleb (*B0* or *B1+B2*), we used Fisher's Exact test. To compare the proportion of vitreous incarceration grades observed in the incisions (*V0*, *V1*, or *V2*), according to the conjunctival bleb grades detected over the sclerotomies (*B0*, *B1*, or *B2*), we employed the Kruskal-Wallis test. To compare the presence (*B0* or *B1+B2*) and grade (*B0*, *B1*, or *B2*) of conjunctival blebs observed in the sclerotomies, according to the cannula

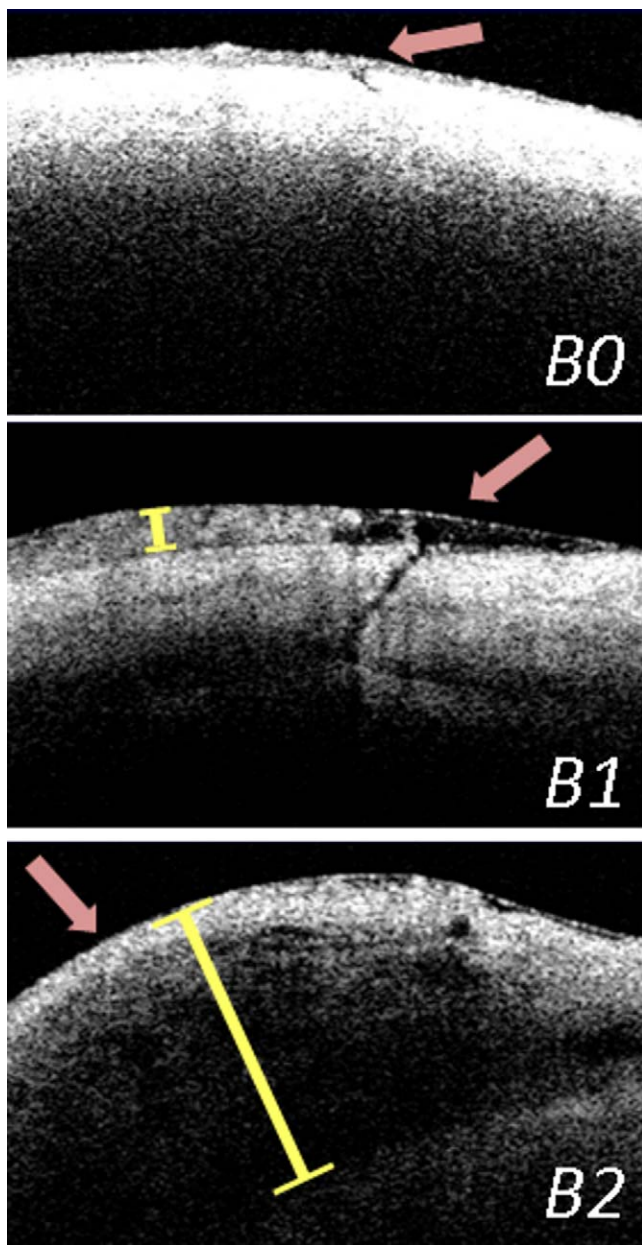


FIGURE 2. Conjunctival blebs were classified by AS-OCT according to the amount of subconjunctival leakage observed. No bleb was classified as grade 0 (*B0*), thin bleb (\leq half scleral thickness) as grade 1 (*B1*), and thick bleb ($>$ half scleral thickness) as grade 2 (*B2*).

removal technique performed (extraction with light probe or cannula plug inserted), we used Fisher's Exact test and the Mann-Whitney *U* test, respectively. Finally, to compare the grade of vitreous incarceration observed in the incisions (*V0*, *V1*, or *V2*), according to the cannula extraction maneuver performed, we used the Mann-Whitney *U* test.

RESULTS

Postmortem vitreous was clear in all globes. Most eyes did not present posterior vitreous detachment; however, for studying vitreous incarceration in anterior sclerotomies, we did not need to extract posterior hyaloid, but just enough core and anterior vitreous to allow BSS to flow freely through the




FIGURE 3. Vitreous incarceration was classified by direct visualization according to the amount of vitreous incarcerated. No incarceration was classified as grade 0 (*V0*), thin incarceration as grade 1 (*V1*), and thick incarceration as grade 2 (*V2*).

cannulas after removing the instruments. No intraoperative complications, such as retinal breaks or retinal detachments, were detected in any case.

Vitreous incarceration was found in 92.8% of the sclerotomies (271/292): 56.8% were *V1* (166/292) and 36% *V2* (105/292). In turn, subconjunctival leakage was detected in 13.7% of the wounds (40/292): 11.3% were *B1* (33/292) and 2.4% *B2* (7/292).

Vitreous incarceration was found in 96.5% of the wounds without conjunctival bleb (*B0*) (55.6% [140/252]) presented vitreous entrapment *V1*, and 40.9% (103/252) [entrapment *V2*]). Amongst the sclerotomies that showed subconjunctival leakage *B1*, 81.8% of them exhibited vitreous incarceration (75.7% [25/33] showed incarceration *V1*, and 6.1% [2/33] incarceration *V2*). Finally, when the incisions with conjunctival

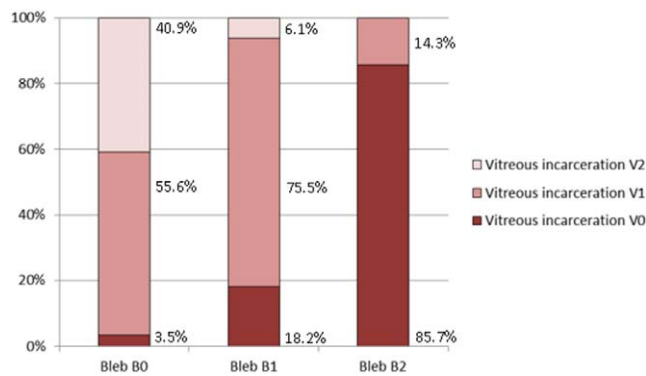


FIGURE 4. Proportion of vitreous incarceration grades detected in the sclerotomies, according to the incisional conjunctival bleb observed. Significant differences were observed ($P < 0.001$; Kruskal-Wallis test).

blebs *B2* were studied, 14.3% of them had vitreous entrapment *V1* (1/7) and none of them presented vitreous strands *V2* (Fig. 4). When we compared the presence of vitreous incarceration (*V0* or *V1+V2*) observed in the sclerotomies, according to the absence or presence of conjunctival bleb (*B0* or *B1+B2*), significant differences were found between the greater proportion of vitreous incarceration presented in the sclerotomies without conjunctival bleb (243/252) when compared with the less proportion of residual vitreous detected in sclerotomies with subconjunctival leakage (28/40) ($P < 0.001$; Fisher's Exact test). When we compared the proportion of vitreous incarceration grades (*V0*, *V1*, or *V2*) observed in the three sclerotomy subgroups, according to the conjunctival bleb grade detected (*B0*, *B1*, or *B2*), significant differences were found ($P < 0.001$; Kruskal-Wallis test). These differences were mainly based on the greater number of vitreous incarcerations *V2* observed in sclerotomies without conjunctival bleb, and the fewer number of vitreous entrapments *V1* presented in the sclerotomies with conjunctival bleb *B2* (Fig. 4).

Conjunctival blebs were detected in 19.9% (29/146) of the incisions whose cannulas were extracted with the light probe inserted (15.1% showed bleb *B1*, 4.8% bleb *B2*). In turn, subconjunctival leakage was detected in 7.5% (11/146) of the incisions whose cannulas were removed with the plug inserted (7.5% showed blebs *B1* and none bleb *B2*) (Fig. 5). Significant differences were found when we compared the presence ($P = 0.003$, Fisher's Exact test) and the grade ($P = 0.029$, Mann-Whitney *U* test) of conjunctival blebs observed in the sclerotomies, according to the cannula removal technique performed (light pipe or cannula plug inserted).

On the other hand, significant differences were found ($P < 0.001$, Mann-Whitney *U* test) between the greater vitreous amount observed in the sclerotomies whose cannulas were extracted with the plug inserted (41.8% *V1*, 52.7% *V2*) when compared with that detected in the incisions whose cannulas were removed over the light probe (71.9% *V1*, 19.2% *V2*).

DISCUSSION

Since the establishment of the microincisional vitrectomy systems 23- and 25-gauge as the first choice vitrectomy technique for an increasing number of vitreoretinal surgeons,^{1,2} numerous authors have evaluated the postoperative closure competency of these sutureless sclerotomies.⁸⁻¹⁵

In our study, the presence of vitreous incarceration in the inner face of the sclerotomies was related to the absence of conjunctival blebs over the incisions. In addition, the amount

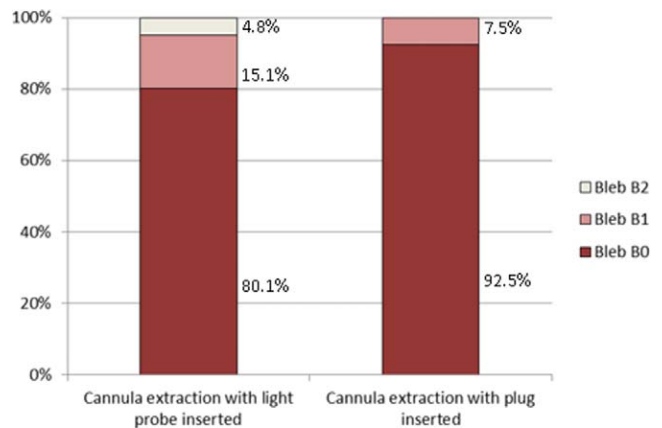


FIGURE 5. Proportion of conjunctival bleb grades detected in the incisions, according to the cannula extraction technique performed. Significant differences were observed ($P = 0.029$, Mann-Whitney *U* test).

(grade) of vitreous entrapment in the sclerotomies was inversely associated with the amount of subconjunctival leakage. Therefore, residual vitreous seems to work as an incisional plug, favoring the closure of the wounds; moreover, the mechanical occlusion obtained is proportional to the amount of vitreous entrapped.

Previously, studies that analyzed TSV sclerotomies by ultrasound biomicroscopy (UBM)^{14,15} did not find significant association between the presence of a conjunctival bleb and vitreous incarceration. However, they evaluated the sclerotomies one day after the surgery, so factors involved in subconjunctival bleb resolution, such as postoperative pressure patching and subconjunctival fluid expression by blinking were not avoided. In our study, the use of an animal model allowed us not only to use higher sensitivity evaluation methods than UBM in the study of conjunctival blebs and vitreous incarceration (AS-OCT^{18,19} and direct visualization,¹⁷ respectively), but also to analyze the sclerotomies in the immediate postoperative period, unlike in human studies. We considered it valuable to examine the sclerotomies shortly after the vitrectomy was finished, since this allowed us to study the real association between the presence of incisional vitreous entrapment and the sclerotomy closure. The time gap between vitrectomy and AS-OCT exploration may alter the presence of conjunctival blebs in the early postvitrectomy period, making results less reliable.

Recently, some authors have studied sclerotomy occlusion incompetency after vitrectomy.⁸⁻¹⁵ These studies have identified the gauge of the cannulas,¹¹ the angle of the incisions,¹⁴ the preoperative diagnosis,⁹ the surgical duration,⁹ and the age of the patient⁹ as factors involved in the postoperative sclerotomy leakage. However, the influence that the presence of incisional vitreous incarceration may exert on sclerotomy closure competency was not considered previously. This vitreous entrapment has been related to postoperative complications, such as peripheral retinal tears as a result of postoperative vitreous contraction,²¹⁻²³ acute endophthalmitis due to the presence of an incisional vitreous wick that may facilitate the entry of bacteria into the vitreous cavity,²⁴ and fibrovascular proliferation that is considered a major risk factor for recurring vitreous hemorrhage in diabetic patients.²⁵ However, it was important to evaluate the role that the residual vitreous may have on sclerotomy closure after vitrectomy, given that there are maneuvers with the ability to modify the presence of this vitreous entrapment.^{16,26,27}

Extracting the scleral cannula over the light pipe in an animal model has been related to less vitreous incarceration than removing the cannula with the plug inserted, due to the displacement effect of the vitreous placed inside the cannula by the illumination probe.¹⁶ With this maneuver, it is accepted a higher incidence and grade of conjunctival blebs over the sclerotomies and, therefore, a greater need of scleral suture. Postvitrectomy complications related to the presence of vitreous incarceration²¹⁻²⁵ cannot be avoided in the postoperative period; after the surgery we can only check the patient and act if any problem appears. In turn, the risk of complications associated with sclerotomy closure incompetency⁵⁻⁷ can be prevented by suturing the incisions. Thus, if these preclinical data were confirmed in humans, and with the aim of diminishing the risk of complications related to vitreous incarceration, it would be recommendable to remove the cannulas over the light pipe after vitrectomy in spite of the higher rate of incisional closure incompetency expected, as long as leaking incisions were sutured immediately.

Despite the morphologic similarities between human and pig eyes,²⁸⁻³¹ absolute incidence and grades of conjunctival blebs over the incisions and vitreous incarceration in sclerotomies obtained in our model should not be considered. The important outcome of our study is the inverse association between these two parameters (vitreous incarceration/conjunctival bleb), and the effect that the cannula extraction technique has on incisional closure competency.

Our animal model may become the basis for future studies aimed to analyze the influence that other modifiable factors may exert on the incisional vitreous incarceration and the presence of conjunctival bleb after vitrectomy, such as the gauge of the sclerotomies (23- and 25-gauge), the length and angle of the scleral tunnels, the shape of the wounds (lineal- or V-shaped incisions), presence of gas tamponade inside the vitreous cavity, IOP value during the cannula extraction, and suturing of sclerotomies. It may be also interesting to evaluate the relationship between the presence of incisional vitreous incarceration and subconjunctival leakage in eyes operated by different surgeons, to see if the results obtained in our study can be applicable to all vitreoretinal specialists.

Acknowledgments

The authors thank Tim Corson, PhD, from the IOVS Volunteer Editor Program for editing the manuscript.

Disclosure: **J. Benitez-Herreros**, None; **L. Lopez-Guajardo**, None; **C. Camara-Gonzalez**, None; **A. Perez-Crespo**, None; **A. Silva-Mato**, None; **A. Alvaro-Meca**, None; **M.A. Teus**, None

References

- Eckardt C. Transconjunctival sutureless 23-gauge vitrectomy. *Retina*. 2005;25:208-211.
- Fujii GY, De Juan E Jr, Humayun MS, et al. A new 25-gauge instrument system for transconjunctival sutureless vitrectomy surgery. *Ophthalmology*. 2002;109:1807-1812.
- Chen E. 25-gauge transconjunctival sutureless vitrectomy. *Curr Opin Ophthalmol*. 2007;18:188-193.
- Kellner L, Wimpfing B, Stolba U, Brannath W, Binder S. 25-gauge vs 20-gauge system for pars plana vitrectomy: a prospective randomized clinical trial. *Br J Ophthalmol*. 2007;91:945-948.
- Shaikh S, Ho S, Richmond PP, Olson JC, Barnes CD. Untoward outcomes in 25-gauge versus 20-gauge vitreoretinal surgery. *Retina*. 2007;27:1048-1053.
- Scott IU, Flynn HW Jr, Dev S, Shaikh S, Mitra RA, Arevalo JF, et al. Endophthalmitis after 25-gauge and 20-gauge pars plana

- vitrectomy: incidence and outcomes. *Retina*. 2008;28:138-142.
- Kunimoto DY, Kaiser RS. Incidence of endophthalmitis after 20- and 25-gauge vitrectomy. *Ophthalmology*. 2007;114:2133-2137.
- Shimada H, Nakashizuka H, Mori R, Mizutani Y, Hattori T. 25-gauge scleral tunnel transconjunctival vitrectomy. *Am J Ophthalmol*. 2006;142:871-873.
- Lin AL, Ghate DA, Robertson ZM, O'Sullivan PS, May WL, Chen CJ. Factors affecting wound leakage in 23-gauge sutureless pars plana vitrectomy. *Retina*. 2011;31:1101-1108.
- Woo SJ, Park KH, Hwang JM, Kim JH, Yu YS, Chung H. Risk factors associated with sclerotomy leakage and postoperative hypotony after 23-gauge transconjunctival sutureless vitrectomy. *Retina*. 2009;29:456-463.
- Lopez-Guajardo L, Benitez-Herreros J, Silva-Mato A. Experimental model to evaluate mechanical closure resistance of sutureless vitrectomy sclerotomies using pig eyes. *Invest Ophthalmol Vis Sci*. 2011;52:4080-4084.
- Benitez-Herreros J, Lopez-Guajardo L, Cámara-González C, Silva-Mato A. Influence of the sclerotomy use on mechanical incision competency in experimental model of vitrectomized eyes. *Curr Eye Res*. 2012;37:120-123.
- López-Guajardo L, Pareja-Esteban J, Teus-Guezala MA. Oblique sclerotomy technique for prevention of incompetent wound closure in transconjunctival 25-gauge vitrectomy. *Am J Ophthalmol*. 2006;141:1154-1156.
- López-Guajardo L, Vleming-Pinilla E, Pareja-Esteban J, Teus-Guezala MA. Ultrasound biomicroscopy study of direct and oblique 25-gauge vitrectomy sclerotomies. *Am J Ophthalmol*. 2007;143:881-883.
- Gutfleisch M, Dietzel M, Heimes B, Spital G, Pauleikhoff D, Lommatzsch A. Ultrasound biomicroscopic findings of conventional and sutureless sclerotomy sites after 20-, 23-, and 25-G pars plana vitrectomy. *Eye (Lond)*. 2010;24:1268-1272.
- Benitez-Herreros J, Lopez-Guajardo L, Camara-Gonzalez C, Silva-Mato A. Influence of the interposition of a non-hollow probe during cannula extraction on sclerotomy vitreous incarceration in sutureless vitrectomy. *Invest Ophthalmol Vis Sci*. 2012;54:7322-7326.
- Lopez-Guajardo L, Benitez-Herreros J, Camara-Gonzalez C, Silva-Mato A. Assessment of vitreous incarceration in sclerotomies with optical coherence tomography, ultrasound biomicroscopy and direct visualization. *Ophthalmic Surg Lasers Imaging*. 2012;43:S117-S122.
- Garcia JP Jr, Rosen RB. Anterior segment imaging: optical coherence tomography versus ultrasound biomicroscopy. *Ophthalmic Surg Lasers Imaging*. 2008;39:476-484.
- Zhang Y, Wu W, Zhang M, Song BW, Du XH, Lu B. Evaluating subconjunctival bleb function after trabeculectomy using slit-lamp optical coherence tomography and ultrasound biomicroscopy. *Chin Med J*. 2008;121:1274-1279.
- Mihailovic Z, Atanasijevic T, Popovic V, Milosevic MB. Could lactates in vitreous humour be used to estimate the time since death. *Med Sci Law*. 2011;51:156-160.
- Buettner H, Macherer R. Histopathologic findings in human eyes after pars plana vitrectomy and lensectomy. *Arch Ophthalmol*. 1977;95:2029-2033.
- Gosse E, Newsom R, Lochhead J. The incidence and distribution of iatrogenic retinal tears in 20-gauge and 23-gauge vitrectomy. *Eye*. 2012;26:140-143.
- Tan HS, Mura M, de Smet MD. Iatrogenic retinal breaks in 25-gauge macular surgery. *Am J Ophthalmol*. 2009;148:427-430.
- Chen SD, Mohammed Q, Bowling B, Patel CK. Vitreous wick syndrome—a potential cause of endophthalmitis after intravitreal injection of triamcinolone through the pars plana. *Am J Ophthalmol*. 2004;137:1159-60; author reply 1160-1161.

25. Hotta K, Hirakata A, Ohi Y, et al. Ultrasound biomicroscopy for examination of the sclerotomy site in eyes with proliferative diabetic retinopathy after vitrectomy. *Retina*. 2000;20:52-58.
26. Chalam KV, Shah GY, Agarwal S, Gupta SK. Illuminated curved 25-gauge vitrectomy probe for removal of subsclerotomy vitreous in vitreoretinal surgery. *Indian J Ophthalmol*. 2008;56:331-334.
27. Sabti K, Kapusta M, Mansour M, Overbury O, Chow D. Ultrasound biomicroscopy of sclerotomy sites: the effect of vitreous shaving around sclerotomy sites during pars plana vitrectomy. *Retina*. 2001;21:464-468.
28. Olsen TW, Sanderson S, Feng X, Hubbard WC. Porcine sclera: thickness and surface area. *Invest Ophthalmol Vis Sci*. 2002;43:2529-2532.
29. Olsen TW, Aaberg SY, Geroski DH, Edelhauser HF. Human sclera: thickness and surface area. *Am J Ophthalmol*. 1998;125:237-241.
30. Nicoli S, Ferrari G, Quarta M, et al. Porcine sclera as a model of human sclera for in vitro transport experiments: histology, SEM, and comparative permeability. *Mol Vis*. 2009;15:259-266.
31. Lee B, Litt M, Buchsbaum G. Rheology of the vitreous body: part 3. Concentration of electrolytes, collagen and hyaluronic acid. *Biorheology*. 1994;31:339-351.