

# Ultra-Widefield Fluorescein Angiographic Findings in Patients With Recurrent Vitreous Hemorrhage After Diabetic Vitrectomy

Dong Yoon Kim, June-Gone Kim, Yoon Jeon Kim, Soo Geun Joe, and Joo Yong Lee

Department of Ophthalmology, Asan Medical Center, University of Ulsan, College of Medicine, Seoul, Korea

Correspondence: June-Gone Kim, Department of Ophthalmology, Asan Medical Center, University of Ulsan, College of Medicine, 88, Olympic-ro 43-gil, Songpa-gu, Seoul 138-736, Korea;

junekim@amc.seoul.kr.

Submitted: June 26, 2014

Accepted: September 26, 2014

Citation: Kim DY, Kim J-G, Kim YJ, Joe SG, Lee JY. Ultra-widefield fluorescein angiographic findings in patients with recurrent vitreous hemorrhage after diabetic vitrectomy. *Invest Ophthalmol Vis Sci.* 2014;55:7040-7046. DOI:10.1167/iovs.14-15112

**PURPOSE.** To analyze differences in ultra-widefield fluorescein angiography (UWFFA) findings between patients with recurrent postvitrectomy diabetic vitreous hemorrhage (PVDVH) and patients with non-PVDVH (NPVDVH).

**METHODS.** Patients were categorized as PVDVH when vitreous hemorrhage recurred after diabetic vitrectomy. Age-matched control diabetic patients in whom vitreous hemorrhage did not recur after vitrectomy were assigned to the NPVDVH group. Baseline characteristics were compared between groups. Also peripheral angiographic findings such as peripheral neovascularization, nonperfusion, and late peripheral vascular leakage were analyzed by UWFFA.

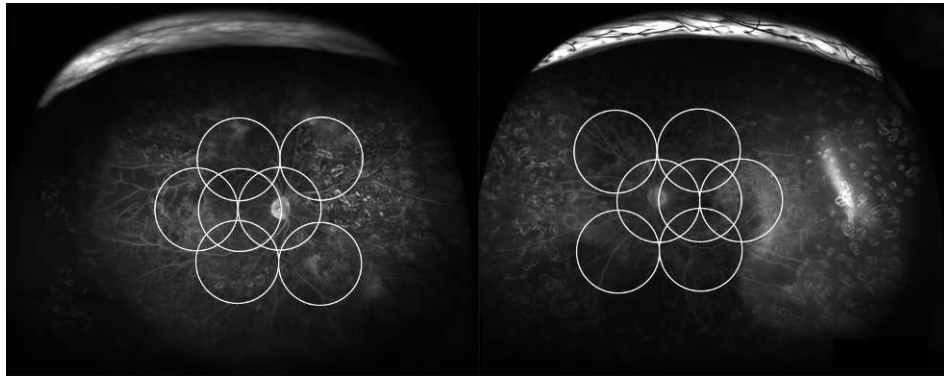
**RESULTS.** A total of 46 eyes were included this retrospective study: 22 with PVDVH and 24 with NPVDVH. Preoperative, 3-month postoperative, and final-visit best corrected visual acuity (BCVA) were not different between the two groups. The rate of peripheral neovascularization was significantly different (PVDVH 40.9%, NPVDVH 8.3%,  $P = 0.010$ ). The rate of peripheral nonperfusion was significantly greater in PVDVH eyes than in NPVDVH eyes (81.8% vs. 37.5%,  $P = 0.002$ ). The rate of late peripheral vascular leakage was also significantly greater in PVDVH eyes (90.9% vs. 29.2%,  $P < 0.001$ ). These differences in peripheral angiographic findings were not seen within the conventional Early Treatment Diabetic Retinopathy Study (ETDRS) 7 standard fields. Ischemic index was also significantly higher in the PVDVH group than in the NPVDVH group.

**CONCLUSIONS.** Compared with diabetic vitrectomized eyes that did not have recurring vitreous hemorrhage, PVDVH eyes had a higher rate of peripheral neovascularization, nonperfusion, and late peripheral vascular leakage. These differences were not found within the conventional ETDRS 7 standard fields. Therefore, it is important to assess peripheral retinal vessels by UWFFA after diabetic vitrectomy. Furthermore, in cases of peripheral neovascularization, peripheral nonperfusion, and late peripheral vascular leakage, additional treatment may be necessary to prevent PVDVH.

**Keywords:** ultra-widefield fluorescein angiography, postvitrectomy diabetic vitreous hemorrhage, diabetes, vitrectomy

The incidence of postvitrectomy diabetic vitreous hemorrhage (PVDVH) ranges from 12% to 63%.<sup>1-3</sup> With technical advances in treatment, the incidence of PVDVH has declined.<sup>4-6</sup> Nevertheless, PVDVH remains an important complication of diabetic vitrectomy because it affects the patient's vision and sometimes requires repeated surgical procedures.<sup>3,7</sup> However, determining the etiology of recurrent vitreous hemorrhage after diabetic vitrectomy can be difficult. Previous studies reported that early recurrent hemorrhage after vitrectomy for proliferative diabetic retinopathy (PDR) may originate from dissected fibrovascular tissue or from dispersion of residual blood at the vitreous base or retinal surface into the vitreous cavity. Furthermore, possible causes of late recurrent hemorrhage after vitrectomy for PDR include fibrovascular proliferation from sclerotomy sites; neovascularization of residual fibrovascular tissue, the vitreous base, the iris, and angle; or trauma.<sup>1,3,8,9</sup>

With advances in scanning laser ophthalmoscope technology, it is possible to obtain high-resolution angiographic images of the peripheral retina. The Optos C200 MA scanning laser ophthalmoscope (Optos PLC, Dunfermline, UK) is one of the commercially available systems for peripheral retinal fluorescein angiography. The Optos system can get peripheral retinal images without the need for a contact lens or pupillary dilation. Several reports have presented peripheral retinal fluorescein angiographic findings of retinal vein occlusion, uveitis, and diabetes.<sup>10-17</sup> However, little is known about ultra-widefield fluorescein angiographic findings in PVDVH eyes. The aim of the present study was to analyze the differences in ultra-widefield fluorescein angiographic findings such as peripheral nonperfusion, late peripheral vascular leakage, and retinal neovascularization between patients with recurrent PVDVH and patients with non-PVDVH (NPVDVH).



**FIGURE 1.** Interpretation of ultra-widefield fluorescein angiographic findings and overlaid conventional ETDRS 7 field template. Peripheral retinal neovascularization was defined as focal leakage beyond the temporal retinal vascular arcades. Peripheral nonperfusion was defined as capillary nonperfusion greater than 5 disc diameters in area outside the vascular arcades. Late peripheral vessel leakage was defined as late venous or arterial hyperfluorescence peripheral to the temporal vascular arcades. Late-phase UWFFA data obtained 3 to 5 minutes after dye injection was used to analyze late peripheral vessel leakage.

## METHODS

### Study Design and Participants

A retrospective review was conducted of all patients who underwent vitrectomy for diabetic vitreous hemorrhage at Asan Medical Center in Seoul, Korea, from January 2007 through October 2013. Inclusion criteria were as follows: (1) three-port pars plana vitrectomy for diabetic vitreous hemorrhage or tractional retinal detachment, with or without cataract surgery; (2) clinically significant PVDVH after a postoperative period in which the vitreous was clear; (3) panretinal photocoagulation performed before diabetic vitrectomy or during diabetic vitrectomy; (4) ultra-widefield fluorescein angiography (UWFFA) performed after PVDVH was cleared; and (5) an interval of more than 1 month between UWFFA and last intravitreal bevacizumab injection. As a control group, patients without recurrent vitreous hemorrhage after three-port pars plana vitrectomy for diabetic vitreous hemorrhage or tractional retinal detachment were also included in this study. Exclusion criteria included other ocular disease that might affect vision, active intraocular inflammation and/or infection, or recurrent vitreous hemorrhage caused by trauma. The study was approved by the Institutional Review Board of Asan Medical Center and followed the tenets of the Declaration of Helsinki.

Postvitrectomy diabetic vitreous hemorrhage was defined as occurring in eyes with recurrent vitreous hemorrhage after diabetic vitrectomy. Non-PVDVH was defined as occurring in eyes with no episode of recurrent vitreous hemorrhage after diabetic vitrectomy.

### Primary and Secondary Objectives

The primary objective of this study was to analyze the differences in ultra-widefield fluorescein angiographic findings between patients with recurrent PVDVH and patients with NPVDVH. We also analyzed the differences in fluorescein angiographic findings within the conventional Early Treatment Diabetic Retinopathy Study (ETDRS) 7 standard fields between two groups. The secondary objectives of this study were to determine (1) differences in baseline characteristics between PVDVH and NPVDVH patients; (2) whether the maintenance treatment of intravitreal bevacizumab injection or additional panretinal photocoagulation may prevent the recurrence of PVDVH; (3) whether the interval between UWFFA and last intravitreal bevacizumab injection impacted ultra-widefield

fluorescein angiographic findings in PVDVH eyes; and (4) whether recurrent vitreous hemorrhage affected best corrected visual acuity (BCVA) at last visit.

### Ophthalmic Examinations

All patients underwent a complete bilateral ophthalmic examination, including BCVA using the Snellen chart. The BCVA results were converted to the logarithm of the minimal angle of resolution (logMAR) scale. Patients capable only of counting fingers, detecting hand motion, light perception, or having no light perception were assigned logMAR values of 2.0, 2.3, 2.7, and 3.0, respectively.<sup>18</sup> After onset of recurrent vitreous hemorrhage, if the disc was obscured by vitreous hemorrhage, ultrasonography was performed. When the vitreous hemorrhage was cleared, all subjects underwent UWFFA using the Optos C200 MA imaging system (Optos PLC) after standard intravenous infusion of 5 mL 10% sodium fluorescein.

### Interpretation of Ultra-Widefield Fluorescein Angiography

Using UWFFA, the presence of peripheral retinal neovascularization, peripheral retinal nonperfusion, and late peripheral vascular leakage was determined by two independent observers (DYK and YJK). If there was discordance in their interpretation, a third observer (J-GK) was asked to assess the peripheral retinal angiographic findings. We also determined these peripheral angiographic findings within the conventional ETDRS 7 fields described in the ETDRS. After we overlaid the ETDRS 7 field template on the UWFFA, the image beyond the ETDRS 7 fields was erased. Overlaid ETDRS 7 field images were analyzed by another retinal specialist (SGJ) who did not know the ultra-widefield fluorescein angiographic findings. The ultra-widefield fluorescein angiographic findings of PVDVH eyes and overlaid ETDRS 7 field template are shown in Figure 1. Peripheral retinal neovascularization was defined as focal leakage beyond the temporal retinal vascular arcades. Peripheral nonperfusion was defined as capillary nonperfusion greater than 5 disc diameters in area outside the vascular arcades. Late peripheral vessel leakage was defined as late venous or arterial hyperfluorescence peripheral to the temporal vascular arcades and nasal periphery. Late-phase UWFFA data obtained 3 to 5 minutes after dye injection were used to analyze late peripheral vessel leakage. The ischemic index was calculated using the previously described meth-

TABLE 1. Ultra-Widefield Angiographic Findings of the Two Groups

	Group		P Value
	Without PVDVH (%)	With PVDVH (%)	
UWFFA			
Peripheral neovascularization	2/24 (8.3%)	9/22 (40.9%)	<0.05*
Peripheral nonperfusion	9/24 (37.5%)	18/22 (81.8%)	<0.05*
Late peripheral vascular leakage	7/24 (29.2%)	20/22 (90.9%)	<0.05*
Ischemic index	0.11 ± 0.15	0.49 ± 0.29	<0.05†
7SF			
Peripheral neovascularization	2/24 (8.3%)	3/22 (8.3%)	0.564*
Peripheral nonperfusion	2/24 (8.3%)	5/22 (22.7%)	0.175*
Late peripheral vascular leakage	4/24 (16.7%)	6/22 (27.3%)	0.384*

7SF, Conventional Early Treatment Diabetic Retinopathy Study (ETDRS) 7 standard fields image.

\* Pearson  $\chi^2$  test.

† Mann-Whitney *U* test.

od.<sup>19,20</sup> Briefly, the total image area and the area of capillary nonperfusion seen in the arteriovenous phase were encircled using the ImageJ program (version 1.48; National Institutes of Health, Bethesda, MD, USA). Pixels of the nonperfusion area was divided by pixels of total image area.

### Management of Postvitrectomy Diabetic Vitreous Hemorrhage

Whenever the PVDVH occurred, intravitreal bevacizumab was injected immediately in all cases of PVDVH. Furthermore, for recurrent PVDVH cases, maintenance therapy of intravitreal bevacizumab injection at 2- or 3-month intervals was used to prevent recurrent PVDVH. Some cases of PVDVH underwent additional panretinal photocoagulation after UWFFA. Air–fluid exchange was performed in patients with thick PVDVH in whom vitreous hemorrhage was not resolved after intravitreal bevacizumab injection or in those wanting faster visual recovery.

### Statistical Analysis

The Kolmogorov-Smirnov test was used to determine whether the data were normally distributed. Clinical characteristics were compared between PVDVH and NPVDVH groups using the Mann-Whitney *U* test. Fisher's exact test or Pearson  $\chi^2$  test was used to analyze the difference in peripheral retinal neovascularization, peripheral retinal nonperfusion, and late peripheral vascular leakage between the two groups. The Mann-Whitney *U* test was used to compare BCVA between the two groups. SPSS version 21.0 (SPSS, Inc., Chicago, IL, USA) was used for all analyses, and a *P* value < 0.05 was considered statistically significant.

## RESULTS

Among the patients who underwent vitrectomy for diabetic vitreous hemorrhage or tractional retinal detachment at Asan Medical Center in Seoul, Korea, from January 2007 through October 2013, 22 eyes satisfied the inclusion criteria for the current study. In addition, 24 eyes with NPVDVH were included in this study as the control group.

### Primary Objective

Ultra-widefield fluorescein angiographic findings of the two groups are shown in Table 1 and Figure 2. Figure 2 shows ultra-widefield fluorescein angiographic findings for NPVDVH and PVDVH. Table 1 shows the comparison of ultra-widefield

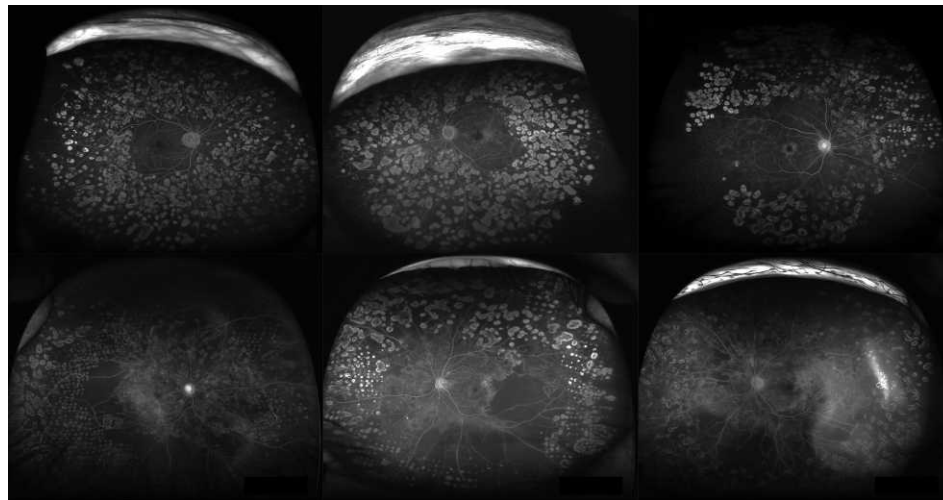
fluorescein angiographic findings between the two groups. The rate of peripheral neovascularization was significantly different between groups, with a higher rate observed in the PVDVH group (PVDVH 40.9%, NPVDVH 8.3%, *P* < 0.05). The rate of peripheral nonperfusion greater than 5 disc diameters was significantly higher in PVDVH patients than in NPVDVH patients (81.8% vs. 37.5%, *P* < 0.05). In addition, the rate of late peripheral vascular leakage was significantly greater in the PVDVH group than in the NPVDVH group (90.9% vs. 29.2%, *P* < 0.05). However, within the conventional EDTRS 7 fields, those differences were not found. The ischemic index was significantly higher in the PVDVH group than in the NPVDVH group (0.49 ± 0.29 vs. 0.11 ± 0.15, *P* < 0.05).

### Secondary Objectives

The baseline characteristics of each patient are shown in Table 2. The preoperative logMAR BCVA, the preoperative diagnosis, and the total number of panretinal photocoagulations were not significantly different between the two groups. Glycated hemoglobin (HbA1C) levels (preoperatively and at final visit) and the duration of diabetes (preoperatively and at final visit) were also not significantly different between the two groups.

The characteristics of PVDVH are listed in Table 3. The mean number of episodes of PVDVH was 2.18 ± 1.71. The mean time to first PVDVH was 5.32 ± 6.08 months after diabetic vitrectomy. Among the 22 eyes with PVDVH, 11 (50.0%) developed PVDVH within 3 months of diabetic vitrectomy. The mean time to UWFFA after PVDVH was 2.77 ± 2.09 months. All PVDVH eyes were treated by intravitreal bevacizumab injection, with a mean number of injections of 6.73 ± 5.28. To prevent recurrent PVDVH, maintenance treatment via intravitreal bevacizumab injection at 2- or 3-month intervals was performed in 18 eyes (81.8%); of these, only three eyes had recurrence of vitreous hemorrhage during intravitreal bevacizumab maintenance treatment. Ten eyes received additional panretinal photocoagulation after UWFFA; of these, only one eye (10.0%) developed recurrence of vitreous hemorrhage after additional panretinal photocoagulation. Eight eyes received both treatments (maintenance treatment with intravitreal bevacizumab injection and additional panretinal photocoagulation) after UWFFA; of these, no eye developed recurrence of vitreous hemorrhage.

Ultra-widefield fluorescein angiographic findings according to the interval between UWFFA and last bevacizumab injection in PVDVH patients are described in Table 4. We divided patients into two groups according to interval between the last intravitreal bevacizumab injection and UWFFA: an interval less than 3 months in one group and an interval more than 3



**FIGURE 2.** Ultra-widefield fluorescein angiographic findings of postvitrectomy diabetic vitreous hemorrhage (PVDVH) and patients with non-PVDVH (NPVDVH). *Top:* ultra-widefield fluorescein angiographic findings of NPVDVH. *Bottom:* ultra-widefield fluorescein angiographic findings of PVDVH. Unlike NPVDVH, PVDVH eyes showed peripheral neovascularization, peripheral nonperfusion, and late peripheral vascular leakage.

months in the other group. The rates of peripheral neovascularization, peripheral nonperfusion, and late peripheral vascular leakage were not significantly different according to the interval between UWFFA and last bevacizumab injection.

The logMAR BCVA at selected time points in the two groups is shown in Table 5. Preoperative logMAR BCVA was not significantly different between the two groups (PVDVH 1.04 ± 0.73, NPVDVH 1.16 ± 0.71, *P* = 0.543). LogMAR BCVA values at 3 months after vitrectomy and at last visit were also not

significantly different between the two groups (3 months after vitrectomy, PVDVH 0.33 ± 0.33, NPVDVH 0.37 ± 0.48, *P* = 0.982) (last visit, PVDVH 0.19 ± 0.31, NPVDVH 0.24 ± 0.47, *P* = 0.558).

**DISCUSSION**

The etiology of PVDVH following successful complete vitrectomy is diverse. While advances in surgical treatment

**TABLE 2.** Baseline Characteristics of the Two Groups

	Group		<i>P</i> Value
	Without PVDVH Mean ± SD (Range)	With PVDVH Mean ± SD (Range)	
Number of eyes	24	22	
Age, y	58.58 ± 10.90 (35-74)	54.68 ± 9.84 (39-81)	0.152*
Sex, male/female	16/8	17/5	0.425†
Diagnosis			
Simple VH	17, 70.8%	14, 63.6%	0.603‡
VH + tRD	7, 29.2%	8, 36.4%	
Number of panretinal photocoagulations	2047.58 ± 311.80 (1550-2535)	2205.75 ± 615.98 (1304-3765)	0.580*
Gauge surgery			0.349‡
20 gauge	4, 16.7%	1, 4.5%	
23/25 gauge	20, 83.3%	21, 95.5%	
F/U duration after vitrectomy, mo	42.13 ± 17.76 (13-82)	31.64 ± 18.04 (9-83)	<0.05*
HbA1C preoperatively	8.10 ± 0.93 (5.4-9.6)	8.11 ± 1.30 (5.3-10.7)	0.978*
HbA1C at last F/U	7.74 ± 1.42 (5.50-10.70)	7.60 ± 1.12 (5.6-10.1)	0.750*
Refractive error, SE	-0.11 ± 1.11 (-2.88 to 2.50)	-0.36 ± 1.11 (-3.00 to 0.75)	0.657*
Preoperative logMAR BCVA	1.16 ± 0.71 (0.10-2.30)	1.04 ± 0.74 (0.20-2.30)	0.543*
Systemic disease			
Hypertension	6/24, 25%	6/22, 27.3%	0.861†
Duration of HTN, y	9.50 ± 7.89 (2-23)	5.50 ± 6.35 (1-18)	0.331*
Duration of DM at last F/U, y	17.17 ± 6.91 (5-30)	14.73 ± 6.92 (2-28)	0.238*
Duration of DM preoperatively, y	13.67 ± 6.84 (1-25)	12.14 ± 6.50 (1-26)	0.704*

VH, vitreous hemorrhage; tRD, tractional retinal detachment; SE, spherical equivalent; SD, standard deviation; HTN, hypertension; DM, diabetes; F/U, follow-up.

\* Mann-Whitney *U* test.

† Pearson  $\chi^2$  test.

‡ Fisher's exact test.

**TABLE 3.** Recurrent Vitreous Hemorrhage After Vitrectomy for Diabetic Vitreous Hemorrhage

	PVDVH Mean ± SD (Range)
Number of eyes	22
Silicone oil tamponade during diabetic vitrectomy	1/22, 4.5%
Episodes of recurrent PVDVH	2.18 ± 1.71 (1-8)
Time to first PVDVH, mo	5.32 ± 6.08 (1-25)
0-3 mo	11/22, 50.0%
4-6 mo	7/22, 31.8%
After 6 mo	4/22, 18.2%
Time to recovery from first episode of PVDVH, d	23.00 ± 14.83 (7-56)
Intravitreal bevacizumab injection after PVDVH	22/22, 100.0%
Number of bevacizumab injections	6.73 ± 5.28 (2-23)
Bevacizumab maintenance treatment	18/22, 81.8%
Recurrence during bevacizumab maintenance treatment	3/18, 16.7%
Time to UWFFA after last bevacizumab injection, mo	2.77 ± 2.31 (1-8)
Time to UWFFA after PVDVH, mo	2.77 ± 2.09 (1-8)
Additional panretinal photocoagulation after UWFFA	10/22, 45.5%
Recurrence after additional panretinal photocoagulation	1/10, 10.0%
Air-fluid exchange for PVDVH	7/22, 31.8%
Repeated surgery for PVDVH required	0/22, 0%

have decreased the incidence of PVDVH, it remains a serious complication for surgeons and patients. Determining the exact cause of PVDVH is important for the treatment and prevention of recurrent PVDVH. Many studies have reported that fibrovascular proliferation at the sclerotomy site is the main cause of PVDVH. Hershberger et al.<sup>8</sup> reported that 85% of PVDVH eyes had fibrovascular ingrowth at the sclerotomy site. Using UWFFA, peripheral retinal fluorescein angiographic images can be obtained. Several studies have reported the peripheral fluorescein angiographic findings for various diseases.<sup>10-15</sup> However, little is known about ultra-widefield fluorescein angiographic findings of PVDVH eyes. In this study, we analyzed the difference in peripheral fluorescein angiographic findings between PVDVH and NPVDVH patients.

Our current results show that the rates of peripheral retinal neovascularization, peripheral nonperfusion, and late peripheral vascular leakage were significantly greater in PVDVH eyes than in NPVDVH eyes. However, those differences were not found within the conventional ETDRS 7 fields. Figure 3 shows the UWFFA of PVDVH eyes overlaid by the conventional ETDRS 7 field template; multiple instances of nonperfusion and late peripheral vascular leakage were found anterior to the conventional ETDRS 7 fields. We thought that the underlying cause of PVDVH might be peripheral retinal neovascularization if it was found on UWFFA. However, if peripheral retinal neovascularization was not found on UWFFA, the underlying cause of PVDVH might be related to fibrovascular ingrowth at the sclerotomy site or peripheral retinal neovascularization beyond UWFFA.

Oliver and Schwartz<sup>17</sup> reported that untreated peripheral nonperfusion and late peripheral vascular leakage detected using UWFFA are associated with retinal neovascularization in diabetic retinopathy. They suggested that upregulation of vascular endothelial growth factor (VEGF), which promotes capillary hyperpermeability, may result in late peripheral vascular leakage. Therefore, they hypothesized that late peripheral vascular leakage could be a marker for active diabetic retinopathy and may be a sensitive marker of ischemia in diabetic retinopathy.<sup>17</sup> Furthermore, Funatsu et al.<sup>21</sup> reported that high vitreous levels of VEGF are a significant risk factor for poor outcome of vitreous surgery in patients with PDR.

After diabetic vitrectomy, the higher VEGF concentration in the vitreous cavity may induce peripheral retinal neovascularization or fibrovascular proliferation at the sclerotomy site, and the induced peripheral retinal neovascularization or fibrovascular proliferation at the sclerotomy site may contribute to the development of PVDVH. In our present report, a higher rate of peripheral nonperfusion and late peripheral vascular leakage was observed in eyes with PVDVH. As previously mentioned, these peripheral angiographic findings may reflect a higher level of VEGF in the vitreous cavity and retinal ischemia. Therefore, a higher rate of peripheral nonperfusion and late peripheral vascular leakage in UWFFA may be associated with PVDVH.

Aiello et al.<sup>22</sup> reported that the VEGF concentration in vitreous fluid declines after successful laser photocoagulation. If upregulated VEGF levels are a causative factor for PVDVH, we hypothesized that additional peripheral laser photocoagu-

**TABLE 4.** Ultra-Widefield Angiographic Findings According to Time to UWFFA After Last Bevacizumab Injection in PVDVH Eyes

	Group		P Value
	Time to UWFFA After IVB < 3 mo	Time to UWFFA After IVB ≥ 3 mo	
Peripheral neovascularization	5/14, 35.7%	4/8, 50.0%	0.662*
Peripheral nonperfusion	11/14, 78.6%	7/8, 87.5%	1.000*
Late peripheral vascular leakage	13/14, 92.9%	7/8, 87.5%	1.000*

IVB, intravitreal bevacizumab injection.

\* Fisher's exact test.

TABLE 5. LogMAR BCVA at Selected Time Points in the Two Groups

	Group		P Value
	Without PVDVH Mean $\pm$ SD (Range)	With PVDVH Mean $\pm$ SD (Range)	
Preoperative logMAR BCVA	1.16 $\pm$ 0.71 (0.10–2.30)	1.04 $\pm$ 0.73 (0.20–2.30)	0.543*
3-mo logMAR BCVA	0.37 $\pm$ 0.48 (0.00–2.30)	0.33 $\pm$ 0.33 (0.00–1.15)	0.982*
LogMAR BCVA at initial PVDVH		1.64 $\pm$ 0.72 (0.40–2.30)	
Final-visit logMAR BCVA	0.24 $\pm$ 0.47 (0.00–2.30)	0.19 $\pm$ 0.31 (0.00–1.15)	0.558*
Final-visit IOP, mm Hg	16.21 $\pm$ 3.20 (12–21)	16.50 $\pm$ 2.48 (12–21)	0.799*

IOP, intraocular pressure.

\* Mann-Whitney *U* test.

lation or intravitreal bevacizumab maintenance treatment to diabetic vitrectomized eyes with peripheral fluorescein angiographic findings may result in mitigating VEGF upregulation. This would eventually prevent the development of PVDVH. In fact, in our present analyses, of 18 eyes that received intravitreal bevacizumab maintenance treatment for PVDVH, only three eyes (16.7%) developed recurrence of vitreous hemorrhage. And among 10 eyes that received additional panretinal photocoagulation after UWFFA, only one eye (10.0%) developed recurrence of vitreous hemorrhage. However, future prospective studies are needed to determine the exact preventive effect of laser and bevacizumab maintenance treatment on recurrent vitreous hemorrhage in eyes with peripheral nonperfusion and late peripheral vascular leakage.

All eyes were treated by intravitreal bevacizumab injection for PVDVH. Mean time to UWFFA after the last bevacizumab injection was  $2.77 \pm 2.31$  months (range, 1–8 months). We analyzed whether the interval between UWFFA and the last intravitreal bevacizumab injection had an effect on ultra-widefield fluorescein angiographic findings of PVDVH eyes. As the retinal new vessel was regressed 2.9 months after intravitreal bevacizumab injection (Schmidinger et al.<sup>23</sup>), we divided patients into two groups according to the interval between the last intravitreal bevacizumab injection and UWFFA: a <3-month group and a  $\geq 3$ -month group. Similarly to previous findings (Schmidinger et al.<sup>23</sup>), peripheral retinal neovascularization slightly regressed within 3 months after intravitreal bevacizumab injection (peripheral retinal neovascularization; less than 3 months = 35.7%, more than 3 months = 50.0%). However, we did not see statistically significant differences in the peripheral angiographic findings between the two groups. Therefore, we assumed that intravitreal bevacizumab injection

does not change the peripheral fluorescein angiographic findings for PVDVH eyes at 1 month after injection. However, future studies with larger numbers of patients are needed to confirm the influence of bevacizumab on peripheral angiographic findings of PVDVH eyes.

Finally, we investigated whether PVDVH has an effect on patients' final vision. Mason et al.<sup>24</sup> reported that vitreous hemorrhage after diabetic vitrectomy appears to be a risk factor for light perception only and no light perception vision following diabetic vitrectomy. However, Tolentino et al.<sup>25</sup> have reported that postdiabetic vitrectomy hemorrhage did not significantly influence final visual outcome in their patients, and Shi and Huang<sup>26</sup> reported that with surgical and nonsurgical treatments, visual acuity increased in 86% of the PVDVH eyes. We compared the BCVA between PVDVH and NPVDVH eyes preoperatively, 3 months after vitrectomy, and at the last visit. In contrast to the findings by Mason et al.,<sup>24</sup> the BCVA preoperatively, 3 months postoperatively, and at the final visit did not differ between our two study groups. Therefore, we thought that prompt treatment of PVDVH with intravitreal bevacizumab injection or maintenance therapy of intravitreal bevacizumab or additional panretinal photocoagulation may improve visual prognosis of PVDVH patients.

The strength of our current study is that ultra-widefield fluorescein angiographic images were carefully analyzed by retinal subspecialists (DYK, YJK, and JGK) who were masked to the clinical information of the patients. In addition, this is the first report to analyze ultra-widefield fluorescein angiographic findings of PVDVH eyes. However, our study has limitations that are inherent to its retrospective design. The sample size of this study was also relatively small, which may have limited the statistical strength of the analysis. Therefore, future studies examining a larger number of patients are needed to confirm our ultra-widefield fluorescein angiographic findings of PVDVH.

In conclusion, compared with diabetic vitrectomized eyes in which vitreous hemorrhage not recur after diabetic vitrectomy, PVDVH eyes had a higher rate of peripheral neovascularization, peripheral nonperfusion, and late peripheral vascular leakage. However, these differences was not found within the conventional ETDRS 7 fields. Therefore, it is important to evaluate peripheral retinal vessels using UWFFA after diabetic vitrectomy, especially in PVDVH eyes. Furthermore, in cases of peripheral neovascularization, peripheral nonperfusion, and late peripheral vascular leakage, additional treatment such as peripheral laser photocoagulation and intravitreal bevacizumab injection may be necessary to prevent PVDVH.

#### Acknowledgments

Disclosure: **D.Y. Kim**, None; **J.-G. Kim**, None; **Y.J. Kim**, None; **S.G. Joe**, None; **J.Y. Lee**, None

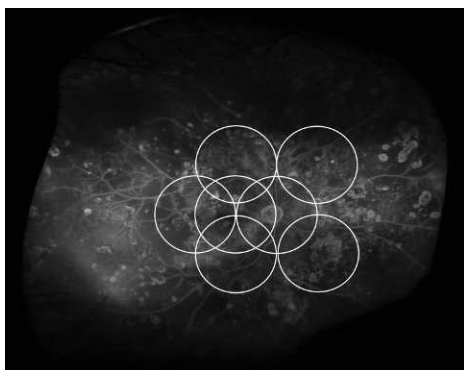


FIGURE 3. Ultra-widefield fluorescein angiography of postvitrectomy diabetic vitreous hemorrhage (PVDVH) overlaid by the conventional ETDRS 7 field template. There was extensive nonperfusion area and late peripheral vessel leakage anterior to the conventional ETDRS 7 fields.

## References

- West JF, Gregor ZJ. Fibrovascular ingrowth and recurrent haemorrhage following diabetic vitrectomy. *Br J Ophthalmol*. 2000;84:822-825.
- Yang CM. Surgical treatment for diabetic retinopathy: 5-year experience. *J Formos Med Assoc*. 1998;97:477-484.
- Novak MA, Rice TA, Michels RG, Auer C. Vitreous hemorrhage after vitrectomy for diabetic retinopathy. *Ophthalmology*. 1984;91:1485-1489.
- Yeh PT, Yang CM, Yang CH, Huang JS. Cryotherapy of the anterior retina and sclerotomy sites in diabetic vitrectomy to prevent recurrent vitreous hemorrhage: an ultrasound biomicroscopy study. *Ophthalmology*. 2005;112:2095-2102.
- Mason JO III, Colagross CT, Vail R. Diabetic vitrectomy: risks, prognosis, future trends. *Curr Opin Ophthalmol*. 2006;17:281-285.
- Sima P, Zoran T. Long-term results of vitreous surgery for proliferative diabetic retinopathy. *Doc Ophthalmol*. 1994;87:223-232.
- Yorston D, Wickham L, Benson S, Bunce C, Sheard R, Charteris D. Predictive clinical features and outcomes of vitrectomy for proliferative diabetic retinopathy. *Br J Ophthalmol*. 2008;92:365-368.
- Hershberger VS, Augsburger JJ, Hutchins RK, Raymond LA, Krug S. Fibrovascular ingrowth at sclerotomy sites in vitrectomized diabetic eyes with recurrent vitreous hemorrhage: ultrasound biomicroscopy findings. *Ophthalmology*. 2004;111:1215-1221.
- Sato T, Morita S, Bando H, Sato S, Ikeda T, Emi K. Early vitreous hemorrhage after vitrectomy with preoperative intravitreal bevacizumab for proliferative diabetic retinopathy. *Middle East Afr J Ophthalmol*. 2013;20:51-55.
- Friberg TR, Gupta A, Yu J, et al. Ultrawide angle fluorescein angiographic imaging: a comparison to conventional digital acquisition systems. *Ophthalmic Surg Lasers Imaging*. 2008;39:304-311.
- Kaines A, Oliver S, Reddy S, Schwartz SD. Ultrawide angle angiography for the detection and management of diabetic retinopathy. *Int Ophthalmol Clin*. 2009;49:53-59.
- Kaines A, Tsui I, Sarraf D, Schwartz S. The use of ultra wide field fluorescein angiography in evaluation and management of uveitis. *Semin Ophthalmol*. 2009;24:19-24.
- Prasad PS, Oliver SC, Coffee RE, Hubschman JP, Schwartz SD. Ultra wide-field angiographic characteristics of branch retinal and hemicentral retinal vein occlusion. *Ophthalmology*. 2010;117:780-784.
- Reddy S, Hu A, Schwartz SD. Ultra wide field fluorescein angiography guided targeted retinal photocoagulation (TRP). *Semin Ophthalmol*. 2009;24:9-14.
- Tsui I, Kaines A, Havunjian MA, et al. Ischemic index and neovascularization in central retinal vein occlusion. *Retina*. 2011;31:105-110.
- Tsui I, Kaines A, Schwartz S. Patterns of periphlebitis in intermediate uveitis using ultra wide field fluorescein angiography. *Semin Ophthalmol*. 2009;24:29-33.
- Oliver SC, Schwartz SD. Peripheral vessel leakage (PVL): a new angiographic finding in diabetic retinopathy identified with ultra wide-field fluorescein angiography. *Semin Ophthalmol*. 2010;25:27-33.
- Lange C, Feltgen N, Junker B, Schulze-Bonsel K, Bach M. Resolving the clinical acuity categories "hand motion" and "counting fingers" using the Freiburg Visual Acuity Test (FrACT). *Graefes Arch Clin Exp Ophthalmol*. 2009;247:137-142.
- Patel RD, Messner LV, Teitelbaum B, Michel KA, Hariprasad SM. Characterization of ischemic index using ultra-widefield fluorescein angiography in patients with focal and diffuse recalcitrant diabetic macular edema. *Am J Ophthalmol*. 2013;155:1038-1044, e1032.
- Singer M, Tan CS, Bell D, Sadda SR. Area of peripheral retinal nonperfusion and treatment response in branch and central retinal vein occlusion. *Retina*. 2014;34:1736-1742.
- Funatsu H, Yamashita H, Mimura T, Noma H, Nakamura S, Hori S. Risk evaluation of outcome of vitreous surgery based on vitreous levels of cytokines. *Eye (Lond)*. 2007;21:377-382.
- Aiello LP, Avery RL, Arrigg PG, et al. Vascular endothelial growth factor in ocular fluid of patients with diabetic retinopathy and other retinal disorders. *N Engl J Med*. 1994;331:1480-1487.
- Schmidinger G, Maar N, Bolz M, Scholda C, Schmidt-Erfurth U. Repeated intravitreal bevacizumab (Avastin®) treatment of persistent new vessels in proliferative diabetic retinopathy after complete panretinal photocoagulation. *Acta Ophthalmol*. 2011;89:76-81.
- Mason JO III, Colagross CT, Haleman T, et al. Visual outcome and risk factors for light perception and no light perception vision after vitrectomy for diabetic retinopathy. *Am J Ophthalmol*. 2005;140:231-235.
- Tolentino FI, Cajita VN, Gancayco T, Skates S. Vitreous hemorrhage after closed vitrectomy for proliferative diabetic retinopathy. *Ophthalmology*. 1989;96:1495-1500.
- Shi L, Huang YF. Postvitrectomy diabetic vitreous hemorrhage in proliferative diabetic retinopathy. *J Res Med Sci*. 2012;17:865-871.