

# Parallelism for Quantitative Image Analysis of Photoreceptor–Retinal Pigment Epithelium Complex Alterations in Diabetic Macular Edema

Akihito Uji, Tomoaki Murakami, Noriyuki Unoki, Ken Ogino, Takahiro Horii, Shin Yoshitake, Yoko Dodo, and Nagahisa Yoshimura

Department of Ophthalmology and Visual Sciences, Kyoto University Graduate School of Medicine, Kyoto, Japan

Correspondence: Akihito Uji, Department of Ophthalmology and Visual Sciences, Kyoto University Graduate School of Medicine, 54 Shogoin Kawahara-cho, Sakyo-ku, Kyoto 606-8507, Japan; akihito1@kuhp.kyoto-u.ac.jp.

Submitted: January 13, 2014

Accepted: April 27, 2014

Citation: Uji A, Murakami T, Unoki N, et al. Parallelism for quantitative image analysis of photoreceptor–retinal pigment epithelium complex alterations in diabetic macular edema. *Invest Ophthalmol Vis Sci.* 2014;55:3361–3367. DOI:10.1167/iovs.14-13948

**PURPOSE.** To propose a new method to quantitatively and comprehensively evaluate photoreceptor-RPE complex alterations on spectral-domain optical coherence tomography (SD-OCT) imaging in eyes with diabetic macular edema (DME).

**METHODS.** Spectral-domain OCT images from a consecutive series of 90 eyes in 79 patients with DME and 30 healthy eyes in 30 volunteers were analyzed retrospectively. The subfoveal area covering the photoreceptor layers was skeletonized and the orientation of the segmented lines was termed “parallelism,” which reflects image complexity. Photoreceptor layer status at the fovea was categorized by graders, including continuity of the external limiting membrane (ELM) line, inner segment ellipsoid line, and the presence of hyperreflective foci in the outer retinal layers. The relationships among parallelism, visual acuity, and photoreceptor layer status were evaluated.

**RESULTS.** Parallelism was significantly lower in eyes with DME than in normal eyes ( $P < 0.0001$ ), and correlated strongly with visual acuity in eyes with DME ( $R = -0.592$ ;  $P < 0.0001$ ). Eyes with an intact inner segment ellipsoid line or ELM line had significantly better visual acuity (VA) and higher parallelism than eyes with a discontinuous or absent inner segment ellipsoid line or ELM line. Parallelism was significantly higher ( $P < 0.0001$ ) and logMAR VA significantly better ( $P < 0.0001$ ) in the group without hyperreflective foci in the outer retinal layers than in the group with hyperreflective foci in the outer retinal layers.

**CONCLUSIONS.** Parallelism has the potential to reflect structural changes of the photoreceptor layers in DME.

Keywords: diabetic macular edema, optical coherence tomography, image analysis

Diabetic macular edema (DME) is a leading cause of visual dysfunction in patients with diabetes. The number of patients with diabetic retinopathy is expected to increase over the next few decades; therefore, a further revitalization of research and development on efficient and high-quality evaluation techniques for DME needs to be addressed.<sup>1,2</sup>

Along with the popularization of optical coherence tomography (OCT) in recent decades, clinicians have been able to detect thickening of the sensory retina and vascular lesions in DME more easily and objectively compared with examination using biomicroscopy only.<sup>3–5</sup> In particular, OCT has enabled clinicians to objectively measure retinal thickness for assessments of disease severity or therapy evaluations, and a modest correlation between OCT-measured central retinal thickness and visual acuity (VA) has been reported in DME to date.<sup>4–10</sup>

More recently, because of improvements in OCT image quality achieved by developments in both hardware and software, later generations of OCT systems have provided cross-sectional imaging of the retina at a higher resolution, allowing clinicians to analyze smaller structures and the individual retinal layers.<sup>11–14</sup> In particular, the external limiting membrane (ELM), which corresponds to the adherens junctions between the Müller cells and photoreceptor cells,<sup>15</sup> and

the inner segment ellipsoid line<sup>16</sup> on the OCT images reportedly provide important information about pathologies of the photoreceptors.<sup>17–20</sup> Hyperreflective foci in DME, subclinical findings that are invisible during clinical ophthalmoscopic examinations, are related to foveal photoreceptor damage and concomitant visual disturbance.<sup>21–24</sup> A correlation has been established between damage to the foveal photoreceptors and the VA in retinal diseases, including DME, suggesting the clinical relevance of both macular thickening and the photoreceptor damage in DME.<sup>25</sup>

Several methods, including detection of inner segment ellipsoid line and ELM discontinuities or measurement of photoreceptor outer segment (PROS) lengths, have been reported for qualitative or quantitative evaluations of the photoreceptor layer on OCT images by using graders or software.<sup>18–20,26–28</sup> However, alterations of the photoreceptor layer on OCT images of eyes with DME involve not only discontinuities of the inner segment ellipsoid lines and ELM lines, but also transformations of these lines, the presence of hyperreflective foci, and irregular RPE lines; these features are too complicated to evaluate by looking at only one aspect of the alterations.<sup>22,23,29</sup> The development of robust algorithms for comprehensive analyses are eagerly anticipated.

In this study, we proposed a new method to quantitatively and comprehensively evaluate the complexity of photoreceptor-RPE complex alterations by using “parallelism,” which we previously reported as a new, robust, and practical parameter of the structural integrity of retinal layers.<sup>30</sup> This parameter reflects how parallel line objects are to each other on OCT images and can be calculated using line segments generated by simply filtering and thresholding the original image. The increased complexity of photoreceptor-RPE complex images as a result of the above-mentioned alterations in DME has the potential to decrease parallelism. The algorithm for calculating parallelism was tested using OCT scans from healthy subjects and patients with DME, and its clinical relevance was explored.

## METHODS

### Subjects

This was a retrospective, observational, cross-sectional study. All the research and measurements adhered to the tenets of the Declaration of Helsinki and were approved by the institutional review board at Kyoto University Graduate School of Medicine for retrospective review of existing patient data. We retrospectively examined 90 eyes in 79 patients (mean age  $\pm$  SD, 65.3  $\pm$  8.6 years; range, 35–88 years) with DME who visited Kyoto University Hospital from June 2008 through June 2010. The inclusion criterion was the availability of spectral domain OCT (SD-OCT) images of sufficient quality. All patients had undergone comprehensive ophthalmologic examinations, including measurements of best-corrected VA (BCVA), slit-lamp biomicroscopy, color fundus photography, and SD-OCT. The exclusion criteria included the presence of serous retinal detachment, hard exudates at the fovea, significant media opacities (including cataract or vitreous hemorrhage), and other retinal diseases, such as uveitis or vitreomacular traction syndrome. Data for 30 eyes of 30 volunteers (63.0  $\pm$  9.9 years; range, 38–77 years) were retrospectively collected from our database of healthy volunteers as candidate control eyes.

### Optical Coherence Tomography

Spectral-domain OCT (Spectralis; Heidelberg Engineering, Heidelberg, Germany) images were used for analyses of retinal sectional images of the macula. Sixty-one raster scans (30  $\times$  25 degrees) in high-speed mode and 30-degree cross-hair scans in high-resolution mode were used in this study. Raster scans were used for mean foveal thickness measurement (radius, 500  $\mu$ m) using built-in software, and cross-sectional images were used for calculation of parallelism. The presumed foveal center was determined as the area lacking inner retinal layers in the macular region<sup>31</sup> and the pathomorphology within a 1-mm area centered at the presumed fovea was assessed for each eye. We evaluated the status of the ELM line, inner segment ellipsoid line at the fovea, and the presence of hyperreflective foci in the outer retinal layers, as previously described.<sup>22</sup> Eyes in which the inner segment ellipsoid line was detected as a complete line in the fovea were classified as inner segment ellipsoid line(+), and eyes in which the inner segment ellipsoid line was detected as a discontinuous line in the fovea were classified as inner segment ellipsoid line( $\pm$ ); when the inner segment ellipsoid line could not be detected in the fovea, eyes were classified as inner segment ellipsoid line(–). Each eye also was classified based on the status of the ELM line beneath the fovea by using the same criteria described for the inner segment ellipsoid line (i.e., ELM line[+], ELM line[ $\pm$ ], and ELM line[–]). Two experienced examiners (KO, TH) blinded to the clinical

findings categorized the status of the outer retinal layers, including continuity of the inner segment ellipsoid line, continuity of the ELM line, and the presence of hyperreflective foci. In cases of disagreement, the results were discussed until consensus was reached. The kappa coefficient was calculated as a measure of agreement between the observers.

### Calculation of Parallelism

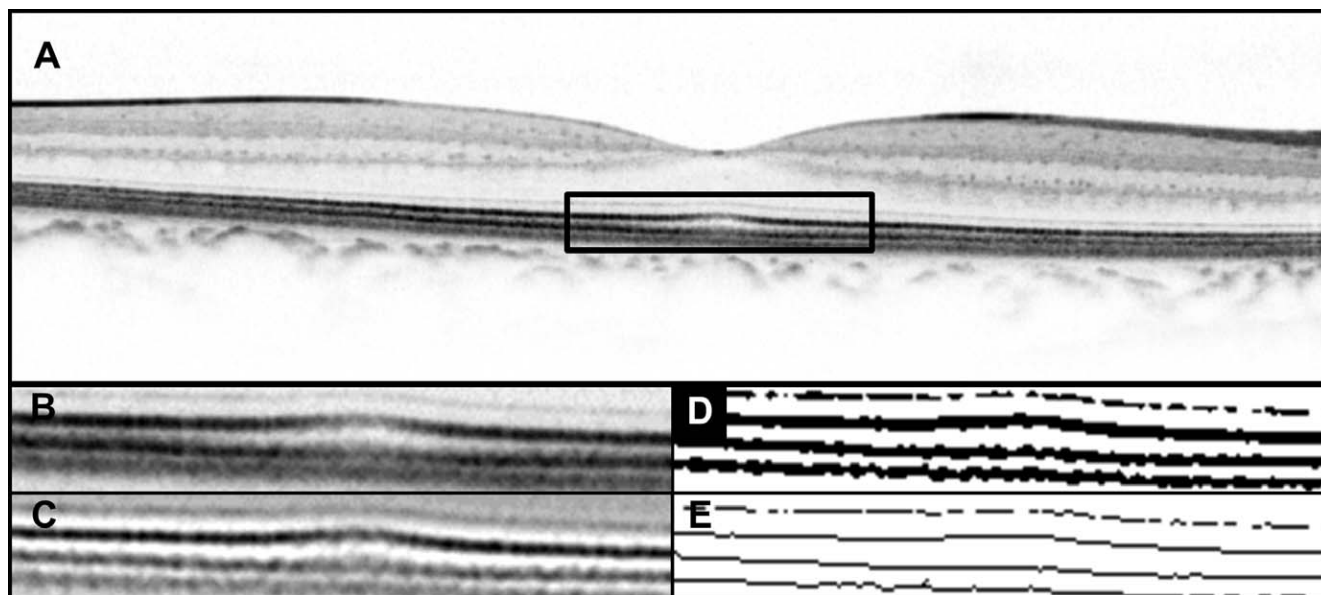
Cross-sectional images at 30 degrees through the fovea were chosen for each eye. To quantitatively evaluate the complexity of photoreceptor-RPE complex alterations, we first cropped a rectangular region of interest (ROI) measuring 1000  $\times$  150  $\mu$ m covering the photoreceptor-RPE complex at the fovea, and extracted skeletonized images (lines) from the OCT images by applying filtration through a 1- to 2-pixel band-pass filter using an ImageJ (<http://imagej.nih.gov/ij/>; provided in the public domain by the National Institutes of Health, Bethesda, MD, USA) software plug-in Kbi\_BandPass (<http://hasezawa.ib.k.u-tokyo.ac.jp/zp/Kbi/ImageJKbiPlugins>) followed by binarization with intensity thresholding using Otsu's thresholding method for automatic binarization-level decisions using the plug-in Kbi\_ThrOtsu (<http://hasezawa.ib.k.u-tokyo.ac.jp/zp/Kbi/ImageJKbiPlugins>) (Fig. 1).<sup>32–34</sup> It is of note that the analysis of parallelism requires only information regarding the orientation of structures in the ROI, which can be obtained using line segments rather than solid lines. The calculation of parallelism from the skeletonized image was fully described in previous articles.<sup>30,32,33</sup> Briefly, in digital images, neighboring pixel pairs can be categorized as 0°, 45°, 90°, and 135° with respect to the horizon. In this study, parallelism was defined as follows:

$$\text{Parallelism} = \frac{|n_0 - n_{90}| + |n_{45} - n_{135}|}{n_0 + n_{45} + n_{90} + n_{135}}, \quad (1)$$

where  $n_0$ ,  $n_{45}$ ,  $n_{90}$ , and  $n_{135}$  are the numbers of pixel pairs at 0°, 45°, 90°, and 135°, respectively. Parallelism can range from 0 to 1, and images with more parallel line segments have higher parallelism. The mean parallelism values from a horizontal scan and vertical scan were calculated for each eye and used for the analyses. All digital images were processed by a single operator (AU) using ImageJ and a software plug-in.

### Statistical Analysis

All values are expressed as mean  $\pm$  SD. All BCVA measurements were converted to logMAR equivalents before statistical analysis. Comparisons between healthy subjects and DME patients with regard to age, logMAR VA, parallelism, and retinal thickness were performed using Student's *t*-tests. Comparisons of the logMAR VA values and parallelism of the three groups classified based on the status of the inner segment ellipsoid line or ELM line were carried out using a one-way ANOVA, with post hoc comparisons tested by the Scheffé procedure. Comparisons of the logMAR VA values and parallelism between the two hyperreflective foci groups (foci absent in the outer retinal layers group versus foci present in the outer retinal layers group) were carried out using Student's *t*-tests. The relationships between logMAR VA and parallelism, logMAR VA and foveal thickness, and parallelism and foveal thickness were analyzed using Pearson's correlation coefficient. A *P* value less than 0.05 was considered statistically significant. All analyses, except for the kappa coefficient assessments, were performed using StatView (version 5.0; SAS Institute, Cary, NC, USA). Calculation of the kappa coefficient was performed using SPSS (version 17; SPSS Inc., Chicago, IL, USA).



**FIGURE 1.** Calculation of parallelism through skeletonizing OCT images of the photoreceptor-RPE complex in a healthy subject. Images are of the right eye of a 74-year-old woman from our database of healthy volunteers. (A) A horizontal line scan from an SD-OCT image. (B) A magnified view of the area outlined in black in (A). (C) A filtered image of (B) after the application of a band-pass filter for noise reduction and enhancement of the line segments. (D) A binarized image of (C) after using Otsu's thresholding method for automatic binarization level decisions. (E) A skeletonized image generated from (D). Each line segment represents the orientation of the striped pattern of the photoreceptor-RPE complex. Line segments are depicted as parallel lines, and the parallelism calculated for this area was 0.937.

## RESULTS

### Assessment of Interobserver Agreement

The kappa coefficient was 0.704 ( $P < 0.001$ ) for the ELM line, 0.809 ( $P < 0.001$ ) for the inner segment ellipsoid line, and 0.756 ( $P < 0.001$ ) for the presence of hyperreflective foci. The results indicated good interobserver agreement.

### Differences in Parallelism Between Healthy Subjects and Patients With DME

Skeletonized OCT images in cases of DME with disrupted ELM or inner segment ellipsoid lines and hyperreflective foci in the outer retinal layers showed many line segments in random orientations in the ROI, which have the potential to decrease the parallelism of the images (Fig. 2). Meanwhile, in healthy subjects and cases of DME with less disrupted photoreceptor layers and without hyperreflective foci in the outer retinal layers, line segments were observed as parallel lines (Figs. 1 and 3). Parallelism was significantly ( $P < 0.0001$ ) lower and logMAR VA was significantly ( $P < 0.0001$ ) worse in eyes with DME than in normal eyes (Table 1). Retinal thicknesses were significantly higher in eyes with DME than in normal eyes ( $P < 0.0001$ ).

### Association Between Parallelism and Photoreceptor Status

We further investigated how photoreceptor status in DME contributed to parallelism values. There were significant differences among the three inner segment ellipsoid line groups in parallelism ( $P < 0.0001$ ) and logMAR VA ( $P < 0.0001$ ) (Table 2). In the inner segment ellipsoid line(+) group, parallelism was significantly higher and logMAR VA was significantly better than those in either the inner segment ellipsoid line( $\pm$ ) ( $P = 0.0077$  and  $P = 0.0198$ ) or inner segment ellipsoid line(-) groups ( $P < 0.0001$  for both comparisons).

There also were significant differences among the three ELM line groups in parallelism ( $P < 0.0001$ ) and logMAR VA ( $P < 0.0001$ ). In the ELM line(+) group, parallelism was significantly higher and logMAR VA was significantly better than those in either the ELM line( $\pm$ ) ( $P < 0.0001$  and  $P = 0.0004$ ) or ELM line(-) groups ( $P < 0.0001$  for both comparisons). Parallelism was significantly higher ( $P < 0.0001$ ) and logMAR VA was significantly better in the group without hyperreflective foci in the outer retinal layers than in the group with hyperreflective foci in the outer retinal layers.

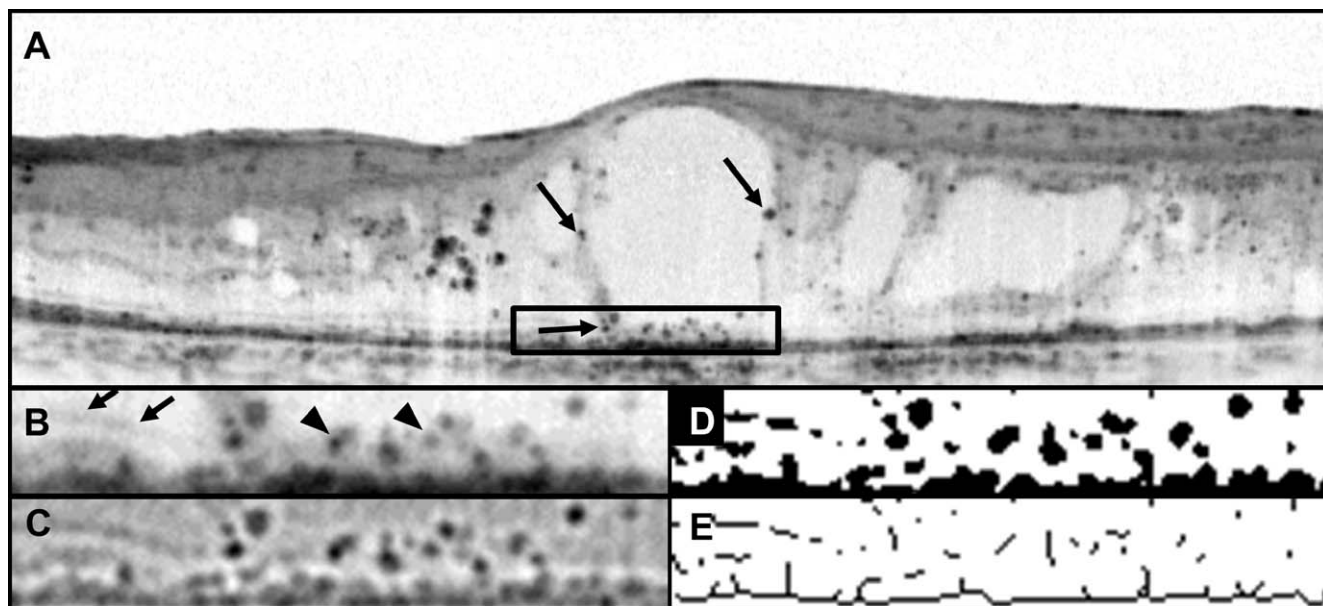
### Correlation Among VA, Parallelism, and Foveal Thickness in Patients With DME

Parallelism correlated well with logMAR VA ( $R = -0.592$ ;  $P < 0.0001$ ) (Fig. 4). Moreover, foveal thickness correlated significantly with logMAR VA ( $R = 0.381$ ;  $P = 0.0002$ ). Significant negative correlations were observed between parallelism and foveal thickness ( $R = -0.316$ ;  $P = 0.0316$ ).

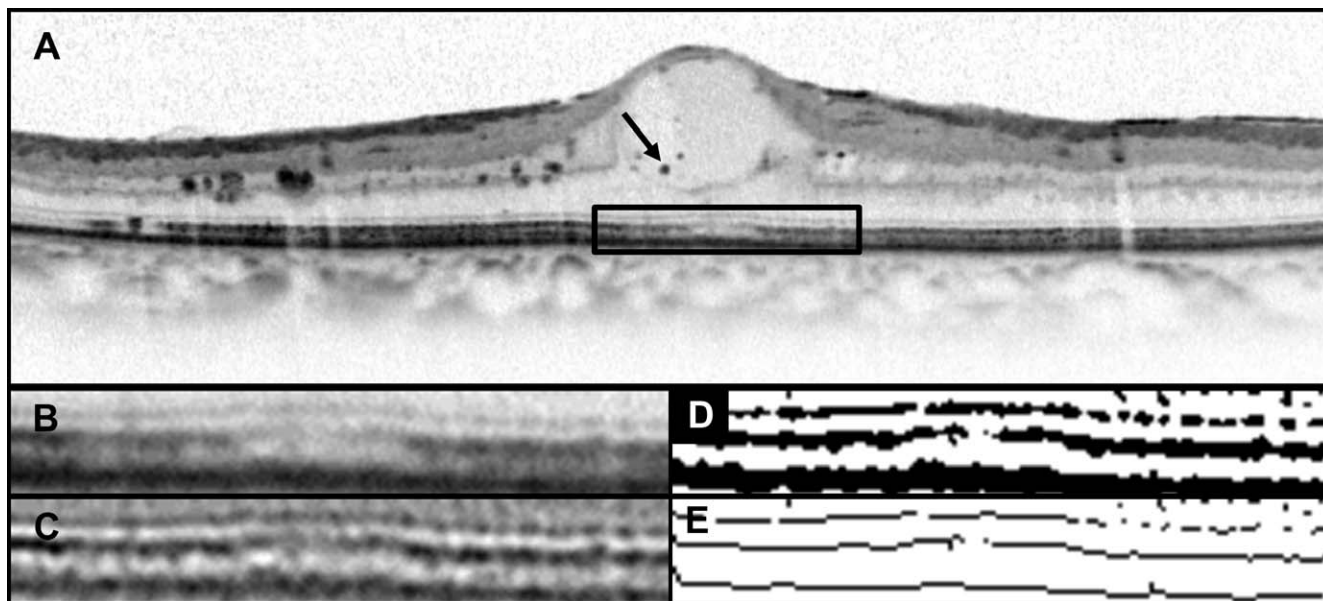
## DISCUSSION

This study is based on a methodology according to which photoreceptor-RPE complex alterations in DME are comprehensively quantifiable by interpreting the alterations as changes in image complexity. Parallelism, a parameter reflecting the orientations of lines in the image, was applied as a parameter representing the complexity of photoreceptor-RPE complex alterations, and the results demonstrated that parallelism was clinically relevant in eyes with DME. To the best of our knowledge, this is the first study that used parallelism as a surrogate marker for photoreceptor-RPE complex alterations in OCT image analysis.

Significant differences between normal eyes and eyes with DME and significant correlations with VA were detected with the use of parallelism. Moreover, eyes with an intact inner segment ellipsoid line or ELM line had significantly higher



**FIGURE 2.** Calculation of parallelism through skeletonizing OCT images of the photoreceptor-RPE complex of a DME patient with hyperreflective foci in the outer retinal layers. Images are of the left eye of a 65-year-old man with DME. The Snellen equivalent BCVA was 20/50 in this eye. (A) A horizontal line scan of the SD-OCT image through the fovea shows cystoid macular edema and hyperreflective foci (*arrows*) in both the inner and outer retinal layers. The foveal thickness was 642  $\mu\text{m}$ . (B) A magnified view of the area *outlined in black* in (A). The ELM line and inner segment ellipsoid line were disrupted and categorized as ELM line( $\pm$ ) and inner segment ellipsoid line( $\pm$ ), respectively. The ELM line sank and deformed toward the RPE (*arrow*). Hyperreflective foci (*arrowheads*) are observed in the area where the ELM line and inner segment ellipsoid line are absent, and some were deposited on the RPE. (C) A filtered image of (B) after the application of a band-pass filter for noise reduction and enhancement of the line segments. (D) A binarized image of (C) after using Otsu's thresholding method for automatic binarization level decisions. (E) A skeletonized image generated from (D). Line segments were observed in random orientations, which contributed to decreased parallelism. The parallelism value calculated for this area was 0.492.



**FIGURE 3.** Calculation of parallelism through skeletonizing OCT images of the photoreceptor-RPE complex of a DME patient without hyperreflective foci in the outer retinal layers. Images are of the left eye of a 74-year-old man with DME. The Snellen equivalent BCVA was 20/25 in this eye. (A) A horizontal line scan of the SD-OCT image through the fovea shows cystoid macular edema and hyperreflective foci (*arrows*) in the inner retinal layers, but not in the outer retinal layers. The foveal thickness was 440  $\mu\text{m}$ . (B) A magnified view of the area *outlined in black* in (A). The inner segment ellipsoid line was disrupted and categorized as ELM line(+) and inner segment ellipsoid line( $\pm$ ). Neither ELM line deformation nor hyperreflective foci are observed in the image. (C) The filtered image from (B) after the application of a band-pass filter for noise reduction and enhancement of the line segments. (D) A binarized image of (C) after using Otsu's thresholding method for automatic binarization level decisions. (E) A skeletonized image generated from (D). Line segments are depicted as almost parallel lines, and the parallelism calculated for this area was 0.689.

**TABLE 1.** Differences in Parallelism Between Healthy Subjects and Patients With DME in OCT Images

Characteristic	Normal Eyes	Eyes With DME	P Value
No. eyes/patients	30/30	90/79	—
Men/women	16/14	49/41	—
Age, y	63.0 ± 9.9	65.3 ± 8.6	0.2140
VA, logMAR	−0.153 ± 0.002	0.360 ± 0.104	<0.0001
Parallelism	0.745 ± 0.082	0.572 ± 0.151	<0.0001
Retinal thickness	259 ± 17	474 ± 117	<0.0001

parallelism than eyes with either an interrupted or absent inner segment ellipsoid line or ELM line. These results suggest that parallelism reflects assessments of inner segment ellipsoid line or ELM line continuity by graders. Meanwhile, the results also imply that inner segment ellipsoid line and ELM line continuity may be closely related to other components that decrease the image complexity of the photoreceptor-RPE complex, given that parallel discontinuous lines in the image cannot contribute to a decrease in parallelism per se. Parallelism has the potential to reflect structural changes in the photoreceptor-RPE complex, which include discontinuity of inner segment ellipsoid line or ELM line, among other changes.

One of the possible candidates that can decrease parallelism and show a relationship with photoreceptor layer discontinuity is the presence of hyperreflective foci in the outer retinal layers. As we previously reported, hyperreflective foci in the outer retinal layers, subclinical findings that are invisible during clinical ophthalmoscopic examinations, have been reported to have a pathological association with disrupted inner segment ellipsoid lines or ELM lines in SD-OCT images of eyes with DME.<sup>22</sup> In fact, in the current study, we identified a significant difference in parallelism between the groups with and without hyperreflective foci in the outer retinal layers. In eyes with hyperreflective foci in the outer retinal layers, the hyperreflective foci themselves and their deposits on the RPE line can contribute to irregular and bumpy RPE lines, and are considered to be skeletonized through image processing as random lines at angles to the inner segment ellipsoid lines or ELM lines.

Deformation of the ELM line, which can be often seen in DME, is another candidate that can decrease parallelism in eyes with DME. In cases with disrupted ELM lines, the ELM lines sometimes sank and merged with the RPE, as previously reported.<sup>22</sup> Because the ELM corresponds to the adherens junctions between the Müller cells and photoreceptor cells and acts as a barrier against macromolecules,<sup>15</sup> these deformations may represent cellular damage and can occur in association with ELM line discontinuity. Meanwhile, parallelism in cases with disrupted ELM or inner segment ellipsoid lines without any line deformation or hyperreflective foci may not be low values, as shown in Figure 3. However, considering the good

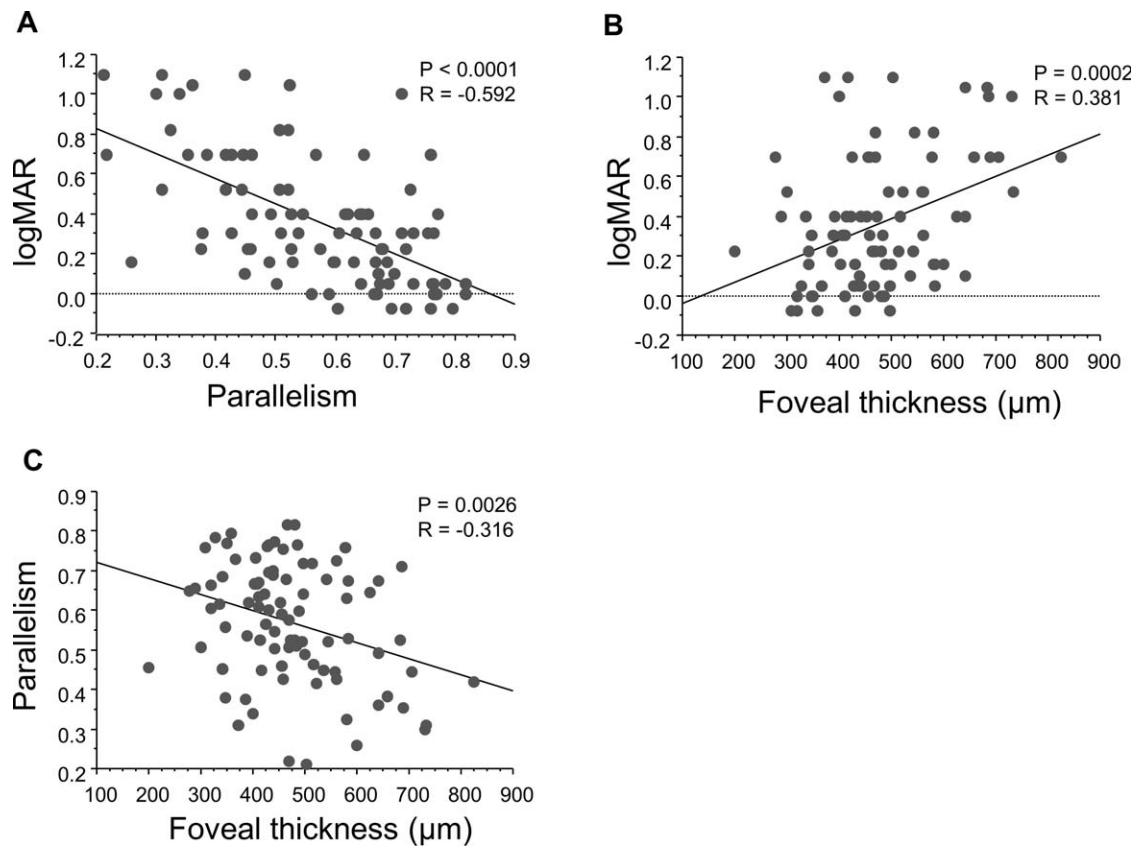
association between grader-based evaluations of photoreceptor layer continuity and parallelism, increases in image complexity resulting from the above-mentioned presence of hyperreflective foci or ELM line deformation other than inner segment ellipsoid line or ELM line discontinuity may have the potential to be a comprehensive and useful sign that reflects damage to the outer retinal layers, at least in eyes with DME.

A number of studies have reported quantitative or automatic evaluations of the photoreceptor layer on OCT images using software. Ooto and colleagues<sup>26,28</sup> described a method to define inner segment ellipsoid line disruption on SD-OCT (Spectralis) images as decreased reflectivity of the inner segment ellipsoid line in the fovea, and showed a significant association with the findings acquired by using adaptive optics scanning laser ophthalmoscopy in eyes with a healed macular hole. Wanek et al.<sup>7</sup> reported a method for automatic en face imaging of inner segment ellipsoid line by SD-OCT (Spectralis) and described findings in patients with various retinal diseases, including DME. Collectively, these studies demonstrate intensity-based inner segment ellipsoid line detection methods and show their clinical relevance. Although these methods are designed for good performance in the selective abstraction of inner segment ellipsoid line, they may not reflect information about photoreceptor-RPE complex alterations, other than discontinuity of the inner segment ellipsoid line, which we are focusing on.

Other groups showed the usefulness of PROS measurements. Forooghian et al.<sup>19</sup> used Cirrus HD-OCT (Carl Zeiss Meditec, Inc., Dublin, CA, USA) and reported a significant relationship between PROS thickness automatically measured using their prototype software and visual acuity in DME. Alasil et al.<sup>18</sup> used a Stratus OCT machine (Carl Zeiss Meditec, Inc.) and manually measured PROS thickness using custom software entitled "OCTOR," which allows for the precise positioning of prespecified boundaries on individual B-scans, and found a correlation with visual acuity. Although these studies show the clinical relevance of PROS measurements in DME, we speculate that PROS measurements also can reflect photoreceptor-RPE complex alterations other than discontinuity of the inner segment ellipsoid lines or ELM lines, such as hyperreflective foci in the outer retinal layers or bumpy RPE lines, as

**TABLE 2.** Association Between Photoreceptor Status and Parallelism of Photoreceptor-RPE Complex in OCT Images

	Parallelism	P Value	VA, logMAR	P Value
Inner segment ellipsoid line(+), <i>n</i> = 13	0.715 ± 0.078		0.073 ± 0.144	
Inner segment ellipsoid line(±), <i>n</i> = 55	0.598 ± 0.125		0.300 ± 0.234	
Inner segment ellipsoid line(−), <i>n</i> = 22	0.422 ± 0.119	<0.0001	0.680 ± 0.347	<0.0001
ELM line(+), <i>n</i> = 35	0.679 ± 0.100		0.176 ± 0.220	
ELM line(±), <i>n</i> = 48	0.520 ± 0.136		0.421 ± 0.298	
ELM line(−), <i>n</i> = 7	0.396 ± 0.102	<0.0001	0.862 ± 0.236	<0.0001
Hyperreflective foci in outer retinal layers				
Absent, <i>n</i> = 49	0.644 ± 0.131		0.206 ± 0.228	
Present, <i>n</i> = 41	0.486 ± 0.126	<0.0001	0.543 ± 0.325	<0.0001



**FIGURE 4.** Correlations among VA, parallelism, and foveal thickness in patients with DME. (A) A significant negative correlation was shown between parallelism and logMAR VA ( $R = -0.592$ ;  $P < 0.0001$ ). (B) Foveal thickness demonstrated a modest correlation with logMAR VA ( $R = 0.381$ ;  $P = 0.0002$ ). (C) Significant negative correlations were found between parallelism and foveal thickness ( $R = -0.316$ ;  $P = 0.0316$ ).

is the case with parallelism, because PROS measurements have the potential to measure the deformation of lines as increased and decreased thicknesses. However, thickness measurements of small objects on OCT images require careful attention, in that the measurements may contain potential inaccuracies. Parallelism, which is based on a simple filtering process, is faithful to the original image and avoids problems associated with segmentation failure and picture interpolation to create solid segmentation lines.

Retinal thickness is a well-accepted parameter related to visual impairment in DME. In this study, parallelism showed a significant negative correlation with retinal thickness. This result supports the finding previously reported by Murakami et al.,<sup>35</sup> in which several relationships between the characteristics of the cystoid spaces and the photoreceptor changes beneath them were shown in DME for the first time. Parallelism, along with retinal thickness that can be calculated automatically with fewer segmentation errors, has the potential to shed light on the mechanism of photoreceptor changes in DME in future studies.

Our study has the following limitations: (1) We evaluated only horizontal and vertical scans for each subject without using the 3-dimensional scanning mode for full delineation. (2) This study was cross-sectional and retrospective in nature. Another longitudinal study should be planned in the future. (3) Parallelism is solely a marker for complexity. Considering that shape and size of the objects in the image depend on a degree of filtering, multiple objects can be extracted to produce a single fused object. Although the preprocessing methods were performed for all OCT images uniformly and the outcome of the current study was not considered to be biased, further

improvement of the filtering process to bring computer recognition closer to human recognition is warranted.

In conclusion, parallelism is proposed as a new practical parameter for the complexity of photoreceptor-RPE complex alterations in DME. Parallelism was significantly lower in eyes with DME than in normal eyes, and correlated strongly with VA in eyes with DME. This parameter has the potential to reflect structural changes in photoreceptor layers, which include not only discontinuity of inner segment ellipsoid lines or ELM lines, but also other changes, such as the presence of hyperreflective foci.

#### Acknowledgments

Disclosure: **A. Uji**, None; **T. Murakami**, None; **N. Unoki**, None; **K. Ogino**, None; **T. Horii**, None; **S. Yoshitake**, None; **Y. Dodo**, None; **N. Yoshimura**, None

#### References

1. Saaddine JB, Honeycutt AA, Narayan KM, Zhang X, Klein R, Boyle JP. Projection of diabetic retinopathy and other major eye diseases among people with diabetes mellitus: United States, 2005-2050. *Arch Ophthalmol*. 2008;126:1740-1747.
2. Klein R, Klein BE, Moss SE, Cruickshanks KJ. The Wisconsin Epidemiologic Study of Diabetic Retinopathy. XV. The long-term incidence of macular edema. *Ophthalmology*. 1995;102:7-16.
3. Otani T, Kishi S. Tomographic findings of foveal hard exudates in diabetic macular edema. *Am J Ophthalmol*. 2001;131:50-54.

4. Hee MR, Puliafito CA, Wong C, et al. Quantitative assessment of macular edema with optical coherence tomography. *Arch Ophthalmol*. 1995;113:1019-1029.
5. Browning DJ, Glassman AR, Aiello LP, et al. Relationship between optical coherence tomography-measured central retinal thickness and visual acuity in diabetic macular edema. *Ophthalmology*. 2007;114:525-536.
6. Bandello F, Polito A, Del Borrello M, Zemella N, Isola M. "Light" versus "classic" laser treatment for clinically significant diabetic macular oedema. *Br J Ophthalmol*. 2005;89:864-870.
7. Martidis A, Duker JS, Greenberg PB, et al. Intravitreal triamcinolone for refractory diabetic macular edema. *Ophthalmology*. 2002;109:920-927.
8. Laursen ML, Moeller F, Sander B, Sjoelie AK. Subthreshold micropulse diode laser treatment in diabetic macular oedema. *Br J Ophthalmol*. 2004;88:1173-1179.
9. Ozdemir H, Karacorlu M, Karacorlu SA. Regression of serous macular detachment after intravitreal triamcinolone acetate in patients with diabetic macular edema. *Am J Ophthalmol*. 2005;140:251-255.
10. Massin P, Duguid G, Erginay A, Haouchine B, Gaudric A. Optical coherence tomography for evaluating diabetic macular edema before and after vitrectomy. *Am J Ophthalmol*. 2003;135:169-177.
11. Kiernan DF, Mieler WF, Hariprasad SM. Spectral-domain optical coherence tomography: a comparison of modern high-resolution retinal imaging systems. *Am J Ophthalmol*. 2010;149:18-31.
12. Sakamoto A, Hangai M, Yoshimura N. Spectral-domain optical coherence tomography with multiple B-scan averaging for enhanced imaging of retinal diseases. *Ophthalmology*. 2008;115:1071-1078.e7.
13. Fleckenstein M, Charbel Issa P, Helb HM, et al. High-resolution spectral domain-OCT imaging in geographic atrophy associated with age-related macular degeneration. *Invest Ophthalmol Vis Sci*. 2008;49:4137-4144.
14. Murakami T, Nishijima K, Akagi T, et al. Segmentational analysis of retinal thickness after vitrectomy in diabetic macular edema. *Invest Ophthalmol Vis Sci*. 2012;53:6668-6674.
15. Marmor MF. Mechanisms of fluid accumulation in retinal edema. *Doc Ophthalmol*. 1999;97:239-249.
16. Spaide RF. Questioning optical coherence tomography. *Ophthalmology*. 2012;119:2203-2204.e1.
17. Sakamoto A, Nishijima K, Kita M, Oh H, Tsujikawa A, Yoshimura N. Association between foveal photoreceptor status and visual acuity after resolution of diabetic macular edema by pars plana vitrectomy. *Graefes Arch Clin Exp Ophthalmol*. 2009;47:1325-1330.
18. Alasil T, Keane PA, Updike JF, et al. Relationship between optical coherence tomography retinal parameters and visual acuity in diabetic macular edema. *Ophthalmology*. 2010;117:2379-2386.
19. Forooghian F, Stetson PF, Meyer SA, et al. Relationship between photoreceptor outer segment length and visual acuity in diabetic macular edema. *Retina*. 2010;30:63-70.
20. Maheshwary AS, Oster SF, Yuson RM, Cheng L, Mojana F, Freeman WR. The association between percent disruption of the photoreceptor inner segment-outer segment junction and visual acuity in diabetic macular edema. *Am J Ophthalmol*. 2010;150:63-67.e1.
21. Bolz M, Schmidt-Erfurth U, Deak G, Mylonas G, Kriechbaum K, Scholda C. Optical coherence tomographic hyperreflective foci: a morphologic sign of lipid extravasation in diabetic macular edema. *Ophthalmology*. 2009;116:914-920.
22. Uji A, Murakami T, Nishijima K, et al. Association between hyperreflective foci in the outer retina, status of photoreceptor layer, and visual acuity in diabetic macular edema. *Am J Ophthalmol*. 2012;153:710-717, 717.e1.
23. Nishijima K, Murakami T, Hirashima T, et al. Hyperreflective foci in outer retina predictive of photoreceptor damage and poor vision after vitrectomy for diabetic macular edema. *Retina*. 2014;34:732-740.
24. Ota M, Nishijima K, Sakamoto A, et al. Optical coherence tomographic evaluation of foveal hard exudates in patients with diabetic maculopathy accompanying macular detachment. *Ophthalmology*. 2010;117:1996-2002.
25. Murakami T, Nishijima K, Sakamoto A, Ota M, Horii T, Yoshimura N. Association of pathomorphology, photoreceptor status, and retinal thickness with visual acuity in diabetic retinopathy. *Am J Ophthalmol*. 2011;151:310-317.
26. Yokota S, Ooto S, Hangai M, et al. Objective assessment of foveal cone loss ratio in surgically closed macular holes using adaptive optics scanning laser ophthalmoscopy. *PLoS One*. 2013;8:e63786.
27. Wanek J, Zelkha R, Lim JI, Shahidi M. Feasibility of a method for en face imaging of photoreceptor cell integrity. *Am J Ophthalmol*. 2011;152:807-814. e1.
28. Ooto S, Hangai M, Takayama K, Ueda-Arakawa N, Hanebuchi M, Yoshimura N. Photoreceptor damage and foveal sensitivity in surgically closed macular holes: an adaptive optics scanning laser ophthalmoscopy study. *Am J Ophthalmol*. 2012;154:174-186.e2.
29. Murakami T, Yoshimura N. Structural changes in individual retinal layers in diabetic macular edema. *J Diabetes Res*. 2013;2013:920713.
30. Uji A, Murakami T, Unoki N, et al. Parallelism as a novel marker for structural integrity of retinal layers in optical coherence tomographic images in eyes with epiretinal membrane. *Am J Ophthalmol*. 2014;157:227-236.e4.
31. Murakami T, Nishijima K, Sakamoto A, Ota M, Horii T, Yoshimura N. Foveal cystoid spaces are associated with enlarged foveal avascular zone and microaneurysms in diabetic macular edema. *Ophthalmology*. 2011;118:359-367.
32. Yoneda A, Higaki T, Kutsuna N, et al. Chemical genetic screening identifies a novel inhibitor of parallel alignment of cortical microtubules and cellulose microfibrils. *Plant Cell Physiol*. 2007;48:1393-1403.
33. Ueda H, Yokota E, Kutsuna N, et al. Myosin-dependent endoplasmic reticulum motility and F-actin organization in plant cells. *Proc Natl Acad Sci U S A*. 2010;107:6894-6899.
34. Otsu N. A threshold selection method from gray-level histograms. *IEEE Trans Syst Man Cybern*. 1979;9:62-66.
35. Murakami T, Nishijima K, Akagi T, et al. Optical coherence tomographic reflectivity of photoreceptors beneath cystoid spaces in diabetic macular edema. *Invest Ophthalmol Vis Sci*. 2012;53:1506-1511.