

Mild Decentration Measured by a Scheimpflug Camera and Its Impact on Visual Quality Following SMILE in the Early Learning Curve

Meiyan Li,¹ Jing Zhao,¹ Huamao Miao,¹ Yang Shen,¹ Ling Sun,¹ Mi Tian,¹ Elizabeth Wadium,² and Xingtao Zhou¹

¹Key Lab of Myopia, Ministry of Health, Department of Ophthalmology, EYE & ENT Hospital of Fudan University, Shanghai, China

²Department of Surgery, Division of Otolaryngology – Head and Neck Surgery, University of Wisconsin School of Medicine and Public Health, Madison, Wisconsin, United States

Correspondence: Xingtao Zhou, 19 Baoqing Road, Shanghai, China 200031; doctzhouxingtao@163.com.

Submitted: December 5, 2013

Accepted: May 5, 2014

Citation: Li M, Zhao J, Miao H, et al. Mild decentration measured by a Scheimpflug camera and its impact on visual quality following SMILE in the early learning curve. *Invest Ophthalmol Vis Sci.* 2014;55:3886–3892. DOI:10.1167/iovs.13-13714

PURPOSE. To measure decentration following femtosecond laser small incision lenticule extraction (SMILE) for the correction of myopia and myopic astigmatism in the early learning curve, and to investigate its impact on visual quality.

METHODS. A total of 55 consecutive patients (100 eyes) who underwent the SMILE procedure were included. Decentration was measured using a Scheimpflug camera 6 months after surgery. Uncorrected and corrected distance visual acuity (UDVA, CDVA), manifest refraction, and wavefront errors were also measured. Associations between decentration and the preoperative spherical equivalent were analyzed, as well as the associations between decentration and wavefront aberrations.

RESULTS. Regarding efficacy and safety, 40 eyes (40%) had an unchanged CDVA; 32 eyes (32%) gained one line; and 11 eyes (11%) gained two lines. Fifteen eyes (15%) lost one line of CDVA, and two eyes (2%) lost two lines. Ninety-nine of the treated eyes (99%) had a postoperative UDVA better than 1.0, and 100 eyes (100%) had a UDVA better than 0.8. The mean decentered displacement was 0.17 ± 0.09 mm. The decentered displacement of all treated eyes (100%) was within 0.50 mm; 70 eyes (70%) were within 0.20 mm; and 90 eyes (90%) were within 0.30 mm. The vertical coma showed the greatest increase in magnitude. The magnitude of horizontal decentration was found to be associated with an induced horizontal coma.

CONCLUSIONS. This study suggests that, although mild decentration occurred in the early learning curve, good visual outcomes were achieved after the SMILE surgery. Special efforts to minimize induced vertical coma are necessary.

Keywords: refractive surgery, corneal topography, decentration

Accurate centration in corneal refractive surgeries helps to maximize visual outcomes and is believed to be of great importance. Decentered treatment may result in undesirable side effects, such as, halos, glare, monocular diplopia, and a reduction in visual acuity.¹ Although the active eye tracker has been introduced to reduce the incidence of decentered treatment, decentration still occurs.

Small incision lenticule extraction (SMILE) is a relatively new technique for the correction of myopia and myopic astigmatism that was first reported by Shah et al.² and Sekundo et al.³ in 2011. Recent evidence suggests that this procedure provides excellent clinical outcomes, considering its safety, efficacy, predictability, and postoperative ocular surface health following treatment.^{2–6} One potential limitation of this technique is that no active eye tracker is used during the procedure, which may increase the risk of decentration, and visual outcomes may be subject to a surgeon's operative experience.

Herein, we conducted a prospective study to determine the distribution of lenticule decentration following SMILE, and to investigate the relationship between decentration, wavefront aberrations, and preoperative spherical equivalents.

PATIENTS AND METHODS

Patients

Fifty-five consecutive patients (100 eyes) receiving SMILE procedures for the correction of myopia were recruited for the study between June 2010 and June 2012 at the Department of Ophthalmology of Fudan University Eye and ENT Hospital (Shanghai, People's Republic of China).

All recruited subjects read and signed an information and consent form before participating in the study. The Ethical Committee of the Fudan University EENT Hospital Review Board approved the study protocol. All subjects were treated in accordance with the tenets of the Declaration of Helsinki.

Surgical Techniques

The femtosecond laser system (VisuMax; Carl Zeiss Meditec AG, Jena, Germany) was used to perform refractive surgical procedures. The surgical technique used was based on the one described by Sekundo et al.³ After a standard sterile draping and insertion of the eye speculum, the patient's eye

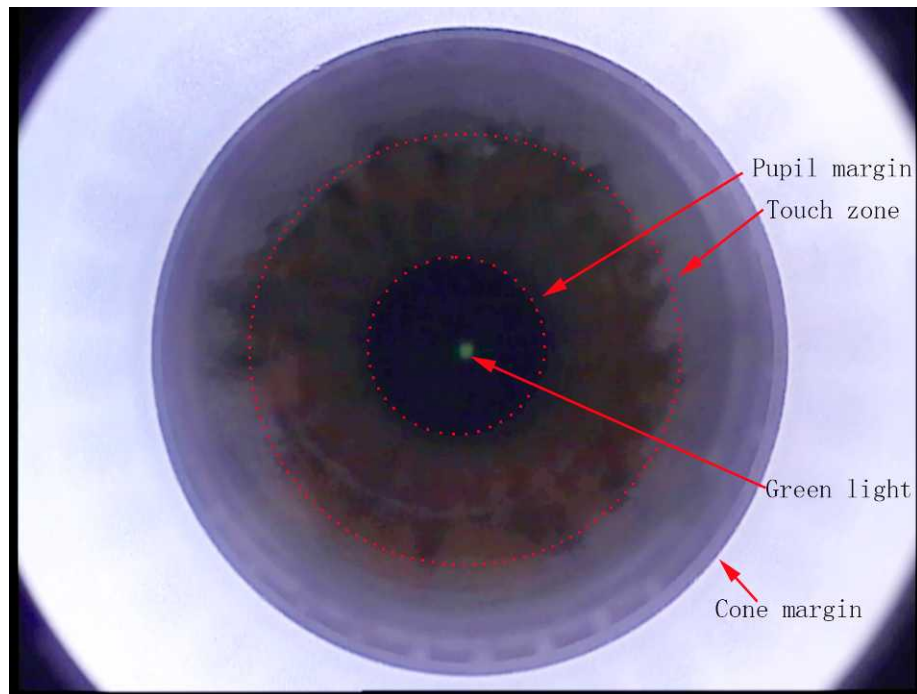


FIGURE 1. Diagram showing what can be seen in the microscope of the femtosecond laser system (Carl Zeiss Meditec AG) during the centration procedure in SMILE. The touch zone is a circular area produced by the contact of the cone on the cornea. Dashed circles have been added to clearly define the regions. Additionally, contrast and brightness have been adjusted.

was positioned under an illuminated and curved suction cone. Patients were asked to fixate on the internal target light, which was mounted coaxial with the femtosecond laser beam. The following centration method was used: the patient was told to keep their focus on the blinking green light. The surgeon observed the eye through the microscope and controlled the movement with a joystick. As the patient-bed moved slowly up, with the cornea approaching the cone, the surgeon carefully observed both the pupil and the “touch zone” produced by the contact between the cornea and the cone. The centration was accepted by the surgeon when the ring of the “touch zone” was concentric with the margin of the suction cone (Fig. 1). The patient was told to continue focusing on the blinking target light, even as suction was applied. The repetition rate was set to 500 kHz, with a pulse energy of 130 nJ. The thickness of the cap (similar to the flap created in a femtosecond LASIK treatment) was intended to be 100 μm . The diameter of the cap was 7.5 mm, 1 mm larger than the diameter of the refractive lenticule (6.5 mm). Side cuts made for access to the lenticule were set 90° apart at a circumferential width of 2.0 to 4.5 mm. The femtosecond laser system (Carl Zeiss Meditec AG) produced ultra-short pulses of light, which created photodisruption at its focal point, resulting in a rapidly expanding cloud of free electrons and ionized molecule plasma. A series of small gas bubbles were formed from the corneal tissue vaporization, resulting in cleavage of tissue planes. The main tissue planes were created in the following sequence: the posterior surface of the refractive lenticule, then the anterior surface of the refractive lenticule, followed by a single side-cut incision. After suction was released, the patient was moved into a position of observation under the femtosecond laser (Carl Zeiss Meditec AG) surgical microscope. The refractive lenticule was dissected through the side-cut opening incision and was removed manually using micro-forceps. All of the surgical procedures were performed by the same surgeon (XZ).

Measurement of Decentration

At month 6, the postoperative topographic maps were analyzed to determine the distance and phase of the treatment center from the corneal vertex. The corneal topography used was acquired with a Scheimpflug camera (Pentacam; Oculus, Wetzlar, Germany). The patient was asked to open both eyes and to stare at a target. The automatic release mode was used to reduce operator-dependent variables, with 25 single images captured for each eye within 2 seconds. All of the Scheimpflug scans were performed by a single, experienced operator. Measurement quality was checked in the quality specification (QS) window. Only the measurements showing “QS” = OK were acceptable. If the comment of “QS” was marked yellow or red, indicating uncertain measurements, the examination was repeated.⁷

The postoperative elevation (front) map in the one-map view was used to analyze the centers of the optical zone (Fig. 2). The postoperative reference best-fit sphere (BFS) radius was set to have the same value as its preoperative counterpart. Then, a circle-like or an oval-like area and a protrusion of the anterior surface were indicated by negative numbers and considered the optical zone. The topographic graph displayed the (0, 0) point as the corneal vertex (approximate fixation point), a black cross at the pupil center, and a coordinate (x , y) in millimeters for any point relative to the (0, 0) point where the cursor is moved. The same observer (ML) performed all measurements to ensure consistency. As there was no standardized method to determine centers of optical zone, the centration strategy used in the present study was as follows: the observer placed a transparency with multiple concentric circles on top of the elevation (front) map and situated the cursor in the center of the concentric circles (x_1 , y_1 ; Fig. 2). A new coordinate (x_2 , y_2) was generated by subtracting the pupil center coordinate (x_0 , y_0) from (x_1 , y_1). Finally, we obtained a new coordinate (x_3 , y_3), as follows:

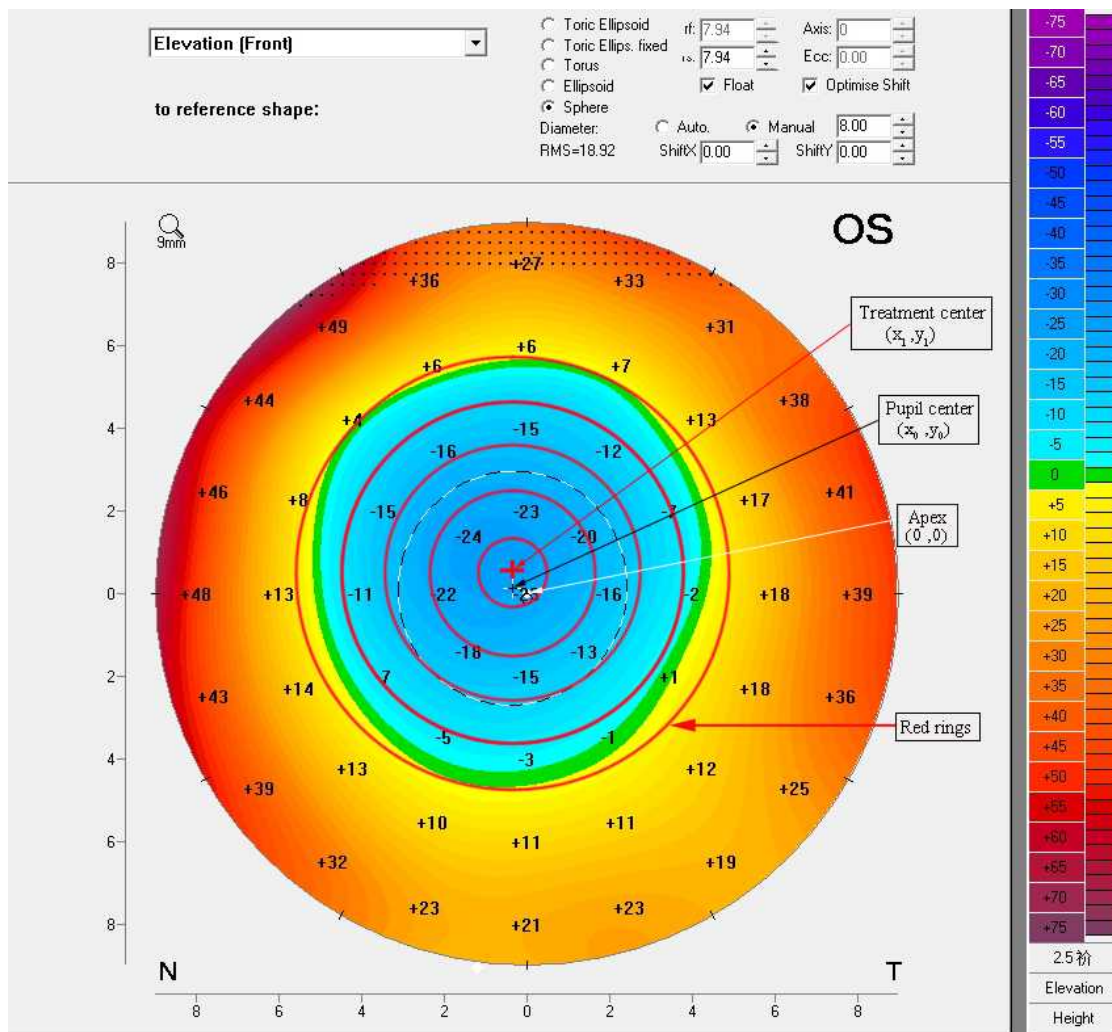


FIGURE 2. Elevation (*front*) corneal topography map showing the transparency with multiple concentric circles that was used on top of the elevation (*front*) map, centered over the treatment zone. The treatment zone was defined by the transition from green to yellow. The center of the concentric circles was defined as the treatment center.

$x_3 = x_2 + x_{0'}$ ($x_{0'}$ represents the pupil center coordinate on the corresponding preoperative map);

$y_3 = y_2 + y_{0'}$ ($y_{0'}$ represents the pupil center coordinate on the corresponding preoperative map)

The coordinate x_3 refers to the horizontal decentered displacement relative to the corneal vertex, and y_3 refers to the vertical decentered displacement relative to the corneal vertex. The total decentered displacement is $\sqrt{x_3^2 + y_3^2}$. The initial pupil decentration was used to calculate the decentration with respect to the pre-operative vertex.

Aberration Measurements

Wavefront aberrations were measured preoperatively and postoperatively at month 6 by an aberrometer (Wavefront Supported Custom Ablation; Carl Zeiss Meditec, Jena, Germany). The coefficients of the Optical Society of America standard were analyzed for a standardized diameter of 6.0 mm. The root mean square (μm) was used to analyze the coma, trefoil, and high order aberrations (HOAs). The coefficients of vertical trefoil, horizontal trefoil, vertical coma, horizontal coma, and spherical aberration were analyzed because they are clinically significant in visual quality. Preoperative to postop-

erative aberrations differences were also calculated. Potential associations between the induced aberrations and decentrations were assessed.

Data Analysis

Statistical software (SAS 9.3; SAS Institute, Inc., Cary, NC, USA) was used to analyze the data. Continuous variables were described as the means \pm SD. Considering the potential correlations between right and left eyes of the same patients, a generalized estimating equation (GEE) model was used to analyze the preoperative to postoperative changes of wavefront aberrations and to compare the difference in decentration between the right and left eyes. Associations between decentration, aberrations, and preoperative spherical equivalents were examined by GEE and expressed as a coefficient. The statistical significance level was set at 0.05.

RESULTS

Patients

This nonrandomized, prospective clinical study included 100 eyes of 55 consecutive patients (38 females, 17 males). Patient

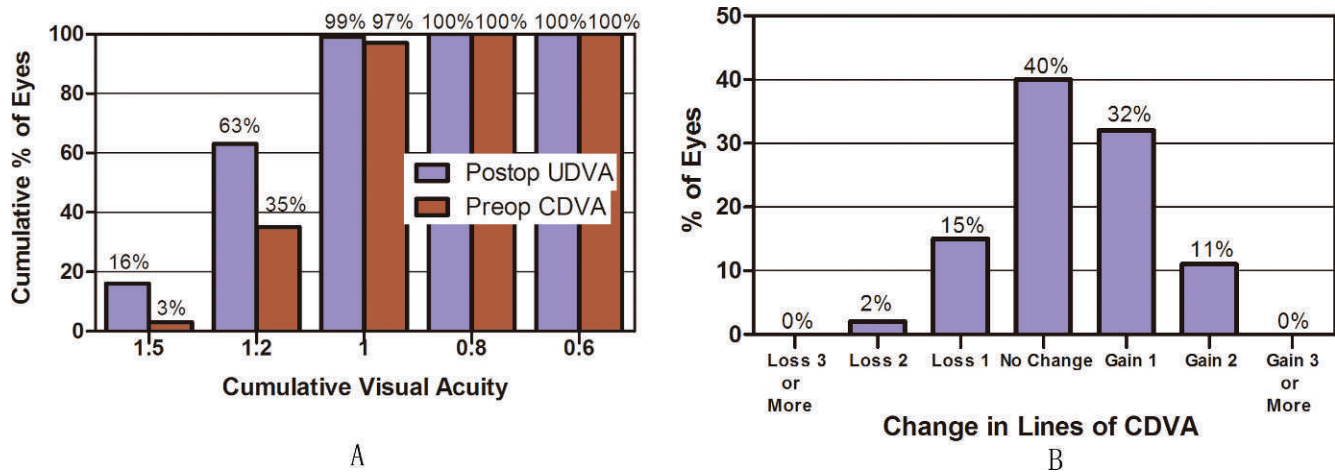


FIGURE 3. Visual outcomes after small incision lenticule extraction. (A) Cumulative visual acuity of postoperative UDVA and preoperative CDVA. (B) Change in lines of CDVA.

age at the time of refractive surgery was 28.1 ± 6.9 years (range, 18–52). The spherical equivalent refraction and cylindrical error were -6.45 ± 1.49 diopters (D; range, -3.90 to -9.63) and -0.81 ± 0.70 D (range, 0.00 to -3.00), respectively. The preoperative corrected distance visual acuity (CDVA, logMAR) was -0.03 ± 0.05 (range, -0.18 to 0.10).

After surgery, 99 of the treated eyes (99%) had a postoperative uncorrected distance visual acuity (UDVA) of 1.0 or greater, and 100 eyes (100%) were greater than 0.8. Regarding the safety of the procedure, 40 eyes (40%) had an unchanged CDVA; 32 eyes (32%) gained one line; and 11 eyes (11%) gained two lines. Fifteen eyes (15%) lost one line, and two eyes (2%) lost two lines (Fig. 3). Regarding the patient satisfaction survey, out of all the treated patients, there were two eyes with monocular diplopia. The detailed information of the two eyes is summarized in Table 1.

Optical Zone Center Locations

The optical zone center locations and their distances relative to the corneal vertex at the postoperative 6-month visit are summarized in Figure 4 and Table 2. The mean total decentred distance was 0.17 ± 0.09 mm (range, 0.02–0.49). It can be observed from Figure 4 that decentration occurred

TABLE 1. Summary of Two Patients With Monocular Diplopia

	Case 33	Case 43
Age	25	24
Sex	Male	Male
Eye	Left	Left
Secondary image location	Superior	Superior-temporal
Total decentred amount, mm	0.20	0.49
Induced horizontal coma, μm^*	0.45	0.37
Induced vertical coma, μm^*	-0.38	0.18
Induced total HOA (μm)	0.41	0.44
UDVA	1.0	1.0
Preoperative refraction, D	$-6.75/-0.75 \times 115$	$-3.50/-1.75 \times 5$
Preoperative CDVA	1.0	1.0
Postoperative refraction, D	$0.25/-0.75 \times 25$	$0.00/-0.50 \times 70$
Postoperative CDVA	1.2	1.0

* Preoperative to postoperative coefficient differences.

not only along the vertical axis, but tended to be superior on average. Figure 5 provides the distribution of the magnitude of the total decentred distance. A total of 100 treated eyes (100%) were within 0.50 mm; 70 eyes (70%) were within 0.20 mm; and 90 eyes (90%) were within 0.30 mm.

When the results were compared between the right and left eyes, there was no statistically significant difference in the distance of horizontal decentration ($P = 0.054$) or vertical decentration ($P = 0.92$) between right and left eyes.

Wavefront Aberrations

The vertical coma, horizontal coma, spherical aberration, coma, and HOAs had significantly increased at month 6 postoperatively (Fig. 6). No significant differences were found in terms of the vertical trefoil, horizontal trefoil, and trefoil (all $P > 0.05$). Of these aberrations, the vertical coma showed the greatest increase in magnitude.

According to the frequency distribution in Figure 5, we further compared the induced ocular aberrations (vertical trefoil, horizontal trefoil, vertical coma, horizontal coma, spherical aberration, coma, trefoil, and HOAs) between those having decentred distances greater than the delimit value and those within the delimit value, setting the delimit values at 0.20, 0.25, and 0.30 mm. These results indicated that there was no statistical significance between the two groups at any delimited value (all $P > 0.05$).

When the induced aberrations were compared between the right eyes and left eyes, no statistical differences were found between right eyes and left eyes in terms of vertical trefoil, horizontal trefoil, vertical coma, horizontal coma, spherical aberration, coma, trefoil, and HOAs (all $P > 0.05$).

Association Analysis

Multivariate association analysis found a significant relationship between the magnitude of the horizontal decentration and the induced horizontal coma ($\beta = -0.31$, $P < 0.0001$). No associations were found between horizontal decentration and induced horizontal trefoil ($\beta = -0.02$, $P = 0.85$); induced spherical aberration ($\beta = 0.05$, $P = 0.61$); induced HOAs ($\beta = 0.05$, $P = 0.37$); or preoperative spherical equivalent ($\beta = 0.002$, $P = 0.75$).

Regarding vertical decentration, the association between vertical decentration and the induced vertical coma was insignificant ($\beta = 0.02$, $P = 0.84$). In addition, no associations

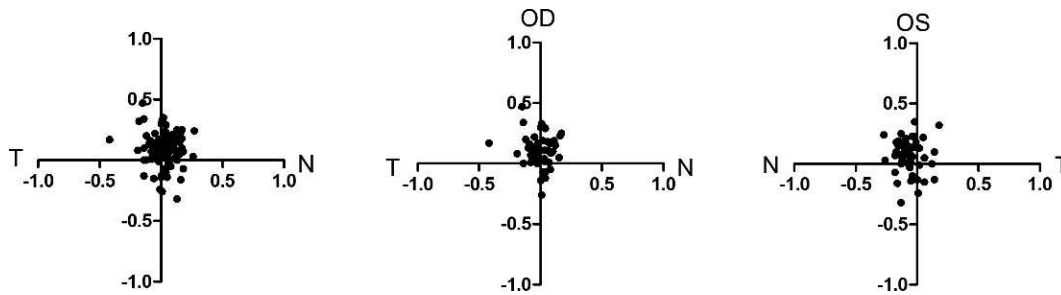


FIGURE 4. Scatterplot showing distribution of treatment centers (black dots) with respect to the corneal vertex in total eyes, right eyes, and left eyes. Positive vertical coordinates stand for superior displacements, and negative for inferior ones. The left eye horizontal data are flipped when plotted with the right eye data on the total eye graph.

were found between vertical decentration and induced vertical trefoil ($\beta = 0.12, P = 0.43$); induced spherical aberration ($\beta = 0.12, P = 0.22$); induced HOAs ($\beta = 0.16, P = 0.24$); or preoperative spherical equivalent ($\beta = 0.02, P = 0.07$).

DISCUSSION

The SMILE technique is a breakthrough in the correction of myopia and myopic astigmatism. It has unique merit in that, although no transition zone is created, the postoperative topographic maps exhibit a larger optical zone than topographic maps generated after femtosecond LASIK (FS-LASIK) which have the same preoperative refractions and designed optical zone. It would be expected that the SMILE surgery might have a high tolerance for decentration; in other words, a decentered zone might have only a mild impact on a patient's visual quality.

Bueeler et al.⁸ reported that it was unlikely that optical quality would deteriorate if the lateral alignment error was within 0.45 mm. Llorente et al.⁹ reported that, in 90% of eyes, even an accuracy of 0.80 mm or better would be sufficient. However, many patients who complain of visual disturbances after refractive surgeries have visual acuities of 1.0 or better and refractions close to plano. Thus, it is inadequate to assess their symptoms with conventional measures of acuity or refraction. In this study, there were two eyes (case 33 and case 43) reporting postoperative monocular coma-like diplopia, although with a UDVA of 1.0 or better (Table 1). A previous study reported that monocular diplopia following LASIK appears to correlate with postoperative corneal refractive power variation inside the pupillary area, caused by decentered or inhomogeneous ablation.¹⁰ Seen from the postoperative topography, the inhomogeneous anterior surface of the cornea (bowtie pattern) in the pupil zone contributes greatly to the visual disturbance in the two eyes complaining of visual disturbances in the present study.

It is worth noting that, in the present study, the attempted treatment center is the corneal vertex. Alternate treatment centers suggested in previous literature included the visual

axis, pupil center, and corneal vertex.¹¹ The corneal intercept of the visual axis would be the most ideal reference. The corneal vertex is the point of maximum elevation when the patient is fixating on the internal target.¹² Previous studies have provided evidence that corneal vertex centration is superior to entrance pupil centration in terms of induced ocular aberrations and asphericity.^{11,13,14} For the SMILE procedure, patients with a large angle kappa might be excluded from surgery to avoid decentered treatment. In other words, the entrance pupil center tends to be close to the corneal vertex in patients with a small kappa angle, and the surgeons could perform the centration procedure more easily in patients with a small angle kappa than in those with a large angle kappa. Although no eye-tracker was designed for the SMILE procedure, it is possible that, when the patient bed slowly moves up and approaches the cornea, the corneal vertex may fit the center of the contact surface of the suction cone. Our result showing a very mild mean alignment error confirmed the accuracy of this centration. Lee et al.¹⁵ reported that the mean decentration was 0.23 ± 0.10 mm, significantly higher than what we reported. Although the method used to determine the magnitude of decentration may vary among studies, our results indicated that accurate centration could be achieved in the SMILE technique's early phase of the learning curve.

Decentration usually results from an initial decentration or from involuntary eye movement during treatment. Intraoperative drift occurs when the eye moves involuntarily or when the surgeon attempts to correct an apparent decentration during treatment. In the SMILE technique, we considered that most of the decentration results from an initial decentration in

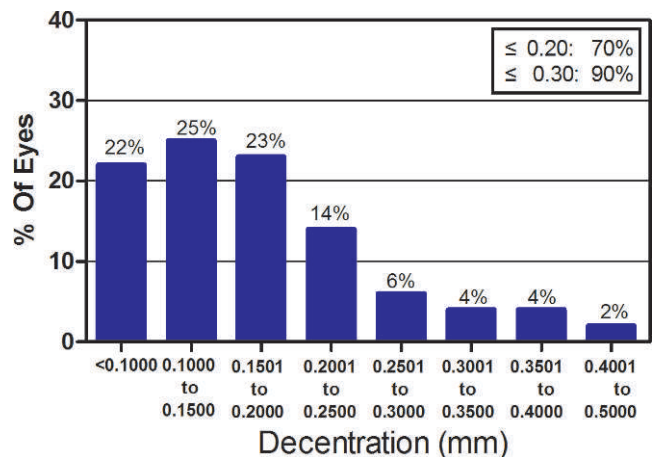


FIGURE 5. Distribution of total decentered displacements (millimeters).

TABLE 2. Treatment Center Location and Distance Relative to Corneal Vertex

	Horizontal Center Location	Vertical Center Location	Total Center Distance
Total, n = 100 eyes	0.03 ± 0.11	0.09 ± 0.14	0.17 ± 0.09
Right eye, n = 50 eyes	-0.01 ± 0.10	0.11 ± 0.13	0.17 ± 0.10
Left eye, n = 50 eyes	0.06 ± 0.10	0.07 ± 0.14	0.18 ± 0.08

Positive values of location represent superior and nasal directions relative to the corneal vertex. Means ± SD, in millimeters.

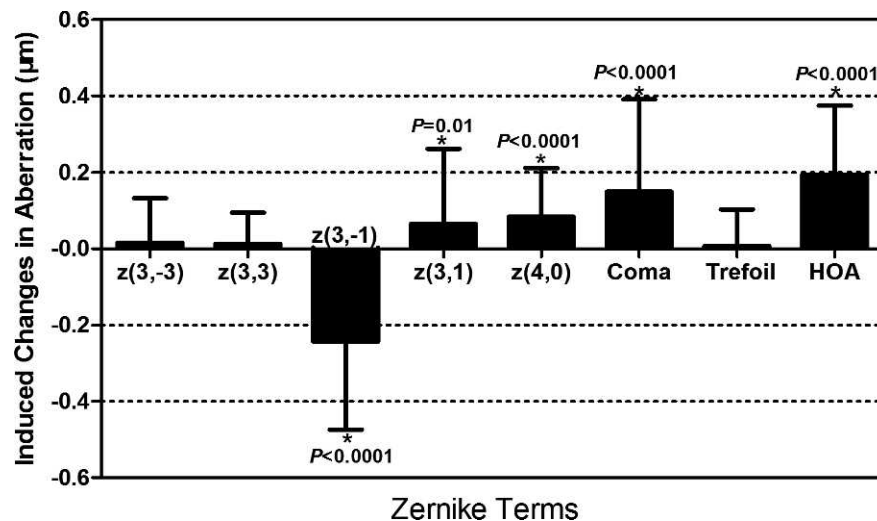


FIGURE 6. Induced changes in wavefront aberrations (6.0-mm analysis pupil diameter reported according to the Optical Society of America standards). *Significantly different from the preoperative values.

the surgeons' alignment when the patient bed moves up to match the cornea. It is important that, in the centration procedure, the patient bed moves slowly up, especially at the moment when the cone touches the cornea, to allow the corneal vertex to automatically fit the apex of the cone. Otherwise, a sudden suction between the cornea and the suction cone may result in decentration.

The current study showed that horizontal coma, vertical coma, spherical aberration, coma, and HOAs were significantly increased at 6 months postoperatively. Of these aberrations, vertical coma showed the greatest increase, which may well correspond with the result in the present study that decentration is greatest along the vertical axis. Consistent with our results, Padmanabhan et al.¹⁶ reported that, in LASIK treatment, the decentration was predominantly along the vertical meridian, which explains well why the greatest increase in HOAs was vertical coma.

In particular, we analyzed the possible associations among magnitudes of decentration, induced ocular aberrations, and preoperative spherical equivalents. Theoretically, ocular coma induction is associated directly with the magnitude of the attempted diopters and the magnitude of decentration.¹⁷ Moreno-Barriuso et al.¹⁸ reported that there seems to be a direct relation between the ablation decentration and the amount of induced coma aberration. In the present study, a significant association was found between the magnitude of horizontal decentration and the induced horizontal coma, but the association between the magnitude of vertical decentration and the induced vertical coma tended to be nonexistent, consistent with several other studies demonstrating poor associations between decentration and vertical coma. Mrochen et al.¹⁹ investigated the effect of decentration on aberrations 1 month after photorefractive keratectomy (PRK) and found that the amount of decentration is correlated with induced horizontal coma ($R^2 = 0.98$, $P < 0.0001$), but decentration was not correlated with induced vertical coma ($R^2 = 0.09$, $P = 0.35$). Oshika et al.²⁰ demonstrated that the amount of decentration is not correlated with the magnitude of coma-like aberrations after PRK and LASIK. Conversely, the study of Padmanabhan et al.¹⁶ found a moderately strong and statistically significant relationship between decentration and vertical coma 1 month after LASIK treatment. It is possible that the varying conclusions of these studies may be due to the complicated influence factors of wavefront aberrations. It is

well accepted that changes in wavefront aberrations after corneal refractive surgery are influenced by multiple factors^{15,21,22} such as gravity, corneal irregularity, corneal haze, wound healing, amount of time following surgery,¹⁵ and intraocular pressure.²²

Lee et al.¹⁵ reported that an ablation decentration greater than 0.30 mm from the center of the pupil entrance was associated with a greater induction of total HOA, coma, and spherical aberration after PRK, when compared with an ablation decentration of less than 0.15 mm. However, no significant difference in aberrations was noted between the two groups if the delimit value was set at 0.20, 0.25, or 0.30 mm.

A limitation of this study is that it is an observational study and no comparison with conventional FS-LASIK procedures is made. Future studies with randomized controlled design are needed to compare the differences in decentration between the two procedures in order to help refractive surgeons plan and evaluate treatment interventions.

In conclusion, the results of this study suggest that the SMILE technique can achieve accurate centration and good visual quality in the early phase of the learning curve. Special efforts to minimize induced vertical coma are necessary.

Acknowledgments

The authors thank Yongfu Yu (Department of Epidemiology, School of Public Health, Aarhus University, Denmark) for his help with the statistical analyses.

Supported by the Natural Science Foundation of China (Grant 11074052); the Key Project of Science and Technology of Shanghai (Grant 11JC1402000); the Outstanding Academic Leaders Program of Shanghai (Grant XBR2013098); and a scholarship Award for Excellent Doctoral Student granted by the Ministry of Education (JFF158003).

Disclosure: M. Li, None; J. Zhao, None; H. Miao, None; Y. Shen, None; L. Sun, None; M. Tian, None; E. Wadium, None; X. Zhou, None

References

- Vinciguerra P, Randazzo A, Albe E, Epstein D. Tangential topography corneal map to diagnose laser treatment decentration. *J Refract Surg*. 2007;23:S1057-S1064.

2. Shah R, Shah S, Sengupta S. Results of small incision lenticule extraction: all-in-one femtosecond laser refractive surgery. *J Cataract Refract Surg*. 2011;37:127-137.
3. Sekundo W, Kunert KS, Blum M. Small incision corneal refractive surgery using the small incision lenticule extraction (SMILE) procedure for the correction of myopia and myopic astigmatism: results of a 6 month prospective study. *Br J Ophthalmol*. 2011;95:335-339.
4. Vestergaard A, Ivarsen AR, Asp S, Hjortdal JO. Small-incision lenticule extraction for moderate to high myopia: predictability, safety, and patient satisfaction. *J Cataract Refract Surg*. 2012;38:2003-2010.
5. Li M, Zhao J, Shen Y, et al. Comparison of dry Eye and corneal sensitivity between small incision lenticule extraction and femtosecond LASIK for myopia. *PLoS One*. 2013;8:e77797.
6. Zhao J, Yao P, Li M, et al. The morphology of corneal cap and its relation to refractive outcomes in femtosecond laser small incision lenticule extraction (SMILE) with anterior segment optical coherence tomography observation. *PLoS One*. 2013;8:e70208.
7. Grewal DS, Brar GS, Grewal SP. Posterior corneal elevation after LASIK with three flap techniques as measured by Pentacam. *J Refract Surg*. 2011;27:261-268.
8. Bueeler M, Mrochen M, Seiler T. Maximum permissible lateral decentration in aberration-sensing and wavefront-guided corneal ablation. *J Cataract Refract Surg*. 2003;29:257-263.
9. Llorente L, Barbero S, Merayo J, Marcos S. Total and corneal optical aberrations induced by laser in situ keratomileusis for hyperopia. *J Refract Surg*. 2004;20:203-216.
10. Takei K, Sano Y, Achiron LR, et al. Monocular diplopia related to asymmetric corneal topography after laser in situ keratomileusis. *J Refract Surg*. 2001;17:652-657.
11. Wu L, Zhou X, Chu R, Wang Q. Photoablation centration on the corneal optical center in myopic LASIK using AOV excimer laser. *Eur J Ophthalmol*. 2009;19:923-929.
12. Park CY, Oh SY, Chuck RS. Measurement of angle kappa and centration in refractive surgery. *Curr Opin Ophthalmol*. 2012; 23:269-275.
13. Reinstein DZ, Archer TJ, Gobbe M. Is topography-guided ablation profile centered on the corneal vertex better than wavefront-guided ablation profile centered on the entrance pupil? *J Refract Surg*. 2012;28:139-143.
14. Arbelaez MC, Vidal C, Arba-Mosquera S. Clinical outcomes of corneal vertex versus central pupil references with aberration-free ablation strategies and LASIK. *Invest Ophthalmol Vis Sci*. 2008;49:5287-5294.
15. Lee SB, Hwang BS, Lee J. Effects of decentration of photorefractive keratectomy on the induction of higher order wavefront aberrations. *J Refract Surg*. 2010;26:731-743.
16. Padmanabhan P, Mrochen M, Viswanathan D, Basuthkar S. Wavefront aberrations in eyes with decentered ablations. *J Cataract Refract Surg*. 2009;35:695-702.
17. Guirao A, Williams DR, Cox IG. Effect of rotation and translation on the expected benefit of an ideal method to correct the eye's higher-order aberrations. *J Opt Soc Am A Opt Image Sci Vis*. 2001;18:1003-1015.
18. Moreno-Barriuso E, Lloves JM, Marcos S, Navarro R, Llorente L, Barbero S. Ocular aberrations before and after myopic corneal refractive surgery: LASIK-induced changes measured with laser ray tracing. *Invest Ophthalmol Vis Sci*. 2001;42:1396-1403.
19. Mrochen M, Kaemmerer M, Mierdel P, Seiler T. Increased higher-order optical aberrations after laser refractive surgery: a problem of subclinical decentration. *J Cataract Refract Surg*. 2001;27:362-369.
20. Oshika T, Klyce SD, Applegate RA, Howland HC, El DM. Comparison of corneal wavefront aberrations after photorefractive keratectomy and laser in situ keratomileusis. *Am J Ophthalmol*. 1999;127:1-7.
21. Fang L, Wang Y, He X. Theoretical analysis of wavefront aberration caused by treatment decentration and transition zone after custom myopic laser refractive surgery. *J Cataract Refract Surg*. 2013;39:1336-1347.
22. Hu L, Wang Q, Yu P, et al. The influence of intraocular pressure on wavefront aberrations in patients undergoing laser-assisted in situ keratomileusis. *Invest Ophthalmol Vis Sci*. 2013;54:5527-5534.