

The Oral Iron Chelator Deferiprone Protects Against Systemic Iron Overload–Induced Retinal Degeneration in Hpcidn Knockout Mice

Delu Song,¹ Liangliang Zhao,^{1,2} Yafeng Li,¹ Majda Hadziahmetovic,³ Ying Song,¹ John Connelly,⁴ Michael Spino,^{4,5} and Joshua L. Dunaief¹

¹FM. Kirby Center for Molecular Ophthalmology, Scheie Eye Institute, University of Pennsylvania, Philadelphia, Pennsylvania

²Department of Ophthalmology, Second Hospital of Jilin University, Changchun, China

³Department of Ophthalmology, Drexel University School of Medicine, Philadelphia, Pennsylvania

⁴ApoPharma, Inc., Toronto, Canada

⁵Leslie Dan Faculty of Pharmacy, University of Toronto, Toronto, Canada

Correspondence: Joshua L. Dunaief, 305 Stellar Chance Labs, 422 Curie Boulevard, Philadelphia, PA 19104; jdunaief@upenn.edu.

Submitted: April 10, 2014

Accepted: June 10, 2014

Citation: Song D, Zhao L, Li Y, et al. The oral iron chelator deferiprone protects against systemic iron overload–induced retinal degeneration in Hpcidn knockout mice. *Invest Ophthalmol Vis Sci.* 2014;55:4525–4532. DOI:10.1167/iovs.14-14568

PURPOSE. To investigate the retinal-protective effects of the oral iron chelator deferiprone (DFP) in mice lacking the iron regulatory hormone hepcidin (Hpc). These *Hpc* knockout (KO) mice have age-dependent systemic and retinal iron accumulation leading to retinal degeneration.

METHODS. *Hpc* KO mice were given DFP in drinking water from age 6 to 18 months. They were then compared to *Hpc* KO mice not receiving DFP by fundus imaging, electroretinography (ERG), histology, immunofluorescence, and quantitative PCR to investigate the protective effect of DFP against retinal and retinal pigment epithelial (RPE) degeneration.

RESULTS. In *Hpc* KO mice, DFP diminished RPE depigmentation and autofluorescence on fundus imaging. Autofluorescence in the RPE layer in cryosections was significantly diminished by DFP, consistent with the fundus images. Immunolabeling with L-ferritin and transferrin receptor antibodies showed a decreased signal for L-ferritin in the inner retina and RPE cells and an increased signal for transferrin receptor in the inner retina, indicating diminished retinal iron levels with DFP treatment. Plastic sections showed that photoreceptor and RPE cells were well preserved in *Hpc* KO mice treated with DFP. Consistent with photoreceptor protection, the mRNA level of rhodopsin was significantly higher in retinas treated with DFP. The mRNA levels of oxidative stress–related genes heme oxygenase-1 and catalase were significantly lower in DFP-treated *Hpc* KO retinas. Finally, ERG rod a- and b- and cone b-wave amplitudes were significantly higher in DFP-treated mice.

CONCLUSIONS. Long-term treatment with the oral iron chelator DFP diminished retinal and RPE iron levels and oxidative stress, providing significant protection against retinal degeneration caused by chronic systemic iron overload in *Hpc* KO mice. This indicates that iron chelation could be a long-term preventive treatment for retinal disease involving iron overload and oxidative stress.

Keywords: deferiprone, oxidative stress, hepcidin, retinal degeneration

Iron is essential for retinal metabolism, but excess iron, especially labile ferrous iron, can produce damaging free radicals. Our previous work showed increased iron levels in age-related macular degeneration (AMD) retinas compared to age-matched normal controls,¹ indicating that iron-mediated oxidative stress may contribute to retinal degeneration in AMD. Supporting this hypothesis, mice deficient in the ferroxidases ceruloplasmin (Cp) and hephaestin (Heph) have retinal iron accumulation and degeneration with features of AMD.^{2,3}

Normally, iron is imported into cells through transferrin receptor-mediated endocytosis. It can then be stored in ferritin or incorporated into iron-dependent enzymes or heme. Iron can be exported from cells by ferroportin (Fpn), the only known iron exporter, in cooperation with ferroxidases Cp or Heph.^{4,5} Hepcidin (Hpc) is widely expressed in many tissues,

including the photoreceptors, Müller cells, and RPE of the retina.⁶ Hepcidin binds to Fpn, triggering its internalization and lysosomal-dependent degradation.^{7,8} When the liver senses elevated iron levels, it secretes Hpc into the bloodstream. The Hpc then triggers degradation of Fpn in the enterocytes, preventing iron uptake from the gut.⁹ The retina also upregulates Hpc in response to elevated iron levels, which may result in diminished iron uptake into the retina from vascular endothelial cells. Due to unregulated Fpn-mediated iron transport, *Hpc* knockout (KO) mice have age-dependent systemic (resulting from excessive iron import in the gut) and retinal (resulting from increased serum iron and perhaps from unregulated Fpn-mediated iron import into the retina) iron accumulation causing retinal degeneration.¹⁰

The retinal degeneration is most likely caused by oxidative stress, which we have previously demonstrated occurs in the retinas of iron-overloaded mice.² Proteins that normally protect against this stress include the iron binding proteins ferritin and transferrin, as well as the ferroxidases, which convert iron into its less reactive ferric form.^{4,5} Also, the antioxidants heme oxygenase 1 and catalase can help prevent iron-induced oxidative damage.

Here we tested deferiprone (DFP), an orally administered iron chelator, for retinal protection. Deferiprone is approved as a second-line treatment by the Food and Drug Administration for reducing iron overload in patients with thalassemia syndromes. It has physicochemical properties favoring its dissolution and gastrointestinal absorption from drinking water and cell penetration. It is not associated with retinal toxicity in patients and mice.¹¹ Previously we found that DFP ameliorated oxidative stress and protected against retinal degeneration in *Cp/Hepb* double knockout (DKO) mice, which have retinal iron accumulation due to diminished retinal iron export despite low serum iron levels.¹¹ In addition, we showed that DFP protects against retinal degeneration triggered by other mechanisms, including light-induced retinal damage,¹² NaIO₃-induced retinal degeneration, and hereditary retinal degeneration due to *rd6* mutation.¹³ Similarly, a study by Obolensky et al.¹⁴ showed that treatment with zinc-deferoxamine, which combines the protective effect of zinc with increased deferoxamine cell permeability, inhibited retinal oxidative stress and protected against photoreceptor degeneration in an *rd10* model of retinitis pigmentosa.

The goal of the present study was to test whether long-term treatment with DFP might protect against retinal and RPE degeneration in *Hepc* KO mice, which have excessive iron not only locally in the eye, but also in the systemic circulation. We administered DFP in drinking water to *Hepc* KO mice from 6 months of age and assessed retinal protection at 18 months of age. Our results suggest that iron chelation may serve as a long-term protective agent for systemic iron overload-induced retinal degeneration.

MATERIALS AND METHODS

Animals

Hepc KO mice on a C57BL/6J background were generated as previously described.¹⁵ Six-month male *Hepc* KO mice were fed a standard laboratory diet with free access to water with or without DFP (1 mg/mL) ad libitum and were maintained in a temperature-controlled room at 21°C to 23°C with a 12-hour:12-hour light-dark photoperiod. Mice were treated with DFP in the drinking water for 12 months until euthanasia at 18 months of age. Experimental procedures were performed in accordance with the ARVO Statement for the Use of Animals in Ophthalmology and Vision Research. All protocols were approved by the animal care review board of the University of Pennsylvania.

Fundus Photography

Hepc KO mice were anesthetized with a mixture delivering (in mg/kg body weight) 25 ketamine, 10 xylazine, and 1000 urethane. The pupils of the mice were dilated with topical application of 1% tropicamide saline eyedrops (Mydracyl; Alcon, New York, NY, USA). Color and autofluorescence images were acquired using a fundus camera (Micron III; Phoenix Research Laboratories, Inc., Pleasanton, CA, USA).

Immunofluorescence

The globes fixed in 4% paraformaldehyde (PFA) were rinsed in PBS, and the eye cups were generated by removing the anterior segment. The eye cups were infiltrated in 30% sucrose overnight and embedded in Tissue-Tek OCT (Sakura Finetek, Torrance, CA, USA). Immunofluorescence was performed on 10- μ m-thick sections as previously published.¹¹ The primary antibodies were rabbit anti-mouse light ferritin (F17; a kind gift of Paolo Arosio, University of Brescia, Italy) at 1:2500 dilution and a rat anti-mouse transferrin receptor antibody (AbD Serotec, Raleigh, NC, USA) at a 1:250 dilution. Primary antibody was detected using fluorophore-labeled secondary antibodies (Jackson ImmunoResearch Laboratories, Inc., West Grove, PA, USA). Control sections were treated identically but without primary antibody. The sections were analyzed by fluorescence microscopy with identical exposure parameters (model TE300 microscope [Nikon, Tokyo, Japan] with Image-Pro software [Media Cybernetics, Silver Spring, MD, USA]).

Morphologic Analysis

Enucleated eyes were immersion fixed in 2% paraformaldehyde and 2% glutaraldehyde, and eye cups were made by dissecting away the cornea and lens. The tissues were then dehydrated in increasing concentrations of ethanol, infiltrated overnight, and embedded the next day in plastic (JB4; Polysciences, Inc., Warrington, PA, USA). For standard histology, 3- μ m-thick plastic sections were cut in the sagittal plane and were toluidine blue stained by incubation of the sections in 1% toluidine blue O and 1% sodium tetraborate decahydrate (Sigma-Aldrich, St. Louis, MO, USA) for 5 seconds. Stained sections were observed and photographed using bright-field illumination (model TE300; Nikon). The number of nuclei per column of outer nuclear layer (ONL) photoreceptors was counted in triplicate at 200- μ m intervals from the optic nerve head (ONH) to 1400 μ m from the ONH as we have described.¹²

Quantitative Real-Time PCR

Gene expression in the neurosensory retina and RPE plus choroid samples obtained from DFP-treated and untreated mice was analyzed by quantitative RT-PCR as we have described.¹⁶ Probes used were rhodopsin (*Rho*, Mm01184405_m1), retinal pigment epithelium 65 (*Rpe65*, Mm00504133_m1), ferritin light chain (*Ftl*, Mm03030144_g1), transferrin receptor (*Tfrc*, Mm00441941_m1), heme oxygenase 1 (*Hmox1*, Mm00516005_m1), and catalase (*Cat*, Mm00437992_m1). Eukaryotic 18S rRNA (Hs99999901_s1) was used as an endogenous control. Real-time quantitative PCR (qPCR) with Taqman probes (ABI, Grand Island, NY, USA) was performed using a DNA amplification/detection system (Prism model 7500; ABI) with the $\Delta\Delta$ CT method, which provides normalized expression values. The amount of target mRNA was compared among the groups of interest. All reactions were performed in biological (three mice) and technical (three qPCR replicates per biological sample) triplicates.

Electroretinography

Electroretinography (ERG) recordings followed procedures described previously.¹⁷ In brief, mice were dark-adapted overnight and then anesthetized with a cocktail delivering (in mg/kg body weight) 25 ketamine, 10 xylazine, and 1000 urethane. Pupils were dilated with 1% tropicamide saline solution (Mydracyl; Alcon), and mice were placed on a stage maintained at 37°C. Two electrodes made of UV-transparent plastic with embedded platinum wires were placed in

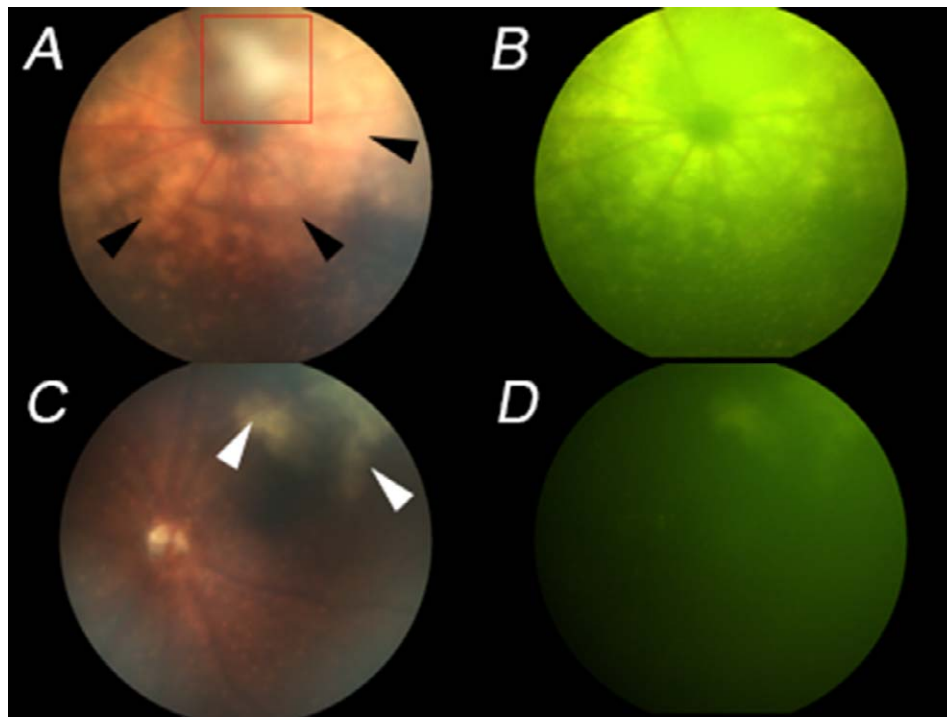


FIGURE 1. Fundus imaging showed that DFP-treated *Hepc* KO mice were protected against retinal degeneration. In untreated mice, there was yellowish retinal depigmentation (A) (black arrows). These depigmented areas were autofluorescent, corresponding to hypopigmented, autofluorescent RPE cells observed previously in cryosections (B). In contrast, DFP-treated *Hepc* KO mice had a smaller area of depigmentation (C) as well as less autofluorescence (D). The red boxed area in (A) indicates a lens opacity. The opacity is clearly in front of the retina, as it obscures the blood vessels. The white patches in (C) (arrowheads), which are behind the retinal blood vessels, indicate focal retinal degeneration.

electrical contact with the corneas. A platinum wire loop placed in the mouth served as the reference and ground electrode. The ERGs were then recorded (Espion Electrophysiology System; Diagnosys LLC, Lowell, MA, USA). The apparatus was modified by the manufacturer for experiments with mice by substituting light-emitting diodes with emission maximum at 365 nm for standard blue ones. The stage was positioned in such a way that the mouse's head was located inside the stimulator (ColorDome; Diagnosys LLC), thus ensuring uniform full-field illumination. The flash intensities of rod a- and b-waves are 0.01 and 500 scot cd m⁻² s, respectively. The white flash intensity of the cone b-wave is flash of 500 scot cd m⁻² s with a rod-suppressing steady background of 30 scot cd m⁻² s.

Statistical Analysis

The means \pm standard error were calculated for each comparison pair. Statistical analyses for ERG and qPCR were performed in GraphPad Prism 6.0 (San Diego, CA, USA) using the Student's two-group, two-sided *t*-test. $P < 0.05$ was considered statistically significant. Comparison of ONL thickness (nuclei) was performed using one-way ANOVA with post hoc pairwise comparisons using Bonferroni adjustment.

RESULTS

DFP Diminished Hypopigmented, Autofluorescent Lesions Detected by In Vivo Retinal Photography

The retinas of 18-month-old *Hepc* KO mice with or without DFP treatment were imaged using a fundus camera to assess the retinal-protective activity of DFP. The retinas of untreated

Hepc KO mice had striking widespread hypopigmented (Fig. 1A), autofluorescent (Fig. 1B) lesions, which were most abundant around the disc. In contrast, DFP-treated *Hepc* KO mice had small depigmented spots around the disc and a limited hypopigmented, autofluorescent region superior to the disc (Figs. 1C, 1D).

DFP Decreased the Autofluorescence in RPE Cells and Retinal Ferritin Levels Detected in Cryosections

In 18-month-old *Hepc* KO retinas, RPE cells were massively hypertrophic and migrating toward the inner retina (white asterisks in Fig. 2A). However, in DFP-treated retinas, only a few hypertrophic RPE cells were observed (red asterisks in Fig. 2B). Additionally, photoreceptors were preserved in DFP-treated mice, indicated by the thicker ONL containing more photoreceptor nuclei. Compared to nontreated *Hepc* KO retinas (Fig. 2C), the transferrin receptor signal was increased and L-ferritin signal was decreased in DFP-treated retinas (Fig. 2D), consistent with diminished retinal iron levels in the DFP-treated mice.

Preservation of Retinal Morphology in DFP-Treated Mice

Morphologic analysis was performed, and the numbers of photoreceptor nuclei were counted in three sagittal sections through the ONH from each eye. Consistent with morphologic changes in cryosectioned tissues, DFP provided significant preservation of RPE and photoreceptors throughout the retina (Figs. 3A, 3B). Compared to 18-month wild type (WT) (Fig. 3C), *Hepc* KO retinas had markedly hypertrophic RPE cells,

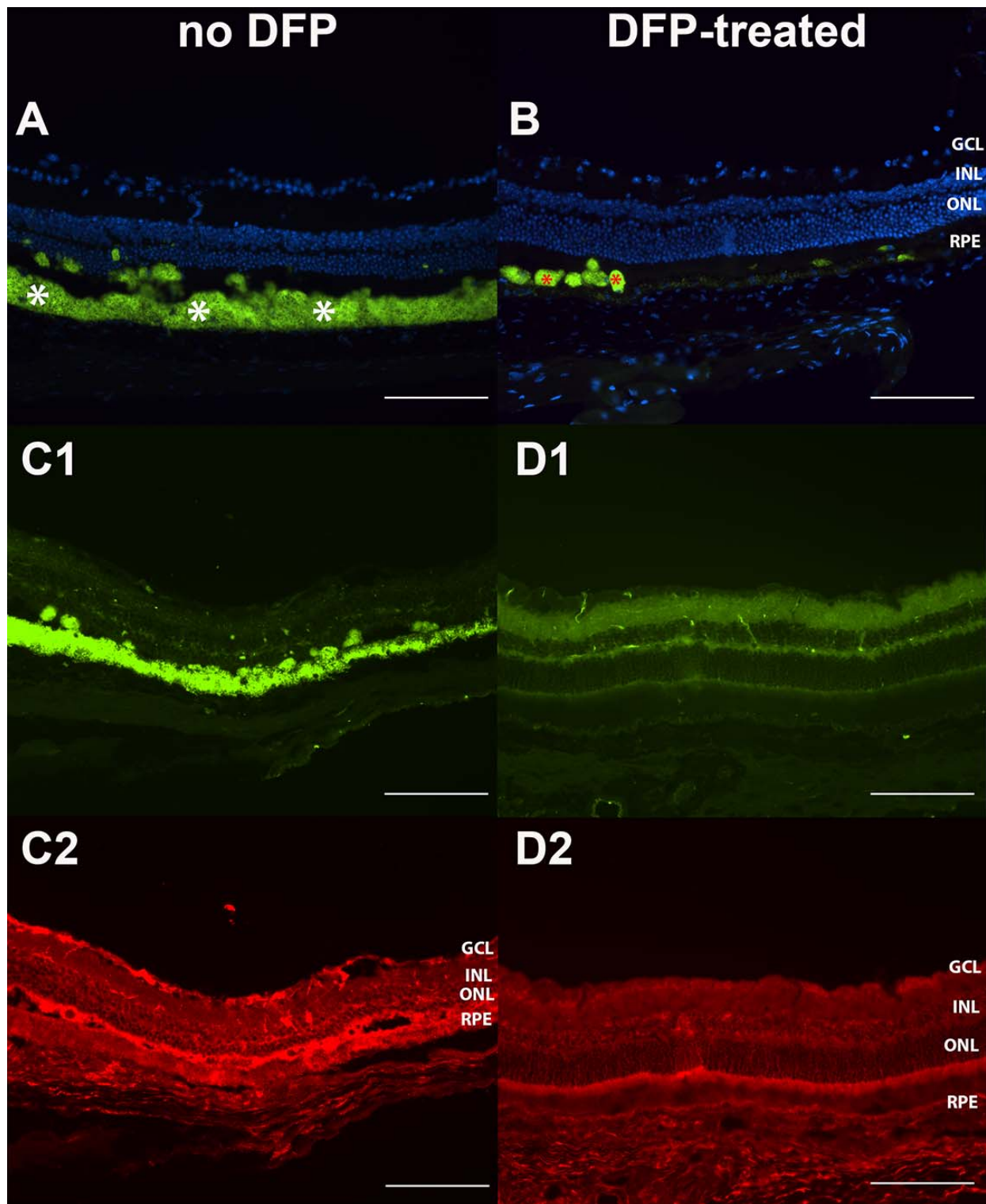


FIGURE 2. Photomicrographs showing autofluorescence and double labeling for L-ferritin and transferrin receptor in *Hepc* KO retinas with and without DFP. In retina sections of *Hepc* KO mice with 4',6-diamidino-2-phenylindole (DAPI) staining only, the RPE layer showed autofluorescence (*white asterisks* in [A]); however, the autofluorescent RPE cells were significantly fewer in DFP-treated retinas (*red asterisks* in [B]). Compared to nontreated *Hepc* KO retinas (C1, C2), the DFP-treated retinas showed increased signal for transferrin receptor in inner retina (D1) and decreased signal for L-ferritin in inner retina and RPE cells (D2). *Scale bars:* 100 μ m. RPE, retinal pigment epithelium; ONL, outer nuclear layer; INL, inner nuclear layer; GCL, ganglion cell layer.

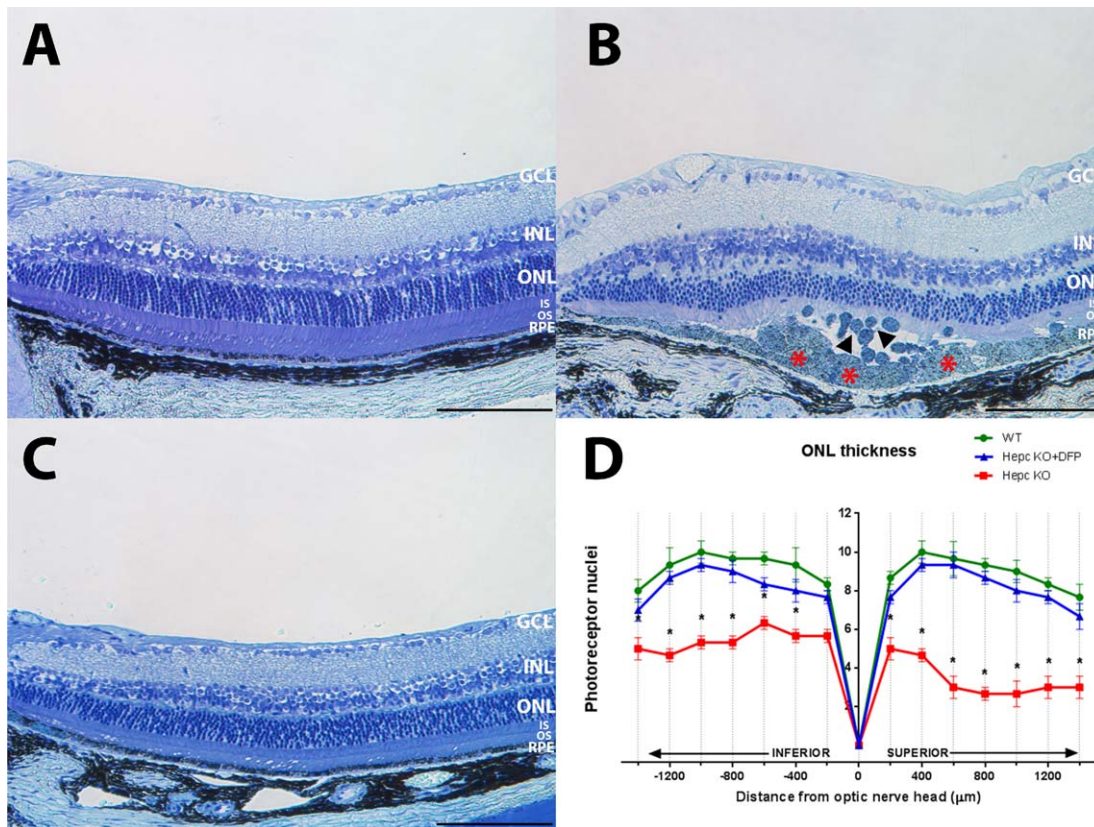


FIGURE 3. Bright-field photomicrographs of plastic sections of *Hepc* KO retinas with or without DFP and WT retinas, and plot showing photoreceptor nuclei preservation of ONL in DFP-treated *Hepc* KO retinas. Sagittal plane sections pass through optic nerve head. Photomicrographs of plastic sections showing hypertrophic RPE cells (red asterisks in [B]) that are migrating toward the inner retina (black arrowheads in [B]), with degeneration of overlying inner and outer segments and thinning of outer nuclear layer. The DFP-treated *Hepc* KO retina (A) appears more similar to WT (C). Plot of the thickness of the ONL, measured in numbers of photoreceptor nuclei per column (D). Measurements were made in triplicate every 200 μm from the ONH. *n* = 3. *Significant difference. Scale bars: 50 μm. RPE, retinal pigment epithelium; OS, photoreceptor outer segment; IS, photoreceptor inner segment; ONL, outer nuclear layer; INL, inner nuclear layer; GCL, ganglion cell layer.

thinning of the photoreceptor nuclear layer, and disorganization and shortening of the photoreceptor inner/outer segments, but the DFP-treated *Hepc* KO retinas had a thicker ONL and only a few slightly hypertrophic RPE cells.

DFP Protects Retinas From Iron Overload–Induced Oxidative Stress

Consistent with morphologic analysis, mRNA levels of *Rbo* in neurosensory retina were higher in DFP-treated *Hepc* KO mice (Fig. 4). L-ferritin mRNA levels were lower and transferrin receptor mRNA levels were significantly higher in retinas of *Hepc* KO mice receiving DFP treatment, which is in agreement with the immunolabeling results. To investigate the effect of DFP on oxidative stress, levels of two genes upregulated by iron overload–induced oxidative stress, heme oxygenase 1 and catalase, were assessed. Both heme oxygenase and catalase mRNA levels were significantly lower in retinas from DFP-treated mice.

ERG Responses Are Well Preserved by DFP

To evaluate the protection of retinal function by DFP, ERG was performed at age 18 months. Corresponding to histological findings, *Hepc* KO mice had significantly higher amplitude rod a- (Fig. 5A), rod b- (Fig. 5B), and cone b-wave (Fig. 5C) ERG responses after 12-month treatment with DFP.

DISCUSSION

In this study, we investigated whether long-term, systemic administration of DFP is effective in preventing retinal and RPE degeneration in *Hepc* KO mice. Our data indicate that DFP decreased retinal and RPE iron levels (based on changes detected by qPCR in iron-related genes) and provided protection against retinal and RPE degeneration. The protective effect of DFP may result from diminished oxidative stress secondary to iron level reduction in both RPE and neurosensory retina (NSR), as we found lower levels of mRNA expression for the antioxidant-related genes *Hmox-1* and *Cat* in mice receiving DFP.

Previously, we studied *Cp/Hepb* DKO mice; these have age-dependent retinal iron accumulation and degeneration despite systemic iron deficiency, so it is likely that the retina accumulates iron as a result of impaired retinal iron export. However, in *Hepc* KO mice, the retinal iron accumulation is exacerbated by high serum iron rather than resulting solely from impaired retinal iron regulation.

Patients with hemochromatosis, either primary or secondary, have excessive iron accumulation in the heart, pancreas, and liver.^{18–21} The most common mutation resides in a major histocompatibility complex class I–related gene, *HFE*.²² The gene product binds the transferrin receptor and forms a stable complex, thus decreasing the affinity of the receptor for transferrin. The *HFE* mutation results in more transferrin

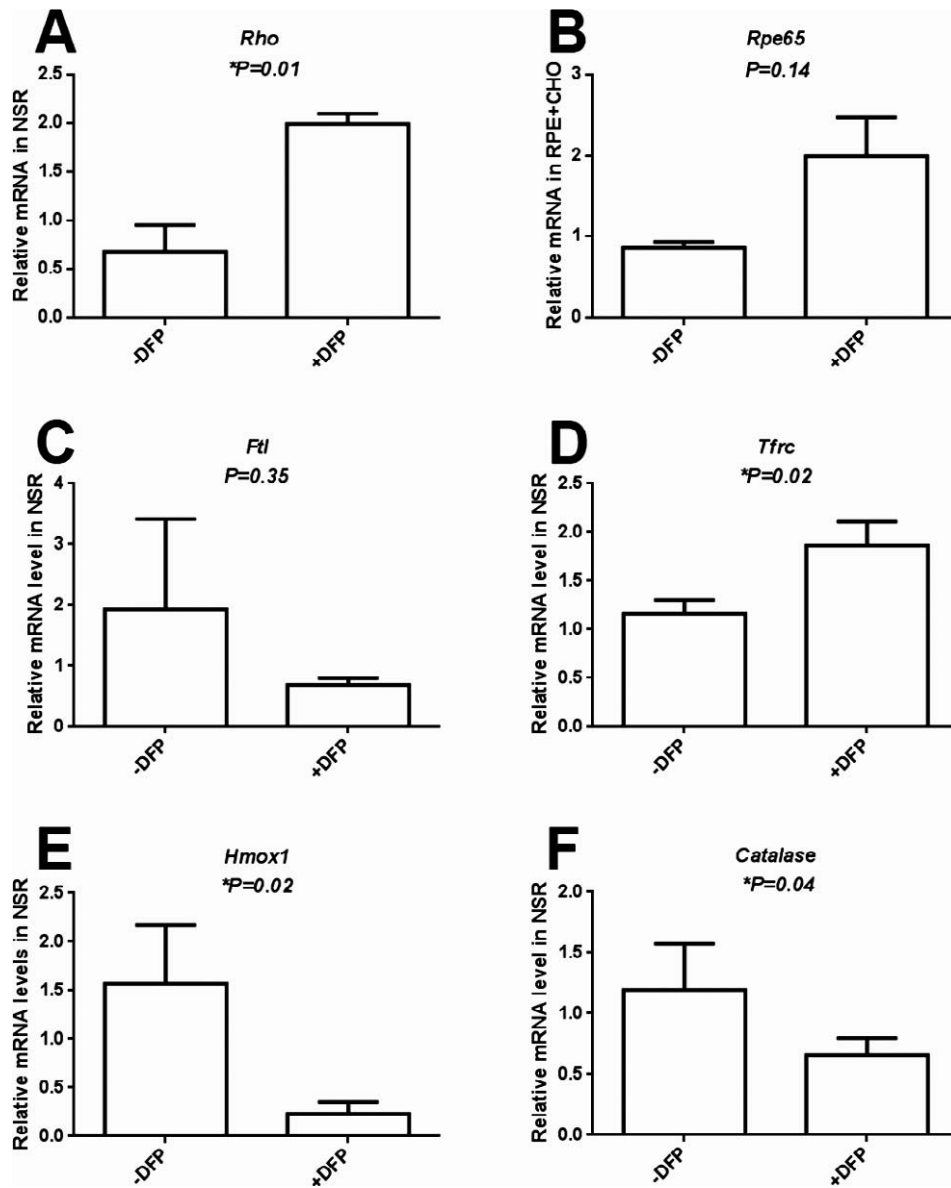


FIGURE 4. Graphs showing relative mRNA levels measured by qPCR. The *Rho* mRNA levels in NSR were higher in DFP-treated *Hepc* KO mice compared to nontreated mice (A). *Rpe65* mRNA levels in the RPE/choroid were not significantly changed. (B) DFP did not alter L-ferritin (Lft) mRNA level but increased transferrin receptor (*Tfrc*) mRNA levels significantly in NSR (C, D). *Hmox1* and catalase mRNA levels in neural retina (E, F) were significantly decreased after DFP treatment (E, F). *n* = 3. *Significant difference. CHO, choroid; Lft, light chain of ferritin; Tfrc, transferrin receptor; Hmox-1, heme oxygenase 1.

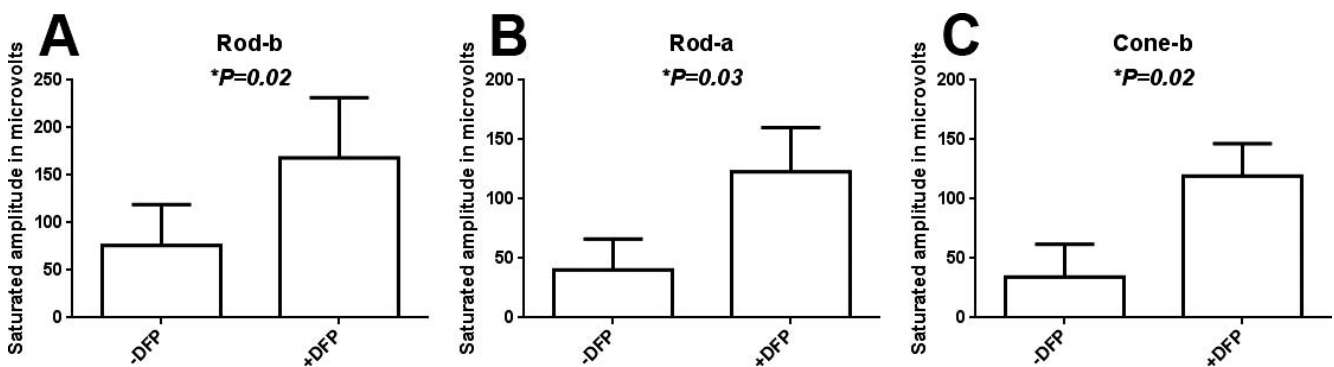


FIGURE 5. DFP protects *Hepc* KO mice from functional impairment measured by ERG. Saturated rod b-, a-, and cone b-wave responses were significantly higher in DFP-treated *Hepc* KO mice. *n* = 3. *Significant difference.

binding to Tfrc and subsequently more iron import into the cells of target tissues. There are two reports of retinal iron accumulation in hemochromatosis patients.^{23,24} Similarly, animal studies by Gnana-Prakasam et al.²⁵ showed that *HFE* KO mice, a mouse model of hemochromatosis, have increased retinal iron accumulation associated with their systemic iron overload. These results suggest that serum iron overload may exacerbate retinal iron overload, even though the retina is separated from the systemic circulation by the blood-retina barrier. The protection of DFP against retinal and RPE degeneration in *Hepc* KO mice supports the hypothesis that DFP could be retina protective when serum iron, in addition to retinal iron levels, are elevated. The mechanism of DFP's retinal protection in the *Hepc* KO mice could therefore be through chelation of serum iron and/or retinal iron.

Another unique characteristic of *Hepc* KO mice is the chronic disease process; the retinal degeneration appears at about 17 months of age. Our data demonstrate that DFP can prevent chronic iron overload-induced degeneration in the context of long-term administration, which is potentially a preventive or progression-slowng strategy for chronic diseases such as AMD. The present study indicates that DFP can diminish the oxidative stress that underlies the extensive RPE degeneration in *Hepc* KO mice and protect the cells from massive hypertrophy.

Compared to other iron chelation drugs, the benefits of DFP include the ability to cross the blood-brain barrier, rapid penetrance into cells and tissues, and no evidence of retinal toxicity. Deferoxamine, on the other hand, is unsuitable for oral dosing and also has been reported to cause retinal damage.²⁶ Another orally available iron chelator, deferasirox, has not been shown to cross the blood-retinal barrier. Of the three drugs, DFP has the lowest affinity for iron, so it is less likely to remove iron from sites where it is tightly bound and physiologically needed; rather, it will remove free or loosely bound iron that is available to cause oxidative damage.

In theory, DFP could be delivered orally or locally. Local administration may circumvent the 1% risk of reversible agranulocytosis associated with oral DFP. Further studies are needed to determine whether local administration could be effective. While further safety and pharmacokinetic investigations are warranted for potential treatment of diverse retinal disorders, the present study indicates that DFP has promise for long-term prevention and treatment of retinal and RPE degeneration in which iron overload or oxidative stress is involved.

Acknowledgments

We thank Gui-shuang Ying, MD, PhD (Center for Preventive Ophthalmology and Biostatistics at University of Pennsylvania) for help with biostatistics analysis.

Supported by National Eye Institute (NEI) Grant R01 EY015240, Research to Prevent Blindness, the Pennsylvania Lions Eye Research Foundation, a gift in memory of Dr. Lee F. Mauger, the Paul and Evanina Mackall Foundation Trust, the F.M. Kirby Foundation, and a research grant from ApoPharma, Inc., Toronto.

Disclosure: **D. Song**, None; **L. Zhao**, None; **Y. Li**, None; **M. Hadziahmetovic**, None; **Y. Song**, None; **J. Connelly**, None; **M. Spino**, None; **J.L. Dunaief**, ApoPharma (F), P

References

- Hahn P, Milam AH, Dunaief JL. Maculas affected by age-related macular degeneration contain increased chelatable iron in the retinal pigment epithelium and Bruch's membrane. *Arch Ophthalmol*. 2003;121:1099-1105.
- Hadziahmetovic M, Dentchev T, Song Y, et al. Ceruloplasmin/hephaestin knockout mice model morphologic and molecular features of AMD. *Invest Ophthalmol Vis Sci*. 2008;49:2728-2736.
- Hahn P, Qian Y, Dentchev T, et al. Disruption of ceruloplasmin and hephaestin in mice causes retinal iron overload and retinal degeneration with features of age-related macular degeneration. *Proc Natl Acad Sci U S A*. 2004;101:13850-13855.
- Harris ZL, Durley AP, Man TK, Gitlin JD. Targeted gene disruption reveals an essential role for ceruloplasmin in cellular iron efflux. *Proc Natl Acad Sci U S A*. 1999;96:10812-10817.
- Vulpe CD, Kuo YM, Murphy TL, et al. Hephaestin, a ceruloplasmin homologue implicated in intestinal iron transport, is defective in the sla mouse. *Nat Genet*. 1999;21:195-199.
- Gnana-Prakasam JP, Martin PM, Mysona BA, Roon P, Smith SB, Ganapathy V. Hpcidin expression in mouse retina and its regulation via lipopolysaccharide/Toll-like receptor-4 pathway independent of Hfe. *Biochem J*. 2008;411:79-88.
- Knutson MD, Oukka M, Koss LM, Aydemir F, Wessling-Resnick M. Iron release from macrophages after erythrophagocytosis is up-regulated by ferroportin 1 overexpression and down-regulated by hepcidin. *Proc Natl Acad Sci U S A*. 2005;102:1324-1328.
- Nemeth E, Tuttle MS, Powelson J, et al. Hepcidin regulates cellular iron efflux by binding to ferroportin and inducing its internalization. *Science*. 2004;306:2090-2093.
- Mena NP, Esparza A, Tapia V, Valdés P, Núñez MT. Hepcidin inhibits apical iron uptake in intestinal cells. *Am J Physiol Gastrointest Liver Physiol*. 2008;294:G192-G198.
- Hadziahmetovic M, Song Y, Ponnuru P, et al. Age-dependent retinal iron accumulation and degeneration in hepcidin knockout mice. *Invest Ophthalmol Vis Sci*. 2011;52:109-118.
- Hadziahmetovic M, Song Y, Wolkow N, et al. The oral iron chelator deferiprone protects against iron overload-induced retinal degeneration. *Invest Ophthalmol Vis Sci*. 2011;52:959-968.
- Song D, Song Y, Hadziahmetovic M, Zhong Y, Dunaief JL. Systemic administration of the iron chelator deferiprone protects against light-induced photoreceptor degeneration in the mouse retina. *Free Radic Biol Med*. 2012;53:64-71.
- Hadziahmetovic M, Pajic M, Grieco S, et al. The oral iron chelator deferiprone protects against retinal degeneration induced through diverse mechanisms. *Transl Vis Sci Technol*. 2012;1:7.
- Obolensky A, Berenshtein E, Lederman M, et al. Zinc-deferrioxamine attenuates retinal degeneration in the rd10 mouse model of retinitis pigmentosa. *Free Radic Biol Med*. 2011;51:1482-1491.
- Lesbordes-Brion J-C, Viatte L, Bennoun M, et al. Targeted disruption of the hepcidin 1 gene results in severe hemochromatosis. *Blood*. 2006;108:1402-1405.
- Wolkow N, Song D, Song Y, et al. Ferroxidase hephaestin's cell-autonomous role in the retinal pigment epithelium. *Am J Pathol*. 2012;180:1614-1624.
- Lyubarsky AL, Lem J, Chen J, Falsini B, Iannaccone A, Pugh EN Jr. Functionally rodless mice: transgenic models for the investigation of cone function in retinal disease and therapy. *Vision Res*. 2002;42:401-415.
- Wallace D-F, Subramaniam V-N. Non-HFE haemochromatosis. *World J Gastroenterol*. 2007;13:4690-4698.
- Beutler E. Hemochromatosis: genetics and pathophysiology. *Annu Rev Med*. 2006;57:331-347.
- Fleming RE, Britton RS, Waheed A, Sly WS, Bacon BR. Pathophysiology of hereditary hemochromatosis. *Semin Liver Dis*. 2005;25:411-419.

21. Wrighting DM, Andrews NC. Iron homeostasis and erythropoiesis. *Curr Top Dev Biol.* 2008;82:141-167.
22. Feder JN, Penny DM, Irrinki A, et al. The hemochromatosis gene product complexes with the transferrin receptor and lowers its affinity for ligand binding. *Proc Natl Acad Sci U S A.* 1998;95:1472-1477.
23. Davies G, Dymock I, Harry J, Williams R. Deposition of melanin and iron in ocular structures in haemochromatosis. *Br J Ophthalmol.* 1972;56:338-342.
24. Roth AM, Foos RY. Ocular pathologic changes in primary hemochromatosis. *Arch Ophthalmol.* 1972;87:507-514.
25. Gnana-Prakasam JP, Thangaraju M, Liu K, et al. Absence of iron-regulatory protein Hfe results in hyperproliferation of retinal pigment epithelium: role of cystine/glutamate exchanger. *Biochem J.* 2009;424:243-252.
26. Hidajat RR, McLay JL, Goode DH, Spearing RL. EOG as a monitor of desferrioxamine retinal toxicity. *Doc Ophthalmol.* 2004;109:273-278.