

# Macular Choroidal Thickness in Children: The Shandong Children Eye Study

Juan Mei Zhang,<sup>1,2</sup> Jian Feng Wu,<sup>3</sup> Jian Hua Chen,<sup>1,3</sup> Ling Wang,<sup>1</sup> Tai Liang Lu,<sup>4</sup> Wei Sun,<sup>4</sup> Yuan Yuan Hu,<sup>4</sup> Wen Jun Jiang,<sup>5</sup> Da Dong Guo,<sup>5</sup> Xing Rong Wang,<sup>5</sup> Hong Sheng Bi,<sup>5</sup> and Jost B. Jonas<sup>6</sup>

<sup>1</sup>The 1st Clinical School, Shandong University of Traditional Chinese Medicine, Jinan, Shandong, China

<sup>2</sup>Department of Ophthalmology, Linyi People's Hospital, Linyi, Shandong, China

<sup>3</sup>School of Ophthalmology and Optometry, Shandong University of Traditional Chinese Medicine, Jinan, Shandong, China

<sup>4</sup>The Second Affiliated Hospital of Shandong University of Traditional Chinese Medicine, Jinan, Shandong, China

<sup>5</sup>Eye Institute of Shandong University of Traditional Chinese Medicine, Jinan, Shandong, China

<sup>6</sup>Department of Ophthalmology, Medical Faculty Mannheim of the Ruprecht-Karls-University, Heidelberg, Germany

Correspondence: Hongsheng Bi, Eye Institute of Shandong University of Traditional Chinese Medicine, Ying Xiong Shan Road, Number 48, Shi Zhong District, Jinan, Shandong, China; hongshengbi@126.com.

JMZ and JFW are joint first authors.

HSB and JBJ are joint senior authors.

JMZ and JFW contributed equally to the work presented here and should therefore be regarded as equivalent authors.

Submitted: April 20, 2015

Accepted: June 24, 2015

Citation: Zhang JM, Wu JF, Chen JH, et al. Macular choroidal thickness in children: The Shandong Children Eye Study. *Invest Ophthalmol Vis Sci*. 2015;56:7646-7652. DOI:10.1167/iov.15-17137

**PURPOSE.** To examine the thickness of the macular choroid and its associations in school children aged 6 to 18 years.

**METHODS.** The school-based cross-sectional Shandong Children Eye Study included 6026 (94.7%) of 6364 eligible children fulfilling the inclusion criterion of an age from 4 to 18 years. Spectral-domain optical coherence tomography (SD-OCT) was performed for a subgroup of 972 school children aged 6+ years. All participants underwent ocular examinations, including measurement of visual acuity, cycloplegic refractometry, biometry, and SD-OCT (enhanced depth imaging mode) for measurement of choroidal thickness.

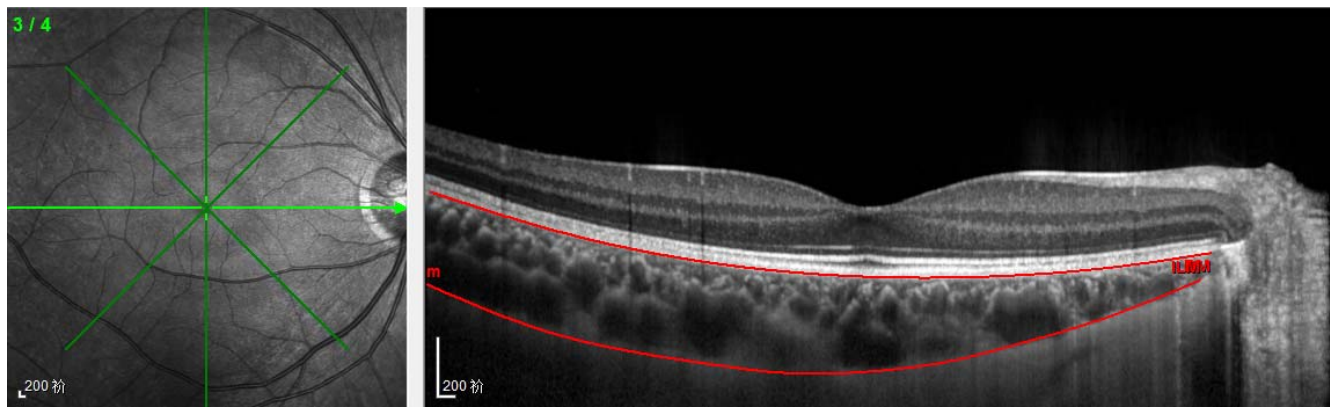
**RESULTS.** The study included 972 children (501 girls) with a mean age of  $11.3 \pm 3.3$  years (range, 6-18 years) and mean axial length of  $24.10 \pm 1.56$  mm (range, 16.57-28.82 mm). Mean choroidal thickness was thicker ( $P < 0.001$ ) at 500  $\mu$ m temporal to the foveola ( $290 \pm 67 \mu$ m) than in the subfoveal region ( $283 \pm 67 \mu$ m; range, 113-507  $\mu$ m) and the region 500  $\mu$ m superior to the fovea ( $283 \pm 66 \mu$ m), where it was thicker ( $P < 0.001$ ) than at 500  $\mu$ m inferior of the foveola ( $281 \pm 66 \mu$ m), and it was thinnest ( $P < 0.001$ ) at 500  $\mu$ m nasal of the foveola ( $268 \pm 67 \mu$ m). In multivariate analysis, thicker SFCT was (overall correlation coefficient  $r$ : 0.51) associated with shorter axial length ( $P < 0.001$ ; standardized correlation coefficient  $\beta$ : -0.48;  $B$ : -23.7; 95% confidence interval [CI]: -27.2 to -20.3), male sex ( $P = 0.006$ ;  $\beta$ : -0.08;  $B$ : -10.7; 95% CI: -18.3 to -3.11), and younger age ( $P = 0.04$ ;  $\beta$ : -0.07;  $B$ : -1.46; 95% CI: -2.85 to -0.07).

**CONCLUSIONS.** As in adults, thicker SFCT in children and teenagers was markedly associated with shorter axial length, and to a lesser degree with male sex and older age. As in adults, increasing axial myopia in teenagers is associated with choroidal thinning and development of a leptochoroid.

**Keywords:** choroidal thickness, choroid, optical coherence tomography, leptochoroid, Shandong Children Eye Study

Development of the enhanced depth imaging mode of spectral-domain optical coherence tomography (OCT) has made the visualization and measurement of the choroid in vivo feasible.<sup>1,2</sup> Previous investigations have determined the thickness of the choroid in the macular region and have assessed relationships between choroidal thickness measurements and other ocular and systemic variables such as axial length and age.<sup>3-5</sup> Most of these studies were performed on adults, whereas children and teenagers have only rarely been examined, and if, then mostly in relatively small study populations.<sup>6-15</sup> The study by Park and Oh,<sup>6</sup> in which the choroidal thickness profiles were assessed in 48 healthy children, revealed a mean subfoveal choroidal thickness (SFCT) of  $348 \pm 83 \mu$ m. In the investigation by Read and colleagues<sup>7</sup> on 194 children with an age of 4 to 12 years and a spherical equivalent refractive error ranging between +1.25 and -0.50

diopters, mean SFCT was  $330 \pm 65 \mu$ m (range, 189-538  $\mu$ m). Interestingly, SFCT increased significantly ( $P = 0.04$ ) with older age from  $312 \pm 62 \mu$ m in the 4- to 6-year-old age group to  $337 \pm 65 \mu$ m in the 7- to 9-year-olds to  $341 \pm 61 \mu$ m in the 10- to 12-year-olds. In another study by Read and associates<sup>8</sup> on 104 children with an age of 10 to 15 years, thicker SFCT was significantly associated with more hyperopic refractive error (correlation coefficient  $r$ : 0.39;  $P < 0.001$ ) and older age ( $r$ : 0.21;  $P = 0.02$ ). Mapelli and coworkers<sup>9</sup> analyzed choroidal volume variations in 52 healthy children with an age between 2 and 17 years and a mean axial length of  $22.8 \pm 0.98$  mm. Larger total macular choroidal volume (mean:  $0.55 \pm 1.82 \text{ mm}^3$ ) and foveal choroidal volume (mean:  $0.26 \pm 0.07 \text{ mm}^3$ ) increased significantly with shorter axial length and older age. Choroidal volume increased by  $0.21 \text{ mm}^3$  or 2.5% for every year of age, and decreased by  $1.0 \text{ mm}^3$  or 11.7% for every millimeter of axial



**FIGURE 1.** The choroid was delimited by two lines using the Spectralis linear measurement tool: The *top line* passing through the outer border of the hyperreflective RPE layer was automatically produced by the software, and the *bottom line* through the inner scleral border was drawn manually by the examiner.

length.<sup>9</sup> Ruiz-Moreno et al.<sup>10</sup> examined 83 eyes from 43 children with an age of less than 18 years and 75 eyes from 50 healthy adult volunteers. They did not find a significant ( $P = 0.19$ ) difference in mean SFCT between the children ( $313 \pm 65 \mu\text{m}$ ) and adults ( $306 \pm 103 \mu\text{m}$ ).<sup>10</sup> Bidaut-Garnier and colleagues<sup>11</sup> measured in 174 children (aged 3.5–14.9 years) a mean SFCT of  $343 \pm 75 \mu\text{m}$ , which increased with older age and shorter axial length. Zengin and coworkers<sup>12</sup> evaluated 160 patients with an age between 4 and 23 years and reported on a mean SFCT of  $308 \pm 48 \mu\text{m}$ , ranging from 206 to 410  $\mu\text{m}$ . Thicker SFCT was associated with older age and shorter axial length.<sup>12</sup> The Copenhagen Child Cohort 2000 Eye Study included 1323 healthy 11- and 12-year-old children and revealed a mean SFCT of  $369 \pm 81 \mu\text{m}$  in girls and  $348 \pm 72 \mu\text{m}$  in boys.<sup>13</sup> Longer axial length was associated with a thinner subfoveal choroid after adjusting for age and sex. There was no difference in choroidal thickness between sexes ( $P = 0.14$ ) after adjusting for age and axial length.<sup>13</sup>

Most of the previous studies, except for the Copenhagen Child Cohort Study, included relatively few children and they were usually not population-based. Knowledge about the choroidal thickness in children is important to obtain information about the normal growth and enlargement of the eye in children, and it is helpful for the diagnosis of macular and choroidal diseases, as the assessment of the macular choroidal thickness has become an integral part in the assessment of macular disorders. Some maculopathies, such as polypoidal choroidal vasculopathy, central serous chorioretinopathy, and Vogt-Koyanaga-Harada disease, are associated with an abnormally thick choroid, other macular diseases such as myopic maculopathy are related with an abnormally thin choroid, and AMD (except for geographic atrophy) is not correlated with an abnormal choroidal thickness.<sup>16–21</sup> We therefore conducted this study to measure the choroidal thickness in children in a population-based setting.

## METHODS

Our investigation was of the Shandong Children Eye Study, which was a school-based cross-sectional study among children in the province of Shandong in Eastern China. The ethics committee of Shandong University of Traditional Medicine approved the study design, and written consent was obtained from the parents of the children participating in the study. The age of the children ranged between 6 and 18 years. Children with strabismus, amblyopia, any systemic diseases, ocular surgery or injury, and history of using contact lenses and

chronic drugs, such as analgesics, decongestants, and antihistamines, were excluded from our investigation.

All children underwent a series of ocular examinations, including measurement of uncorrected visual acuity, best-corrected visual acuity, keratometry, refractometry without cycloplegia and under cycloplegia (auto-refractometer KR-8900; Topcon Co., Tokyo, Japan), slit examination of the anterior and posterior ocular segments, and ocular biometry (IOL Master; Carl Zeiss Meditec, Dublin, CA, USA). Cycloplegia was obtained by instilling 1% cyclopentolate eye drops (Alcon, Fort Worth, TX, USA) three times into the conjunctival cul-de-sac in an interval of 10 minutes each. The refractive spherical equivalent was defined as the sum of the spherical refractive error plus half of the cylindrical refractive error. The study design has been described in detail previously.<sup>22,23</sup>

The retina and choroid were additionally examined by OCT (Spectralis; Heidelberg Engineering Co., Heidelberg, Germany). All OCT examinations were performed before cycloplegic drops were instilled and between 9 AM and 12 PM to reduce the potentially confounding influence of cycloplegia or of diurnal variations in choroidal thickness.<sup>24</sup> The values of the keratometric measurements and of the noncycloplegic refractive error were given into the system of the OCT device, which then automatically compensated for the axial magnification of the retinal images. For each OCT examination, a series of four radial OCT scan lines, centered on the fovea and each separated by  $45^\circ$  were captured through the enhanced depth imaging mode (Fig. 1). The automatic real-time eye tracking function of the instrument was adopted, and 100 B-scans per radial OCT image were averaged. The OCT examination of all participants was carried out by one skilled technician. Two experienced ophthalmologists who were masked to the ocular measurements of the participants analyzed the images by using the Heidelberg Eye Explorer software (v.5.3.3.0; Heidelberg Engineering Co.), and the measurement results of both examiners were averaged. If the measurement differed between the two examiners by more than 10  $\mu\text{m}$ , the measurements had to be repeated until both examiners differed by less than 10  $\mu\text{m}$ . Choroidal thickness was defined as the distance from the outer surface of the hyperreflective line referred to as Bruch's membrane/RPE complex to the hyperreflective line of the inner sclera border. The Bruch's membrane/RPE complex line was automatically produced by the software, whereas the line of the inner sclera border was marked manually. A circle centered on the fovea with a radius of 500  $\mu\text{m}$  was made and the intersection points of the circle and the horizontal and vertical scan lines were obtained. The choroidal thickness at these locations was determined. The

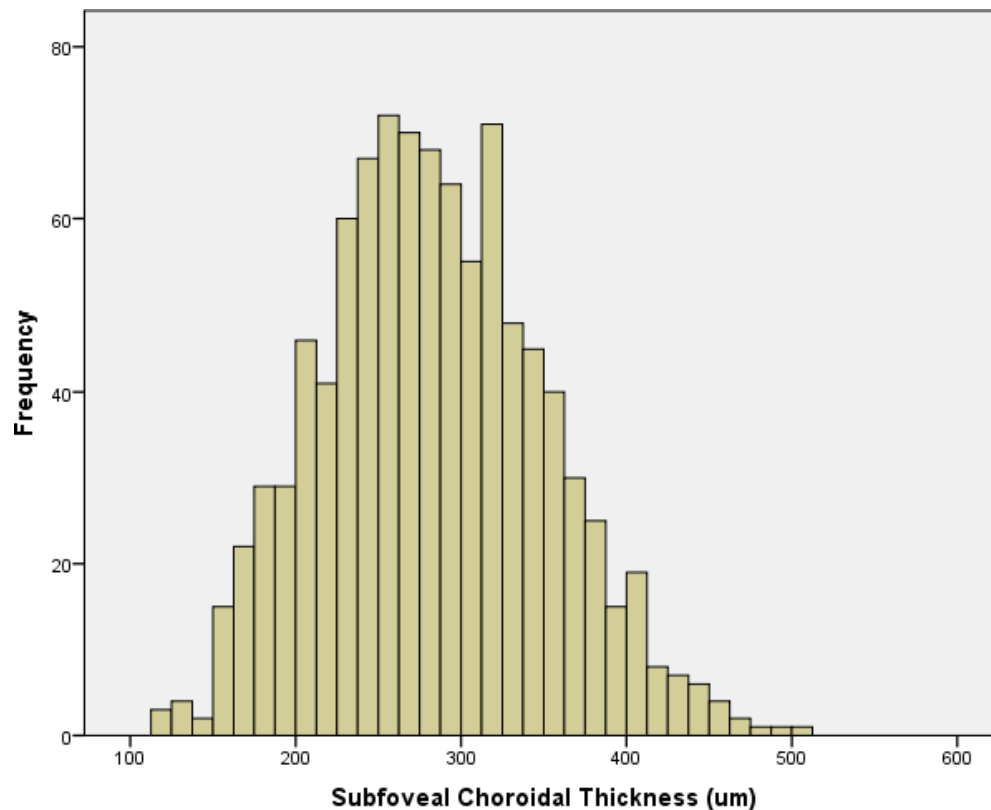


FIGURE 2. Histogram showing the distribution of subfoveal choroidal thickness in the Shandong Children Eye Study.

measurements obtained in only one randomly selected eye per individual were taken for further statistical analysis.

Inclusion criterion for the current study was an age of 6+ years and the availability of OCT images taken with the enhanced depth imaging mode. Age of 6+ years was an inclusion criterion, because it is difficult to obtain OCT images for children younger than 6 years. Statistical analysis was carried out using a commercially available statistical software package (SPSS for Windows, version 22.0; IBM-SPSS, Chicago, IL, USA). We calculated the mean values, which were expressed as mean  $\pm$  SE. In univariate analysis, we assessed associations between choroidal thickness measurements and other ocular or systemic parameters such as axial length, age, and sex. Eventually, we performed a multivariate regression analysis with choroidal thickness as the dependent parameter, and as independent variables all parameters that were significantly associated with choroidal thickness in the univariate analysis. 95% confidence intervals (CIs) were presented. All *P* values were 2-sided and were considered statistically significant when they were less than 0.05.

## RESULTS

The study included 972 children (501 girls) with a mean age of  $11.3 \pm 3.3$  years (range, 6–18 years). The mean cycloplegic spherical equivalent of the right eyes was  $-1.41 \pm 2.60$  diopters (range,  $-10.38$  to  $+14.25$  diopters), and that of the left eyes was  $-1.27 \pm 2.63$  diopters (range,  $-10.63$  to  $+14.13$  diopters). Mean axial length of the right eyes and left eyes was  $24.10 \pm 1.56$  mm (range, 16.57–28.82 mm) and  $24.08 \pm 1.33$  mm (range, 16.45–28.23 mm), respectively. The group of children included into the study as compared with the remaining participants of the Shandong Children Eye Study with an age of 6+ years were significantly ( $P < 0.001$ ) older

( $11.3 \pm 3.3$  vs.  $10.8 \pm 2.7$  years), and due to the correlation between older age and development of axial myopia, the children of our study were significantly ( $P < 0.001$ ) more myopic ( $-1.41 \pm 2.60$  vs.  $0.49 \pm 2.12$  diopters) and had longer axial length ( $24.10 \pm 1.56$  vs.  $23.6 \pm 1.17$  mm). Reason for the difference in age between the participants of the present study as compared with the other participants of the Shandong Children Eye Study was that it was more difficult to obtain OCT images in younger children than in older children.

Mean choroidal thickness in the subfoveal location was  $283 \pm 67$   $\mu$ m (range, 113–507  $\mu$ m) (Fig. 2), at the location 500  $\mu$ m temporal of the foveola  $290 \pm 67$   $\mu$ m (range, 118–506  $\mu$ m), at the location 500  $\mu$ m nasal of the foveola  $268 \pm 67$   $\mu$ m (range, 111–501  $\mu$ m), at the location 500  $\mu$ m superior of the foveola  $283 \pm 66$   $\mu$ m (range, 101–512  $\mu$ m), and at the location 500  $\mu$ m inferior of the foveola  $281 \pm 66$   $\mu$ m (range, 120–503  $\mu$ m) (Table 1). The choroid was significantly ( $P < 0.001$ ) the thickest at the location 500  $\mu$ m temporal to the foveola, followed by the subfoveal region and the region 500  $\mu$ m superior to the fovea, where the choroid was significantly ( $P < 0.001$ ) thicker than in the region 500  $\mu$ m nasal to the fovea. Choroidal thickness was thinnest ( $P < 0.001$ ) at the location 500  $\mu$ m nasal to the foveola (Table 1). This sequence of region with respect to the distribution of choroidal thickness was independent of age. In the group of teenagers aged 15+ years, choroidal thickness was thickest 500  $\mu$ m temporal to the foveola ( $251 \pm 62$   $\mu$ m), followed by the region 500  $\mu$ m superior to the foveola ( $245 \pm 61$   $\mu$ m) and the subfoveal region ( $244 \pm 62$   $\mu$ m), followed by the region 500  $\mu$ m inferior to the foveola ( $242 \pm 63$   $\mu$ m), and finally the region 500  $\mu$ m nasal to the foveola ( $236 \pm 61$   $\mu$ m).

In univariate analysis, thicker SFCT was significantly associated with the systemic parameters of younger age ( $P < 0.001$ ; correlation coefficient *r*:  $-0.35$ ) (Fig. 3), lower body



TABLE 1. Choroidal Thickness (Mean ± SD) (μm) in the Participants of the Shandong Children Eye Study

Location of Measurement	Choroidal Thickness	Range	Difference to Subfoveal Region, Mean	P Value of Difference to Subfoveal Region
Subfoveal	283 ± 67	113-507	-	-
500 μm temporal to the foveola	290 ± 67	118-506	-8	<0.001
500 μm nasal to the foveola	268 ± 67	111-501	15	<0.001
500 μm superior to the foveola	283 ± 66	101-512	-1	0.052
500 μm inferior to the foveola	281 ± 66	120-503	2	<0.001

mass index ( $P < 0.001$ ;  $r: -0.16$ ), shorter body height ( $P < 0.001$ ;  $r: -0.30$ ), lighter body weight ( $P < 0.001$ ;  $r: -0.26$ ), and lower diastolic blood pressure ( $P < 0.001$ ;  $r: -0.15$ ); and with the ocular parameters of shorter axial length ( $P < 0.001$ ;  $r: -0.50$ ) (Fig. 4), flatter anterior chamber depth ( $P < 0.001$ ;  $r: -0.26$ ), thicker lens thickness ( $P < 0.001$ ;  $r: 0.31$ ), shorter mean corneal curvature radius ( $P < 0.001$ ;  $r: -0.13$ ), more hyperopic refractive error ( $P < 0.001$ ;  $r: 0.20$ ), and better best-corrected visual acuity ( $P < 0.001$ ;  $r: 0.23$ ). Similar relationships were found for the choroidal thickness measurement obtained at the four other measurement locations. Subfoveal choroidal thickness was not significantly associated with sex ( $P = 0.56$ ), level of paternal education ( $P = 0.73$ ) and of maternal education ( $P = 0.82$ ), central corneal thickness ( $P = 0.82$ ), corneal diameter ( $P = 0.30$ ), or IOP ( $P = 0.23$ ).

The multivariate analysis included SFCT as dependent variable and all parameters as independent variables that were significantly associated with SFCT in the univariate analysis. Due to reasons of collinearity, we first dropped body weight (variance inflation factors [VIF]: 85) and body height (VIF: 3.5) and refractive error (VIF: 4.1). We then dropped, step by step, all parameters that were no longer significantly associated with SFCT: diastolic blood pressure ( $P = 0.97$ ), body mass index ( $P = 0.59$ ), best-corrected visual acuity ( $P = 0.40$ ), and age ( $P = 0.13$ ). In the final mode, thicker SFCT was associated (overall correlation coefficient  $r: 0.52$ ) with shorter axial length ( $P < 0.001$ ; standardized correlation coefficient  $\beta: -0.58$ ; non-standardized correlation coefficient  $B: 30$ ; 95% CI:  $-35$  to

$-26$ ), deeper anterior chamber depth ( $P < 0.001$ ;  $\beta: 0.19$ ;  $B: 45$ ; 95% CI:  $22-68$ ), thicker lens thickness ( $P = 0.002$ ;  $\beta: 0.13$ ;  $B: 48$ ; 95% CI:  $17-79$ ), and longer anterior corneal curvature radius ( $P = 0.02$ ;  $\beta: 0.09$ ;  $B: 24$ ; 95% CI:  $3.9-43.0$ ). If sex was added to the list of independent variables, anterior corneal curvature radius was dropped ( $P = 0.07$ ), and thicker SFCT was significantly (overall correlation coefficient  $r: 0.54$ ) associated with shorter axial length ( $P < 0.001$ ;  $\beta: -0.50$ ), deeper anterior chamber depth ( $P = 0.004$ ;  $\beta: 0.13$ ), thicker lens thickness ( $P = 0.001$ ;  $\beta: 0.14$ ), male sex ( $P = 0.04$ ;  $\beta: -0.07$ ), and marginally significantly associated with younger age ( $P = 0.051$ ;  $\beta: -0.08$ ) (Table 2). If best-corrected visual acuity was added to the model, it was not significantly ( $P = 0.51$ ;  $\beta: 0.03$ ) associated with SFCT. If in view of their interdependencies, all biometric parameters except for axial length were dropped, thicker SFCT was associated with shorter axial length ( $P < 0.001$ ;  $\beta: -0.48$ ;  $B: -23.7$ ; 95% CI:  $-27.2$  to  $-20.3$ ), male sex ( $P = 0.006$ ;  $\beta: -0.08$ ;  $B: -10.7$ ; 95% CI:  $-18.3$  to  $-3.11$ ) and younger age ( $P = 0.04$ ;  $\beta: -0.07$ ;  $B: -1.46$ ; 95% CI:  $-2.85$  to  $-0.07$ ).

For the choroidal thickness measurements obtained in the four meridians at a distance of 500 μm to the foveola, similar relationships as for SFCT were detected.

DISCUSSION

In our school-based study on SFCT in children and teenagers in rural and urban East China, the choroid was significantly the thickest at 500 μm temporal to the foveola, followed by the subfoveal region and the region 500 μm inferior to the foveola. The choroid was thinnest in the nasal perifoveal region. This regional distribution of the macular choroidal thickness was independent of age. In multivariate analysis, thicker SFCT (mean:  $283 \pm 67$  μm; range,  $113-507$  μm) was associated with shorter axial length ( $P < 0.001$ ;  $\beta: -0.50$ ), deeper anterior chamber depth ( $P = 0.004$ ;  $\beta: 0.13$ ), thicker lens thickness ( $P = 0.001$ ;  $\beta: 0.14$ ), and male sex ( $P = 0.04$ ;  $\beta: -0.07$ ), and marginally significantly associated with younger age ( $P = 0.051$ ;  $\beta: -0.08$ ). If all biometric parameters except for axial length were dropped, thicker SFCT was associated with shorter axial length ( $P < 0.001$ ;  $\beta: -0.48$ ), male sex ( $P = 0.006$ ;  $\beta: -0.08$ ), and younger age ( $P = 0.04$ ;  $\beta: -0.07$ ). It was not significantly ( $P = 0.51$ ) associated with best-corrected visual acuity.

The results found in our study can be compared with the findings obtained in previous investigations. In our study, the choroid was thickest temporal to the foveola, and it was thinnest in the nasal parafoveal region. Similar observations were made in previous studies on children.<sup>6,7,10</sup> In the study by Read et al.,<sup>7</sup> the 4- to 6-year-old children showed the thickest choroid ( $322 \pm 60$  μm) 1.5 mm superior to the foveal center. For 7- to 9-year-olds, the mean thickest choroid ( $344 \pm 63$  μm) was located in a superior-temporal location 0.8 mm from the foveal center. The thickest choroid of the 10- to 12-year-olds ( $350 \pm 58$  μm) was located 0.9 mm temporal to the foveal center. In the study by Sanchez-Cano and colleagues<sup>15</sup> on young adults, choroidal thickness was thickest in the region 1.5 mm superior to the foveola, followed by the temporal

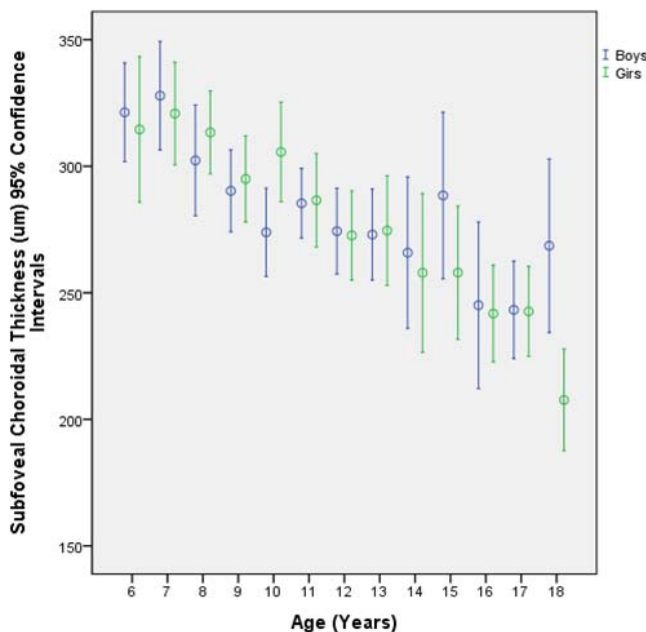


FIGURE 3. Scatterplot showing the correlation between age and subfoveal choroidal thickness stratified by sex in participants of the Shandong Children Eye Study.

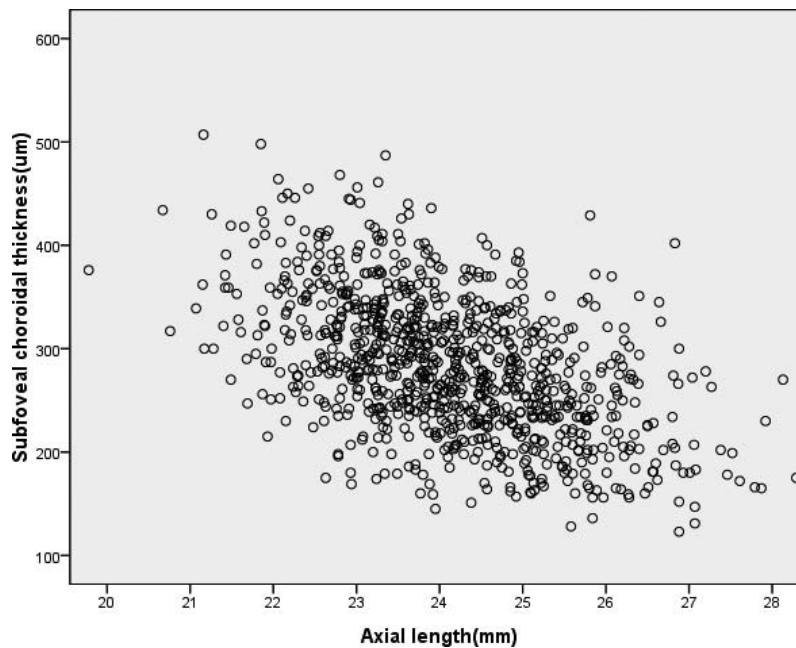


FIGURE 4. Scatterplot showing the relationship between axial length and subfoveal choroidal thickness in in participants of the Shandong Children Eye Study.

region and the subfoveal region. In another study by Read et al.<sup>8</sup> on children, choroidal thickness was significantly the thickest (346 µm) in the superior region and superior-temporal (341 µm) location at a distance of 1 to 3 mm from the foveal center, and it was thinnest in the nasal region and inferior-nasal (306 µm) area. Interestingly, in adults the choroid was thickest in the subfoveal region, usually followed by the temporal region and superior region, and it was thinnest in the nasal perifoveal region.<sup>3,4,25</sup> If the regional distribution of choroidal thickness is compared between the studies on children and the studies on adults, one may infer that the fovea of the retina in spatial relationship to the choroid may move into the temporal direction or that choroidal thickness locally adapts to the eventual location of the fovea in adults.

The mean thickness of the subfoveal choroid in our study was  $283 \pm 67$  µm and ranged between 113 µm and 507 µm (Fig. 2). These values were partially different from those obtained in other investigations. In a study on 48 Korean children aged 4 to 10 years, SFCT was 348 µm, and it was 342 µm in 174 French children aged 3.5 to 15 years.<sup>6,11</sup> These values were higher than those for our study population. In a study on 194 Australian children aged 4 to 12 years, mean SFCT was 330 µm, and in the Copenhagen Child Cohort 2000 Eye Study, mean SFCT was 369 µm in girls and 348 µm in boys aged 11 to 12 years.<sup>7,13</sup> These value were also thicker than in our study population. The most likely reason for the differences in SFCT between the various study populations may be differ-

ences in age, and particularly in axial length, between the study samples.

Subfoveal choroidal thickness ranged in our study population between 113 and 507 µm (Fig. 2). In the Beijing Eye Study on an adult population, a considerably larger range between a minimum of 8 µm and a maximum of 854 µm in SFCT was observed.<sup>5</sup> The wide range in SFCT may generally be due to the dependency of SFCT on various factors, such as axial length, anterior chamber depth, lens thickness, sex, and age. It indicates that a single SFCT value may clinically not be very helpful in the diagnosis of maculopathies if it cannot be adjusted for parameters that physiologically influence SFCT.

In most studies on choroidal thickness, including our investigation, choroidal thickness decreased with longer axial length.<sup>2-5,7,12</sup> In our study population of children, SFCT decreased by approximately 25 µm per millimeter increase in axial length (Table 2). In the study by Li and colleagues,<sup>26</sup> SFCT of young adults decreased by 58 µm for each millimeter increase in axial length. In a large population-based study on adults aged 50+ years, SFCT decreased by approximately 45 µm per millimeter increase in axial length.<sup>5</sup>

The SFCT also decreased with older age, with a decrease of approximately 1.5 to 1.0 µm per year increase in age in our population of children (Fig. 3). Similar observations were made in other studies on children by Read and colleagues.<sup>7,8</sup> In contrast, in the study by Bidaut-Garnier et al.,<sup>11</sup> choroidal thickness increased significantly from early childhood to

TABLE 2. Associations (Multivariate Analysis) Between Subfoveal Choroidal Thickness (µm) and Ocular and Systemic Parameters in the Shandong Children Eye Study

Parameter	P Value	Standardized Correlation Coefficient $\beta$	Nonstandardized Correlation Coefficient B	95% CI	Variance Inflation Factor
Axial length, mm	<0.001	-0.5	-25.3	-30.1 to -20.4	2.13
Anterior chamber depth, mm	0.004	0.13	31.6	9.90 to 53.3	1.95
Lens thickness, mm	0.001	0.14	50.1	20.1 to 80.0	1.62
Sex	0.04	-0.07	-9.75	-19.0 to 0.48	1.10
Age, y	0.051	-0.08	-1.69	-3.38 to -0.01	1.51

adolescence. Also, Zengin and coworkers<sup>12</sup> described that 16- to 23-year-old participants had thicker SFCT compared with the younger ones. Other studies also reported that choroidal volume increased with age in young children.<sup>9,14</sup> In a population-based cohort study of 1323 healthy 11- and 12-year-old children, a positive association of pubertal development with choroidal thickness in girls was revealed.<sup>13</sup> In other investigations on children, choroidal thickness decreased with older age.<sup>6,10</sup> In the Beijing Eye Study, SFCT decreased by 4  $\mu\text{m}$  per year increase in age beyond an age of 50 years after adjusting for axial length and other parameters.<sup>5</sup> An age-related decline in SFCT in adults has also been reported by Margolis and Spaide<sup>27</sup> (SFCT decrease by 15.6  $\mu\text{m}$  for each decade of life), by Ikuno and Tano<sup>28</sup> (SFCT decrease by 14  $\mu\text{m}$  per decade of life), and Ding and coworkers<sup>4</sup> (SFCT decrease by 54  $\mu\text{m}$  per decade of life). These intravitreal measurements were confirmed by histomorphometric investigations by Ramrattan and coworkers.<sup>29</sup> In the interpretation of the relationship between age and SFCT in our study population, one has to take into account that the association was only marginally statistically significant ( $P = 0.051$ ) and relatively weak, with a standardized correlation coefficient  $\beta$  of  $-0.08$ . The comparison of the age-related decline rates in SFCT between the children of our study and adults of various other investigations makes one infer that the relationship between age and SFCT may be curvilinear, with a slight decrease in SFCT in the early years of life, and a steeper decrease in SFCT later in life. It has remained unclear so far at which cutoff value of age the steeper age-related decline in SFCT starts.

The association between thicker choroid and male sex also has been reported for other study populations. Li et al.<sup>26</sup> reported that choroidal thickness was 18% higher in men than in women in young adults. Barteselli et al.<sup>30</sup> measured the choroidal volume and reported that men had significantly higher choroidal volume than women. As the relationship between age and SFCT, the association between sex and SFCT in our study population was relatively weak with a standardized correlation coefficient  $\beta$  of  $-0.07$  and a  $P$  value of 0.04 (Table 2). One may therefore beware of an overinterpretation of the association.

The clinical importance of SFCT has not yet been fully explored. Recent studies have suggested that lower best-corrected visual acuity was associated with a thinner choroid (also called leptochoroid), in particular with a subfoveal choroid thinner than 30  $\mu\text{m}$ .<sup>31,32</sup> In the children and teenager population of our study, choroidal thickness was not related with best-corrected visual acuity in the multivariate analysis. It may suggest that the association between a leptochoroid and decreased visual acuity may develop in adult life. A potential reason explaining the discrepancy between children and adults may be that children, as also our study population, rarely are extremely high axially myopic and also that an age-related loss of retinal photoreceptors and RPE cells may not have started or may not have markedly effected yet the total count of these cells in the retina of children.<sup>33,34</sup>

Potential limitations of our study need to be described. First, our study did not include children with an age younger than 6 years. Previous histomorphometric studies have shown that up to the end of the second or third year of life, the volumes of the sclera and choroid increase with older age, whereas after the age of approximately 2 to 3 years, choroidal and scleral volumes remain mostly constant.<sup>35</sup> At the same time, choroidal and scleral thickness decrease with older age, mostly due to the age-related increase in axial length.<sup>35</sup> The results of our study are therefore valid only for children with an age of 6 or more years. Second, the study included Chinese children, so that it has remained open whether the results of our study can

be fully transferred to children with another ethnicity. Third, we measured only the total thickness of the choroid, not taking into account the various layers of the choroid nor did we assess the density of the choriocapillaris or what could have been possible if the new technology of OCT-based angiography had been applied.<sup>36</sup>

In conclusion, as in adults, thicker SFCT in children and teenagers was markedly associated with shorter axial length, and to a lesser degree with male sex and older age. As in adults, increasing axial myopia in teenagers is associated with choroidal thinning and development of a leptochoroid. In contrast to adults, choroidal thinning was not associated with a decrease in best-corrected visual acuity.

### Acknowledgments

Supported by the National Health and Family Planning Commission of China (201302015), the Shandong Science and Technology Department (2011GGB14097, 2011GGH21835, 2012YD18081), the Shandong Health Department (2011HD014), and the Jinan Science and Technology Bureau (201102061).

Disclosure: **J.M. Zhang**, None; **J.F. Wu**, None; **J.H. Chen**, None; **L. Wang**, None; **T.L. Lu**, None; **W. Sun**, None; **Y.Y. Hu**, None; **W.J. Jiang**, None; **D.D. Guo**, None; **X.R. Wang**, None; **H.S. Bi**, None; **J.B. Jonas**, Allergan, Inc. (C), Merck Sharp & Dohme Co., Inc. (C), Alimera Co. (C), Boehringer Ingelheim Co. (C), Sanofi Co. (C), Pfizer Co. (C), P

### References

- Spaide RF, Koizumi H, Pozzoni MC. Enhanced depth imaging spectral-domain optical coherence tomography. *Am J Ophthalmol*. 2008;146:496-500.
- Fujiwara T, Imamura Y, Margolis R, Slakter JS, Spaide RF. Enhanced depth imaging optical coherence tomography of the choroid in highly myopic eyes. *Am J Ophthalmol*. 2009;148:445-450.
- Ikuno Y, Kawaguchi K, Nouchi T, Yasuno Y. Choroidal thickness in healthy Japanese subjects. *Invest Ophthalmol Vis Sci*. 2010;51:2173-2176.
- Ding X, Li J, Zeng J, et al. Choroidal thickness in healthy Chinese subjects. *Invest Ophthalmol Vis Sci*. 2011;52:9555-9560.
- Wei WB, Xu L, Jonas JB, et al. Subfoveal choroidal thickness: the Beijing Eye Study. *Ophthalmology*. 2013;120:175-180.
- Park KA, Oh SY. Choroidal thickness in healthy children. *Retina*. 2013;33:1971-1976.
- Read SA, Collins MJ, Vincent SJ, Alonso-Caneiro D. Choroidal thickness in childhood. *Invest Ophthalmol Vis Sci*. 2013;54:3586-3593.
- Read SA, Collins MJ, Vincent SJ, Alonso-Caneiro D. Choroidal thickness in myopic and nonmyopic children assessed with enhanced depth imaging optical coherence tomography. *Invest Ophthalmol Vis Sci*. 2013;54:7578-7586.
- Mapelli C, Dell'Arti L, Barteselli G, et al. Choroidal volume variations during childhood. *Invest Ophthalmol Vis Sci*. 2013;54:6841-6845.
- Ruiz-Moreno JM, Flores-Moreno I, Lugo F, Ruiz-Medrano J, Montero JA, Akiba M. Macular choroidal thickness in normal pediatric population measured by swept-source optical coherence tomography. *Invest Ophthalmol Vis Sci*. 2013;54:353-359.
- Bidaut-Garnier M, Schwartz C, Puyraveau M, Montard M, Delbosc B, Saleh M. Choroidal thickness measurement in children using optical coherence tomography. *Retina*. 2014;34:768-774.
- Zengin MO, Karahan E, Yilmaz S, Cinar E, Tuncer I, Kucukerdonmez C. Association of choroidal thickness with



- eye growth: a cross-sectional study of individuals between 4 and 23 years. *Eye (Lond)*. 2014;28:1482-1487.
13. Li XQ, Jeppesen P, Larsen M, Munch IC. Subfoveal choroidal thickness in 1323 children aged 11 to 12 years and association with puberty: the Copenhagen Child Cohort 2000 Eye Study. *Invest Ophthalmol Vis Sci*. 2014;55:550-555.
  14. Park KA, Oh SY. An optical coherence tomography-based analysis of choroidal morphologic features and choroidal vascular diameter in children and adults. *Am J Ophthalmol*. 2014;158:716-723.
  15. Sanchez-Cano A, Orduna E, Segura F, et al. Choroidal thickness and volume in healthy young white adults and the relationships between them and axial length, ametropia and sex. *Am J Ophthalmol*. 2014;158:574-583.
  16. Manjunath V, Fujimoto JG, Duker JS. Cirrus HD-OCT high definition imaging is another tool available for visualization of the choroid and provides agreement with the finding that the choroidal thickness is increased in central serous chorioretinopathy in comparison to normal eyes. *Retina*. 2010;30:1320-1321.
  17. Maruko I, Iida T, Sugano Y, Ojima A, Ogasawara M, Spaide RF. Subfoveal choroidal thickness after treatment of central serous chorioretinopathy. *Ophthalmology*. 2010;117:1792-1799.
  18. Chung SE, Kang SW, Lee JH, Kim YT. Choroidal thickness in polypoidal choroidal vasculopathy and exudative age-related macular degeneration. *Ophthalmology*. 2011;118:840-845.
  19. Kim SW, Oh J, Kwon SS, Yoo J, Huh K. Comparison of choroidal thickness among patients with healthy eyes, early age-related maculopathy, neovascular age-related macular degeneration, central serous chorioretinopathy, and polypoidal choroidal vasculopathy. *Retina*. 2011;31:1904-1911.
  20. Wood A, Binns A, Margrain T, et al. Retinal and choroidal thickness in early age-related macular degeneration. *Am J Ophthalmol*. 2011;152:1030-1038.
  21. Arora KS, Jefferys JL, Maul EA, Quigley HA. The choroid is thicker in angle closure than in open angle and control eyes. *Invest Ophthalmol Vis Sci*. 2012;53:7813-7818.
  22. Wu JF, Bi HS, Wang SM, et al. Refractive error, visual acuity and causes of vision loss in children in Shandong, China. The Shandong Children Eye Study. *PLoS One*. 2013;8:e82763.
  23. Jiang WJ, Wu JF, Hu YY, et al. Intraocular pressure and associated factors in children: The Shandong Children Eye Study. *Invest Ophthalmol Vis Sci*. 2014;55:4128-4134.
  24. Tan CS, Ouyang Y, Ruiz H, Sadda SR. Diurnal variation of choroidal thickness in normal, healthy subjects measured by spectral domain optical coherence tomography. *Invest Ophthalmol Vis Sci*. 2012;53:261-266.
  25. Manjunath V, Taha M, Fujimoto JG, Duker JS. Choroidal thickness in normal eyes measured using Cirrus HD optical coherence tomography. *Am J Ophthalmol*. 2010;150:325-329.
  26. Li XQ, Larsen M, Munch IC. Subfoveal choroidal thickness in relation to sex and axial length in 93 Danish university students. *Invest Ophthalmol Vis Sci*. 2011;52:8438-8441.
  27. Margolis R, Spaide RF. A pilot study of enhanced depth imaging optical coherence tomography of the choroid in normal eyes. *Am J Ophthalmol*. 2009;147:811-815.
  28. Ikuno Y, Tano Y. Retinal and choroidal biometry in highly myopic eyes with spectral-domain optical coherence tomography. *Invest Ophthalmol Vis Sci*. 2009;50:3876-3880.
  29. Ramrattan RS, van der Schaft TL, Mooy CM, de Bruijn WC, Mulder PG, de Jong PT. Morphometric analysis of Bruch's membrane, the choriocapillaris, and the choroid in aging. *Invest Ophthalmol Vis Sci*. 1994;35:2857-2864.
  30. Barteselli G, Chhablani J, El-Emam S, et al. Choroidal volume variations with age, axial length, and sex in healthy subjects: a three-dimensional analysis. *Ophthalmology*. 2012;119:2572-2578.
  31. Shao L, Xu L, Wei WB, et al. Visual acuity and subfoveal choroidal thickness. The Beijing Eye Study. *Am J Ophthalmol*. 2014;158:702-709.
  32. Spaide RF. Age-related choroidal atrophy. *Am J Ophthalmol*. 2009;147:801-810.
  33. Panda-Jonas S, Jonas JB, Jakobczyk-Zmija M. Retinal photoreceptor density decreases with age. *Ophthalmology*. 1995;102:1853-1859.
  34. Panda-Jonas S, Jonas JB, Jakobczyk-Zmija M. Retinal pigment epithelium cell count, density and correlations in normal human eyes. *Am J Ophthalmol*. 1996;121:181-189.
  35. Shen L, Xu X, You QS, et al. Scleral thickness in Chinese eyes. *Invest Ophthalmol Vis Sci*. 2015;56:2720-2727.
  36. Jia Y, Bailey ST, Hwang TS, et al. Quantitative optical coherence tomography angiography of vascular abnormalities in the living human eye. *Proc Natl Acad Sci U S A*. 2015;112:E2395-E2402.