

# Estimation of the Relative Amount of Hemoglobin in the Cup and Neuroretinal Rim Using Stereoscopic Color Fundus Images

Cristina Pena-Betancor,<sup>1</sup> Marta Gonzalez-Hernandez,<sup>1</sup> Francisco Fumero-Batista,<sup>2</sup> Jose Sigut,<sup>2</sup> Erica Medina-Mesa,<sup>1</sup> Silvia Alayon,<sup>2</sup> and Manuel Gonzalez de la Rosa<sup>1</sup>

<sup>1</sup>Hospital Universitario de Canarias, University of La Laguna, La Laguna, Tenerife, Spain

<sup>2</sup>Department of Computer Science, University of La Laguna, La Laguna, Tenerife, Spain

Correspondence: Manuel Gonzalez de la Rosa, 25 de Julio 34, 38004 Santa Cruz de Tenerife, Spain; mgdelarosa@telefonica.net.

Submitted: September 1, 2014  
Accepted: January 29, 2015

Citation: Pena-Betancor C, Gonzalez-Hernandez M, Fumero-Batista F, et al. Estimation of the relative amount of hemoglobin in the cup and neuroretinal rim using stereoscopic color fundus images. *Invest Ophthalmol Vis Sci.* 2015;56:1562–1568.  
DOI:10.1167/iovs.14-15592

**PURPOSE.** To calculate the relative amount of hemoglobin (Hb) in sectors of the optic nerve head (ONH) from stereoscopic color fundus images using the Laguna ONhE method and compare the results with the visual field evaluation and optical coherence tomography (OCT).

**METHODS.** Healthy eyes ( $n = 87$ ) and glaucoma eyes ( $n = 71$ ) underwent reliable Oculus Spark perimetry and Cirrus OCT. Optical nerve head color images were acquired with a nonmydriatic stereoscopic Wx Kowa fundus camera. Laguna ONhE program was applied to these images to calculate the relative Hb amount in the cup and six sectors of the rim. Receiver operating characteristic (ROC) analysis and correlations between parameters were calculated.

**RESULTS.** We did not observe any variations in the relative amount of Hb in relation to age in healthy subjects ( $R^2 = 0.033$ ,  $P > 0.05$ ). Maximum ROC area confidence intervals were observed for a combination between perimetric indices and the Laguna ONhE Glaucoma discriminant function (0.970–0.899) followed by rim area (0.960–0.883), and mean deviation (MD; 0.944–0.857). In glaucoma cases, relative Hb amount presented significant reduction in all rim sectors, especially 231° to 270° and 81° to 120° ( $P < 0.001$ ), except in the temporal 311° to 40° ( $P = 0.11$ ). Perimetry mean sensitivity by sectors was better correlated with respective Hb levels than with rim areas or the corresponding nerve fiber thickness, especially the superior and inferior sectors ( $P < 0.05$ ).

**CONCLUSIONS.** Visual field sensitivity was better correlated with Hb levels than with rim sector areas or the corresponding nerve fiber thickness. In many cases the remaining rim show low perfusion, especially in the superior and inferior sectors.

Keywords: glaucoma, hemoglobin, perimetry, visual field, optic nerve head, perfusion

Our first publication on the Laguna ONhE method for calculating the relative amount of hemoglobin (Hb), in the optic nerve head (ONH)<sup>1</sup> has continued to arouse the interest of several research groups to evaluate perfusion “in situ.” Circulation rate has been estimated by laser Doppler<sup>2</sup> and laser speckle flowgraphy,<sup>3</sup> and vascular structure by OCT angiography.<sup>4</sup>

That publication resulted in an interesting suggestion by Denniss<sup>5</sup> to analyze the relative amount of hemoglobin present in the rim and in the cup separately. In a previous paper<sup>6</sup> the author indirectly estimated the relative presence of Hb by analyzing the differential light absorption (DLA) to radiation of 570 nm (Hb isosbestic point), and creating manual masks to separate the information from the vessels, the cup and disc.

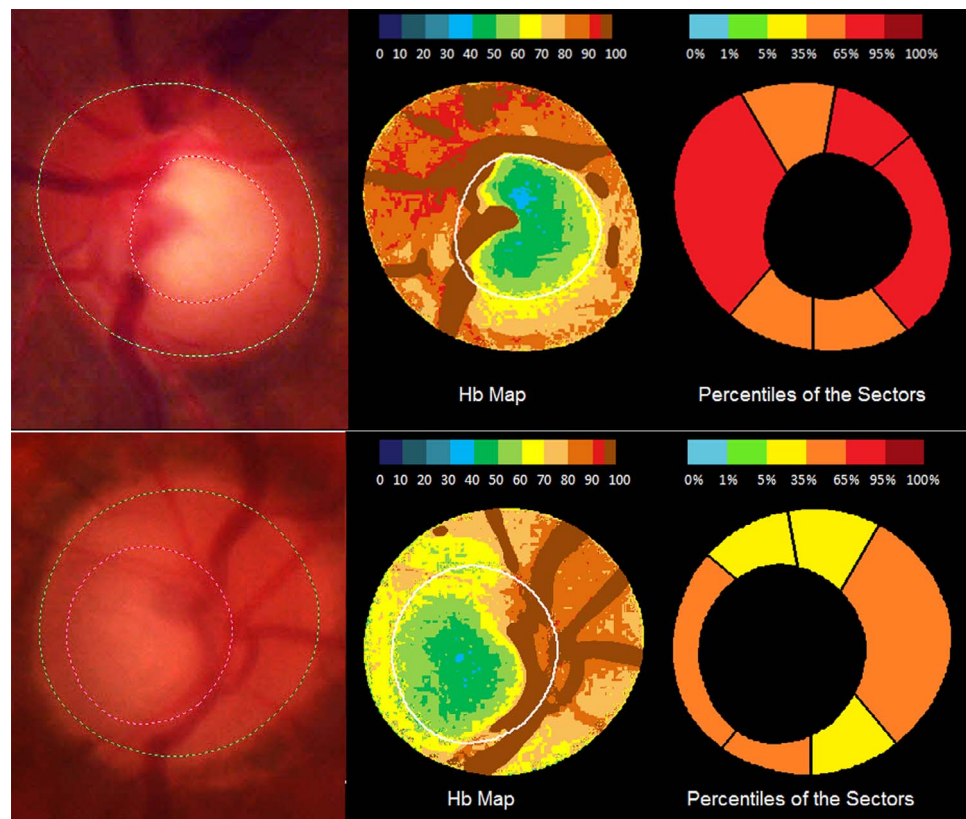
In our response<sup>7</sup> we discussed two alternatives. One would involve overlapping Hb maps with disc and cup boundaries obtained by OCT. The second would be the direct application of the Laguna ONhE method to color images of the ONH obtained by stereophotography with three-dimensional reconstruction of the shape of the nerve. The advantage of the latter method would be its simplicity because no other complex instrument is required. The difficulty would be to obtain pairs

of images with perfectly adjusted and reproducible angles. The possibility offered by the Kowa Wx Camera (Kowa Co., Ltd., Tokyo, Japan) to obtain both images simultaneously, and evidence of its usefulness to measure ONH topographic parameters<sup>8</sup> led us to direct our work in this direction, to separate the information from cup and rim as suggested by Denniss.

## METHODS

The study protocol adhered to the tenets of the Declaration of Helsinki and was approved by the institutional review board of the University Hospital of the Canary Islands. The participants were informed about the study objectives and signed informed consent was obtained from all.

A sample of 87 healthy eyes and 71 glaucomatous eyes were consecutively and prospectively selected. Healthy eyes were recruited from patients referred for refraction who underwent routine examination without abnormal ocular findings, hospital staff, and relatives of patients in our hospital. Patients with glaucoma were enrolled from the Department of Ophthalmol-



**FIGURE 1.** Two examples of delimitation of the disc, rim, and cup (*left*) in subjects with glaucoma. Maps show the relative amount of hemoglobin expressed as a percentage (*center*) and percentiles of hemoglobin in rim sectors with respect to the healthy population (*right*).

ogy of the University Hospital of the Canary Islands, Tenerife, Spain. One eye from each subject was randomly chosen for the study, unless only one eye met the inclusion criteria.

Eligible subjects had to have a best-corrected visual acuity of 20/40 or better, refractive error within  $\pm 5$  diopters (D) equivalent sphere, and  $\pm 2$  D astigmatism, and an open anterior chamber angle. The presence of cataract was not considered a criterion for exclusion a priori. Age and previous cataract and glaucoma surgery were not criteria for exclusion. We excluded patients with any other associated eye disease that could interfere with the interpretation of the results.

### Study Protocol

Participants underwent a full ophthalmologic examination, including: clinical history, visual acuity, slit-lamp biomicroscopy, IOP measurement, and ophthalmoscopy of the posterior segment.

All glaucoma patients had perimetric assessment, having undergone at least two previous examinations. White-on-white Spark strategy was used in an Easyfield perimeter (Oculus Optikgeräte GmbH, Wetzlar, Germany).<sup>9,10</sup> An abnormal perimetry was defined as reproducible glaucomatous visual field loss in the absence of any other abnormalities to explain the defect.

Photographs of the optic disc were obtained using a Kowa Wx nonmydriatic fundus retinograph (Kowa Co., Ltd.). Disk boundaries were defined automatically by the fundus camera, using a method essentially based on high reflectance, and checked manually by an expert user. Similarly, the boundary between cup and rim was automatically defined by the fundus camera (VK-2 software version) using a three-dimensional reconstruction of the two images. Finally this boundary was

manually reviewed by the expert by alternately oscillating both images to subjectively verify its depth.

The analysis of 24 sectors of the nerve described previously<sup>1</sup> was used to obtain the Glaucoma discriminant function (GDF) index and estimates of the rim area and vertical cup-to-disc (C/D) ratio. In addition we calculated the relative amount of Hb in the cup and in the six sectors of the rim into which it is usually divided.<sup>11</sup>

The Laguna ON<sub>n</sub>E program has been previously described in detail<sup>1</sup>; it used mathematical algorithms for automatic component segmentation to identify the central retinal vessels and the ONH tissue itself. The program analyzed three components of ONH photographs: blue (B), green (G), and red (R) and applied the formula  $(R - G)/R$  to the pixels of vessels and tissue.<sup>1</sup> The result obtained for the vessels was used as the reference value for calculating the Hb content in the tissue. The  $(R - G)/R$  value was calculated for any area of the tissue, then divided by the  $(R - G)/R$  value for the vessels and the result was multiplied by 100.<sup>12</sup> Thus, a relative measure (percentage) of the amount of Hb in the tissue was obtained. Finally, the influence of the lens status was compensated for by analyzing the differences between the green and blue components before calculating the results of the relative Hb amount. The blue, green, and red components were assessed with an image analysis program using the Matlab image processing toolbox (The MathWorks, Inc., Natick, MA, USA; Fig. 1).

Glaucoma discriminant function, described in the previous work, combined the results of Hb obtained in various regions of the ONH to differentiate between glaucoma and normality.<sup>1</sup> In this new analysis, the GDF index was combined with

**TABLE 1.** Demographic and Clinical Characteristics of Both Study Groups

	Control Group Mean ± SD	Glaucoma Group Mean ± SD	P
Age, y	61.7 ± 13.7	64.7 ± 11.8	0.07*
BCVA (Snellen)	0.99 ± 0.10	0.71 ± 0.25	<0.001*
Rim area (OCT)	1.49 ± 0.36	0.82 ± 0.36	<0.001*
Rim area (stereoscopy)	1.72 ± 0.38	1.43 ± 0.47	<0.001*
C/D (OCT)	0.43 ± 0.17	0.72 ± 0.16	<0.001*
C/D (stereoscopy)	0.42 ± 0.11	0.61 ± 0.16	<0.001*
Average RNFLT (OCT)	92.49 ± 9.27	73.72 ± 18.99	<0.001*
GDFc (Laguna ONhE)	2.76 ± 9.24	-16.59 ± 11.41	<0.001*
MD of Spark perimetry, dB	-0.54 ± 2.06	-10.53 ± 9.02	<0.001*
PSD of Spark perimetry, dB	1.18 ± 0.56	4.26 ± 3.16	<0.001*
Sex (M/F)	40/47	34/37	0.75†
N	87	71	

P < 0.05 was considered statistically significant (in bold). BCVA, best-corrected visual acuity; RNFLT, retinal nerve fiber layer thickness; M/F, male/female; N, number of cases.

\* Student's *t*-test.

†  $\chi^2$  test.

morphologic information obtained by stereopsis (rim area and vertical C/D ratio), labeled GDF combined (GDFc).

The peripapillary retinal nerve fiber layer (RNFL) thickness and ONH parameters (rim area, disc area, cup volume, and vertical C/D ratio) were measured using the optic disc cube 200 × 200 acquisition protocol (software version 5.2) of the Cirrus spectral-domain optical coherence tomography (OCT; Carl Zeiss Meditec, Dublin, CA, USA). Left eye data were converted to a right eye format. All images were acquired with a quality greater than 6/10.

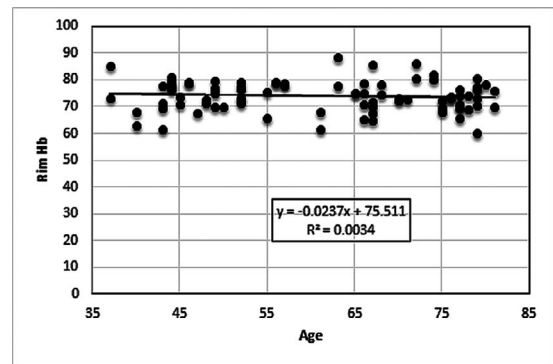
All the ophthalmic examinations, perimetry tests, and morphologic evaluations were performed within 1 month from the subject's date of enrollment in the study.

**Classification Into Groups**

Healthy eyes had an IOP of less than 21 mm Hg, no history of increased IOP, normal optic disc morphology, and normal visual field results. The glaucoma group comprised subjects with POAG, pseudoexfoliative glaucoma, and pigmentary glaucoma. Glaucomatous eyes had focal (localized notching) or diffuse neuroretinal rim narrowing with concentric enlargement of the optic cup, or both, and/or abnormal perimetry, regardless of the IOP values.

**Statistical Analysis**

All statistical analyses were performed using the Statistical software (version 6.0; StatSoft, Inc., Tulsa, OK, USA) and MedCalc (version 7.3; MedCalc software, Mariakerke, Belgium). The areas under the receiver operating characteristic curves (AUCs) were calculated for all parameters of every test. Sensitivities at a fixed specificity close to 95% (5% false positive rate) were compared between the parameters with the largest AUCs. Using the data on Hb in the 24 sectors of the ONH, we estimated the rim area and vertical C/D ratio using stepwise multiple regression. After checking for a normal distribution of the variables, Pearson correlations were also calculated between the structural and functional parameters. When a



**FIGURE 2.** Rim relative Hb amount of healthy subjects according to age.

curvilinear relationship was observed between variables, it was analyzed using the program TableCurve 2D v5.01.05 (Systat, Inc., San Jose, CA, USA).

**RESULTS**

During four weeks in March 2014, we consecutively examined 92 healthy subjects and 75 with confirmed or suspected glaucoma. Five healthy subjects and four in the glaucoma group were excluded for different reasons: four due to very blurred images as a result of intense miosis associated with cataract or not, and five did not complete the testing protocol. Finally, we analyzed 87 healthy eyes and 71 eyes in the glaucoma group. Mean deviation (MD) ± SD of Spark perimetry was -0.54 ± 2.06 dB in healthy subjects and -10.53 ± 9.02 dB in the glaucoma group (Table 1). In 30 subjects of the glaucoma group, MD was higher than -2dB.

We did not observe any variations in the relative amount of Hb in relation to age in the rim of healthy subjects (Fig. 2).

Glaucomatous eyes presented significantly less relative amount of Hb than healthy eyes in the cup and all sectors of the rim (P < 0.05) except the temporal sector (P > 0.11), and especially the inferonasal and superonasal sectors (P < 0.001; Table 2).

For the whole sample, the best correlation between instruments using linear regression was between the Laguna ONhE discriminant function (GDF) and the OCT C/D ratio. (Table 3).

Good correlation (R<sup>2</sup> = 0.62-0.64, P < 0.001) was observed between OCT vertical C/D ratio values and those estimated from Hb values and those obtained using stereoscopic Kowa

**TABLE 2.** Relative Amount (Percentage) of Hemoglobin (Mean ± SD) in the Cup and Six Sectors of the Rim

Sector	Normal, %	Glaucoma, %	P*
Hb cup	62.1 ± 10.1	57 ± 10.7	<b>0.001</b>
Hb rim (121°-230°)	78.3 ± 6.9	75.9 ± 9.1	0.04
Hb rim (231°-270°)	78.9 ± 6.5	74.2 ± 10.1	<b>0.0005</b>
Hb rim (271°-310°)	71.2 ± 6.6	67 ± 10.2	<b>0.002</b>
Hb rim (311°-40°)	61.3 ± 7.8	63 ± 9.4	0.11
Hb rim (41°-80°)	72.8 ± 6.8	69.2 ± 11.5	0.01
Hb rim (81°-120°)	81.9 ± 6.6	76.9 ± 9.7	<b>0.0002</b>

P < 0.008 was considered statistically significant including a Bonferroni correction (in bold). Hb, relative amount of hemoglobin in the sector (%).

\* Student's *t*-test.



TABLE 3. Coefficients of Determination ( $R^2$ ) Between Different Indices in the Whole Sample

	Hb Total	Hb Sup.+Inf.	Hb+Kowa GDF	OCT Rim Area	OCT C/D	OCT Thickness	VF DM
Hb Sup.+Inf.	0.799						
GDF	0.105	0.109					
OCT rim area	0.094	0.049	0.497				
OCT C/D	0.208	0.123	0.536	0.648			
OCT thickness	0.138	0.129	0.282	0.393	0.334		
VF DM	0.321	0.412	0.402	0.376	0.387	0.323	
VF PSD	0.148	0.178	0.356	0.317	0.320	0.249	0.623

$P < 0.001$  for all comparisons. Sup.+Inf., average superior and inferior sectors.

images (Fig. 3). The correlation of rim area for the same comparisons was  $R^2 = 0.44$  and  $R^2 = 0.24$  ( $P < 0.001$ ).

The relation between the perimetric indices mean sensitivity (MS) or MD and some morphologic parameters is really curvilinear. Using normalized values of MS, GDFc, and OCT rim area with respect to their mean value and SD of the total sample, the relation of MS with the other two indices is similar in both cases, and the relation between the simpler formulas proposed by TableCurve could be as follows:

$$\text{OCT rim area or GDFc} = 1.5 + 1.07 \times e^{MS}. \quad (1)$$

The coefficients of determination using this type of adjustment were  $R^2 = 0.48$  between MS and GDFc, and  $R^2 = 0.53$  between MS and OCT rim area (Fig. 4).

Dividing the visual field<sup>13</sup> into regions corresponding to sectors of the rim, the mean visual field deviations of each region correlated better with relative Hb amounts than with the respective rim areas of each sector or the corresponding thickness of nerve fiber layer, especially in the superior and inferior sectors ( $P < 0.05$ ; Fig. 5).

On selective analysis of glaucoma patients, significant correlation was observed between mean Hb and the superior and inferior rim sectors and MD ( $R^2 = 0.58$ ;  $P < 0.0001$ ; Fig. 6), with pattern standard deviation (PSD;  $R^2 = 0.181$ ,  $P = 0.0002$ ) and with RNFL thickness ( $R^2 = 0.103$ ,  $P = 0.006$ ). Glaucoma discriminant function combined showed high linear correla-

tion with OCT vertical C/D ratio ( $R^2 = 0.450$ ,  $P < 0.0001$ ) and with rim area ( $R^2 = 0.300$ ,  $P < 0.0001$ ).

Confidence intervals (CIs) of the receiver operating characteristic (ROC) areas showed maximum values for a combination between discriminant function GDFc of Laguna ONhE and the indices MD and PSD of Spark perimetry, using the formula  $(\text{GDFc} \times 2) + (\text{PSD} \times -5) + \text{MD}$ . However, the estimated CIs presented overlapping with those obtained using various morphologic and functional indices, such as OCT rim area, MD, or GDFc. Therefore, with this sample size, we cannot affirm statistically significant differences between these indices (Table 4).

## DISCUSSION

Simultaneous stereoscopic images obtained with the Wx Kowa fundus camera allow cup and rim segmentation and are applicable to the topographic measurement of Hb without recourse to any other instrument. Vertical C/D ratio seems to have greater diagnostic capacity than rim area using stereoscopic images, possibly because the horizontal plane of image capture favors the perception of depth in a vertical direction.

The combination of Hb data with vertical C/D ratio values allowed us to obtain a combined GDFc index with a wide range and whose cut-off may be adjusted, taking into account the results of this study, to provide positive values in normal situations and negative results in glaucoma. The association between this index, which includes morphologic and perfusion information, with two perimetric indexes, in an equation with different weights, seems to have slightly better diagnostic ability. These results need to be confirmed in an independent set of data and will be published in another paper.

Numerous comparative studies have been performed to compare the relationship between visual field sensitivity and morphologic indices, using confocal tomography (Heidelberg Retina Tomograph; HRT),<sup>14-16</sup> scanning laser polarimetry (GDx),<sup>17-21</sup> or OCT.<sup>22-26</sup> The absorption of Hb at 570 nm correlated well with the differences in sensitivity between the upper and lower visual fields.<sup>6</sup>

Our results seem to show that function is better related with the relative amount of Hb in blood irrigating the retinal nerve fiber layer than with its thickness or its area. This aspect seems of interest because it may indicate that reduced perfusion precedes tissue atrophy. This assumption seems reasonable from a physiological point of view and is reinforced by the observation that in many cases of glaucoma the remaining rim has insufficient perfusion, although it is possible that once established the damage is irreversible, even if perfusion improves. This would occur, for example, on activation of apoptotic mechanisms.

In addition, this relationship is not curvilinear, as found on comparing function with many morphologic indices, but has a

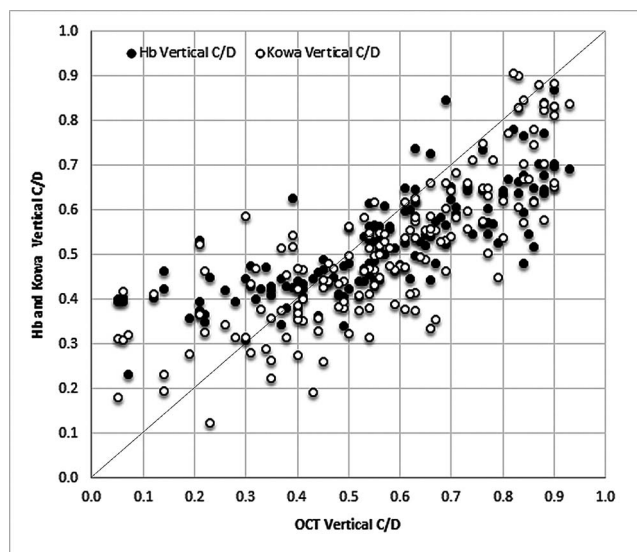


FIGURE 3. Relation between vertical C/D ratio obtained by OCT, that measured by stereoscopic images and that estimated from Hb values.

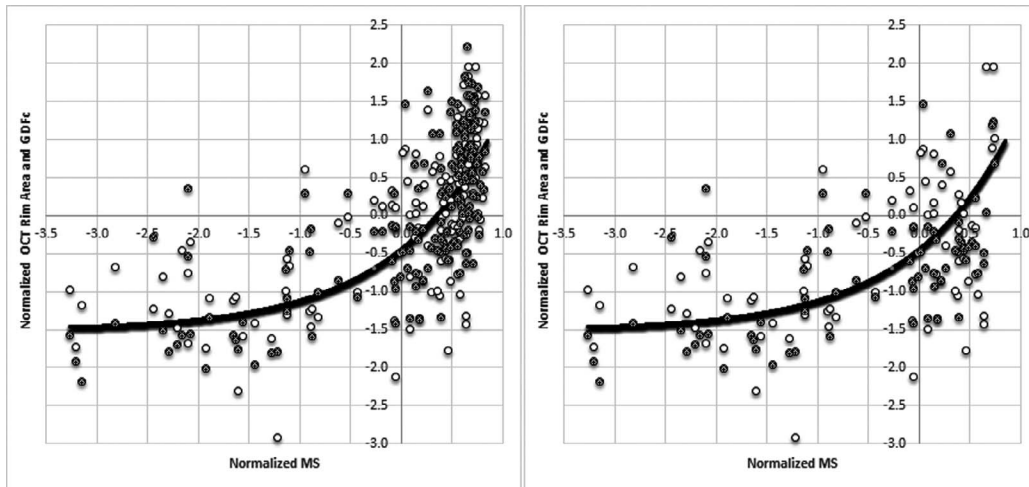


FIGURE 4. Relation between normalized values of mean sensitivity (MS), OCT rim area (gray), and GDFc of the Laguna ONhE program (white) showing an approximately curvilinear fit for both relations (curve). Left: All cases. Right: Without normal cases.

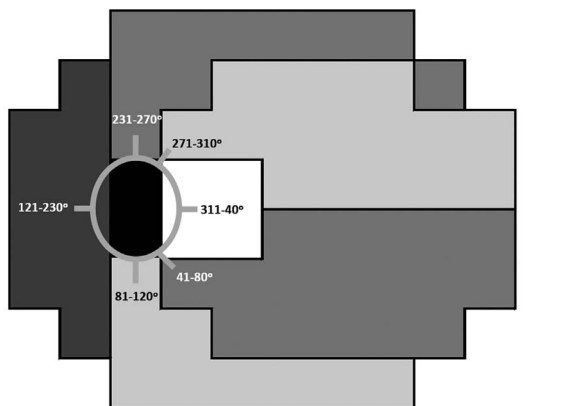
linear appearance, so it appears not to suffer a collapse in the advanced stages of the disease, as with morphologic indices.

This hypothesis opens interesting avenues of study for the future, since it appears that the progression of the disease may have a dependency relationship with Hb levels observed in the optic nerve, especially in the superior and inferior regions of the neuroretinal rim. If this hypothesis is confirmed, the test model we propose could provide information about the stability of the disease process, thus acquiring interesting prognostic value.

It is interesting to compare our results with those recently published in a study involving a new technique of OCT angiography.<sup>27</sup> The differences between the data obtained in that study compared with ours may be explained by the small sample size of patients analyzed with this new OCT and also by the completely different population samples studied. They must therefore be considered with caution but, on the other hand, we believe they deserve exposure since these two procedures have relatively similar objectives. However, with all the above mentioned reservations, our method appears to show a greater relationship with other morphologic and functional indices of glaucoma than the recently described OCT angiography. A comparison using both procedures on the same patients would be required to rigorously describe their differences.

Other important issues for the future may be the specific assessment of normal-pressure glaucoma or longitudinal glaucoma studies that allow evaluating the prognostic value of the method, and comparisons with other methods to analyze perfusion.

Finally, we would mention that promising studies have been initiated using Laguna ONhE for other diseases that cause damage to the optic nerve. Interesting results have been



SECTOR	Coefficients of determination (R <sup>2</sup> )			P value	
	Rim Area Vs MS	Hb Vs MS	Thickness Vs MS	A Vs B	B Vs C
231-270°	0.12	0.35	0.11	0.004	0.004
271-310°	0.14	0.30	0.05	0.043	0.001
41-80°	0.12	0.34	0.15	0.004	0.019
81-120°	0.15	0.39	0.01	0.006	0.000
311-40°	0.11	0.03	0.08	0.160	0.300
121-230°	0.09	0.23	0.05	0.060	0.010

FIGURE 5. Sectors of the rim and those corresponding to the visual field (left). Coefficients of determination (R<sup>2</sup>) between mean sensitivity (MS) of each region with rim area, thickness of the nerve fiber layer and the relative amount of Hb of the sector corresponding to the rim (right). P value calculated using Student's *t*-test.

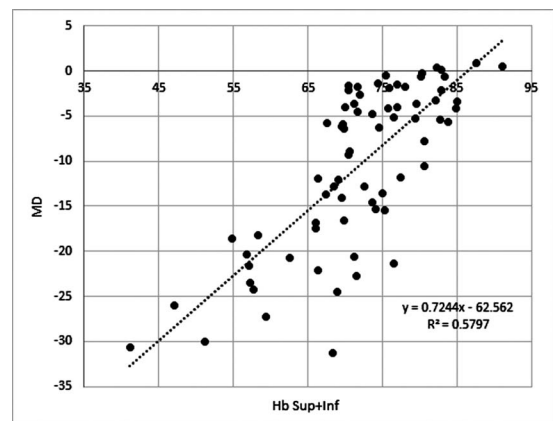


FIGURE 6. Relation between MD and the relative amount of Hb in the superior and inferior sectors of the rim in subjects with glaucoma.

TABLE 4. Results of ROC Analysis: ROC Area Confidence Intervals, Sensitivity for a Specificity of 95.4%

	ROC Area	CI 0.95	CI 0.05	Sensitivity (Specificity 95.4%)	P*
(GDFc × 2) – (PSD × 5) + MD	0.935	0.97	0.899	74.6	1.10E–22
OCT rim area	0.922	0.96	0.883	77.46	4.40E–23
MD	0.901	0.944	0.857	63.38	3.50E–14
OCT C/D	0.899	0.942	0.855	64.79	2.40E–21
GDFc	0.896	0.94	0.851	67.14	4.20E–22
PSD	0.895	0.939	0.85	61.43	4.50E–12
Hb C/D	0.855	0.907	0.803	56.34	1.40E–15
Kowa C/D	0.825	0.881	0.769	64.79	3.60E–13
Hb rim área	0.818	0.875	0.761	61.97	2.20E–13
OCT RNFLT	0.803	0.862	0.744	54.93	8.50E–12
Kowa rim area	0.679	0.75	0.608	30.99	2.40E–05
Hb total average	0.654	0.726	0.581	21.13	1.70E–04

\* Student's *t*-test.

published in multiple sclerosis<sup>28</sup> and progress is being made in the study of other diseases such as Parkinson's and Alzheimer's.

### Acknowledgments

Supported in part by Grant PI12/02307 of the Instituto de Salud Carlos III with European Regional Development funds, and Doctoral Scholarship AP2012-6800 of the Spanish Government (Madrid, Spain). The Insoft SL company contributed to the development of software.

Disclosure: C. Pena-Betancor, None; M. Gonzalez-Hernandez, Insoft SL (I); F. Fumero-Batista, None; J. Sigut, None; E. Medina-Mesa, None; S. Alayon, None; M. Gonzalez de la Rosa, Insoft SL (I), P

### References

- Gonzalez de la Rosa M, Gonzalez-Hernandez M, Sigut J, et al. Measuring hemoglobin levels in the optic nerve head: comparisons with other structural and functional parameters of glaucoma. *Invest Ophthalmol Vis Sci.* 2013;54:482–489.
- Michelson G1, Langhans MJ, Groh MJ. Clinical investigation of the combination of a scanning laser ophthalmoscope and laser Doppler flowmeter. *Ger J Ophthalmol.* 1995;4:342–349.
- Yaoeda K, Shirakashi M, Funaki S, Funaki H, Nakatsue T, Abe H. Measurement of microcirculation in the optic nerve head by laser speckle flowgraphy and scanning laser Doppler flowmetry. *Am J Ophthalmol.* 2000;129:734–739.
- Jia Y, Tan O, Tokayer J, et al. Split-spectrum amplitude-decorrelation angiography with optical coherence tomography. *Opt Express.* 2012;20:4710–4725.
- Denniss J. Estimation of hemoglobin levels in the optic nerve head for glaucoma management. *Invest Ophthalmol Vis Sci.* 2013;54:1515.
- Denniss J, Schiessl I, Nourrit V, Fenerty CH, Gautam R, Henson DB. Relationships between visual field sensitivity and spectral absorption properties of the neuroretinal rim in glaucoma by multispectral imaging. *Invest Ophthalmol Vis Sci.* 2011;52:8732–8738.
- Gonzalez de la Rosa M, Gonzalez-Hernandez M, Sigut J, et al. Author response: estimation of hemoglobin levels in the optic nerve head for glaucoma management. *Invest Ophthalmol Vis Sci.* 2013;54:2011–2012.
- Han J, Cho SY, Kang KD. Correlation between optic nerve parameters obtained using 3D nonmydriatic retinal camera and optical coherence tomography: interobserver agreement on the disc damage likelihood scale. *J Ophthalmol.* 2014;2014:931738.
- de la Rosa MG, Gonzalez-Hernandez M. A strategy for averaged estimates of visual field threshold: Spark. *J Glaucoma.* 2013; 22:284–289.
- Gonzalez de la Rosa M, Gonzalez-Hernandez M, Sanchez-Garcia M, Rodriguez de la Vega R, Diaz-Aleman T, Rios AP. OCULUS-SPARK perimetry compared with three procedures of glaucoma morphologic analysis (GDx, HRT and OCT). *Eur J Ophthalmol.* 2013;23:316–323.
- Garway-Heath DE, Poinoosawmy D, Fitzke FW, Hitchings RA. Mapping the visual field to the optic disc in normal tension glaucoma eyes. *Ophthalmology.* 2000;107:1809–1815.
- Dill DB, Costill DL. Calculation of percentage changes in volumes of blood, plasma, and red cells in dehydration. *J Appl Physiol.* 1974;37:247–248.
- Gonzalez de la Rosa M, Gonzalez Hernández M, Aguilar Estevez J, Abreu Reyes A, Pareja Ríos A. Clasificación topográfica del campo visual glaucomatoso. *Arch Soc Esp Ophthalmol.* 2002;77:87–94.
- Gardiner S, Johnson ChA, Cioffi GA. Evaluation of the structure-function relationship in glaucoma. *Invest Ophthalmol Vis Sci.* 2005;46:3712–3717.
- de la Rosa MG, Gonzalez-Hernandez M, Lozano-Lopez V, et al. Optic disc tomography and perimetry in controls, glaucoma suspects, and early and established glaucomas. *Optom Vis Sci.* 2007;84:33–41.
- Reus NJ, Lemij HG. Relationships between standard automated perimetry, HRT confocal scanning laser ophthalmoscopy, and GDx VCC scanning laser polarimetry. *Invest Ophthalmol Vis Sci.* 2005;46:4182–4188.
- Iester M, Perdicchi A, De Feo F, et al. Comparison between GDx VCC parameter and achromatic perimetry in glaucoma patients. *J Glaucoma.* 2006;15:281–285.
- Schlottmann PG, De Cilla S, Greenfield DS, et al. Relationship between visual field sensitivity and retinal nerve fiber layer thickness as measured by scanning laser polarimetry. *Invest Ophthalmol Vis Sci.* 2004;45:1823–1829.
- Horn FK, Mardin CY, Viestenz A, et al. Association between localized visual field losses and thickness deviation of the nerve fiber layer in glaucoma. *J Glaucoma.* 2005;14:419–425.
- Bowd C, Tavares IM, Medeiros FA, et al. Retinal nerve fiber layer thickness and visual sensitivity using scanning laser polarimetry with variable and enhanced corneal compensation. *Ophthalmology.* 2007;114:1259–1265.
- Mai TA, Reus NJ, Lemij HG. Structure-function relationship is stronger with enhanced corneal compensation than with variable corneal compensation in scanning laser polarimetry. *Invest Ophthalmol Vis Sci.* 2007;48:1651–1658.

22. Takagishi M, Hirooka K, Baba T, et al. Comparison of retinal nerve fiber layer thickness measurements using time domain and spectral domain optical coherence tomography, and visual field sensitivity. *J Glaucoma*. 2011;20:383-387.
23. Nilforushan N, Nassiri N, Moghimi S, et al. Structure-function relationships between spectral-domain OCT and standard achromatic perimetry. *Invest Ophthalmol Vis Sci*. 2012;53:2740-2748.
24. Leite MT, Zangwill LM, Weinreb RN, et al. Structure-function relationships using the Cirrus spectral domain optical coherence tomograph and standard automated perimetry. *J Glaucoma*. 2012;21:49-54.
25. Aptel F, Sayous R, Fortoul V, et al. Structure-function relationships using spectral-domain optical coherence tomography: comparison with scanning laser polarimetry. *Am J Ophthalmol*. 2012;150:825-833.
26. Cvenkel B, Kontestabile AS. Correlation between nerve fibre layer thickness measured with spectral domain OCT and visual field in patients with different stages of glaucoma. *Graefes Arch Clin Exp Ophthalmol*. 2011;249:575-584.
27. Jia Y, Wei E, Wang X, et al. Optical coherence tomography angiography of optic disc perfusion in glaucoma. *Ophthalmology*. 2014;121:1322-1332.
28. Bambo MP, Garcia-Martin E, Perez-Olivan S, et al. Diagnostic ability of a new method for measuring haemoglobin levels in the optic nerve head in multiple sclerosis patients. *Br J Ophthalmol*. 2013;97:1543-1548.