

Quantitative Evaluation of Phase Retardation in Filtering Blebs Using Polarization-Sensitive Optical Coherence Tomography

Shinichi Fukuda,^{1,2} Akari Fujita,¹ Deepa Kasaragod,^{2,3} Yuta Ueno,¹ Sujin Hoshi,¹ Genichiro Kishino,¹ Simone Beheregaray,¹ Yoshiaki Yasuno,^{2,3} and Tetsuro Oshika^{1,2}

¹Department of Ophthalmology, Faculty of Medicine, University of Tsukuba, Ibaraki, Japan

²Computational Optics and Ophthalmology Group, Ibaraki, Japan

³Computational Optics Group, University of Tsukuba, Ibaraki, Japan

Correspondence: Shinichi Fukuda, Department of Ophthalmology, Institute of Clinical Medicine, University of Tsukuba, 1-1-1 Tennoudai, Tsukuba, Ibaraki 305-8575, Japan; caesar.shiizu@gmail.com.

SF and AF contributed equally to the work presented here and should therefore be regarded as equivalent authors.

Submitted: March 11, 2016

Accepted: October 7, 2016

Citation: Fukuda S, Fujita A, Kasaragod D, et al. Quantitative evaluation of phase retardation in filtering blebs using polarization-sensitive optical coherence tomography. *Invest Ophthalmol Vis Sci.* 2016;57:5919-5925. DOI:10.1167/iov.16-19548

PURPOSE. Polarization-sensitive optical coherence tomography (PS-OCT) can detect and evaluate scar fibrosis of the filtering blebs after glaucoma surgery. Although the change in phase retardation reportedly reflects bleb function, quantitative assessment of phase retardation in ocular tissues has not been conducted. We aimed to establish quantitative methods to investigate changes in phase retardation in the blebs after surgery using PS-OCT.

METHODS. Twenty-two blebs of 22 patients who had undergone glaucoma filtration surgery were consecutively examined for 4 months. Phase retardation was measured by PS-OCT and quantitatively analyzed to evaluate its relationship with bleb function based on intraocular pressure and medication use. Cross-sectional re-evaluation was also performed for a previous data set of 153 blebs of 122 patients.

RESULTS. In consecutive measurements, all blebs showed a low phase retardation value and good bleb function until 2 weeks. One month postoperatively, the phase retardation value was significantly increased, whereas bleb function was still good. The phase retardation value at 1 month postoperatively was significantly correlated with bleb function at 4 months postoperatively. While 55.6% of blebs with a high phase retardation value at 1 month subsequently lost function, only 7.7% with a low phase retardation value had bleb failure. In the cross-sectional re-evaluation, the quantitatively evaluated phase retardation value was highly correlated with bleb function ($\beta = 0.770$, $P < 0.001$).

CONCLUSIONS. An increase in phase retardation preceded deterioration of bleb function. The change in phase retardation may provide a prognostic metric for bleb function in the early stage after surgery.

Keywords: phase retardation, polarization-sensitive optical coherence tomography, scar fibrosis of the filtering bleb

Trabeculectomy has been the most common filtration surgery to decrease intraocular pressure for medically uncontrollable glaucoma since its introduction by Cairns in 1968.¹ Because of its relatively high success rate, it is the standard technique among the surgical modalities available for open-angle glaucoma.² Shunt surgery using a nonvalved implantable drainage device (EX-PRESS Glaucoma Filtration Device; Alcon Laboratories, Fort Worth, TX, USA) is another option for glaucoma surgery. This device was approved by the US Food and Drug Administration in 2002 and has been widely utilized in recent years.³ The main causes of failure for both trabeculectomy and shunt surgery with a nonvalved implantable drainage device (Alcon Laboratories) include excessive postoperative conjunctival fibrosis and scarring at the site of the filtering bleb.^{4,5} Intraoperative application of antimetabolic agents such as mitomycin C and 5-fluorouracil reportedly improves the outcome of filtration surgery.⁶⁻⁸ Prevention of bleeding, reduction of inflammation, and use of cytokine suppressing agents are other methods of controlling the fibrosis and scarring process.

Postoperative filtering bleb is primarily evaluated by color photographs and slit-lamp biomicroscopy.⁹⁻¹¹ It was recently considered that the structure within a bleb is also important to assess its function. Several studies have reported that ultrasound biomicroscopy (UBM), in vivo confocal microscopy, and anterior segment optical coherence tomography (AS-OCT) can image the structures inside a filtering bleb.¹²⁻¹⁴ Ultrasound biomicroscopy uses ultrahigh-frequency acoustic waves that obtain structural information upon reflection, while conventional OCT utilizes the intensity of infrared light backscattered from tissue structures. However, neither modality can directly evaluate tissue fibrosis and scarring.

Polarization-sensitive (PS) OCT extends the concept of OCT: it is capable of noninvasively obtaining morphologic and birefringence information.¹⁵ Abnormal collagen, such as that in fibrosis and scarring, has strong birefringence.¹⁶⁻¹⁸ Polarization-sensitive OCT utilizes this optical property seen in organized structures of collagen fibers to directly contrast the fibrotic tissues. We recently demonstrated a high correlation between phase retardation alteration and bleb function in a



large-scale study.¹⁹ We also found that an increase in the intraocular pressure (IOP) was preceded by an alteration of phase retardation. Moreover, this alteration of phase retardation seemed to occur between 1 week and 1 month postoperatively.¹⁹

Phase retardation is a relative delay of two orthogonal states of light that accumulates as it traverses through a birefringent material. Thus, the phase retardation measured by PS-OCT accumulates from the tissue surface to the imaging point along the depth. Because it is easy to detect both the anterior and posterior corneal surfaces, we quantitatively evaluated corneal phase retardation using an en face phase retardation map.^{20,21} In that study, the phase retardation measured at the posterior surface of the cornea, which accumulates from the anterior to posterior surfaces, was analyzed in an en face manner. However, it is challenging to obtain an en face phase retardation map of a bleb. In the case of blebs, it is occasionally difficult to establish a clear boundary between bleb and sclera. Also, for obtaining the en face phase retardation images of the bleb, manual segmentation of all the 128 b-scans is required, which can be extremely time consuming. As the phase retardation represents cumulative information, the phase retardation images are influenced by the tissue thickness. The cornea did not have a large variation of thickness. On the other hand, there is a great variation in the bleb, such as flat bleb and encapsulation. It does make interpretation of bleb en face images very difficult. In our previous bleb study, the phase retardation of the bleb was only qualitatively graded into three groups according to the increase in the phase retardation.¹⁹ Thus, it was difficult to evaluate small changes in phase retardation in the postoperative period.

In this study, we quantitatively evaluated the postoperative alteration in the phase retardation of filtering blebs in the early postoperative period. We also reanalyzed the relationship between the mean phase retardation value of blebs and its function using our previous large-scale data set.¹⁹

PATIENTS AND METHODS

In total, 22 blebs from 22 patients (14 men, 8 women) undergoing trabeculectomy or tube shunting (Alcon Laboratories) were evaluated. The mean age \pm standard deviation of the participants was 64.7 ± 9.6 years. The research followed the tenets of the Declaration of Helsinki, and written informed consent was obtained from each participant. The study was approved by the Institutional Review Board of Tsukuba University. Blebs were evaluated using three-dimensional (3D) corneal and AS-OCT (CAS-OCT, CASIA; Tomey Corporation, Aichi, Japan) and PS-OCT at 1 day, 1 week, 2 weeks, 1 month, 2 months, and 4 months postoperatively.

To compare subjective analysis and objective analysis for phase retardation, we reanalyzed the data set of our previous study.¹⁹ One hundred and fifty-three blebs of 122 patients (68.0 ± 12.7 years) that had undergone trabeculectomy or a tube shunt (Alcon Laboratories) were included.

Trabeculectomy

All trabeculectomy procedures were performed using a fornix-based conjunctival flap. A 4-mm wide half-layer square scleral flap was created, and topical 0.04% mitomycin C was applied between the sclera and Tenon's capsule for 3 minutes with a cellulose sponge. After 3 minutes, the sponge was removed and the entire surgical field was irrigated thoroughly with 200 mL of balanced saline solution. A trabecular block was excised, and a peripheral iridectomy was performed. The scleral flap was closed with four interrupted 10-0 nylon sutures, and the

conjunctiva was closed tightly with interrupted 10-0 nylon sutures.

Tube Shunt

The tube shunt (Alcon Laboratories) was inserted into the anterior chamber through a scleral tunnel under a half-thickness 4-mm wide half-layer square scleral flap followed by closure with three interrupted 10-0 nylon sutures. The scleral tunnel was created by anterior chamber paracentesis with a 27-gauge needle at the anterior edge of the scleral spur that ran parallel to the iris plane. Topical 0.04% mitomycin C was applied as for trabeculectomy. The scleral and conjunctival flaps were sutured with 10-0 nylon.

Polarization Sensitive OCT

A custom-made 3D anterior segment PS-OCT based on the Jones-matrix OCT principle was built by the Computational Optics Group (University of Tsukuba, Tsukuba, Japan) and utilized in this study.²² The Jones matrix OCT requires use of two input polarization states of light for full recovery of the Jones matrix of the sample. The effect of system birefringence, including that of optical fibers, was cancelled by multiplying the tissue Jones matrix by the inverse of the Jones matrix from a reference surface, which was the air-tissue interface in the present study. The eigenvalue of the multiplied Jones matrix is computed at each point of the Jones matrix OCT image, and the phase retardation is obtained as the phase difference between these two eigenvalues. In our method, the phase retardation is defined over the range 0 to π radians. Also, the system is based on swept-source OCT technology with an operating wavelength of 1.3 μm and measurement speed of 30,000 A-lines/s. In addition to conventional OCT images, PS-OCT provides the microstructural properties of the tissue by revealing its birefringent property. The phase retardation can be utilized as an indirect measure of birefringence. The phase retardation is defined as the phase difference induced by the tissue birefringence. It is a cumulative quantity, which is affected by the birefringence of the tissue along the entire depth of the light propagation. The polarization-sensitive OCT system used in this study has been described in detail elsewhere.²³

Blebs were scanned with a horizontal-fast raster pattern with a scanning range of 12×12 mm, consisting of 512 horizontal \times 128 vertical A-lines, using PS-OCT. Blebs were scanned at least twice, and the best image was selected for subsequent analyses. Each PS-OCT image was measured by one of three experienced ophthalmologists (SF, SH, GK).

A whole bleb was scanned with a horizontal-fast raster scan protocol, and perfectly coregistered phase retardation and scattering OCT were computed from the same scan data. The cross-sectional OCT images of the superior and inferior ends of the bleb were manually selected, and the position of these ends was double-checked by an anterior photograph. Three evenly spaced cross-sections were additionally selected between the superior and the inferior ends. In these five OCT cross-sections, the transversal extent with thickened conjunctiva was selected as transversal region of the bleb. If the bleb was flat, the whole transversal extent of the cross-sectional image was selected as the bleb region, alternatively. The scleroconjunctival boundary within the transversal bleb region was then manually delineated and the area above this boundary was selected as a cross-sectional bleb area. This area selection was performed by an experienced ophthalmologist (SF) by using multipurpose image processing and analysis software, ImageJ (<http://imagej.nih.gov/ij/>; provided in the public domain by the National Institutes of Health, Bethesda, MD,

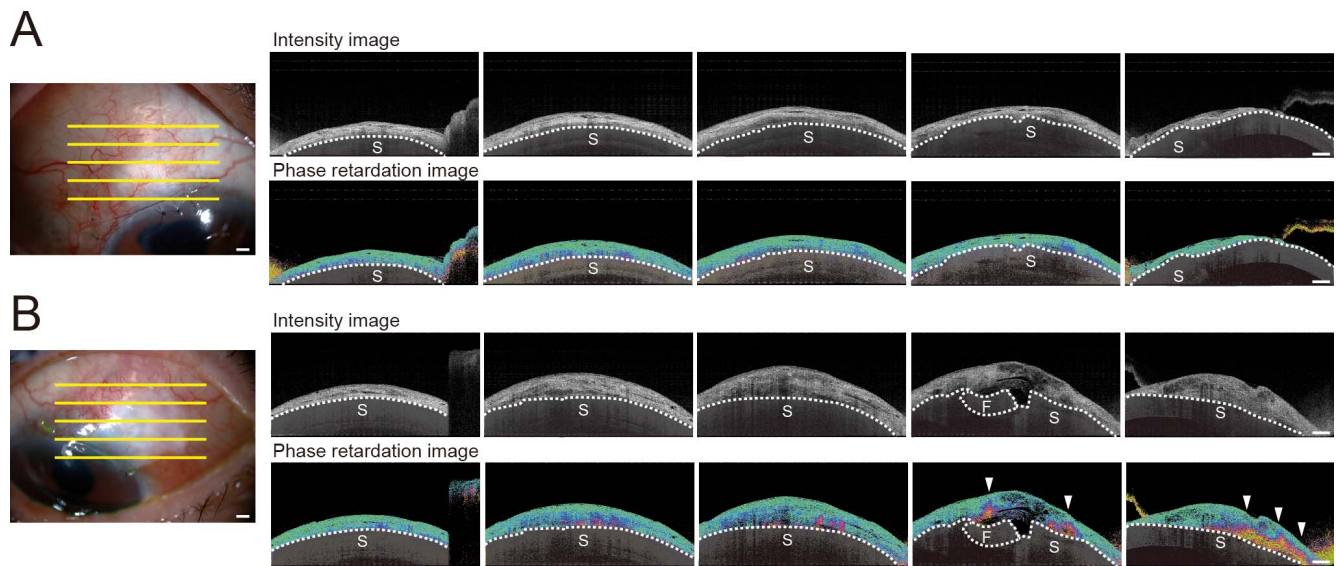


FIGURE 1. The representative two cases of good bleb function. Photographs, intensity images, phase retardation images, and grayscale-converted phase retardation images with PS-OCT. Sclera was also manually covered with a semitransparent black shadow. Dotted line indicates boundary between conjunctiva and sclera. (A) A 70-year-old male 4 months after trabeculectomy had an IOP of 8 mm Hg without hypotensive medications. No abnormal phase retardation was found in conjunctiva. (B) A 60-year-old male 4 months after trabeculectomy had an IOP of 12 mm Hg without hypotensive medications. Arrow indicates irregular and abnormal phase retardation. F, sclera flap; S, sclera. Scale bars: 1 mm.

USA). This process is exemplified in Supplementary Figure S1. The mean of the phase retardation of the bleb was finally computed within the bleb areas over the five cross-sections. This computation was performed by using numeric phase retardation values in a 32-bit precision floating point ranged from 0 to π radians. The Supplementary Figure S2 shows an example of a phase retardation cross-sectional image. Strong alteration of the phase retardation at the sclera is evident. Because this scleral birefringence was not used for our analysis but instead disturbed the subjective image reading, the scleral region was masked in the following figures.

3D CAS-OCT Morphologic Parameters

The morphologic characteristics of the bleb, such as the horizontal and vertical lengths of the internal fluid-filled cavity, height of the internal fluid-filled cavity, maximum and minimum bleb wall thickness, total bleb height, volume of the internal fluid-filled cavity, volume of the hyporeflexive area, number of microcysts, rate of lake under the scleral flap, and rate of filtration opening on the scleral flap were evaluated using 3D CAS-OCT as described previously.^{14,19}

Bleb Functionality

The functionality of the bleb was classified based on IOP and hypotensive medications. Bleb function was defined as “good” if IOP ≤ 14 mm Hg without hypotensive medication; “moderate” if 14 mm Hg $<$ IOP ≤ 18 mm Hg without glaucoma medication; and “poor” if IOP $>$ 18 mm Hg or if hypotensive medication had been prescribed to decrease an IOP of $>$ 18 mm Hg on two consecutive postoperative visits.

Multiple Regression Analyses

The mean phase retardation value was used for reanalysis of 153 blebs from the data set of our previous study.¹⁹ Multiple regression analyses were performed for all 153 blebs to investigate the relationship between these parameters and bleb function. Explanatory variables were age, period after the

operation, phase retardation value, and 3D CAS-OCT morphologic parameters.

Statistical Analysis

The relationships between the change in the phase retardation value and bleb function were analyzed using Spearman’s rank correlation test. We performed 1-way ANOVA to compare phase retardation at each time point after surgery. Associations were considered statistically significant if $P < 0.05$. The analyses were carried out using a commercial software package (StatView, version 5.0; SAS, Inc., Cary, NC, USA). Receiver operating characteristic (ROC) curve analyses were performed to determine the cutoff point of the early postoperative phase retardation value for prediction of bleb function. If bleb function was moderate or poor at 4 months after surgery, it was considered positive for ROC analysis. If bleb function was good at 4 months after surgery, it was considered negative for ROC analysis. The area under the ROC curve (AUC) was also calculated. We performed ROC analysis using statistical software (SPSS, version 19.0; IBM Corp., Armonk, NY, USA).

RESULTS

Postoperative Change in Phase Retardation

Figure 1A shows the intensity and phase retardation images of a functional bleb in which the intensity and phase retardation images were simultaneously acquired by PS-OCT. The patient was a 70-year-old male 4 months after trabeculectomy, and his IOP was 8 mm Hg without hypotensive medications. The white dotted line represents the manually delineated boundary between the conjunctiva and sclera. In the cross-sectional images, the scleral region is shaded dark gray to highlight the conjunctival region. The bleb height was not high, and there was no large fluid pool; however, the conjunctiva included the vast green (low phase retardation) region in the phase retardation image, which indicates low birefringence. Although the hyporeflexive area was small, many multiple microcysts were observed in the intensity images (Fig. 1A).

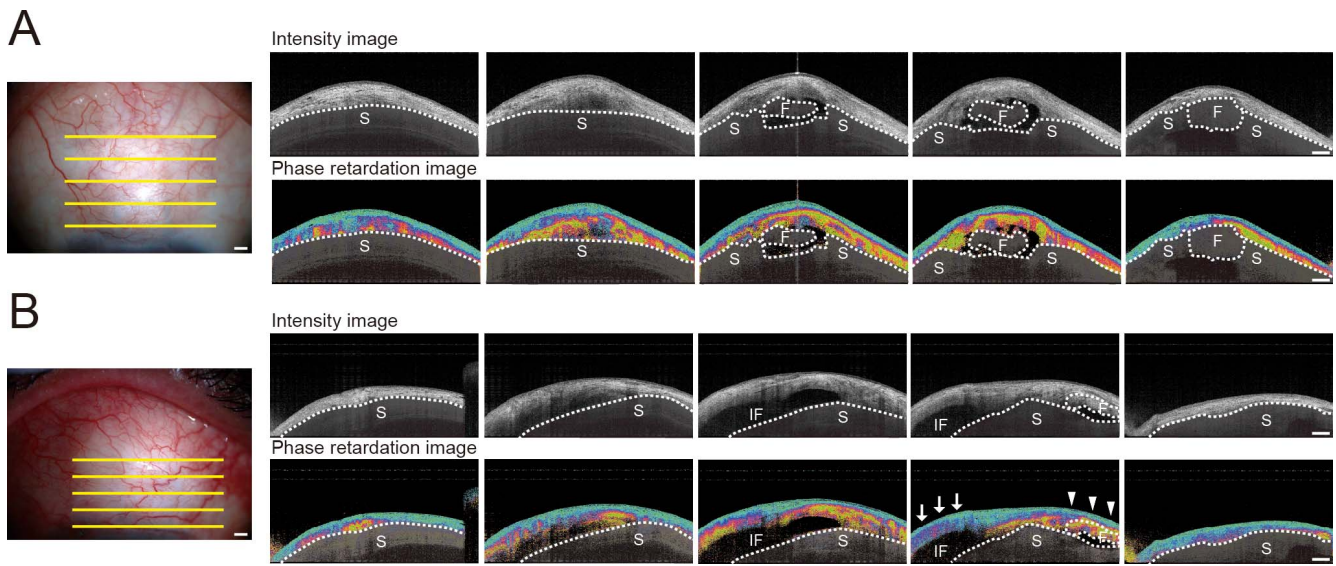


FIGURE 2. The representative two cases of poor bleb function. Photographs, intensity images, phase retardation images, and grayscale-converted phase retardation images with PS-OCT. Sclera was also manually covered with semitransparent black shadow. *Dotted line* indicates boundary between conjunctiva and sclera. (A) A 69-year-old male 4 months after trabeculectomy had an IOP of 17 mm Hg with hypotensive medications. (B) Another case is a 63-year-old male 4 months after trabeculectomy who had an IOP of 18 mm Hg with hypotensive medications. Large fluid pool was covered with irregular and abnormal phase retardation except for the part indicated with an *arrow*. The filtration opening could not be observed and sclera flap was covered with high phase retardation bleb wall (*arrowhead*). F, sclera flap; IF, internal fluid pool; S, sclera. *Scale bars*: 1 mm.

Another example of a functional bleb is shown in Figure 1B. The patient was a 60-year-old man 4 months after trabeculectomy. He had an IOP of 12 mm Hg without hypotensive medications. The bleb had a filtration opening on the scleral flap. Phase retardation was partially increased in the bleb wall as indicated by the white arrowheads.

Two cases of poorly functioning blebs are shown in Figures 2A and 2B. A 69-year-old man 4 months after trabeculectomy had an IOP of 17 mm Hg with hypotensive medications. The bleb had a filtration opening on the scleral flap; however, it was covered by the bleb wall with irregular and abnormal phase retardation (Fig. 2A). In our previous paper, the conjunctiva of normal patients showed low and uniform phase retardation.¹⁹ Hence, we regard the strong alteration of phase retardation shown in Figure 2A as abnormal phase retardation. In the other case, a 63-year-old man 4 months after trabeculectomy had an IOP of 18 mm Hg with hypotensive medications (Fig. 2B). In this bleb, a large fluid pool was observed; however, the region of the bleb wall around the fluid pool was covered with irregular and abnormal phase retardation, excluding the part indicated by arrows. The filtration opening could not be observed, and the scleral flap

was covered with a high phase retardation bleb wall (*arrowhead*). Large and tall blebs do not necessarily show good bleb function.

All blebs showed low phase retardation values and good bleb function until 2 weeks postoperatively. Phase retardation tended to increase 2 weeks postoperatively but was not significant. The phase retardation value was significantly higher 1 month postoperatively than 1 day postoperatively, yet bleb function was still good (Figs. 3, 4). The phase retardation values of the bleb at 2 and 4 months postoperatively were also significantly higher than 1 day after surgery (Fig. 3). In total, 18.2% and 9.1% of blebs had moderate and poor function, respectively, 4 months postoperatively (Fig. 4). The increase in phase retardation preceded the deterioration of bleb function. The mean phase retardation of the bleb at 1, 2, and 4 months postoperatively was significantly correlated with bleb function at 4 months postoperatively ($P = 0.005, 0.037, \text{ and } 0.004$, respectively). These data indicate that the bleb phase retardation at 1 month was a statistically significant predictor of surgical success at 4 months. On the other hand, the IOP in the early postoperatively period was not correlated with bleb function at 4 months postoperatively.

To determine the cutoff phase retardation values at 1 day, 1 week, 2 weeks, 1 month, 2 months, and 4 months postoperatively for the prediction of bleb function, ROC curve

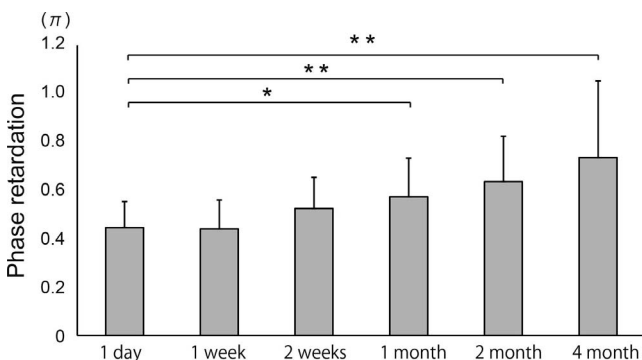


FIGURE 3. The change of phase retardation after glaucoma surgery in the group. Bar graph shows the mean \pm SD. * $P < 0.01$, ** $P < 0.0001$.

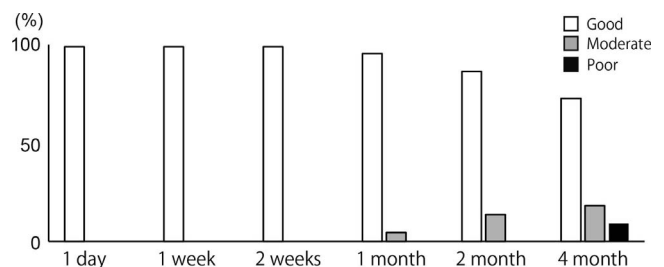


FIGURE 4. Time course of changes of bleb function after glaucoma surgery.

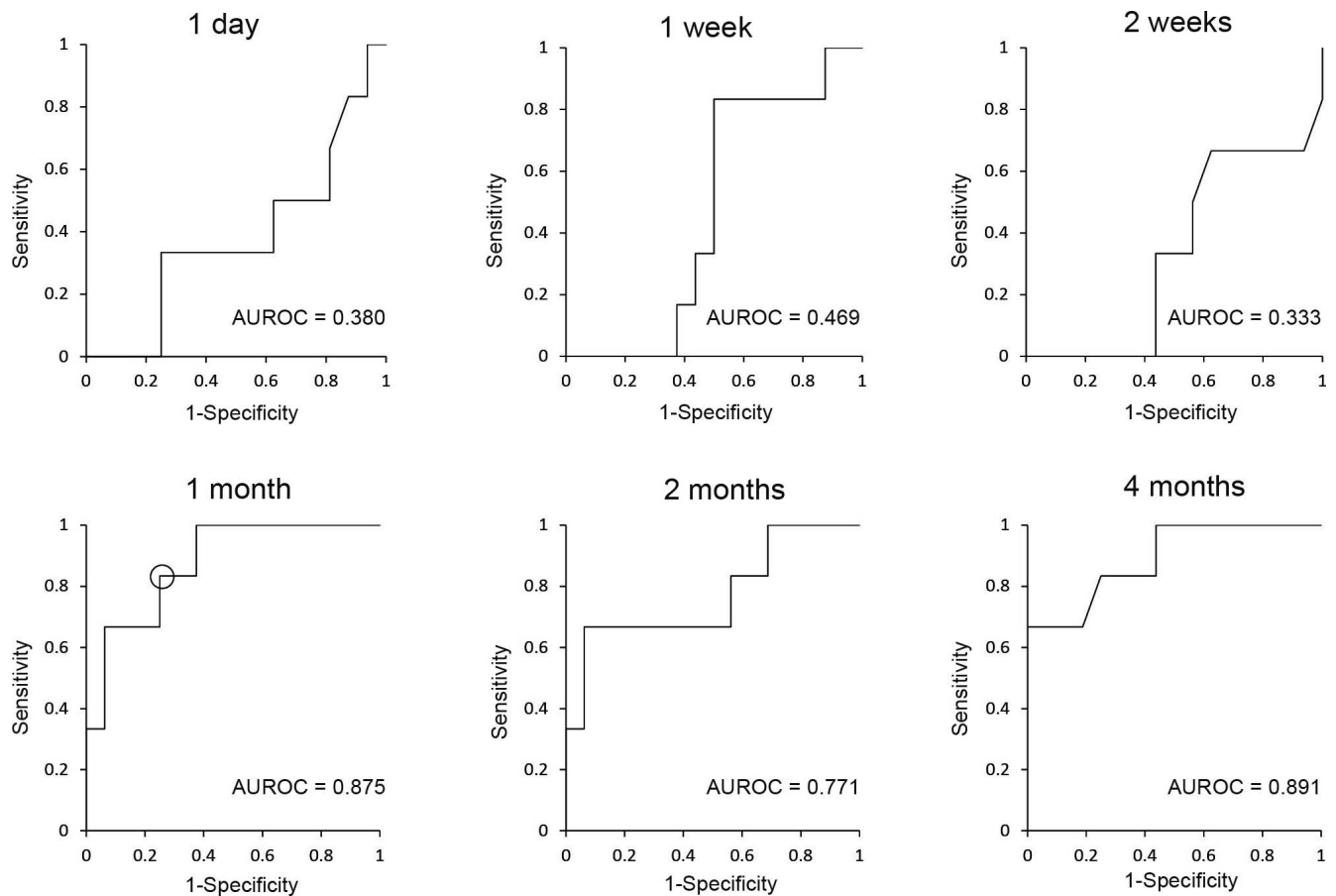


FIGURE 5. Receiver operating characteristic curve analyses for the prediction ability of 1-day, 1-week, 2-week, 1-month, 2-month, and 4-month phase retardation value to bleb function in the early postoperative period. The moderate or poor bleb functions at 4 months after surgery were considered as positive, and the good bleb functions at 4 months after surgery were considered as negative. Cutoff point was chosen at the point indicated by a circle in ROC curve of 1 month after surgery (sensitivity = 83%, specificity = 75%). The values of AUC were also calculated.

analyses were performed and the AUCs were calculated. Moderate or poor bleb function at 4 months postoperatively was considered positive in the ROC analysis, while good bleb function at 4 months postoperatively was considered negative. The values of AUC were 0.380, 0.469, and 0.333 at 1 day, 1 week, and 2 weeks after surgery, respectively. Interestingly, the AUCs at 1, 2, and 4 months postoperatively were higher (0.875, 0.771, and 0.891, respectively; Fig. 5). We chose 0.561 as the cutoff point from the ROC curve of 1 month postoperatively (sensitivity = 83%, specificity = 75%; cutoff point is indicated by a circle in Fig. 5). Blebs were separated into two groups: the high phase retardation group ($n = 9$ blebs), in which the phase retardation value was >0.561 , and the low phase retardation group ($n = 13$ blebs), in which the phase retardation value was <0.561 at 1 month postoperatively. The phase retardation values in the high and low phase retardation groups were 0.502 ± 0.044 and 0.681 ± 0.078 , respectively ($P < 0.0001$, Mann-Whitney U test). Six blebs (55.6%) in the high phase retardation group had moderate or poor bleb function at 4 months postoperatively. On the other hand, only one bleb (7.7%) in the low phase retardation group exhibited deterioration in bleb function at 4 months postoperatively ($P < 0.012$, Fisher's exact test).

Reanalysis of Previous Cross-Sectional Data

Previously, the correlation between bleb function and the grade that was subjectively defined based on PS-OCT phase

retardation image was analyzed by multiple regression analysis. Briefly, the grade of the PS-OCT phase retardation image was defined as grade 1 if the abnormal phase retardation evaluated in the bleb was one-third or less of total bleb area, grade 2 if the abnormal phase retardation was more than one-third but two-thirds or less, and grade 3 if the abnormal phase retardation was more than two-thirds. Instead of this subjective grade, we reanalyzed all cases using the mean phase retardation value of the bleb. The explanatory variables were the phase retardation value, age, period after surgery, and 3D CAS-OCT parameters (horizontal and vertical lengths of the internal fluid-filled cavity, height of the internal fluid-filled cavity, maximum and minimum bleb wall thickness, total bleb height, volume of the internal fluid-filled cavity, volume of the hyporeflexive area, number of microcysts, rate of lake under the scleral flap, and rate of filtration opening on the scleral flap). The mean phase retardation value showed the highest correlation to bleb function ($\beta = 0.770$, $P < 0.001$); it was also higher than the previous results ($\beta = 0.429$, $P < 0.001$, Supplementary Table S1).

DISCUSSION

A variety of cross-sectional imaging modalities such as UBM and AS-OCT have been used to evaluate the association between bleb morphology and bleb function.¹²⁻¹⁴ Moreover, a few studies have investigated the relationship between bleb

morphology in the early postoperative period and long-term postoperative outcomes.^{24,25} However, no studies have evaluated the prognostic ability of internal tissue characteristics such as fibrosis.

The current study is the first to report the prediction ability of internal tissue fibrosis for bleb function using PS-OCT in a noncontact manner. We previously reported that the increase in the IOP tended to be preceded by an alteration in the phase retardation pattern.¹⁹ However, the phase retardation was subjectively graded into three groups. In the current study, the phase retardation value was objective and quantitative. The phase retardation value moderately increased at 2 weeks postoperatively and significantly increased at 1 month postoperatively. The phase retardation value at 1 month postoperatively showed a significant correlation with bleb function at 4 months postoperatively. Interestingly, the AUC of the phase retardation value was increased at 1 month postoperatively in the ROC analysis for the detection of deterioration of bleb function at 4 months postoperatively.

Few studies have evaluated the ability of bleb morphology to predict bleb function in the early postoperative period. Nakano et al.²⁴ reported that blebs with multiple-layer structures at 2 weeks postoperatively were associated with better bleb function at the 6th month. Multifocal blebs had hyporeflexive areas representing loosely arranged connective tissue, subconjunctival separation, and microcysts. Khamar et al.²⁵ also reported that bleb walls with uniform reflectivity in the early postoperative period, as early as 1 month, had poor bleb function at the end of 6 months. Other studies reported that microcysts in blebs observed by slit-lamp microscopy were associated with good function of the mature bleb.^{12,26} In our previous study, we also found that the volume of hyporeflexive areas and the number of microcysts were significantly higher in well-functioning than poorly functioning blebs. However, the quantitatively evaluated phase retardation value was more significantly associated with bleb function than were the hyporeflexive areas and number of microcysts.¹⁹ Internal tissue characteristics may be more sensitive than morphologic characteristics of the bleb.

A previous study reported that both the filtration opening of the scleral flap and the sponge-like structure of the bleb wall are important for proper aqueous humor flow.²⁷ This finding is in accordance with the results of the current study; both the filtration opening of the scleral flap and low phase retardation blebs showed good bleb function (Fig. 1B). On the other hand, filtration scleral flap openings with high phase retardation bleb walls showed poor bleb function (Fig. 2A). The bleb in Figure 2B had a large internal fluid cavity with a partially low phase retardation bleb wall. This bleb, however, showed low bleb function because the scleral flap was not open and it was covered with a high phase retardation bleb wall (Fig. 2B). These results indicate that both the filtration opening of the scleral flap and bleb wall fibrosis are important for good bleb function.

Although the current study assessed only phase retardation, the local birefringence is another emerging readout of PS-OCT. Local birefringence measurements of blebs using PS-OCT were recently introduced.²⁸⁻³⁰ Because the phase retardation does not accurately provide the depth-localized polarization property of the bleb, local birefringence analysis provides more accurate localization of the birefringence change than does phase retardation analysis and shows the precise location of scar tissue.^{22,31} Postoperative surgical manipulation against the trabeculectomy bleb has become a recognized factor for increasing surgical success. Bleb needling provides a relatively simple approach to disrupt subconjunctival scar tissue and restore bleb function. The first needling revision against the bleb was described by Ferrer in 1941,³² and several studies

regarding the successful restoration of failing blebs have been performed.^{33,34} Although previous AS-OCT measurements focused on various causes of obstruction of aqueous humor flow in the bleb (low reflectivity in the bleb walls, microcysts, fluid-filled cavities, and filtration scleral flap opening), a clear strategy to ensure successful needling revision or repeated filtration surgery has not been established.^{12,24,27,35} Local birefringence imaging was recently used to monitor blebs before and after needling revision and remove the scar tissue.²⁸ A narrow cleft of the filtering bleb and highly birefringent scar tissue were found at the location of partial adhesion of the scleral flap before reconstruction of the bleb. The scar tissue was extracted and the region of the cleft was enlarged after bleb reconstruction. Because local birefringence imaging selectively visualizes the fibrosis tissue, it is useful to detect localized scar tissue surrounding the drainage path of the aqueous flow. Tsuda et al.²⁹ reported that a high birefringence region was identified in nonfunctional scarred bleb tissue with local birefringence analysis using PS-OCT. They also confirmed this finding with polarization microscopy of scar tissue resected during revision of the bleb.²⁹ On the other hand, phase retardation is a cumulative quantity of polarization information along depth, and it is therefore sensitive to small changes in polarization and useful to detect early changes in birefringence. For example, the average en face phase retardation of the posterior corneal surface was increased in patients with very early keratoconus due to changes in the lamellar structure of collagen fibers.²⁰ Phase retardation analysis emphasizes small changes by cumulative information and may be useful for small changes in birefringence. In the current study, deterioration of bleb function was preceded by alteration in phase retardation in the early postoperative period. We are planning to compare local birefringence with phase retardation in a future study.

Our study showed no significant association between IOP in the early postoperative period and bleb formation. Intraocular pressure in the early postoperative period is affected by various factors, including postoperative inflammation; aqueous humor production from the ciliary body; and outflow efficiency through the scleral flap, trabecular meshwork, and uveoscleral pathways. The existence of multiple factors determining postoperative IOP may result in the lack of an association. In the late postoperative period, IOP seems to mainly reflect the filtration efficiency of the bleb, which depends on the degree of intrableb scarring and bleb morphology.

Our study has some limitations. The sample size was relatively small, and we did not analyze the clinical morphologic features of the bleb, such as bleb vascularity or leakage.

In conclusion, the mean phase retardation of a bleb showed the highest correlation to its function. Polarization-sensitive OCT provides a prognostic metric for the filtering bleb's function because the phase retardation alteration after filtration surgery precedes the increase in the IOP. This conclusion is supported by our finding that the phase retardation of blebs measured at 1 month postoperatively was significantly correlated with surgical success at 4 months and the ROC analysis results.

Acknowledgments

Supported in part by research Grant KAKENHI 25293353 from the Japan Society for the Promotion of Science, Tokyo, Japan, and the Tomey Corporation.

Disclosure: **S. Fukuda**, None; **A. Fujita**, None; **D. Kasaragod**, Tomey Corp (F), Topcon (F), Nidek (F), Canon (F); **Y. Ueno**, None; **S. Hoshi**, None; **G. Kishino**, None; **S. Beheregaray**, None; **Y.**

Yasuno, Tomey Corp. (F), Topcon (F), Nidek (F), Canon (F), P; T. Oshika, None

References

- Cairns JE. Trabeculectomy. Preliminary report of a new method. *Am J Ophthalmol*. 1968;66:673-679.
- The Advanced Glaucoma Intervention Study (AGIS): 4. Comparison of treatment outcomes within race. Seven-year results. *Ophthalmology*. 1998;105:1146-1164.
- Nyska A, Glovinsky Y, Belkin M, Epstein Y. Biocompatibility of the EX-PRESS miniature glaucoma drainage implant. *J Glaucoma*. 2003;12:275-280.
- Addicks EM, Quigley HA, Green WR, Robin AL. Histologic characteristics of filtering blebs in glaucomatous eyes. *Arch Ophthalmol*. 1983;101:795-798.
- Khaw PT, Occeleston NL, Schultz G, et al. Activation and suppression of fibroblast function. *Eye (Lond)*. 1994;8:188-195.
- Kitazawa Y, Kawase K, Matsushita H, Minobe M. Trabeculectomy with mitomycin. A comparative study with fluorouracil. *Arch Ophthalmol*. 1991;109:1693-1698.
- Katz GJ, Higginbotham EJ, Lichter PR, et al. Mitomycin C versus 5-fluorouracil in high-risk glaucoma filtering surgery. Extended follow-up. *Ophthalmology*. 1995;102:1263-1269.
- Singh K, Mehta K, Shaikh NM, et al. Trabeculectomy with intraoperative mitomycin C versus 5-fluorouracil. Prospective randomized clinical trial. *Ophthalmology*. 2000;107:2305-2309.
- Wells AP, Ashraff NN, Hall RC, Purdie G. Comparison of two clinical bleb grading systems. *Ophthalmology*. 2006;113:77-83.
- Cantor LB, Mantravadi A, WuDunn D, et al. Morphologic classification of filtering blebs after glaucoma filtration surgery: the Indiana Bleb Appearance Grading Scale. *J Glaucoma*. 2003;12:266-271.
- Wells AP, Crowston JG, Marks J, et al. A pilot study of a system for grading of drainage blebs after glaucoma surgery. *J Glaucoma*. 2004;13:454-460.
- Singh M, Chew PT, Friedman DS, et al. Imaging of trabeculectomy blebs using anterior segment optical coherence tomography. *Ophthalmology*. 2007;114:47-53.
- Morita K, Gao Y, Saito Y, et al. In vivo confocal microscopy and ultrasound biomicroscopy study of filtering blebs after trabeculectomy: limbus-based versus fornix-based conjunctival flaps. *J Glaucoma*. 2012;21:383-391.
- Kawana K, Kiuchi T, Yasuno Y, Oshika T. Evaluation of trabeculectomy blebs using 3-dimensional cornea and anterior segment optical coherence tomography. *Ophthalmology*. 2009;116:848-855.
- de Boer JF, Milner TE. Review of polarization sensitive optical coherence tomography and Stokes vector determination. *J Biomed Opt*. 2002;7:359-371.
- Wolman M, Kasten FH. Polarized light microscopy in the study of the molecular structure of collagen and reticulin. *Histochemistry*. 1986;85:41-49.
- Verhaegen PD, van Zuijlen PP, Pennings NM, et al. Differences in collagen architecture between keloid, hypertrophic scar, normotrophic scar, and normal skin: an objective histopathological analysis. *Wound Repair Regen*. 2009;17:649-656.
- Gong P, McLaughlin RA, Liew YM, et al. Assessment of human burn scars with optical coherence tomography by imaging the attenuation coefficient of tissue after vascular masking. *J Biomed Opt*. 2014;19:21111.
- Fukuda S, Beheregaray S, Kasaragod D, et al. Noninvasive evaluation of phase retardation in blebs after glaucoma surgery using anterior segment polarization-sensitive optical coherence tomography. *Invest Ophthalmol Vis Sci*. 2014;55:5200-5206.
- Fukuda S, Yamanari M, Lim Y, et al. Keratoconus diagnosis using anterior segment polarization-sensitive optical coherence tomography. *Invest Ophthalmol Vis Sci*. 2013;54:1384-1391.
- Fukuda S, Kishino G, Hoshi S, et al. Repeatability of corneal phase retardation measurements by polarization-sensitive optical coherence tomography. *Invest Ophthalmol Vis Sci*. 2015;56:3196-3201.
- Makita S, Yamanari M, Yasuno Y. Generalized Jones matrix optical coherence tomography: performance and local birefringence imaging. *Opt Express*. 2010;18:854-876.
- Lim Y, Yamanari M, Fukuda S, et al. Birefringence measurement of cornea and anterior segment by office-based polarization-sensitive optical coherence tomography. *Biomed Opt Express*. 2011;2:2392-2402.
- Nakano N, Hangai M, Nakanishi H, et al. Early trabeculectomy bleb walls on anterior-segment optical coherence tomography. *Graefes Arch Clin Exp Ophthalmol*. 2010;48:1173-1182.
- Khamar MB, Soni SR, Mehta SV, et al. Morphology of functioning trabeculectomy blebs using anterior segment optical coherence tomography. *Indian J Ophthalmol*. 2014;62:711-714.
- Sacu S, Rainer G, Findl O, et al. Correlation between the early morphological appearance of filtering blebs and outcome of trabeculectomy with mitomycin C. *J Glaucoma*. 2003;12:430-435.
- Inoue T, Matsumura R, Kuroda U, et al. Precise identification of filtration openings on the scleral flap by three-dimensional anterior segment optical coherence tomography. *Invest Ophthalmol Vis Sci*. 2012;53:8288-8294.
- Yamanari M, Tsuda S, Kokubun T, et al. Fiber-based polarization-sensitive OCT for birefringence imaging of the anterior eye segment. *Biomed Opt Express*. 2015;6:369-389.
- Tsuda S, Kunikata H, Yamanari M, Nakazawa T. Association between histological findings and polarization-sensitive optical coherence tomography analysis of a post-trabeculectomy human eye. *Clin Exp Ophthalmol*. 2015;43:685-688.
- Kasaragod D, Fukuda S, Ueno Y, Hoshi S, Oshika T, Yasuno Y. Objective evaluation of functionality of filtering bleb based on polarization-sensitive optical coherence tomography. *Invest Ophthalmol Vis Sci*. 2016;57:2305-2310.
- Sugiyama S, Hong YJ, Kasaragod D, et al. Birefringence imaging of posterior eye by multi-functional Jones matrix optical coherence tomography. *Biomed Opt Express*. 2015;6:4951-4974.
- Ferrer H. Conjunctival dialysis in the treatment of glaucoma recurrent after sclerectomy. *Am J Ophthalmol*. 1941;24:788-790.
- Broadway DC, Bloom PA, Bunce C, et al. Needle revision of failing and failed trabeculectomy blebs with adjunctive 5-fluorouracil: survival analysis. *Ophthalmology*. 2004;111:665-673.
- Maestrini HA, Cronemberger S, Matoso HD, et al. Late needling of flat filtering blebs with adjunctive mitomycin C: efficacy and safety for the corneal endothelium. *Ophthalmology*. 2011;118:755-762.
- Kojima S, Inoue T, Kawaji T, Tanihara H. Filtration bleb revision guided by 3-dimensional anterior segment optical coherence tomography. *J Glaucoma*. 2014;23:312-315.