

Structure/Psychophysical Relationships in X-Linked Retinoschisis

Lea D. Bennett,¹ Yi-Zhong Wang,^{1,2} Martin Klein,¹ Mark E. Pennesi,³ Thiran Jayasundera,⁴ and David G. Birch^{1,2}

¹Retina Foundation of the Southwest, Dallas, Texas, United States

²Department of Ophthalmology, University of Texas Southwestern Medical Center, Dallas, Texas, United States

³Oregon Health & Science University, Casey Eye Institute, Portland, Oregon, United States

⁴University of Michigan, Kellogg Eye Center, Ann Arbor, Michigan, United States

Correspondence: Lea D. Bennett, Retina Foundation of the Southwest, Suite 200, 9600 North Central Expressway, Dallas, TX 75231, USA; lbennett@retinafoundation.org.

Submitted: October 7, 2015

Accepted: December 17, 2015

Citation: Bennett LD, Wang YZ, Klein M, Pennesi ME, Jayasundera T, Birch DG. Structure/psychophysical relationships in X-linked retinoschisis. *Invest Ophthalmol Vis Sci*. 2016;57:332–337. DOI:10.1167/iov.15-18354

PURPOSE. To compare structural properties from spectral-domain optical coherence tomography (SDOCT) and psychophysical measures from a subset of patients enrolled in a larger multicenter natural history study of X-linked retinoschisis (XLRs).

METHODS. A subset of males ($n = 24$) participating in a larger natural history study of XLRs underwent high-resolution SDOCT. Total retina (TR) thickness and outer segment (OS) thickness were measured manually. Shape discrimination hyperacuity (SDH) and contour integration perimetry (CIP) were performed on an iPad with the myVisionTrack application. Sensitivity was measured with fundus-guided perimetry (4-2 threshold testing strategy; 10-2 grid, spot size 3, 68 points). Correlation was determined with Pearson's r correlation. Values are presented as the mean \pm SD.

RESULTS. Mean macular OS thickness was less in XLRs patients ($17.2 \pm 8.1 \mu\text{m}$) than in controls ($37.1 \pm 5.7 \mu\text{m}$; $P < 0.0001$) but mean TR thickness was comparable ($P = 0.5884$). For patients, total sensitivity was lower ($13.2 \pm 6.6 \text{ dB}$) than for controls ($24.2 \pm 2.4 \text{ dB}$; $P = 0.0008$) and had a strong correlation with photoreceptor OS ($R^2 = 0.55$, $P = 0.0001$) and a weak correlation with TR thickness ($R^2 = 0.22$, $P = 0.0158$). The XLRs subjects had a logMAR best corrected visual acuity (BCVA) of 0.5 ± 0.3 that was associated with OS ($R^2 = 0.79$, $P < 0.0001$) but not TR thickness ($R^2 = 0.01$, $P = 0.6166$). Shape DH and CIP inner ring correlated with OS ($R^2 = 0.33$, $P = 0.0085$ and $R^2 = 0.47$, $P = 0.0001$, respectively) but not TR thickness ($R^2 = 0.0004$, $P = 0.93$; $R^2 = 0.0043$, $P = 0.75$, respectively).

CONCLUSIONS. When considered from a single visit, OS thickness within the macula is more closely associated with macular function than TR thickness within the macula in patients with XLRs.

Keywords: retinoschisis, SDOCT, micropemetry

Juvenile X-linked retinoschisis (XLRs) is a congenital macular degeneration affecting 1/5000 to 1/25,000 worldwide.^{1–3} The gene associated with XLRs, Retinoschisin (*RS1*),⁴ translates to a retinoschisin protein (RS1), which assists in maintaining retinal structure by binding to the photoreceptors and bipolar cells. Patients are diagnosed in their primary school years with clinical characteristics of bilateral retinal splitting^{5–8} and an electronegative electroretinography (ERG) response with preserved a-wave.⁹ Best corrected visual acuity (BCVA) typically ranges from 20/50 to 20/120 (0.5–0.8 log minimum angle of resolution [logMAR]) and remains stable until the fifth or sixth decade of life when the cavities resolve and visual acuity decreases.¹⁰

Shape discrimination hyperacuity (SDH) and contour integration perimetry (CIP) in patients with intermediate AMD show significant deficits, with macular edema exacerbating the loss of the ability to detect distortions in circular shapes.^{11,12} These tests assess the global integration of visual stimuli over a large retinal area. The SDH tests parafoveal acuity, whereas the CIP determines retinal acuity outside of the central 3°. Due to the foveal edema in XLRs we hypothesize that the global integration measured by SDH/CIP may be affected, although some patients retain a relatively good BCVA. Spectral-

domain optical coherence tomography (SDOCT) studies in XLRs have been reported,^{5,7,13,14} but rarely correlated with fundus-guided perimetry¹⁵ or shape discrimination. Clinical attributes of XLRs have been characterized, but concise relationships with structure and psychophysical function need further exploration.

A multicenter natural history study of XLRs was designed to understand disease progression and determine suitable outcome measures for future gene therapy trials. The results reported here were obtained from a single visit. A subset of patients were tested with additional measures so that we could determine whether photoreceptor outer segment (OS) and/or total retina (TR) thickness could predict performance on visual tasks such as BCVA, fundus-guided perimetry, SDH, and CIP in patients with XLRs.

METHODS

Study Population

Measures were obtained from a cohort of 24 subjects (age 32.2 years \pm 17.7 SD; range, 9–79 years) from a larger group ($n =$



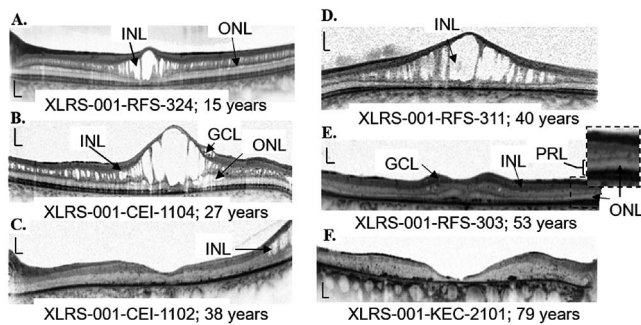


FIGURE 1. Representative SDOCT scans. (A) Cavities were found in the inner nuclear layer (INL) and outer nuclear layer (ONL). (B) Example of schisis cavities in the INL, ONL, and the ganglion cell layer (GCL). (C) Subject CEI-1102 had extramacular schisis in the INL. This subject also had absence of definitive photoreceptor layer (PRL). An example of the PRL is shown in (E). (D) Subject RFS-311 had schisis cavities only in INL. (E) Mild splitting in the INL and GCL is noted in patient RFS-303. The enlarged area of retina is illustrating an intact PRL. (F) KEC-2101, the oldest subject in the study, had no observable cavities, RPE atrophy, and absence of definitive PRL.

78) enrolled in a multicenter natural history study of XLRS, ClinicalTrials.gov NCT0233117. Included here are results from a single visit for patients receiving supplementary evaluations that were not part of the natural history study. These patients were enrolled consecutively after Institutional Review Board approval of protocols. Age-similar normal values were derived from contemporaneous subjects for each test. Not all control subjects performed all tests, so the controls are unique individuals for each analysis. Controls had normal eye exams and normal visual acuity. Analyses of within-patient variability were used to determine whether there were significant differences between eyes for each test. Since there were no significant differences between eyes, we averaged both eyes for $n = 1$ per test. Research adhered to the tenets of the Declaration of Helsinki and was approved by the Western Institutional Review Board.

Spectral-Domain OCT

High-resolution horizontal line scans of the macula were obtained using Spectralis Heidelberg retina angiography + OCT (Heidelberg Engineering, Inc., Heidelberg, Baden-Württemberg, Germany). Horizontal line scans had a mean of 100 scans over 30° including the fovea. The average thicknesses of TR and OS were measured with manual segmentation (Igor Pro 6.03A; Wave Metrics, Inc., Tigard, OR, USA). The OS thickness was determined as the distance between the ellipsoid zone (EZ), otherwise known as the inner segment (IS)/OS junction, and the apical retinal pigmented epithelium (RPE) border.¹⁶ The TR thickness was measured from the inner limiting membrane (ILM) to the basement membrane (BM).¹⁶ These measures were taken at the central 10° with the fovea in the center, therefore depicting thicknesses of the macula.

Microperimetry

Macular sensitivity was determined under mesopic conditions on a microperimeter (MP1-S; NAVIS software, ver. 1.7; Nidek Technologies, Padova, Italy) with spot size 3 (0.43° diameter) and a 10-2 protocol. Perimetric sensitivity (with infrared illumination of the fundus) was determined as the mean of 68 points spanning 20° of the retina. The MP1-S microperimeter tests sensitivity up to 20 dB, but normal subjects and

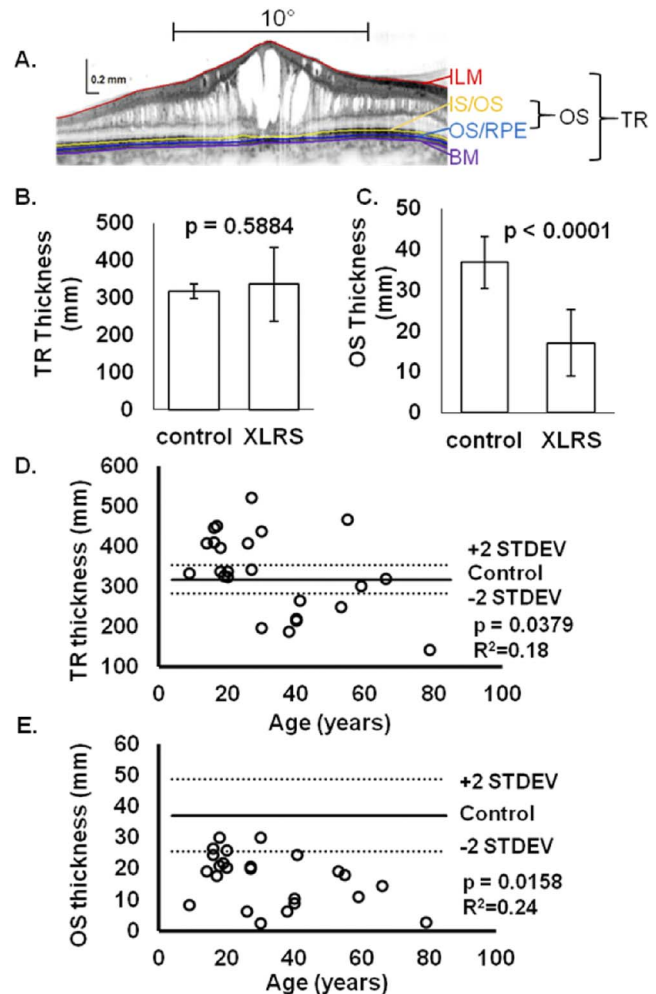


FIGURE 2. Outer segments (OS) and total retina (TR) thickness. (A) Representative SDOCT horizontal line scan from XLRS subject (55 years) showing the central 10° where measurements were made for OS or TR thicknesses. Outer segments were indexed by the distance between the EZ (yellow line) and the OS/retinal pigment epithelium (RPE) border (blue line). Total retina was the distance between the inner limiting membrane (ILM; red line) and the basement membrane (BM; purple line). (B) Total retina thickness was not different between patients and controls, whereas (C) macular OS thickness was smaller in XLRS compared to controls. (D) Total retina thickness in XLRS patients was similar to controls and had a weak correlation with age. (E) Macular OS thickness was lower than in controls and was not associated with age. Correlation was determined with Pearson's r correlation.

some XLRS patients need a higher dynamic range of stimuli intensity to get their true sensitivity (>20 dB). To circumvent the ceiling effect of the MP1-S, a 1.0 log neutral density filter was used when the patient exhibited maximum sensitivity (20 dB) for the majority of the individual test points. One patient had one eye with no light perception. The mean sensitivity for this eye was set to 0 dB, averaged with the fellow eye, and included in the analysis.

Visual Acuity

After refraction, BCVA was assessed by Electronic Visual Acuity Tester (Jaeb Center for Health Research, Tampa, FL, USA). Results for each subject were represented by the Snellen equivalent or as the logMAR.

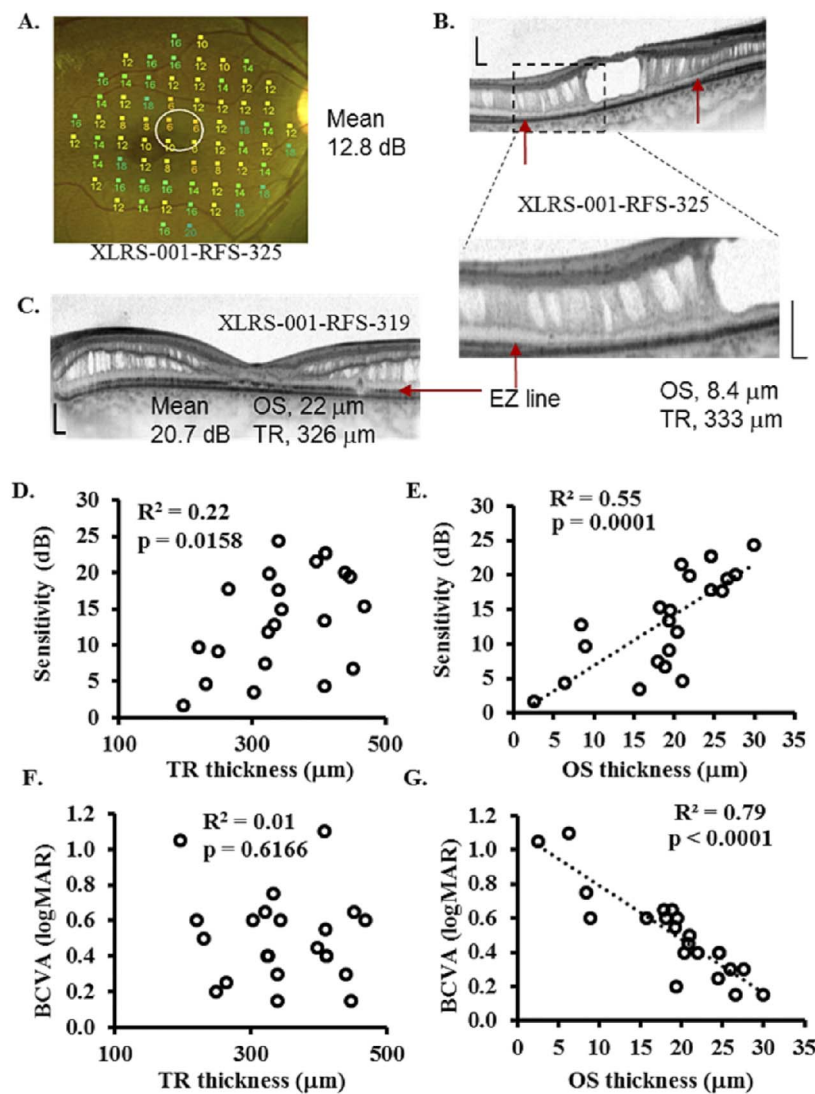


FIGURE 3. Sensitivity was reduced in XLRs subjects. (A) Representative fundus-guided perimetry results from the right eye of a 10-year-old patient. His total mean sensitivity was 12.8 dB and BCVA was 20/80 (0.6 logMAR) in the right eye. (B) The horizontal line scan acquired at the position of the arrow in (A) from the same subject. Notice how the EZ line is discontinuous (*arrows*). The enlargement shows where the EZ line is discontinuous. Scale bars: 200 μm . (C) Subject RFS-319 was a 19-year-old man with mean sensitivity = 20.7 dB, BCVA = 20/40 (0.4 logMAR), central OS thickness = 22 μm , and TR thickness = 326 μm . (D) Subjects with XLRs had a central TR thickness that was weakly correlated with total retinal sensitivity ($R^2 = 0.22$, $P = 0.0158$), whereas (E) macular OS thickness was highly correlated with total retinal sensitivity. (F) Best corrected visual acuity was not associated with TR thickness ($R^2 = 0.01$, $P = 0.6166$) but was (G) highly correlated to macular OS thickness in XLRs patients. Correlation was determined with Pearson's r correlation.

Shape Discrimination Hyperacuity and Contour Integration Perimetry

Shape DH and CIP tests to evaluate central vision were performed on an iPad using the myVisionTrack visual function application.¹² The SDH test displays three smooth and one distorted circle on the iPad. The subject was instructed to touch the distorted circle. The test continues as a 4-alternative, forced choice (4AFC) test algorithm with a 2-down, 1-up adaptive staircase procedure for the amount of distortion presented in each trial until the SDH is determined.¹² The CIP test showed smooth and distorted circular contour segments spatially distributed in an "inner" or "outer" ring using a 4AFC staircase paradigm with a stimulus duration of 0.25 seconds (Wang YZ, Mitchel G. *IOVS* 2013;54:ARVO E-Abstract 5019). As with the SDH test, the subject was instructed to choose the distorted line segment. A maximum likelihood fitting procedure

was implemented to estimate detecting the distortion of contour segments of inner or outer rings.

Differences between sample means were analyzed with Student's 2-tailed t -test and the Pearson coefficient test for the correlation studies. All values are presented as the mean \pm SD.

RESULTS

Patient Information

Each of the 24 patients had an identified mutation in the *RS1* gene. The most common type of mutation was a missense mutation (80%). Other mutations that occurred in our patient population were small frameshifting insertions/deletions (10%), intronic splice site mutations (5%), and exon deletions (5%). Of the patients presented here, two individuals are

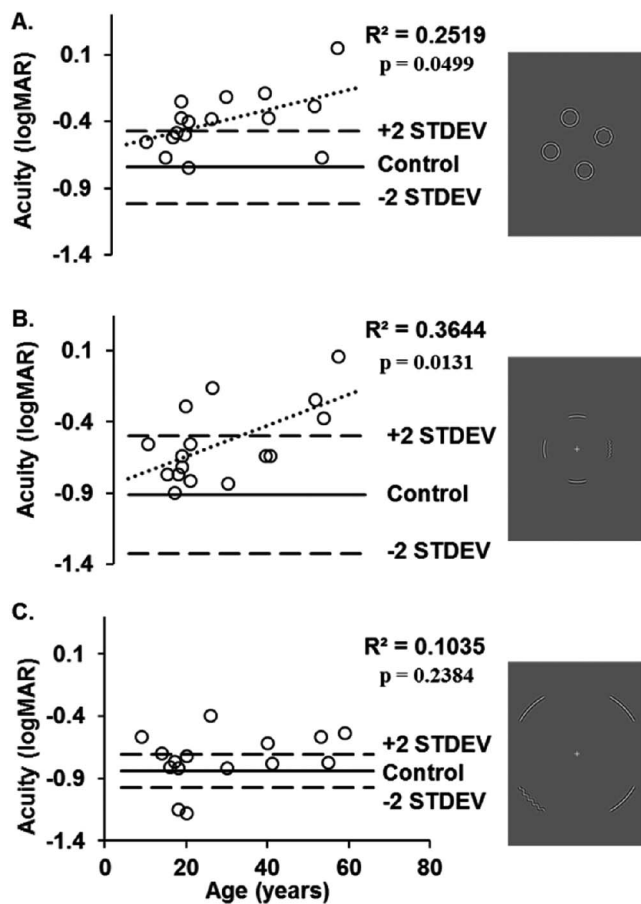


FIGURE 4. X-linked retinoschisis subjects had decreased ability to detect (A) circular (SDH) and (B) contour distortion (CIP inner) compared to controls. (C) Contour integration perimetry outer ring tests were not different between XLRS and control subjects. X-linked retinoschisis patients' detection of circular shape discrimination or contour distortion did not correlate with age. Correlation was determined with Pearson's r correlation.

related as uncle/nephew. There were no other familial relations in this cohort.

For these XLRS patients, BCVA ranged from Snellen equivalent of 20/25 to no light perception with a median logMAR of 0.5 ± 0.3 . Patients ranged in age from 9 to 79 years (mean 32.4 ± 18.1 years). The number of control subjects and their age for each procedure are provided in the Table.

Spectral-Domain OCT

High-resolution SDOCT scans showed different clinical features in our population of XLRS patients. There were seven eyes (14.6%) with cavities intruding into the inner nuclear layer (INL) and outer nuclear layer (ONL; Fig. 1A). Examples for the highest incidence for cavity localizations are shown in Figures 1B through 1D, which involved the INL, ONL, and ganglion cell layer (GCL) or had an INL-only pattern of schisis cavities (12 eyes each; 25%; Figs. 1B–D, respectively). Localization of cavities within the INL and GCL occurred in nine eyes (14.6%) of our patients (Fig. 1E). One eye had cavities in the GCL only (2.1%), and one eye had cavities in the GCL and ONL (2.1%, not shown). Eyes without detectable schisis cavities (six eyes, 12.5%) were also noted in our population (Fig. 1F). Of interest, the photoreceptor layer (PRL, enlarged in Fig. 1E) was absent in the SDOCT scans from eyes devoid of

TABLE. Demographics of Control Subjects

	SDOCT	MP1-s	SDH and CIP
Range, y	14–69	13–56	16–66
Mean, y \pm SD	44.7 ± 18.3	33.2 ± 15.9	35.5 ± 6.0
Number participating, n	10	6	10

cavities (Fig. 1F) and from those with extrafoveal schisis (Fig. 1C).

Since cavity size differs among subjects, we wanted to know if age was a contributing factor to TR thickness in the macula. Figure 2A depicts how the TR and OS thicknesses were measured. The TR, determined as the distance between the ILM and the BM in the central 10° , was $335.6 \pm 97.8 \mu\text{m}$ for XLRS subjects, which was not different than controls ($318.1 \pm 17.7 \mu\text{m}$; $P = 0.5884$; Fig. 2B). However, the OS thickness was smaller in XLRS patients ($17.2 \pm 8.1 \mu\text{m}$) compared to controls ($37.1 \pm 5.7 \mu\text{m}$; $P < 0.0001$; Fig. 2C). When age was considered as a potential factor for either central TR or central OS thickness, we found that there was a weak relationship between XLRS patient age and TR (Fig. 2D; $R^2 = 0.24$, $P = 0.0158$) or OS ($R^2 = 0.18$, $P = 0.0379$; Fig. 2E) thickness.

Microperimetry

To assess central retina function, psychophysical sensitivity was measured with fundus-guided microperimetry. The black arrow on the fundus/microperimetry grid overlay (Fig. 3A) defines the position of the horizontal line scan (Fig. 3B). Subject XLRS-001-RFS-325, a 10-year-old boy, had BCVA of 20/80 (0.6 logMAR) and a lower than normal (24.2 ± 2.4 dB) total mean sensitivity (12.8 dB) in the left eye (Fig. 3A). This subject had a similar central TR thickness ($333 \mu\text{m}$) and smaller OS thicknesses ($8.4 \mu\text{m}$) compared to normal ($318.1 \pm 17.7 \mu\text{m}$ and $37.1 \pm 5.7 \mu\text{m}$, respectively). An area highlighting where the EZ line was absent from the central retina is enlarged. The red arrows point to where the EZ line stops (Fig. 3B), which explains why the average of the central 10° OS for this subject was decreased. Conversely, the EZ line (red arrow) can be seen clearly across the macular region in a 19-year-old subject, XLRS-001-RFS-319 (Fig. 3C). This individual had BCVA of 20/40 (0.4 logMAR), a near-normal mean sensitivity of 20.7 dB, and a comparable TR thickness ($326 \mu\text{m}$) compared to control (24.2 ± 2.4 dB and $318.1 \pm 17.7 \mu\text{m}$, respectively). This subject's OS thickness was $22 \mu\text{m}$, which was larger than the mean OS thickness from all XLRS subjects (13.2 ± 6.6 dB; Fig. 3C). Overall, the mean sensitivity in XLRS patients was lower than the control mean sensitivity (XLRS: 13.2 ± 6.6 dB; control: 24.2 ± 2.4 dB; $P = 0.0008$).

To evaluate the relationship between anatomical features and psychophysical functional measures, the sensitivity or BCVA was analyzed against central TR and macular OS thickness in XLRS subjects. The TR thickness had a weak relationship ($R^2 = 0.22$, $P = 0.0158$), but macular OS thickness was highly correlated (Figs. 3D, 3E; $R^2 = 0.55$, $P = 0.0001$) with mean sensitivity. Similarly, BCVA was weakly associated with TR ($R^2 = 0.01$, $P = 0.6166$) but highly correlated with OS ($R^2 = 0.79$, $P < 0.0001$) thickness in XLRS subjects (Figs. 3F, 3G).

Shape DH and Contour IP

Shape DH was worse in XLRS subjects (-0.4 ± 0.2 logMAR) than in controls (-0.7 ± 0.1 logMAR, $P < 0.001$; Fig. 4A). Detection of contour lines in a ring, designated inner CIP, was higher (worse) for XLRS subjects (-0.6 ± 0.3 logMAR) than for control subjects (-0.9 ± 0.2 logMAR, $P = 0.002$, Fig. 4B).

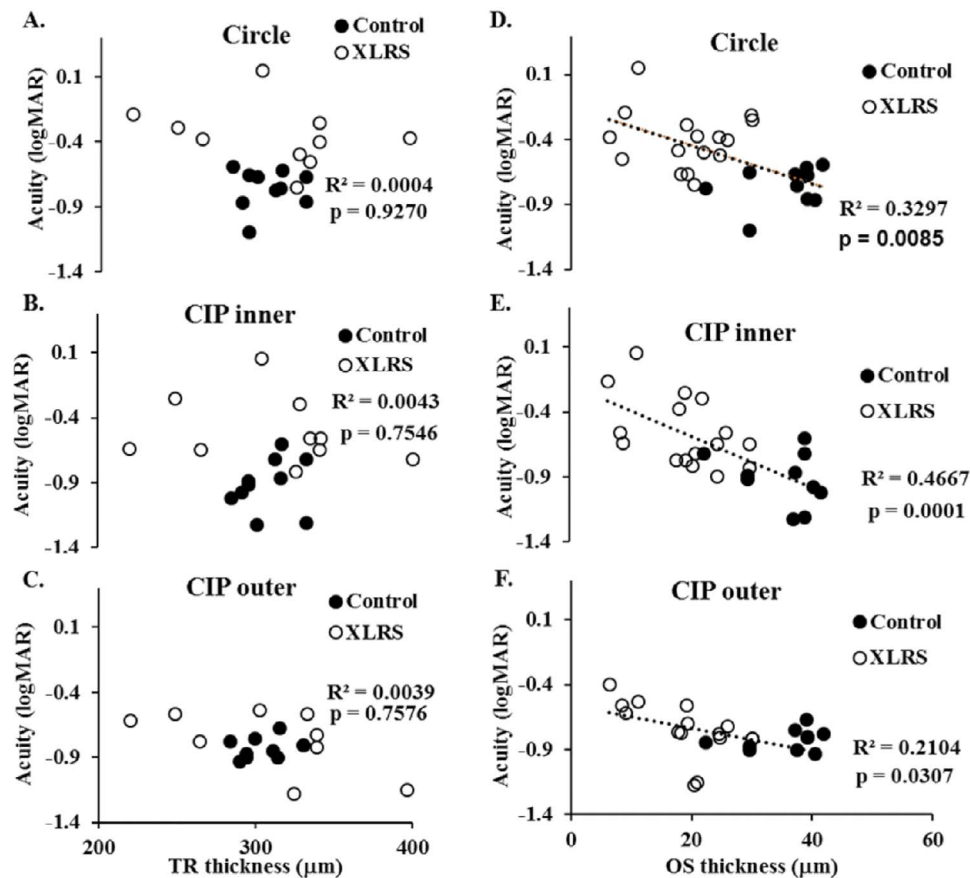


FIGURE 5. (A–C) Shape discrimination hyperacuity and contour integrated perimetry (SDH and CIP) acuity did not correlate with total retina thickness, but (D) circular SDH and (E) CIP inner ring acuity were highly associated with outer segment (OS) thickness. (F) Outer segment thickness had a weak correlation with CIP outer ring acuity. Correlation was determined with Pearson's *r* correlation.

However, thresholds for contour lines in a wider ring (outer CIP) were not different between the groups (XLRs: -0.7 ± 0.2 logMAR; control: -0.8 ± 0.1 logMAR; Fig. 4C). No effect of age was found on SDH and CIP thresholds for patients with XLRs (Fig. 4).

Correlation analysis with TR or OS thickness revealed no association of TR thickness with SDH ($R^2 = 0.0004$, $P = 0.9270$), inner CIP ($R^2 = 0.0043$, $P = 0.7546$), or outer CIP ($R^2 = 0.0039$, $P = 0.7576$) (Figs. 5A–C). However, OS thickness was highly correlated with SDH ($R^2 = 0.3297$, $P = 0.0085$) and inner CIP ($R^2 = 0.4667$, $P = 0.0001$), but weakly associated with outer CIP ($R^2 = 0.2104$, $P = 0.0307$; Figs. 5D–F). Of note, the correlation was similar whether controls were included in the analysis or not.

DISCUSSION

The purpose of the present study was to compare structural properties from SDOCT to psychophysical measures in a subset of patients enrolled in a larger multicenter natural history study of XLRs. Here we showed that the OS length was highly correlated with BCVA (Fig. 3G), fundus-guided perimetry (Fig. 3E), SDH (Fig. 5D), and CIP (Fig. 5E) but that total thickness of the retina had weak association with these measures (Figs. 3D, 3F, 5A–C). The TR thickness failed to show a negative correlation with age in our patients tested with XLRs, unlike previous reports showing that younger patients had large foveal schisis cavities and older patients had thinner retinas with minimal cavities.^{8,13} While this may be

common in progression of the disease, it is certainly not seen in all patients. The cavity size can vary according to the individual regardless of age, which could be the result of the specific mutation, other eye diseases, or medication. For example, two patients (ages 53 and 40) in this group, using ocular carbonic anhydrase inhibitors (CAIs) to reduce the swelling in the retina, had resolution of foveal schisis. Of note, CAI use was not prohibited in this study; not all patients respond to CAIs,^{17–20} and other patients in this study had cystic changes in the macula without resolution while using this medication. Further, this study was not powered to detect group differences between those using and those not using the CAIs.

Although the mean sensitivity was variable in these XLRs subjects, it was still below control sensitivity. Interestingly, sensitivity, a psychophysical examination of macular function, was better correlated with macular OS thickness than central TR thickness in XLRs subjects. This suggests that a defect in the photoreceptors, not maculoschisis, contributes to macular sensitivity loss in patients with XLRs.

Similar to patients with macular edema in AMD,¹² the XLRs patients displayed defects in SDH and CIP, validating our hypothesis that these patients would have a deficit in the global integration visual acuity. This could be due to the cystic cavities distorting straight lines when maculoschisis is present. However, after further analysis, TR thickness did not correlate with SDH or CIP outcomes in XLRs subjects (Figs. 5A–C). Interestingly, it was OS thickness that correlated with the results from SDH and CIP tests (Figs. 5D–F). Thus, the outer retina is the major limitation to the altered SDH/CIP results

shown here. However, it cannot be dismissed that the schisis could have exacerbated the loss of visual integration as found in AMD.¹² This is the first report of shape and contour line discrimination deficits in XLRs. This supports the hypothesis that a photoreceptor defect, rather than maculoschisis, is most responsible for the functional deficit in XLRs. It will be interesting to repeat these tests to determine if the SDH and CIP change over time in these patients. In particular, if age is not a contributing factor and younger patients do not differ from older patients, this would suggest that the shape discrimination defect is present at the earliest stage of disease.

Since it is believed that in the majority of patients the disease shows either no or minimal progression,^{5,21-25} accurate baseline results need to be documented from each subject when considering outcomes for a treatment trial. Furthermore, test-retest variability will also be important when determining significant change in disease progression. Test-retest variability has been obtained for microperimetry and BCVA in seven patients with XLRs, with the authors evaluating the coefficients of repeatability and associated confidence intervals so that they would know the minimum level of change required in a parameter to be considered statistically different from baseline.¹⁵ Test-retest statistics have yet to be determined within our patient population. These measures will be assessed to see how the data vary among these particular XLRs subjects in order to define significant change from baseline for either treatment or longitudinal studies.

Data presented here are consistent with previous measures of schisis cavities and decreased photoreceptor sensitivity in patients with XLRs.⁵⁻⁸ New findings include measures of OS length and the relationship between OS length and macular function based on microperimetry, SDH, CIP, and BCVA. Psychophysical outcome measures in these patients will be imperative when deciphering the effectiveness of therapies in future clinical trials for XLRs.

Acknowledgments

Supported by National Institutes of Health EY09076, Foundation Fighting Blindness, and Applied Genetic Technologies Corporation.

Disclosure: **L.D. Bennett**, None; **Y.-Z. Wang**, None; **M. Klein**, None; **M.E. Pennesi**, None; **T. Jayasundera**, None; **D.G. Birch**, None

References

- George ND, Yates JR, Bradshaw K, Moore AT. Infantile presentation of X linked retinoschisis. *Br J Ophthalmol*. 1995;653-657.
- Tantri A, Vrabec TR, Cu-Unjieng A, Frost A, Annesley WH Jr, Donoso LA. X-linked retinoschisis: a clinical and molecular genetic review. *Surv Ophthalmol*. 2004;49:214-230.
- Audo I, Robson AG, Holder GE, Moore AT. The negative ERG: clinical phenotypes and disease mechanisms of inner retinal dysfunction. *Surv Ophthalmol*. 2008;53:16-40.
- Sauer CG, Gehrig A, Warneke-Wittstock R, et al. Positional cloning of the gene associated with X-linked juvenile retinoschisis. *Nat Genet*. 1997;17:164-170.
- Apushkin MA, Fishman GA, Janowicz MJ. Correlation of optical coherence tomography findings with visual acuity and macular lesions in patients with X-linked retinoschisis. *Ophthalmology*. 2005;112:495-501.
- Haas JU. Das Zusammenkommen von Veraenderungen der Retina und Choriodea. *Arch Augenbeilkd*. 1898;37:343-348.
- Eriksson U, Larsson E, Holmström G. Optical coherence tomography in the diagnosis of juvenile X-linked retinoschisis. *Acta Ophthalmol Scand*. 2004;82:218-223.
- Lesch B, Szabo V, Kanya M, et al. Clinical and genetic findings in Hungarian patients with X-linked juvenile retinoschisis. *Mol Vis*. 2008;14:2321-2332.
- Peachey NS, Fishman GA, Derlacki DJ, Brigell MG. Psychophysical and electroretinographic findings in x-linked juvenile retinoschisis. *Arch Ophthalmol*. 1987;105:513-516.
- Eksandh LC, Ponjavic V, Ayyagari R, et al. Phenotypic expression of juvenile X-linked retinoschisis in Swedish families with different mutations in the XLRs1 gene. *Arch Ophthalmol*. 2000;118:1098-1104.
- Wang YZ. Effects of aging on shape discrimination. *Optom Vis Sci*. 2001;78:447-454.
- Wang YZ, He YG, Mitzel G, Zhang S, Bartlett M. Handheld shape discrimination hyperacuity test on a mobile device for remote monitoring of visual function in maculopathy. *Invest Ophthalmol Vis Sci*. 2013;54:5497-5505.
- Menke MN, Feke GT, Hirose T. Effect of aging on macular features of X-linked retinoschisis assessed with optical coherence tomography. *Retina*. 2011;31:1186-1192.
- Yang HS, Lee JB, Yoon YH, Lee JY. Correlation between spectral-domain OCT findings and visual acuity in X-linked retinoschisis. *Invest Ophthalmol Vis Sci*. 2014;55:3029-3036.
- Jeffrey BG, Cukras CA, Vitale S, Turriff A, Bowles K, Sieving PA. Test-retest intervisit variability of functional and structural parameters in X-linked retinoschisis. *Transl Vis Sci Technol*. 2014;3(5):5.
- Ramachandran R, Zhou L, Locke KG, Birch DG, Hood DCA. Comparison of methods for tracking progression in X-linked retinitis pigmentosa using frequency domain OCT. *Transl Vis Sci Technol*. 2013;2(7):5.
- Thobani A, Fishman GA. The use of carbonic anhydrase inhibitors in the retreatment of cystic macular lesions in retinitis pigmentosa and X-linked retinoschisis. *Retina*. 2011; 31:312-315.
- Apushkin MA, Fishman GA. Use of dorzolamide for patients with X-linked retinoschisis. *Retina*. 2006;26:741-745.
- Gurbaxani A, Wei M, Succar T, McCluskey PJ, Jamieson RV, Grigg JR. Acetazolamide in retinoschisis: a prospective study. *Ophthalmology*. 2014;121:802-803, e803.
- Walia S, Fishman GA, Molday RS, et al. Relation of response to treatment with dorzolamide in X-linked retinoschisis to the mechanism of functional loss in retinoschisis. *Am J Ophthalmol*. 2009;147:111-115, e111.
- Kellner U, Brummer S, Foerster MH, Wessing A. X-chromosomal congenital retinoschisis. Clinical aspects and electrophysiology [in German]. *Fortschr Ophthalmol*. 1990;87:264-268.
- Kjellstrom S, Vijayarathy C, Ponjavic V, Sieving PA, Andreasson S. Long-term 12 year follow-up of X-linked congenital retinoschisis. *Ophthalmic Genet*. 2010;31:114-125.
- Roesch MT, Ewing CC, Gibson AE, Weber BH. The natural history of X-linked retinoschisis. *Can J Ophthalmol*. 1998;33: 149-158.
- Khan NW, Jamison JA, Kemp JA, Sieving PA. Analysis of photoreceptor function and inner retinal activity in juvenile X-linked retinoschisis. *Vis Res*. 2001;41:3931-3942.
- Bowles K, Cukras C, Turriff A, et al. X-linked retinoschisis: RS1 mutation severity and age affect the ERG phenotype in a cohort of 68 affected male subjects. *Invest Ophthalmol Vis Sci*. 2011;52:9250-9256.