

The Evaluation of Diabetic Macular Ischemia Using Optical Coherence Tomography Angiography

Patrick D. Bradley,¹ Dawn A. Sim,¹ Pearse A. Keane,¹ João Cardoso,^{1,2} Rupesh Agrawal,¹ Adnan Tufail,¹ and Catherine A. Egan¹

¹Moorfields Eye Hospital NHS Foundation Trust, London, United Kingdom

²Hospital Garcia de Orta E.P.E., Almada, Portugal

Correspondence: Patrick D. Bradley, Moorfields Eye Hospital NHS Foundation Trust, 162 City Road, London EC1V 2PD, UK; patrickbradley01@gmail.com.

Submitted: August 24, 2015

Accepted: January 11, 2016

Citation: Bradley PD, Sim DA, Keane PA, et al. The evaluation of diabetic macular ischemia using optical coherence tomography angiography. *Invest Ophthalmol Vis Sci.* 2016;57:626-631. DOI:10.1167/iovs.15-18034

PURPOSE. The purpose of this study was to compare optical coherence tomography (OCT) angiography to standard fluorescein angiography (FA) in the grading of diabetic macular ischemia.

METHODS. In our study, OCT angiography and traditional FA images were acquired from 24 diabetic patients. The level of diabetic macular ischemia in the superficial capillary plexus was graded with standard Early Treatment Diabetic Retinopathy Study (ETDRS) protocols and a comparison between conventional FA and OCT angiography was performed. The deep vascular plexus and choriocapillaris were also graded for macular ischemia. Additionally, flow indices were analyzed for all OCT angiography images.

RESULTS. We identified moderate agreement between diabetic macular ischemia grades for conventional FA and OCT angiography (weighted κ of 0.53 and 0.41). In addition, the intergrader agreement for the superficial, deep, and choriocapillaris scores was substantial (weighted κ of 0.65, 0.61, and 0.65, respectively). Finally, the parafoveal flow indices were shown to have a statistically significant relationship with diabetic macular ischemia grades for the superficial capillary plexus ($P = 0.04$) and choriocapillaris ($P = 0.036$), with a trend toward significance for the deep capillary plexus ($P = 0.13$).

CONCLUSIONS. We demonstrated moderate agreement between diabetic macular ischemia grading results for OCT angiography and conventional FA using standard ETDRS protocols. We also showed that OCT angiography images could be graded for diabetic macular ischemia with substantial intergrader agreement.

Keywords: diabetic macular ischemia, optical coherence tomography, fluorescein angiography

Diabetic macular ischemia (DMI) is an important clinical feature of diabetic retinopathy (DR). It has been postulated that the selective loss of pericytes and thickening of the basement membrane in retinal capillaries occurs as a result of exposure to elevated blood glucose over an extended period of time.¹ Clinically, DMI is defined by an enlargement of the foveal avascular zone (FAZ) and paramacular areas of capillary nonperfusion.² In a previous paper, we have demonstrated that a large proportion (approximately 41%) of patients with DR in a tertiary hospital setting have some evidence of macular ischemia.² Of note, this study demonstrated that visual function was affected only in those with moderate to severe macular ischemia.² More recently, an analysis of the RIDE and RISE trials showed that patients with DMI at baseline progressed earlier to neovascular complications of DR during intravitreal ranibizumab treatment than those with normal perfusion at baseline.³ Therefore, baseline assessment of DMI when initiating ranibizumab therapy for diabetic macular edema (DME) has clinical implications and may be of practical importance to patients and physicians when planning review schedules for reassessment of peripheral retinopathy grades for patients receiving injections.

Fluorescein angiography (FA) is widely recognized as an essential tool in the diagnosis and treatment of DR and DMI.^{2,4,5} Assessing the level of macular ischemia in an individual can

often provide important clinical and prognostic information for the clinician in regard to disease severity and progression.^{3,5,6} However, despite its clinical usefulness, FA is acknowledged to have documented risks that include nausea, vomiting, itching and urticaria, and rarely, anaphylaxis.⁷ In recent years, optical coherence tomography (OCT) has become widely accepted as a noninvasive means of acquiring high-resolution images of the retina that can be utilized in the treatment of retinal disease.⁴ The recent development of OCT angiography allows for the visualization of the retinal capillary layers and for the construction of microvascular flow maps.^{4,8-13} This imaging of the retinal vasculature is novel, in that it is accomplished without the need for injection of fluorescein sodium dye.^{4,11,12}

In this retrospective analysis, we utilized standard Early Treatment Diabetic Retinopathy Study (ETDRS) grading protocols to evaluate images obtained via traditional FA and those obtained of the superficial capillary plexus using OCT angiography. We evaluated the level of agreement between DMI grades obtained using both imaging modalities. We also attempted to grade DMI in the deeper layers of the retina, that is, the deep retinal capillary plexus and the choriocapillaris. In the past, conventional FA images have not allowed separate visualization of the superficial and deeper layers of the retinal vasculature.¹⁴ Therefore, we developed novel grading systems



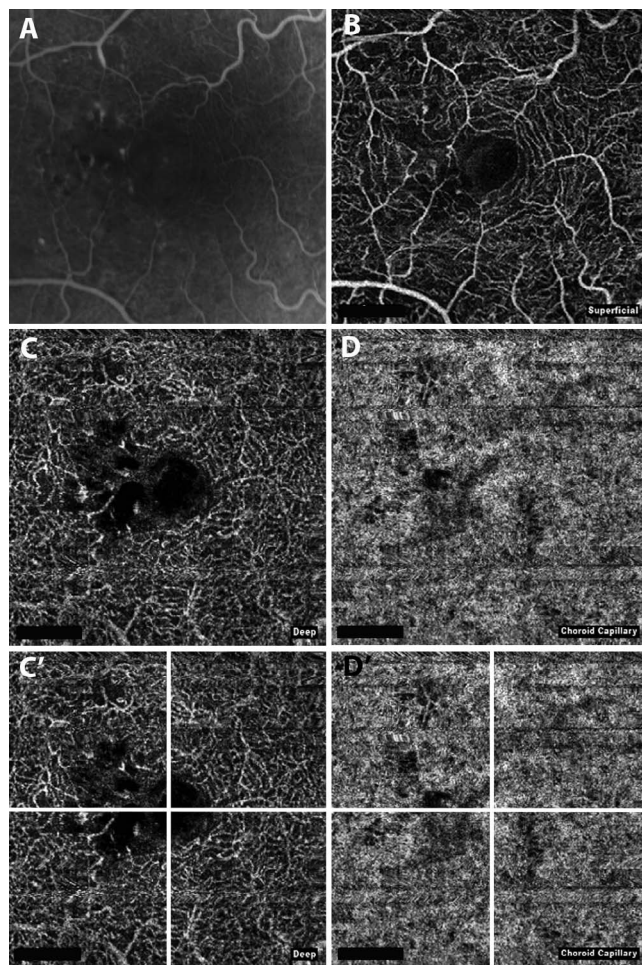


FIGURE 1. Fluorescein angiography and OCT angiography images, which demonstrated identical DMI grades from both graders at all levels of the retinal vasculature. Early-phase FA (25 seconds) (A) demonstrating the presence of macular ischemia in less than one half of the FAZ. Optical coherence tomography angiography of the superficial capillary plexus (B) demonstrating the presence of macular ischemia in less than one half of the FAZ. Optical coherence tomography angiography of the deep capillary plexus (C) demonstrating disruption of the outline of the FAZ. Optical coherence tomography angiography of the choriocapillaris (D) demonstrating loss of speckled (mottled) hyperreflectance homogeneity and the presence of dark defects not compatible with artifact or superficial vessel. Optical coherence tomography angiography of the deep capillary plexus divided into four quadrants for grading (C'), demonstrating disruption of the outline of the FAZ in two or fewer quadrants and thus given the score of mild/moderate macular ischemia per our novel grading system. Optical coherence tomography angiography of the choriocapillaris divided into four quadrants for grading (D'), demonstrating the presence of macular ischemia per our binary grading system.

to evaluate the degree of ischemia in the deep capillary plexus and the choriocapillaris. We also collected the parafoveal flow indices calculated by the OCT software for each patient and examined their relationship to the DMI grades assigned to their respective images.

METHODS

Data Collection

In this retrospective study, clinical data and images were obtained by systematically reviewing the charts of 24 patients

who attended medical retina clinics over a 3-month period of time. Approval for data collection and analysis was obtained from the Institutional Review Board of Moorfields Eye Hospital and adhered to the tenets set forth in the Declaration of Helsinki.

Patient demographic data, retinopathy, and maculopathy grades were obtained from the patient's electronic medical records. Patients with a diagnosis of DR who had undergone both OCT angiography and conventional FA during the same 3-month time period were included in the study. A total of 24 patients were identified who met the imaging criteria. There were 12 (50%) patients who had both FA and OCT angiography on the same day, 4 (16.7%) within 1 month, 1 (4.2%) within 2 months, and 7 (29.2%) within 3 months. The FA and OCT angiography images of the superficial capillary plexus were graded according to standard ETDRS protocols. The images were reviewed by two graders who independently assigned an ETDRS-defined DMI grade. Both graders were masked; that is, FA and OCT angiography images were graded independently. The deep capillary plexus and choriocapillaris were both assessed with grading systems we developed for this project. The parafoveal flow indices for the superficial capillary plexus, the deep capillary plexus, and the choriocapillaris were collected and analyzed for each of the 24 patients.

Image Acquisition Protocol

All OCT angiography images were acquired with an OCT system (Optovue RTVue XR Avanti; Optovue, Inc., Fremont, CA, USA) using automated segmentation algorithms and overlapping B-scan OCT angiography images in a manner previously described by Spaide et al.⁴ The scanning area was captured in 3×3 -mm sections. The images were centered on the macula for all of the 24 images obtained. The superficial and deep capillary plexus and the choriocapillaris were visualized for the purpose of this study. All conventional angiographic images were acquired with either of two digital retinal camera systems (Topcon TRC 50IX; Topcon Medical Systems, Inc., Paramus, NJ, USA) (Heidelberg Spectralis; Heidelberg Engineering, Vista, CA, USA). A single early- to midphase image, centered on the macula, was chosen for analysis of DMI. A late-phase image was chosen for analysis of leakage of perifoveal capillaries. Images were acquired with a 30° field. The FA images were cropped to 3×3 mm, centered on the fovea for comparability to OCT angiography images. No further image manipulation was performed prior to grading.

Qualitative Analysis of FA Images

Diabetic macular ischemia was graded by two assessors using protocols and standard photographs from ETDRS.^{2,5} Briefly, patients were given a score of absent (no disruption of the FAZ), questionable (outline is not smooth or oval, but changes are not clearly pathologic), mild (outline of the FAZ is destroyed for less than half the original circumference), moderate (outline of the FAZ is destroyed for greater than half the original circumference), severe (outline of the FAZ is completely destroyed), or ungradable.^{2,5} Diabetic macular edema was graded as focal (discrete leakage from microaneurysms), diffuse (broad areas of generalized capillary leakage), or ungradable (due to poor image quality).

Qualitative Analysis of OCT Angiography Images

Diabetic macular ischemia was graded in a similar fashion for the 3×3 OCT angiography images. For the superficial capillary plexus, the same protocol (as with FA images) was used by both assessors and was used to assess agreement between FA and OCT angiographic images (Figs. 1A, 1B). The deep

TABLE 1. Patient Demographics and Clinical Characteristics of Patients With and Without Diabetic Macular Ischemia

	N (%)
Age, y, mean	57
Sex, female/male	8/16
Eye, right/left	14/10
Diabetic retinopathy and maculopathy grades	
NPDR	13 (54.2)
PDR, treated and untreated	11 (45.8)
No CSME	5 (20.8)
CSME	19 (79.2)
Previous treatment	
PRP	9 (37.5)
Macular laser	10 (41.7)
Anti-VEGF	7 (29.2)
FA and OCT angiography imaging	
Same day	12 (50)
Within 1 mo	4 (16.7)
Within 2 mo	1 (4.2)
Within 3 mo	7 (29.2)

NPDR, nonproliferative diabetic retinopathy; PDR, proliferative diabetic retinopathy; CSME, clinically significant macular edema.

capillary plexus and choriocapillaris were graded with a novel grading system devised by our study group (Figs. 1C, 1D). The 3×3 images of the macula were divided into four equal quadrants (Figs. 1C, 1D). Disruption was noted as being absent (no disruption of the FAZ), questionable (outline is not smooth or oval, but changes are not clearly pathologic), mild/moderate (outline of the FAZ disrupted in two or fewer quadrants), severe (outline of the FAZ disrupted in three or more quadrants), or ungradable (due to poor image quality or artifact). The choriocapillaris was graded in a binary fashion as present or absent. The presence of ischemia was defined as the loss of speckled hyperreflectance homogeneity or the presence of dark defects not compatible with artifact or superficial vessel shadows. If a determination could not be made, it was deemed ungradable.

Data Analysis and Statistical Methods

Weighted κ values were calculated for intragrader and intergrader assessor agreement. The scale used for interpretation of weighted κ statistics was as follows: slight agreement (0.01–0.20), fair agreement (0.21–0.40), moderate agreement (0.41–0.60), substantial agreement (0.61–0.80), and almost perfect agreement (0.81–0.99). In addition, binary logistic regression was used to test for associations between clinical characteristics and agreement. Spearman's correlation, and 2-

way ANOVA was used to test associations between flow index measurements. Statistical analyses were performed using SPSS software (version 21; SPSS, Inc., Chicago, IL, USA).

RESULTS

Patient Characteristics

Of the 24 patients (24 eyes) included in our study, 16 were male and 8 female, with a median age of 57 years. There were 13 patients with nonproliferative DR and 11 patients with proliferative DR. There were 19 patients with clinically significant macular edema. Nine patients were previously treated with panretinal photocoagulation (PRP). Ten patients were previously treated with a focal macular laser. Seven patients had previously been treated with ranibizumab or bevacizumab (Table 1). Twelve out of the 24 patients had more than 2 weeks elapse between their FA study and OCT angiography.

Agreement Between FA and OCT Angiography–Derived Grades of DMI

Images from FA and OCT angiography–derived images of the superficial retinal capillary plexus showed moderate agreement. The intragrader-weighted κ for graders 1 and 2 were 0.53 (SE = 0.131) and 0.41 (SE = 0.16), respectively (Table 2). A mean of 60.4% of patients had no difference in DMI grades, 33.3% with a one-grade difference, and 2.1% with a two-grade difference between FA and OCT angiography images. A total of 4.2% of images were ungradable (Table 3).

There were no relationships between the agreement in FA and OCT angiography–derived macular ischemia grades with sex, eye graded, visual acuity, DR or maculopathy grade, previous treatment with of PRP or macular laser, and anti-VEGF therapy.

Reproducibility of OCT Angiography Grading

The intergrader agreement for the superficial capillary plexus acquired by OCT angiography demonstrated substantial agreement, with a weighted κ of 0.65 (SE = 0.119). There were 18 (75%) patients who had identical OCT angiography–based DMI grades, 4 (16.67%) with a one-grade difference and 2 (8.33%) with two-grade differences. In two patients, the OCT angiography images were of a poor quality and were deemed ungradable by both graders. The intergrader agreement for the deep capillary plexus was also substantial, with a weighted κ of 0.61 (SE = 0.15). There were 17 (70.8%) patients who had identical OCT angiography–based DMI grades, 5 (20.8%) with a one-grade difference, and 0 (0%) had a two-grade difference. There were two (8.3%) patients deemed gradable by one

TABLE 2. Intra- and Intergrader Agreement for ETDRS-DMI Grades Derived From OCT Angiography and FA Images

	Weighted κ	Standard Error	Level of Agreement
Intergrader agreement			
FA	0.52	0.13	Moderate
OCT angiography			
Superficial plexus	0.65	0.12	Substantial
Deep plexus	0.61	0.15	Substantial
Choriocapillaris	0.65	0.14	Substantial
Intragrader agreement for OCT angiography and FA			
Grader 1	0.53	0.13	Moderate
Grader 2	0.41	0.16	Moderate

TABLE 3. Step Difference in ETDRS-DMI Grades Between FA and OCT Angiography

ETDRS-DMI Grades	Grader 1		Grader 2	
	<i>n</i>	%	<i>n</i>	%
Superficial retinal capillary plexus vs. FA				
No difference	15	62.5	14	58.3
One grade difference	7	29.2	9	37.5
Two grades difference	1	4.2	0	0.0
Ungradable	1	4.2	1	4.2

reviewer and ungradable by the other for the deep capillary plexus. The intergrader agreement for the choriocapillaris was again substantial, with a weighted κ of 0.65 (SE = 0.14). Twenty (83.3%) patients had identical OCT angiography-based DMI grades, four (16.7%) with a one-grade difference, and zero (0%) had a two-grade difference. In our study, three of the patients were considered ungradable by both graders.

Reproducibility of FA Grading

The intergrader agreement for FA was moderate, with a weighted κ of 0.52 (SE = 0.13). A total of 16 (67%) patients had identical FA-based DMI grades, 8 (33%) had a one-grade difference, and 0 (0%) had a two-grade difference. In one patient, the FA images were of poor quality and were deemed ungradable by both graders.

Detecting Macular Ischemia in Different Retinal Vascular Layers

We further tested the relationships between FA and OCT angiography-derived images for the purpose of detecting the presence of macular ischemia. Binary logistic regression analysis for the detection of macular ischemia (i.e., present or absent) showed that there was a relationship between FA and OCT angiography-based detection of macular ischemia in the superficial plexus ($B = 2.86$, SE = 1.22, $P = 0.02$), but no relationships between FA and the deep plexus ($B = 1.61$, SE = 1.05, $P = 0.13$) or choriocapillaris ($B = 1.20$, SE = 0.53, $P = 0.21$). Figure 2 shows an example where macular ischemia was observed to correspond in the superficial and deep plexi, but not with the choriocapillaris. However, in all of our study patients, we did not observe any relationships in ischemia detection between the superficial plexus, deep plexus, and choriocapillaris on analysis of OCT angiography images alone.

Relationship Between FA and OCT Angiography-Derived Grades of DMI With Flow Index Measurements

The OCT angiography-derived DMI grades from the superficial plexus and choriocapillaris were associated with their respective flow indices ($P = 0.04$, $P = 0.036$). The OCT angiography-derived DMI grades from the deep plexus were significantly associated with the superficial flow index ($P = 0.04$) and choriocapillaris flow index ($P = 0.03$), but we only observed a statistical trend with flow index derived from the deep plexus ($P = 0.13$). Although conventional FA-derived DMI grades were not found to be associated with parafoveal flow index measurements of the superficial plexus ($P = 0.66$), deep plexus ($P = 0.322$), or choriocapillaris ($P = 0.86$), the spread of measurements was greater with severity of ETDRS-defined grades of DMI (Fig. 3).

Relationship Between Capillary Density in Different Retinal Vascular Layers

Avascular area measurements were 0.027 mm² (SD = 0.008) in the superficial and 0.014 mm² (SD = 0.008) in the deep plexus. These also showed a modest association ($r = 0.44$, $P = 0.03$). The mean parafoveal capillary density measurements were 40.9% (SD = 11.7) in the superior plexus, 21.4% (SD = 14.4) in the deep, and 67.1% (SD = 17.5) in the choriocapillaris. The superficial plexus density was correlated to the deep plexus ($r = 0.72$, $P = 0.0001$) but not the choriocapillaris ($P = 0.37$, $P = 0.07$). However, the choriocapillaris showed a modest association with the deep capillary plexus ($r = 0.49$, $P = 0.02$). The mean flow index measurements were 0.04 (SD = 0.013) for the superficial plexus, 0.017 (SD = 0.012) in the deep plexus, and 0.059 (SD = 0.022) in the choriocapillaris and showed a relationship between all three layers (adjusted $R^2 = 0.50$, $P = 0.009$).

DISCUSSION

In our study we performed a retrospective analysis of conventional FA and OCT angiography images obtained from a cohort of 24 patients with DR during a 3-month period of time. We demonstrated that there is moderate agreement between the DMI grading results for OCT angiography of the superficial capillary plexus and conventional FA when utilizing standard ETDRS protocols. In addition, our results revealed that images of the retinal vasculature obtained with OCT angiography can be graded for DMI with substantial intergrader agreement. Finally, we demonstrated that the parafoveal flow indices calculated by the OCT software have a statistically significant relationship with DMI grades of their respective OCT angiography images.

Historically, conventional FA has been the standard for evaluating the degree of DMI in patients with DR.^{2,4,5} Although FA was important in identifying DMI, it has lost favor as a clinical trial end point due to its potential risks and the time and cost involved in performing and grading the test. Fluorescein angiography-assessed DMI is rarely evaluated in clinical trials or studies of DR in comparison with OCT assessment of DME, and our understanding of this component of vision-threatening DR therefore stalled. Optical coherence tomography angiography has the potential to improve clinical trial end points and clinical practice by regular evaluation of DMI in a way that is safely tolerated by patients and time-poor clinicians and scientists.

The most important finding of our study was that the degree of DMI in a given patient might reliably be assessed with images of the superficial capillary plexus obtained with OCT angiography. It is noteworthy that in our study 60.4% of the images of the superficial capillary plexus obtained with OCT angiography were given precisely the same ETDRS grades assigned to their respective conventional FA images. The intragrader-weighted κ scores for the two masked graders demonstrated moderate agreement (0.53 for grader 1 and 0.41 for grader 2) when comparing OCT angiography and conventional FA images. However, the fact that the level of agreement was not higher was not surprising given that the images acquired by OCT angiography and conventional FA were obtained via different imaging modalities. Given the differences in the images obtained, the presence of the level of the agreement identified between the imaging modalities is actually quite remarkable. As a result of our findings, we propose that OCT angiography may be a useful clinical tool in the diagnosis and assessment of DMI. Once validated in further prospective studies, OCT angiography could reduce the

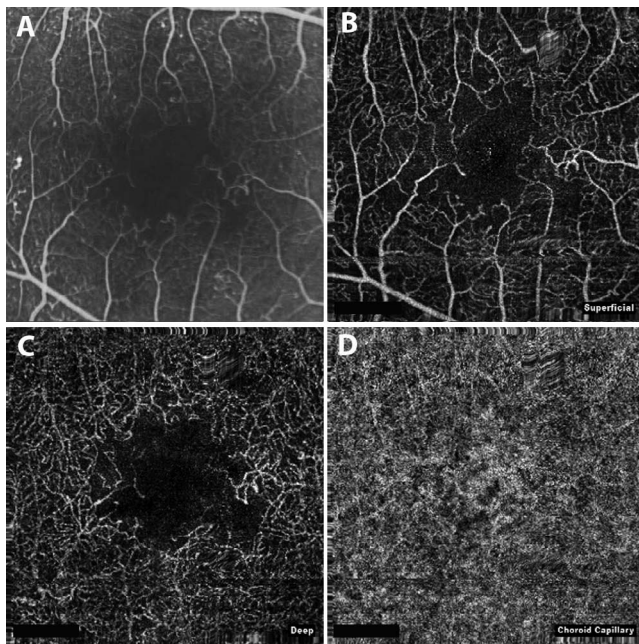


FIGURE 2. An example of FA and OCT angiography images that demonstrated corresponding DMI grades in the superficial and deep vessel plexus but not choriocapillaris. Early-phase FA (20 seconds) (A) demonstrating irregularity of FAZ outline and widening of perifoveal capillary spaces. Optical coherence tomography angiography of the superficial capillary plexus (B) demonstrating corresponding changes. Optical coherence tomography angiography of the deep capillary plexus (C) demonstrating reduction of capillary density in areas corresponding to the superficial plexus where the widening of perifoveal capillary spaces were observed. Preserved speckled (mottled) hyperreflectance homogeneity in the choriocapillaris (D) and the absence of dark defects.

number of indications for which patients would need to be subjected to conventional FA. This could improve patient safety given the documented risks of conventional FA. In addition, it could potentially improve clinical efficiency given the time-consuming nature of performing FA.

Another important finding of our study was the high degree of intergrader agreement for DMI grades when evaluating the images obtained with OCT angiography. We found that the DMI grades for OCT angiography were more reproducible than conventional FA grades in our patients. The intergrader agreement for the superficial capillary plexus acquired by OCT angiography was substantial, with a weighted κ of 0.65. There were 18 (75%) patients who had identical OCT angiography-based DMI grades for the superficial plexus. The intergrader agreement for the deep capillary plexus was also substantial, with a weighted κ of 0.61 (SE = 0.15). There were 17 (70.8%) patients who had identical OCT angiography-based DMI grades. The intergrader agreement for the choriocapillaris was again substantial, with a weighted κ of 0.65 (SE = 0.14). There were 20 (83.3%) patients who had identical OCT angiography-based DMI grades for the choriocapillaris. The level of intergrader agreement for the OCT angiography images was substantially higher than the intergrader agreement for conventional FA in our study, which had a weighted κ of 0.52 (SE = 0.13). The higher agreement between OCT angiography scores may allow for a more consistent scoring of the outline of the FAZ than is possible with conventional FA. Once validated with a larger patient population, this high level of intergrader agreement in evaluating macular ischemia could mean that OCT angiography could potentially be a valuable clinical and

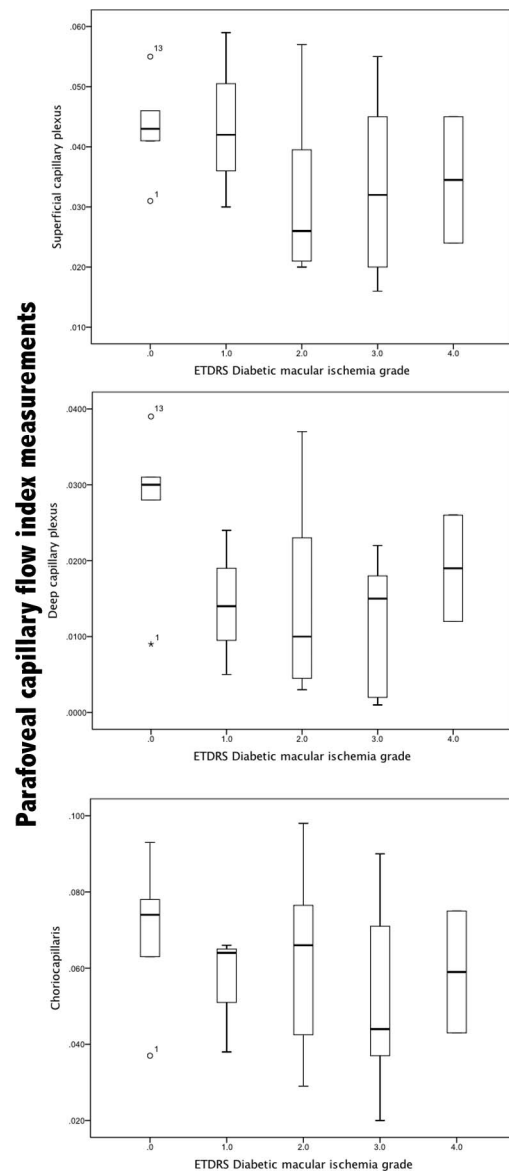


FIGURE 3. Box plot demonstrating statistically significant relationship between OCT angiography-derived DMI grades and the parafoveal flow indices from the superficial plexus (top) and choriocapillaris (bottom) and a trend toward significance for the deep capillary plexus (middle).

research tool by providing consistent and reproducible ischemia grades.

An additional important finding of our study was that OCT angiography-derived DMI grades from the superficial plexus and choriocapillaris have a statistically significant relationship with the flow indices calculated by the OCT software ($P = 0.04$, $P = 0.036$). In other words, when the flow indices were decreased, the ischemia grades indicated a greater severity of disease in a statistically significant fashion. This same finding could not be demonstrated for the deep capillary plexus in a statistically significant manner; however, a trend toward this same relationship was found. It is also noteworthy that the FA-based macular ischemia grades for these patients did not correspond to the flow indices in a statistically significant fashion for the superficial capillary plexus, deep capillary plexus, or the choriocapillaris. Once further validated, our findings suggest that the parafoveal flow indices calculated by

the OCT angiography software could be a valuable indicator of the degree of DMI.

Our study has several limitations. First, the retrospective nature of the study is a recognized weakness. Future prospective studies should be undertaken to further validate our findings. Second, the small sample size included in the study places limits on the conclusions that can be drawn from the data. Larger numbers of patients need to be evaluated with OCT angiography before our findings can be fully validated. Finally, our interpretation of some images was limited by a segmentation artifact. The segmentation artifact appeared to be caused by patient motion during imaging. The recognition of a motion artifact as a limitation of OCT angiography has recently been described in detail by Spaide et al.¹⁵

The future of OCT angiography is promising.¹⁶ Although it is unlikely to replace conventional FA in its current form, it has the potential to alter clinical practice and reduce the indications for which FA is performed.

When considering the data in the RIDE and RISE trials, it is conceivable that the information obtained via OCT angiography could have the potential to identify patients at risk of progression to proliferative retinopathy who are undergoing treatment for DMO.³ We believe that once our findings have been validated in larger prospective trials, clinicians will monitor DMI with OCT angiography rather than conventional FA.

Acknowledgments

Supported by the Department of Health's National Institute for Health Research Biomedical Research Centre for Ophthalmology at Moorfields Eye Hospital, London, United Kingdom, and UCL Institute of Ophthalmology, London, United Kingdom (CAE, PAK, DAS, AT). The views expressed in the publication are those of the author and not necessarily those of the Department of Health.

Disclosure: **P.D. Bradley**, None; **D.A. Sim**, Allergan (R); **P.A. Keane**, Allergan (R); **J. Cardoso**, None; **R. Agrawal**, None; **A. Tufail**, Heidelberg Engineering (S), Novartis (S), Optovue (S), Pfizer (S), GSK (S), Thrombogenics (S), Bayer (S), Allergan (S); **C.A. Egan**, Novartis (F S)

References

1. Beltramo E, Porta M. Pericyte loss in diabetic retinopathy: mechanisms and consequences. *Curr Med Chem*. 2013;20:3218-3225.
2. Sim DA, Keane PA, Zarranz-Ventura J, et al. Predictive factors for the progression of diabetic macular ischemia. *Am J Ophthalmol*. 2013;156:684-692.
3. Ip MS, Domalpally A, Sun JK, Ehrlich JS. Long-term effects of therapy with ranibizumab on diabetic retinopathy severity and baseline risk factors for worsening retinopathy. *Ophthalmology*. 2015;122:367-374.
4. Spaide RF, Klancnik JM Jr, Cooney MJ. Retinal vascular layers imaged by fluorescein angiography and optical coherence tomography angiography. *JAMA Ophthalmol*. 2015;133:45-50.
5. Classification of diabetic retinopathy from fluorescein angiograms. ETDRS report number 11. Early Treatment Diabetic Retinopathy Study Research Group. *Ophthalmology*. 1991;98(suppl 5):807-822.
6. Jia Y, Bailey ST, Hwang TS, et al. Quantitative optical coherence tomography angiography of vascular abnormalities in the living human eye. *Proc Natl Acad Sci U S A*. 2015;112:E2395-E2402.
7. Yannuzzi LA, Rohrer KT, Tindel LJ, et al. Fluorescein angiography complication survey. *Ophthalmology*. 1986;93:611-617.
8. Mariampillai A, Standish BA, Moriyama EH, et al. Speckle variance detection of microvasculature using swept-source optical coherence tomography. *Opt Lett*. 2008;33:1530-1532.
9. Enfield J, Jonathan E, Leahy M. In vivo imaging of the microcirculation of the volar forearm using correlation mapping optical coherence tomography (cmOCT). *Biomed Opt Express*. 2011;2:1184-1193.
10. Chui TY, Vannasdale DA, Burns SA. The use of forward scatter to improve retinal vascular imaging with an adaptive optics scanning laser ophthalmoscope. *Biomed Opt Express*. 2012;3:2537-2549.
11. Jia Y, Tan O, Tokayer J, et al. Split-spectrum amplitude-decorrelation angiography with optical coherence tomography. *Opt Express*. 2012;20:4710-4725.
12. Miura M, Makita S, Iwasaki T, Yasuno Y. Three-dimensional visualization of ocular vascular pathology by optical coherence angiography in vivo. *Invest Ophthalmol Vis Sci*. 2011;52:2689-2695.
13. Jia Y, Bailey ST, Wilson DJ, et al. Quantitative optical coherence tomography angiography of choroidal neovascularization in age-related macular degeneration. *Ophthalmology*. 2014;121:1435-1444.
14. Spaide RF, Klancnik JM Jr, Cooney MJ. Retinal vascular layers in macular telangiectasia type 2 imaged by optical coherence tomographic angiography. *JAMA Ophthalmol*. 2015;133:66-73.
15. Spaide RF, Fujimoto JG, Waheed NK. Image artifacts in optical coherence tomography angiography. *Retina*. 2015;35:2163-2180.
16. Nagiel A, Sadda SR, Sarraf DA. Promising future for optical coherence tomography angiography. *JAMA Ophthalmol*. 2015;133:629-630.