

Multimodal Imaging of Reticular Pseudodrusen in a Population-Based Setting: The Alienor Study

Hélène Chan,¹⁻³ Audrey Cougnard-Grégoire,^{1,2} Marie-Noëlle Delyfer,¹⁻³ France Combillet,^{2,3} Marie-Bénédicte Rougier,¹⁻³ Cédric Schweitzer,¹⁻³ Jean-François Dartigues,^{1,2} Jean-François Korobelnik,¹⁻³ and Cécile Delcourt^{1,2}

¹Inserm U1219, Bordeaux Population Health Research Center, Bordeaux, France

²Université de Bordeaux, ISPED, Bordeaux, France

³CHU de Bordeaux, Service d'Ophtalmologie, Bordeaux, France

Correspondence: Cécile Delcourt, Inserm U1219, Université de Bordeaux, 146 rue Léo Saignat, 33076 Bordeaux Cedex, France; cecile.delcourt@isped.fr

Submitted: March 3, 2016

Accepted: May 5, 2016

Citation: Chan H, Cougnard-Grégoire A, Delyfer M-N, et al. Multimodal imaging of reticular pseudodrusen in a population-based setting: The Alienor Study. *Invest Ophthalmol Vis Sci*. 2016;57:3058-3065. DOI:10.1167/iov.16-19487

PURPOSE. To document reticular pseudodrusen (RPD) using multimodal imaging in French elderly subjects.

METHODS. A total of 494 subjects (970 eyes) aged 77 years or more, from the Alienor study, were examined in 2011 and 2012. Reticular pseudodrusen were defined as definite if they were present with at least two imaging methods among color retinal photographs, macular cube (20° × 15°) of spectral-domain optical coherence tomography (SD-OCT), fundus autofluorescence (FAF), and infrared reflectance (IR). The Youden index was calculated as specificity + sensitivity - 1.

RESULTS. The prevalence of definite RPD was 13.4% and was higher among women (15.6%) than men (10.2%). It increased with age and reached almost 50% in subjects over 85 years. Infrared reflectance was the most sensitive technique (100%) and color fundus photography the least sensitive (34.5% at left eyes and 48.1% at right eyes). The best Youden index was obtained with IR (0.96 at both eyes) followed by SD-OCT (0.87 at right eye and 0.78 at left eye). Reticular pseudodrusen were present in 4.6% of eyes without AMD, 13.0% with early AMD1, 62.6% with early AMD2, 34.6% with atrophic AMD, and 8.1% with neovascular AMD. Reticular pseudodrusen were significantly associated with central and pericentral intermediate soft drusen (odds ratio [OR]: 2.14; 95% confidence interval [CI] = 1.11-4.14 and OR: 1.49; 95% CI = 1.16-1.90, respectively) and central large soft drusen (OR: 1.67; 95% CI = 1.16-2.42).

CONCLUSIONS. Using multimodal imaging, the prevalence of RPD appears higher than previously reported in studies based on retinal photography only. Reticular pseudodrusen frequently accompany other signs of AMD. Infrared reflectance and SD-OCT appear to be particularly relevant methods to diagnose RPD.

Keywords: reticular pseudodrusen, reticular drusen, age-related macular degeneration, scanning laser ophthalmoscopy, fundus autofluorescence, infrared reflectance, optical coherence tomography, multimodal imaging, population-based study

Age-related macular degeneration (AMD) represents the most common cause of blindness in elderly people in industrialized countries.¹ In the early and intermediate stages of AMD, drusen and pigmentary abnormalities are the characteristic phenotypes of the disease. Based on fundus biomicroscopy, drusen are focal deposits of extracellular material located between the retinal pigment epithelium (RPE) and Bruch's membrane and have been classified as hard, soft, cuticular, or calcified drusen.² Since their first description in 1990 by Mimoun et al.,³ reticular pseudodrusen (RPD) have been identified as an additional phenotype of early AMD associated with high risk of progression to advanced AMD.⁴ Initially named "pseudodrusen visible en lumière bleue," terms like subretinal drusenoid deposit, reticular macular disease, and reticular drusen are also commonly found in the context of RPD.⁴⁻⁶ In contrast to conventional drusen, RPD are not located under but above the RPE. Indeed, in optical coherence tomography (OCT), they correspond to granular hyperreflec-

tive deposits in the subretinal space between the RPE and the boundary between the inner and outer segments of the photoreceptors.^{6,7} They are typically located along the superior vascular arcades, realizing a fundus appearance of a yellowish interlacing network of oval or roundish lesions with a diameter of approximately 125 to 250 μm.^{4,8}

In the Beaver Dam Eye Study⁹ and the Blue Mountains Eye Study,¹⁰ the only two longitudinal population-based studies having documented RPD using color fundus photography, the proportion of eyes with RPD that progressed to late AMD within 5 years was 4- to 6-fold higher compared with eyes without RPD but with other early AMD lesions.^{9,10} All studies consistently report a high degree of bilaterality, a preponderance of older age and female sex, and the occurrence of RPD in all AMD phenotypes such as geographic atrophy, choroidal neovascularization or drusen, yet showing the highest prevalence of RPD in multilobular geographic atrophy.^{4,8,10-18}



Several multimodal imaging studies have shown that fundus autofluorescence (FAF), infrared reflectance (IR), spectral-domain OCT (SD-OCT), and multicolor imaging (MC) are superior to other modalities in detecting RPD, including fundus photography, blue channel image of fundus photography, confocal blue reflectance, fluorescein angiography, and indocyanine green angiography. Several authors advise the use of at least two imaging modalities for accurate RPD identification.^{4,19,20} While multimodal imaging has been widely used for documenting RPD in clinical studies, epidemiologic studies have until now relied only on fundus photography, which lacks sensitivity in RPD detection.

In the present study, we documented RPD in a population-based study of elderly French subjects using multimodal imaging that included four methods: color fundus photography, FAF, IR, and SD-OCT imaging.

SUBJECTS AND METHODS

Study Population

The Alienor (Antioxydants, Lipides Essentiels, Nutrition et maladies OculaiRes) Study is a population-based prospective study conducted to assess the associations of age-related eye diseases (AMD, glaucoma, cataract, dry eye syndrome) with nutritional factors, determined from plasma measurements and estimation of dietary intakes.²¹ It also takes into account other major determinants of eye diseases, including gene polymorphisms, environmental factors, and vascular factors.

Subjects of the Alienor Study were recruited from an ongoing population-based study (Three-City [3C] Study) on the vascular risk factors for dementia.²² The 3C Study included 9294 subjects aged 65 years and older in 1999 from three French cities (Bordeaux, Dijon, and Montpellier), among whom 2104 were recruited in Bordeaux. Subjects were contacted individually from the electoral rolls. They were initially recruited between 1999 and 2001 and were followed up approximately every 2 years after baseline. Data collected at each examination included cognitive testing with diagnosis of dementia and assessment of vascular risk factors. In addition, at baseline, fasting blood and DNA samples were collected and kept frozen at -80°C .

The Alienor Study consists of eye examinations, which have been offered to all participants of the 3C cohort in Bordeaux since the third follow-up (2006–2008).²¹ In 2011 and 2012, color fundus photography, SD-OCT, FAF, and IR were included in the eye examination. Among the 1235 participants of the 3C cohort in Bordeaux who were still alive, 759 subjects (61%) accepted this examination. Among them, the eye examination was performed at the home of 257 participants because they were unable to come to the hospital. For those subjects, only fundus photography was available, and they were thus excluded from the present study. In addition, data were missing for at least two methods in eight subjects, leaving 494 participants (970 eyes) for the statistical analysis.

The Alienor Study was conducted in compliance with the Declaration of Helsinki. The design of the Alienor Study was approved by the Ethical Committee of Bordeaux (Comité de Protection des Personnes Sud-Ouest et Outre-Mer III) in May 2006. All participants were informed about the study and gave their written informed consent.

Eye Examination

The eye examination was performed in the Department of Ophthalmology of the University Hospital of Bordeaux. It included a recording of ophthalmic history, measures of visual

acuity, refraction, two 45° nonmydriatic color fundus photographs, SD-OCT, FAF, and IR imaging.

Color fundus photographs (one centered on the macula, the other centered on the optic disc) were performed using a high-resolution digital nonmydriatic retinograph (TRC NW6S; Topcon, Tokyo, Japan). Such high-resolution digital photographs have shown comparable grading qualities to those of previous film-based photographs.²³ Color and contrast were adjusted if needed to obtain better images when interpreting.

The SD-OCT examination was performed using Spectralis (Software Version 5.4.7.0; Heidelberg Engineering, Heidelberg, Germany). Fundus autofluorescence and IR images were obtained using the confocal scanning laser ophthalmoscope (CSLO) of the same device. Fundus autofluorescence images were obtained using an excitation blue light of 488 nm and a barrier filter beginning at 500 nm. Infrared reflectance images were obtained at 810 nm. Examination field size for FAF and IR was $30^{\circ} \times 30^{\circ}$ centered on the macula and a $20^{\circ} \times 15^{\circ}$ cube encompassing the macula for SD-OCT, with 19 horizontal B-scans and a distance between scans of 240 μm .

Retinal photographs were interpreted in duplicate by two specially trained technicians. Inconsistencies between the two interpretations were adjudicated by a senior grader, and all cases of late AMD were confirmed by a retina specialist. Fundus autofluorescence, IR images, and SD-OCT were interpreted by three independent retina specialists in a masked fashion; that is, they neither were involved in the interpretation of any other retinal examination nor had access to color images of the participants. Each image series was deemed absent, present, questionable, or ungradable for the presence of RPD. In the present study, questionable abnormalities were considered as absent. We included subjects for whom at least two of the four imaging techniques were gradable.

Definitions

Reticular Pseudodrusen. On color fundus photography, RPD were identified as yellowish interlacing networks ranging from 125 to 250 μm in width (Fig.).³ On SD-OCT, they were identified as well-defined round or triangular hyperreflective deposits localized between the RPE and the boundary between the inner and outer segments of the photoreceptors (IS/OS boundary) and as small mounds that broke through the IS/OS boundary in more advanced stages.⁷ All stages of RPD were considered. On FAF and IR, RPD were identified as an area of isoautofluorescence/reflectance surrounded by halos of reduced autofluorescence/reflectance, responsible for the “target aspect.”²⁴ Retinal pseudodrusen were defined as definite if they were classified as present with at least two imaging methods from among color fundus photography, FAF, IR, and SD-OCT.

Classification of AMD. Retinal photographs were interpreted according to the international classification and to a modification of the grading scheme used in the Multi-Ethnic Study of Atherosclerosis (MESA) for drusen size, location, and area.^{25,26} Late AMD was defined by the presence of neovascular AMD or geographic atrophy within the grid (3000 μm from the foveal center). Neovascular AMD included serous or hemorrhagic detachment of the RPE or sensory retina, subretinal or sub-RPE hemorrhages, and fibrous scar tissue. Geographic atrophy was defined as a discrete area of retinal depigmentation, 175 μm in diameter or larger, characterized by a sharp border and the presence of visible choroidal vessels. In addition, SD-OCT macular scans (vertical and horizontal lines, macular volume) were interpreted by a retina specialist for signs of retinal atrophy and neovascular AMD (subretinal fluid, subretinal tissue, pigment epithelium detachment, intraretinal fluid). Finally, classification of late atrophic and neovascular

TABLE 1. Prevalence of Reticular Pseudodrusen (RPD) in the Alienor Study, Bordeaux (France), 2011 and 2012, % (*n*)

	Fundus Photo	FAF	SD-OCT	IR	Definite RPD*
Sex					
Men	<i>N</i> = 193, 5.2 (10)	<i>N</i> = 183, 7.6 (14)	<i>N</i> = 204, 15.6 (32)	<i>N</i> = 191, 13.6 (26)	<i>N</i> = 205, 10.2 (21)
Women	<i>N</i> = 271, 7.7 (21)	<i>N</i> = 261, 10.7 (28)	<i>N</i> = 288, 18.7 (54)	<i>N</i> = 272, 21.3 (58)	<i>N</i> = 289, 15.6 (45)
Age, y					
77-79	<i>N</i> = 111, 2.7 (3)	<i>N</i> = 107, 4.7 (5)	<i>N</i> = 118, 8.5 (10)	<i>N</i> = 112, 6.2 (7)	<i>N</i> = 118, 5.9 (7)
80-84	<i>N</i> = 221, 5.4 (12)	<i>N</i> = 213, 8.4 (18)	<i>N</i> = 233, 17.2 (40)	<i>N</i> = 221, 18.1 (40)	<i>N</i> = 233, 12.1 (28)
85+	<i>N</i> = 132, 33.3 (16)	<i>N</i> = 124, 43.6 (19)	<i>N</i> = 142, 54.9 (36)	<i>N</i> = 130, 62.7 (37)	<i>N</i> = 143, 49.5 (31)
Total	<i>N</i> = 464, 6.7 (31)	<i>N</i> = 444, 9.5 (42)	<i>N</i> = 493, 17.4 (86)	<i>N</i> = 463, 18.1 (84)	<i>N</i> = 494, 13.4 (66)

* RPD is considered "definite" when classified as present with at least two methods from among color fundus photography, SD-OCT, FAF, and IR.

AMD was based on all available information (ophthalmologic history and treatments, retinal photographs, OCT scans).

Early AMD was classified from retinal photographs into two groups (in the absence of late AMD): early AMD1 (soft distinct drusen without pigmentary abnormalities or pigmentary abnormalities without large drusen [$>125 \mu\text{m}$]); early AMD2 (soft indistinct drusen and/or reticular drusen and/or soft distinct drusen associated with pigmentary abnormalities [hyper- or hypopigmentation]). Soft distinct and indistinct drusen were larger than $125 \mu\text{m}$ in diameter and with uniform density and sharp edges or decreasing density from the center outward and fuzzy edges, respectively. Pigmentary abnormalities were defined as areas of hyper- and/or hypopigmentation (without visibility of choroidal vessels).

Eyes were classified accordingly into one of the five exclusive groups: no AMD, early AMD1, early AMD2, late atrophic AMD, and late neovascular AMD. In addition, detailed characteristics of early AMD abnormalities were studied, including intermediate drusen ($63\text{--}125 \mu\text{m}$ in diameter), large soft distinct and indistinct drusen ($>125 \mu\text{m}$ in diameter), large area of drusen ($>500 \mu\text{m}$ in diameter), hyperpigmentation, and hypopigmentation. For each item, there were four exclusive categories: absent, questionable, present in pericentral area ($500\text{--}3000 \mu\text{m}$ from fovea), present in central area (within $500 \mu\text{m}$ from fovea) (see Delcourt et al.²⁷ for more details). For the purpose of the present study, questionable abnormalities were considered as absent.

We generated two additional parameters: large soft drusen (combining large soft indistinct and distinct drusen) and pigmentary abnormalities (combining hypo- and hyperpigmentations).

Statistical Analysis

For the estimation of prevalence, subjects were classified according to their worse eye, while for evaluation of methods for RPD diagnosis, each eye was studied. Sensitivity and

specificity values for each imaging modality were calculated against the presence of definite RPD (diagnosed with at least two imaging methods). We first studied the association of RPD with the different stages of AMD and then analyzed the association with all characteristics of early AMD, as defined in our grading scheme. Associations between each stage of AMD and each type of early AMD characteristics and RPD were estimated using logistic generalized estimating equations (GEE) models taking into account data from both eyes and their intraindividual correlations.²³ The associations are presented as odds ratios (ORs) and 95% confidence intervals (CIs). Eyes without RPD were the reference in all models. Analyses were adjusted for age and sex.

Values of $P < 0.05$ were considered significant. All statistical analyses were performed using SAS version 9.3 (procedure GENMOD for the generalized estimating equations analysis; SAS Institute, Inc., Cary, NC, USA).

RESULTS

Four hundred ninety-four subjects (970 eyes) aged 77 years or older were included; 59% were women. Age ranged from 77 to 92 years, with a mean of 83 years (standard deviation: 3.8). Of these 970 eyes, 968 (99.7%) had good image quality on SD-OCT, 928 (95.6%) on IR, 902 (92.9%) on color fundus photography, and 843 (86.9%) on FAF. The prevalence of definite RPD in at least one eye was 13.4% (66/494 subjects) and was higher among women (15.6%) than men (10.2%) (Table 1). The prevalence increased steeply with age and reached almost 50% in subjects aged 85 years or more. Regarding imaging techniques, prevalence of RPD was the lowest when diagnosed by fundus photography (6.7%) and FAF (9.5%) and the highest when diagnosed with IR (18.1%) or SD-OCT (17.4%), although the predominance of women and the increase with age was found with all techniques.

Specificity was at least 95% for all methods (Table 2). Infrared reflectance was the most sensitive imaging technique

TABLE 2. Sensitivity and Specificity of Different Methods for the Detection of Definite Reticular Pseudodrusen in the Alienor Study, Bordeaux (France), 2011 and 2012

	Left Eye				Right Eye			
	<i>N</i>	Sensitivity†, %	Specificity†, %	Youden Index*	<i>N</i>	Sensitivity†, %	Specificity†, %	Youden Index*
Fundus photo	448	34.6 (23.4;47.8)	99.8 (98.6;100.0)	0.34	454	48.2 (35.4;61.2)	100.0 (99.1;100.0)	0.48
FAF	419	74.0 (60.5;84.1)	100.0 (99.0;100.0)	0.74	424	65.5 (52.3;76.6)	99.7 (98.5; 100.0)	0.65
SD-OCT	483	89.7 (79.2;95.2)	97.7 (95.7;98.7)	0.87	485	83.1 (71.5;90.5)	94.8 (92.2;96.6)	0.78
IR	463	100.0 (93.8;100.0)	95.6 (93.1;97.2)	0.96	465	100 (93.9;100.0)	95.8 (93.4;97.4)	0.96

* Youden index = sensitivity + specificity - 1.

† Sensitivity and specificity are given with their 95% confidence intervals between parentheses.

TABLE 3. Associations of Different Stages of Age-Related Macular Degeneration and Early AMD Characteristics With Reticular Pseudodrusen in the Alienor Study, Bordeaux (France), 2011 and 2012

	% With Reticular Pseudodrusen	Age- and Sex-Adjusted OR (95% CI)	P Value
Stages of AMD			
No, <i>n</i> = 633	4.58	1.00 (Reference)	
Early AMD1, <i>n</i> = 131	12.98	1.51 (1.03;2.20)	0.03
Early AMD2, <i>n</i> = 83	62.65	3.22 (1.64;6.33)	0.0007
Late atrophic AMD, <i>n</i> = 26	34.62	2.88 (0.63;13.19)	0.17
Late neovascular AMD, <i>n</i> = 37	8.11	0.41 (0.03;6.36)	0.52
Intermediate soft drusen			
No, <i>n</i> = 507	3.35	1.00 (Reference)	
Pericentral, <i>n</i> = 234	16.67	1.49 (1.16;1.90)	0.002
Central, <i>n</i> = 109	41.28	2.14 (1.11;4.14)	0.02
Large soft drusen			
No, <i>n</i> = 769	9.49	1.00 (Reference)	
Pericentral, <i>n</i> = 49	30.61	1.42 (0.92;2.18)	0.11
Central, <i>n</i> = 38	34.21	1.67 (1.16;2.42)	0.006
Distinct soft drusen			
No, <i>n</i> = 779	9.88	1.00 (Reference)	
Pericentral, <i>n</i> = 51	33.33	1.52 (0.95;2.43)	0.08
Central, <i>n</i> = 26	26.92	0.85 (0.19;3.73)	0.83
Indistinct soft drusen			
No, <i>n</i> = 823	11.06	1.00 (Reference)	
Pericentral, <i>n</i> = 19	21.05	1.16 (0.76;1.77)	0.49
Central, <i>n</i> = 14	42.86	1.92 (0.47;7.82)	0.36
Large area of soft drusen			
No, <i>n</i> = 798	9.52	1.00 (Reference)	
Pericentral, <i>n</i> = 51	47.06	2.15 (0.69;6.67)	0.19
Central, <i>n</i> = 7	14.29	1.85 (0.57;6.03)	0.31
Hyperpigmentation			
No, <i>n</i> = 693	9.38	1.00 (Reference)	
Pericentral, <i>n</i> = 57	19.30	1.47 (0.99;2.18)	0.05
Central, <i>n</i> = 58	36.21	1.15 (0.68;1.97)	0.60
Hypopigmentation			
No, <i>n</i> = 682	9.82	1.00 (Reference)	
Pericentral, <i>n</i> = 71	18.31	1.15 (0.68;1.93)	0.60
Central, <i>n</i> = 57	31.58	1.27 (0.67;2.43)	0.46
Pigmentary abnormalities			
No, <i>n</i> = 670	9.70	1.00 (Reference)	
Pericentral, <i>n</i> = 72	15.28	1.12 (0.70;1.79)	0.64
Central, <i>n</i> = 68	32.35	1.33 (0.73;2.43)	0.34

for detecting RPD (100% at both right and left eyes), followed by SD-OCT (89.7% for left eyes and 83.1% at right eyes) and FAF (74% at left eyes and 65.5% at right eyes) (Table 2). Color fundus photography had low sensitivity: 34.6% on left eyes and 48.2% on right eyes. Infrared reflectance imaging presented the best Youden index (0.96 at both eyes), followed by SD-OCT (0.87 at left eye and 0.78 at right eye).

Associations between the presence of RPD diagnosed with at least two imaging methods and different stages of AMD are presented in Table 3. Reticular pseudodrusen were found in 4.6% of eyes with no AMD, 13.0% of eyes in early AMD1, 62.6% of eyes with early AMD2, 34.6% of eyes with late atrophic AMD, and in 8.1% in eyes with neovascular AMD.

After adjustment for age and sex (Table 3), the presence of RPD was significantly associated with an increased risk for early AMD1 (OR: 1.51; 95 CI = 1.03–2.20) and early AMD2 (OR: 3.22; 95 CI = 1.64–6.33) but was not significantly associated

with an increased risk of late atrophic or neovascular AMD (OR: 2.88; 95 CI = 0.63–13.19 and OR: 0.41; 95 CI = 0.03–6.36, respectively).

Then, after exclusion of the subjects affected by late AMD, we detailed the associations of RPD with early abnormalities (Table 3). Reticular pseudodrusen were present in more than 20% of subjects with central intermediate drusen, large soft drusen (whether central or pericentral), distinct soft drusen (central and pericentral), central indistinct soft drusen, pericentral large area of soft drusen, and central pigmentary abnormalities. After adjustment for age and sex, we found a statistically significant positive association of RPD with central intermediate soft drusen (OR: 2.14; 95 CI = 1.11–4.14), pericentral intermediate soft drusen (OR: 1.49; 95 CI = 1.16–1.90), and central large soft drusen (OR: 1.67; 95 CI = 1.16–2.42). Other early abnormalities were not significantly associated with RPD.

TABLE 4. Sensitivity and Specificity of Various Imaging Modalities for Detecting Reticular Lesions

Modality	Smith et al.	Ueda-Arakawa et al.		De Bats et al.		Present Study	
	Sensitivity, %	Sensitivity, %	Specificity, %	Sensitivity, %	Specificity, %	Sensitivity, %, OD/OS	Specificity, %, OD/OS
Fundus photo	88	-	-	33.1	91.9	34.5/48.1	99.7/100
IR	95	94.6	91.8	84.6	100	100	97.6/94.8
SD-OCT	-	94.6	98.4	99.3	100	89.7/83.0	97.6/94.8
FAF	86	86.5	95.0	73.2	96.7	74/65.4	100/99.7
ICG	100	73.0	100.0	-	-	-	-
Red free	88	75.7	100.0	-	-	-	-
MC	-	-	-	87.1	100	-	-

ICG, indocyanine green angiography.

DISCUSSION

Prevalence

Using multimodal imaging, we found a high prevalence of RPD in our population of elderly subjects: 13.36% among subjects between 77 and 92 years. It increased steeply with age, reaching 49% over 85 years of age. This is much higher than in previous studies relying only on fundus photography (2.4% in subjects aged 75–85 years in the Beaver Dam Eye Study,⁹ by comparison with 10.0% in subjects aged 77–85 years in the present study; 1.96% in subjects aged 49–97 years in the Blue Mountains Study¹⁰). When using only fundus photographs, our prevalence estimate was still somewhat higher than that in the Beaver Dam Eye Study (4.5% in subjects aged 77–85 years).

We confirmed the female preponderance that has been found in several studies,^{4,8,11,15,28} as the rate of RPD was 1.5-fold higher in women than in men. However, female predominance was less pronounced than in the two other studies: In the Beaver Dam and the Blue Mountains Eye Study, the 15-year incidence of reticular drusen was 2.5-fold higher in women than in men.^{9,10}

Imaging

As shown in Table 4, according to the other studies that compared different techniques for the diagnosis of reticular lesions (Smith et al.,⁴ Ueda-Arakawa et al.,²⁰ De Bats et al.¹⁹), IR is one of the most sensitive modalities (95%, 95%, and 85%, respectively). Ueda-Arakawa et al.²⁰ and De Bats et al.¹⁹ found a better sensitivity with SD-OCT than in our study (95%, 99%, and 90/83%, respectively). Indeed, they performed a 30° × 10° to 30° × 25° rectangle encompassing the macula and 31 horizontal B-scans of SD-OCT on a 30° × 25° rectangle, respectively, while we used a 20° × 15° macular cube to obtain 19 horizontal B-scans. Thereby, we probably did not diagnose some RPD if they were outside of the cube, because they are frequently located in the pericentral area and near the superior temporal vascular arcade.^{4,13,20} According to the other studies, specificity was high with the four imaging modalities.

Moreover, in our study, some images could not be taken or graded. These represented 13% ($N = 127$) of eyes for FAF, 7% for color fundus photography ($N = 68$), and 4.3% for IR ($N = 42$), whereas all except two eyes had gradable SD-OCT. Indeed, FAF image quality can be significantly impaired by opacities anterior to RPE, particularly cataract, which absorbs the blue excitation light. As the penetration of infrared light is greater (810 nm), IR imaging is more sensitive in subjects with opacities like dense cataract. Similarly, SD-OCT uses a wavelength that is near infrared (840 nm), and the reduction of artifacts and diffraction of light allow obtaining high-

resolution images. Thus, IR is a highly sensitive noninvasive imaging method to detect RPD, which may be complemented by the use of other imaging techniques. Especially SD-OCT allows recognizing reticular lesions and their precise location in different layers of the retina. For Ueda-Arakawa et al.,²⁰ SD-OCT seems to be the best method if the scans are obtained over a wide area that includes the outside of the macula, especially in eyes with choroidal neovascularization (CNV). Overall, use of at least two modalities may be recommended to detect and confirm the diagnosis of reticular lesions.

Association With AMD

We found a significant association of RPD with early AMD (whether stage 1 [OR: 1.51] or stage 2 [OR 3.22]), as well as intermediate soft drusen (whether central [OR: 2.14] or pericentral [OR: 1.49]) and central large soft drusen (OR: 1.67). Numerous studies have shown an association between RPD and manifestations of advanced forms of AMD, but fewer studies are available regarding early macular abnormalities.^{5,9–11,13,15–17,29,30} In the Beaver Dam Study, drusen type was related to the 15-year incidence of RPD (OR per more severe drusen type [hard distinct < soft distinct < soft indistinct]: 1.37) but not to drusen location or area. In the Blue Mountains Eye Study,¹⁰ the location of any soft drusen at close proximity to the fovea (OR: 2.2) and an area of soft drusen between 375 μm and 0.5 disc area in diameter (OR: 3.2) were significantly associated with a greater risk of reticular drusen. Of 332 eyes with RPD, Sarks et al.¹² found that only 2.7% of them did not have any signs of AMD (<10 drusen). Large drusen were found in 36.8% of eyes, neovascular AMD in 28.6%, drusen < 124 μm in 17.2%, parafoveal hyperpigmentation in 8.4%, and geographic atrophy in 5.1%. In a series of 255 eyes with RPD, Lee et al.¹⁵ found 28.2% of patients with no AMD and 45.1% with early AMD. Zweifel et al.⁷ found that only 4/58 eyes with RPD had neither early nor late AMD. Similarly, Cohen et al.¹¹ found only 11 eyes without early or late AMD among 144 eyes with RPD. In a series of 100 subjects with RPD, Arnold et al.⁸ found 35% of them presenting small hard drusen and 48% soft drusen.⁸ In the present study, 29 of 110 eyes (26%) with RPD were classified as no AMD, 69 (63%) as early AMD, and 12 (11%) as late AMD. It appears that RPD are rarely isolated and are more often associated with other early or late macular abnormalities.

We found that only 8% of subjects with neovascular AMD had RPD. We probably underestimated RPD because they are difficult to identify in very advanced neovascular cases. Thus, it has been reported that RPD fade in the vicinity of CNV but often remain identifiable outside the macula.^{4,12,28} Moreover, in the late stages of AMD, RPD are at an advanced stage and more difficult to identify. As already described in the literature, in the present study, there was a strong association between

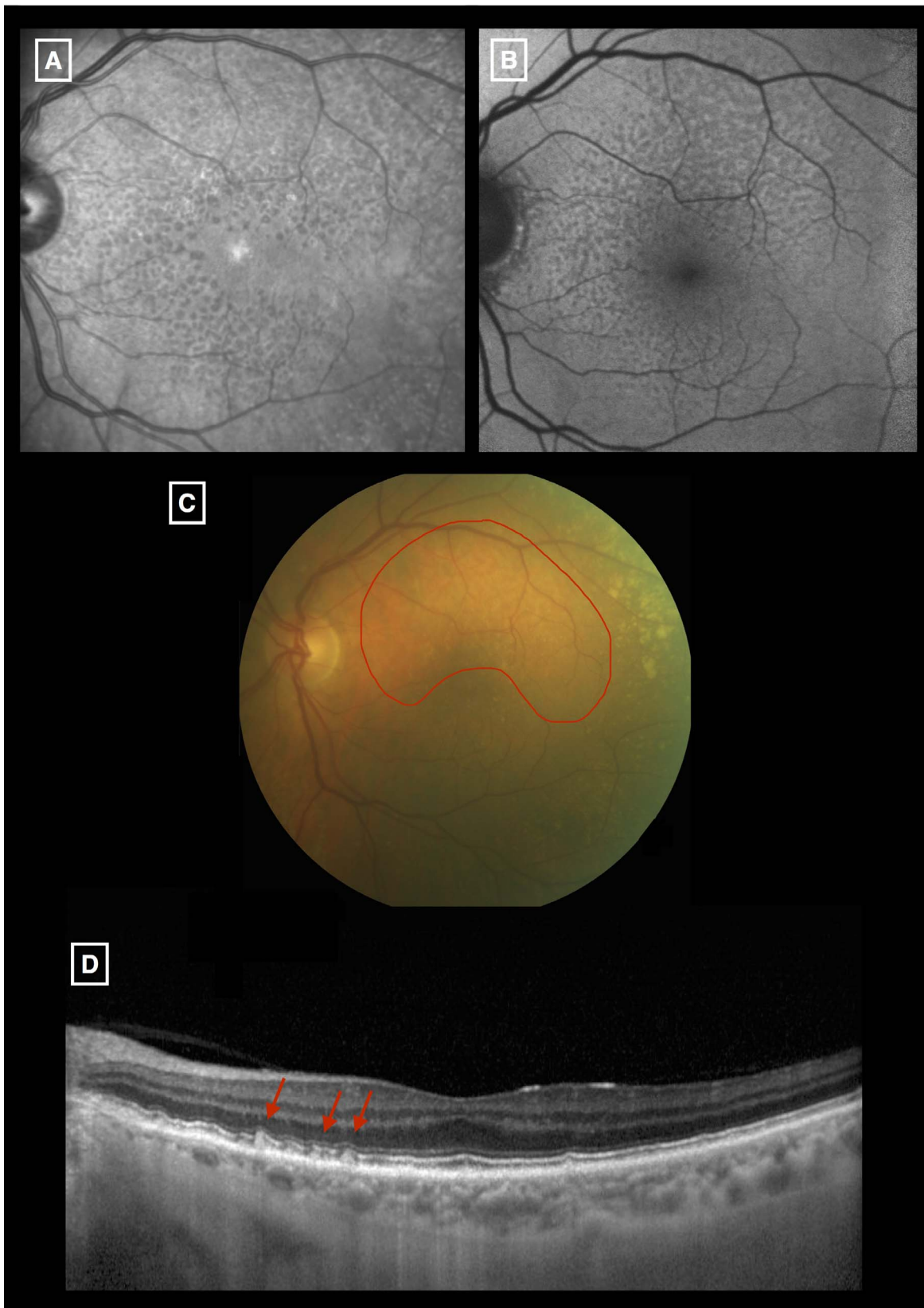


FIGURE. Characteristic signal of reticular lesions by different imaging methods in an 83-year-old woman. Reticular pseudodrusen are clearly visible on infrared reflectance (IR) (A) and fundus autofluorescence (FAF) (B). They are identified as an area of isoautofluorescence/reflectance on the center of each reticular pseudodrusen surrounded by halos of reduced autofluorescence/reflectance, responsible for the “target aspect,” here around the macula, especially along the superior vascular arcades. On color fundus photography (C), RPD (*outlined in red*) are visible along the superior vascular arcades as yellowish interlacing networks ranging from 125 to 250 μm . On spectral-domain optical coherence tomography (SD-OCT) (D), they are identified as well-defined round or triangular hyperreflective deposits localized between, externally, the retinal pigment epithelium layer (RPE) and, internally, the boundary between the inner and outer segments of the photoreceptors (IS/OS boundary) (*arrow*), leading to focal elevation (stage 2) or an abrupt interruption (stage 3) of the inner and outer photoreceptor segment layer.

RPD and late atrophic AMD (OR = 2.9) although it was not statistically significant.^{4,9,13,16,17,29,31}

While the vast majority of published studies are cross sectional, the prognostic value of RPD with regard to the development of atrophic and neovascular AMD can be assessed only through prospective studies. There is a need for such prospective studies, ideally population based, with repeated multimodal imaging of the retina (including at least SD-OCT, IR, and retinal color photographs), over several years, to document the progression of RPD to late AMD (atrophic/neovascular), independently of other early AMD features (soft drusen, pigmentary abnormalities).

Our study has several limitations. Firstly, only 759 (61%) of the 1235 contacted 3C subjects participated in the eye examination. In addition, 257 participants were unable to come to the hospital for the examination and thus were excluded since only fundus photography was available. The subjects included in the present study tended to be younger, of higher socioeconomic status, and healthier compared to other 3C participants (and the general population), thereby limiting the representativeness of our study.

Another limitation is the small number of cases with late AMD (6.9%), which limited the statistical power for detecting associations of neovascular and atrophic AMD with RPD. In addition, some of the late cases were very advanced and thus RPD may not have been visible at this stage, although it may have coexisted with late AMD at earlier stages.

In addition, some imaging modalities were not possible to perform or were ungradable in some participants, particularly for FAF when media opacities were present. Thus, SD-OCT and IR are useful and feasible imaging techniques for the diagnosis of RPD in very elderly subjects. Finally, the scanning range of SD-OCT did not necessarily cover the entire area of other SLO imaging techniques. Therefore, we probably have underestimated the sensitivity of SD-OCT, particularly in cases of CNV where they fade in the vicinity of CNV.

In conclusion, using multimodal imaging, RPD seems to be frequent in subjects over 77 years, particularly over 85 years. Reticular pseudodrusen frequently accompany other signs of early AMD. Their detection is crucial because of the important prognostic information, and the use of multimodal imaging with at least two imaging methods including SD-OCT or one CSLO imaging (IR, FAF) may be recommended in addition to color images. Prospective studies, with follow-up of subjects using such multimodal imaging, are needed to better assess the prognostic value of RPD with regard to the occurrence of late AMD.

Acknowledgments

Supported by Laboratoires Théa (Clermont-Ferrand, France); Université de Bordeaux (Bordeaux, France); and Caisse Nationale de Solidarité pour l'Autonomie CNSA (CNSA). Laboratoires Théa participated in the design of the study, but none of the sponsors participated in the collection, management, statistical analysis, or interpretation of the data, or in the preparation, review, or approval of the present manuscript.

Disclosure: **H. Chan**, None; **A. Cougnard-Grégoire**, Laboratoires Théa (R); **M.-N. Delyfer**, Allergan (C), Bayer (C), Carl Zeiss Meditec (C), Laboratoires Théa (C), Novartis (C); **F. Combillet**, None; **M.-B. Rougier**, Allergan (C), Bayer (C), Bausch & Lomb (C), Laboratoires Théa (C), Novartis (C); **C. Schweitzer**, None; **J.-F. Dartigues**, Ipsen (C), Roche (C); **J.-F. Korobelnik**, Alcon (C), Alimera (C), Allergan (C), Bayer (C), Carl Zeiss Meditec (C), Horus (C), Laboratoires Théa (C, F), Novartis (C), Roche (C); **C. Delcourt**, Allergan (C), Bausch & Lomb (C), Laboratoires Théa (C, R, F), Novartis (C)

References

1. Lim LS, Mitchell P, Seddon JM, Holz FG, Wong TY. Age-related macular degeneration. *Lancet*. 2012;379:1728-1738.
2. Klein R, Davis MD, Magli YL, Segal P, Klein BE, Hubbard L. The Wisconsin age-related maculopathy grading system. *Ophthalmology*. 1991;98:1128-1134.
3. Mimoun G, Soubrane G, Coscas G. Macular drusen [in French]. *J Fr Ophtalmol*. 1990;13:511-530.
4. Smith RT, Sohrab MA, Busuioc M, Barile G. Reticular macular disease. *Am J Ophtalmol*. 2009;148:733-743.
5. Zweifel SA, Imamura Y, Spaide TC, Fujiwara T, Spaide RE. Prevalence and significance of subretinal drusenoid deposits (reticular pseudodrusen) in age-related macular degeneration. *Ophthalmology*. 2010;117:1775-1781.
6. Schmitz-Valckenberg S, Steinberg JS, Fleckenstein M, et al. Combined confocal scanning laser ophthalmoscopy and spectral-domain optical coherence tomography imaging of reticular drusen associated with age-related macular degeneration. *Ophthalmology*. 2010;117:1169-1176.
7. Zweifel SA, Spaide RE, Curcio CA, Malek G, Imamura Y. Reticular pseudodrusen are subretinal drusenoid deposits. *Ophthalmology*. 2010;117:303-312.
8. Arnold JJ, Sarks SH, Killingsworth MC, Sarks JP. Reticular pseudodrusen. A risk factor in age-related maculopathy. *Retina*. 1995;15:183-191.
9. Klein R, Meuer SM, Knudtson MD, Iyengar SK, Klein BEK. The epidemiology of retinal reticular drusen. *Am J Ophtalmol*. 2008;145:317-326.
10. Joachim N, Mitchell P, Rochtchina E, Tan AG, Wang JJ. Incidence and progression of reticular drusen in age-related macular degeneration: findings from an older Australian cohort. *Ophthalmology*. 2014;121:917-925.
11. Cohen SY, Dubois L, Tadayoni R, Delahaye-Mazza C, Debibie C, Quentel G. Prevalence of reticular pseudodrusen in age-related macular degeneration with newly diagnosed choroidal neovascularisation. *Br J Ophtalmol*. 2007;91:354-359.
12. Sarks J, Arnold J, Ho I-V, Sarks S, Killingsworth M. Evolution of reticular pseudodrusen. *Br J Ophtalmol*. 2011;95:979-985.
13. Schmitz-Valckenberg S, Alten F, Steinberg JS, et al. Reticular drusen associated with geographic atrophy in age-related macular degeneration. *Invest Ophtalmol Vis Sci*. 2011;52:5009-5015.
14. Alten F, Clemens CR, Milojcic C, Eter N. Subretinal drusenoid deposits associated with pigment epithelium detachment in age-related macular degeneration. *Retina*. 2012;32:1727-1732.
15. Lee MY, Yoon J, Ham D-I. Clinical characteristics of reticular pseudodrusen in Korean patients. *Am J Ophtalmol*. 2012;153:530-535.
16. Xu L, Blonska AM, Pumariega NM, et al. Reticular macular disease is associated with multilobular geographic atrophy in age-related macular degeneration. *Retina*. 2013;33:1850-1862.
17. Finger RP, Wu Z, Luu CD, et al. Reticular pseudodrusen: a risk factor for geographic atrophy in fellow eyes of individuals with unilateral choroidal neovascularization. *Ophthalmology*. 2014;121:1252-1256.
18. Alten F, Eter N. Current knowledge on reticular pseudodrusen in age-related macular degeneration. *Br J Ophtalmol*. 2015;99:717-722.
19. De Bats F, Mathis T, Mauget-Fàysse M, Joubert F, Denis P, Kodjikian L. Prevalence of reticular pseudodrusen in age-related macular degeneration using multimodal imaging. *Retina*. 2016;36:46-52.
20. Ueda-Arakawa N, Ooto S, Tsujikawa A, Yamashiro K, Oishi A, Yoshimura N. Sensitivity and specificity of detecting reticular

- pseudodrusen in multimodal imaging in Japanese patients. *Retina*. 2013;33:490-497.
21. Delcourt C, Korobelnik J-F, Barberger-Gateau P, et al. Nutrition and age-related eye diseases: the Alienor (Antioxydants, Lipides Essentiels, Nutrition et maladies OculaiRes) Study. *J Nutr Health Aging*. 2010;14:854-861.
 22. 3C Study Group. Vascular factors and risk of dementia: design of the Three-City Study and baseline characteristics of the study population. *Neuroepidemiology*. 2003;22:316-325.
 23. Le Tien V, Strého M, d'Athis P, et al. Interobserver and intraobserver reliability of detecting age-related macular degeneration using a nonmydriatic digital camera. *Am J Ophthalmol*. 2008;146:520-526.
 24. Querques G, Querques L, Martinelli D, et al. Pathologic insights from integrated imaging of reticular pseudodrusen in age-related macular degeneration. *Retina*. 2011;31:518-526.
 25. Bird AC, Bressler NM, Bressler SB, et al. An international classification and grading system for age-related maculopathy and age-related macular degeneration. The International ARM Epidemiological Study Group. *Surv Ophthalmol*. 1995;39:367-374.
 26. Klein R, Klein BEK, Knudtson MD, et al. Prevalence of age-related macular degeneration in 4 racial/ethnic groups in the multi-ethnic study of atherosclerosis. *Ophthalmology*. 2006;113:373-380.
 27. Delcourt C, Delyfer M-N, Rougier M-B, et al. Associations of complement factor H and smoking with early age-related macular degeneration: the ALIENOR study. *Invest Ophthalmol Vis Sci*. 2011;52:5955-5962.
 28. Pumariega NM, Smith RT, Sohrab MA, Letien V, Souied EH. A prospective study of reticular macular disease. *Ophthalmology*. 2011;118:1619-1625.
 29. Marsiglia M, Boddu S, Bearely S, et al. Association between geographic atrophy progression and reticular pseudodrusen in eyes with dry age-related macular degeneration. *Invest Ophthalmol Vis Sci*. 2013;54:7362-7369.
 30. Wilde C, Patel M, Lakshmanan A, Morales MA, Dhar-Munshi S, Amoaku WMK. Prevalence of reticular pseudodrusen in eyes with newly presenting neovascular age-related macular degeneration. *Eur J Ophthalmol*. 2016;26:128-134.
 31. Ueda-Arakawa N, Ooto S, Nakata I, et al. Prevalence and genomic association of reticular pseudodrusen in age-related macular degeneration. *Am J Ophthalmol*. 2013;155:260-269.