

# Evaluation of the Anterior Segment Angle-to-Angle Scan of Cirrus High-Definition Optical Coherence Tomography and Comparison With Gonioscopy and With the Visante OCT

Tin A. Tun,<sup>1</sup> Mani Baskaran,<sup>1,2</sup> Shayne S. Tan,<sup>3</sup> Shamira A. Perera,<sup>1</sup> Tin Aung,<sup>1-3</sup> and Rahat Husain<sup>1,2</sup>

<sup>1</sup>Singapore Eye Research Institute and Singapore National Eye Centre, Singapore

<sup>2</sup>Duke-NUS Graduate Medical School, National University of Singapore, Singapore

<sup>3</sup>Yong Loo Lin School of Medicine, National University of Singapore, Singapore

Correspondence: Tin Aung, Singapore National Eye Centre, 11 Third Hospital Avenue, Singapore 168751; aung.tin@sneec.com.sg.

Submitted: October 7, 2016

Accepted: November 16, 2016

Citation: Tun TA, Baskaran M, Tan SS, Perera SA, Aung T, Husain R. Evaluation of the anterior segment angle-to-angle scan of Cirrus high-definition optical coherence tomography and comparison with gonioscopy and with the Visante OCT. *Invest Ophthalmol Vis Sci.* 2017;58:59-64. DOI: 10.1167/iovs.16-20886

**PURPOSE.** To evaluate the diagnostic performance of the anterior segment angle-to-angle scan of the Cirrus high-definition optical coherence tomography (HD-OCT) in detecting eyes with closed angles.

**METHODS.** All subjects underwent dark-room gonioscopy by an ophthalmologist. A technician performed anterior segment imaging with Cirrus ( $n = 202$ ) and Visante OCT ( $n = 85$ ) under dark-room conditions. All eyes were categorized by two masked graders as per number of closed quadrants. Each quadrant of anterior chamber angle was categorized as a closed angle if posterior trabecular meshwork could not be seen on gonioscopy or if there was any irido-corneal contact anterior to scleral spur in Cirrus and Visante images. An eye was graded as having a closed angle if two or more quadrants were closed. Agreement and area under the curve (AUC) were performed.

**RESULTS.** There were 50 (24.8%) eyes with closed angles. The agreements of closed-angle diagnosis (by eye) between Cirrus HD-OCT and gonioscopy ( $k = 0.59$ ; 95% confidence interval (CI) 0.45-0.72; AC1 = 0.76) and between Cirrus and Visante OCT ( $k = 0.65$ ; 95% CI 0.48-0.82, AC1 = 0.77) were moderate. The AUC for diagnosing the eye with gonioscopic closed angle by Cirrus HD-OCT was good (AUC = 0.86; sensitivity = 83.33; specificity = 77.78). The diagnostic performance of Cirrus HD-OCT in detecting the eyes with closed angles was similar to that of Visante (AUC 0.87 vs. 0.9, respectively;  $P = 0.51$ ).

**CONCLUSIONS.** The anterior segment angle-to-angle scans of Cirrus HD-OCT demonstrated similar diagnostic performance as Visante in detecting gonioscopic closed angles. The agreement between Cirrus and gonioscopy for detecting eyes with closed angles was moderate.

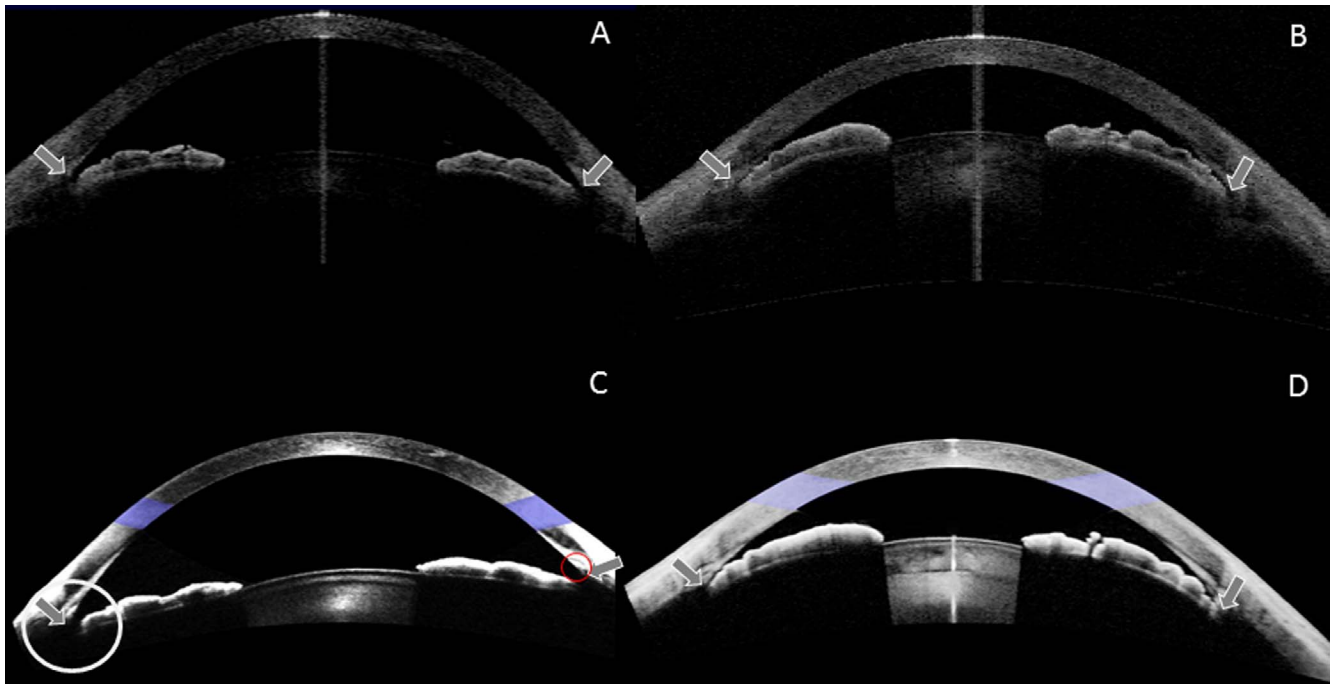
**Keywords:** anterior chamber angle, spectral-domain optical coherence tomography, gonioscopy, Visante optical coherence tomography

Primary angle-closure glaucoma is a leading cause of blindness in Asia.<sup>1,2</sup> Evaluation of the anterior chamber angle of an eye is critical to classify patients with closed angles correctly. Although gonioscopy is the current reference standard in evaluation of anterior chamber angle, its disadvantages, such as its subjectivity, the requirement for training, and high variability among the clinicians, have prompted research in alternative assessment techniques.<sup>3</sup> Anterior segment optical coherence tomography (OCT) provides an objective evaluation of the anterior chamber angle<sup>4,5</sup> and is commonly used in the management of primary angle closure diseases. Optical coherence tomography has recently evolved from a time-domain (TD) to a spectral-domain (SD) system, with increased image acquisition speed and improved image resolution, thereby limiting movement artifacts and increasing image quality.<sup>6-9</sup>

A shorter wavelength of 840 nm, however, limits tissue penetration, especially in anterior segment imaging due to optical attenuation and scattering.<sup>10</sup> Thus, the maximum imaging depth of the SD-OCT in tissues is limited to 2 to 3 mm, which makes previous versions of SD-OCTs unable to capture the whole anterior chamber of an eye in a single image,<sup>11</sup> preventing the assessment of parameters, such as anterior chamber depth, width, and area. Moreover, during image acquisition with those SD-OCTs, the use of an external fixation target may likely alter the anterior chamber angle profile compared with image acquisition in the primary gaze position.<sup>12,13</sup>

Cirrus high-definition (HD) OCT (model 5000; Carl Zeiss Meditec, Dublin, CA, USA) is an SD-OCT that uses 840-nm wavelength for posterior segment imaging. Recently, with the use of an external adaptor lens, it is possible to image the entire anterior chamber of an eye, analogous to the image obtained by





**FIGURE 1.** Anterior segment of an eye obtained by both Visante and Cirrus OCT. Visante images show the eye with open angles (A) and the eye with closed angles (B). Cirrus images show the eye with open angles (C) and the eye with closed angles (D). The *gray arrows* show the scleral spur locations; the *white circle* shows the poorly visible iris insertion at the limbus; the *red ring* shows the trabecular meshwork location.

the Visante OCT (model 1000; Carl Zeiss Meditec) (Fig. 1). The novel anterior segment angle-to-angle scan taken with the new version 8 of the Cirrus HD-OCT uses 20 B-scans, each composed of 1024 A-scans, and is  $15.5 \times 5.8$  mm in dimension. The scan depth of 5.8 mm was achieved by overlapping the source and mirror images (Fig. 2). The axial resolution of Cirrus HD-OCT in the tissue is  $5 \mu\text{m}$  and the maximum scan speed is 68,000 A-scans per second.

The aim of this study was to evaluate the anterior segment angle-to-angle scan of the Cirrus HD-OCT in detecting eyes with closed angles when compared with gonioscopy, the reference standard, and with the Visante OCT (a TD-OCT device that is commonly used in the clinic).

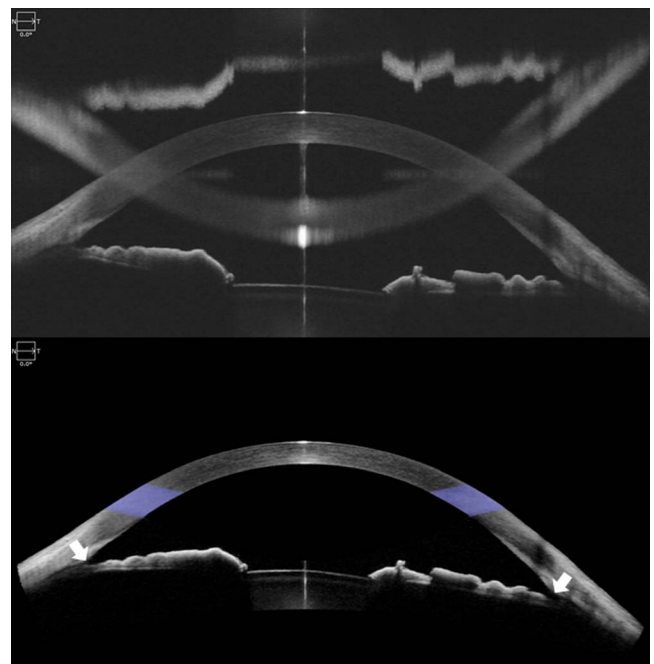
## METHODS

A total of 202 phakic subjects were recruited consecutively from a glaucoma clinic of the Singapore National Eye Center. Written informed consent was obtained from all subjects. The study had the approval of the Singapore Health Services Centralized Institutional Review Board and adhered to the tenets of the Declaration of Helsinki. After taking the medical history, all subjects underwent the following examinations: measurement of visual acuity, anterior segment imaging by the Cirrus and Visante OCTs, slit-lamp biomicroscopy, and dark-room gonioscopy on the same day. Subjects with a history of intraocular surgery or with any corneal abnormalities, such as a dense corneal arcus that would preclude OCT imaging, were excluded from the study; however, subjects with previous laser peripheral iridotomy (LPI) were included.

## Gonioscopy

All subjects underwent dark-room gonioscopy using a Sussman four-mirror lens (Ocular Instruments, Inc., Bellevue, WA, USA) by a single fellowship-trained ophthalmologist (RH) with more

than 10 years' experience in gonioscopy. The examination was performed in the primary gaze position using a 1-mm light beam, which was reduced to a narrow slit to offset horizontally for nasal and temporal quadrants grading, and vertically for superior and inferior quadrants grading. The examiner took extra care not to open the angle by directing the light on the



**FIGURE 2.** A cross-sectional image of an open angle of an eye captured by Cirrus OCT. A raw image of an open angle of an eye is displayed (A); (B) is a post processed image of the anterior chamber of the eye. *White arrows* represent the scleral spur locations.

TABLE 1. Demographic and Imaging Characteristics of Study Subjects ( $n = 202$ )

Variables	Open Angles, $n = 152$	Closed Angles, $n = 50$	P Value
	Mean $\pm$ SD or $n$ (%)		
Age, y	62.3 $\pm$ 10.46	62.16 $\pm$ 7.26	0.93
Sex, female	81 (53.3)	32 (64)	0.19
Ethnicity, Chinese	127 (83.6)	43 (86)	0.78
Spherical equivalent, diopter	-0.64 $\pm$ 3.83	-0.02 $\pm$ 2.93	0.33
Quadrants closed by gonioscopy	0.26 $\pm$ 0.44	3.08 $\pm$ 0.8	<0.01
Quadrants closed by Cirrus HD-OCT	0.32 $\pm$ 0.67	2.0 $\pm$ 1.23	<0.01

pupil or applying inadvertent pressure on the globe. The angle in each quadrant was graded using the Scheie grading system,<sup>14</sup> based on the anatomical structures observed during gonioscopy (grade wide open = all structures visible, grade 1 = iris root visible, grade 2 = ciliary body obscured, grade 3 = posterior trabeculum obscured, grade 4 = only Schwalbe's line visible). A quadrant was considered "closed" if the posterior trabecular meshwork could not be seen in the primary position without indentation (the Scheie grade 3 or 4). An eye was defined as having closed angles if there were 2 or more closed quadrants.

### Cirrus HD-OCT Image Acquisition

The left eye of all participants underwent imaging using the anterior segment angle-to-angle scan mode of Cirrus HD-OCT by a single technician, masked to clinical and gonioscopic data. The right eye was taken if the left eye was not eligible. Seated subjects were asked to fixate on the internal fixation light in the primary gaze position under dark-room conditions. The operator had to pull the upper and lower eyelids to image the superior and inferior angles while avoiding inadvertent pressure on the globe. We assessed the image quality during acquisition and excluded the poor-quality images (such as indeterminate scleral spurs, poorly visible angle recess area, and dense corneal arcus shadows).

### Visante OCT Image Acquisition

A subset of 85 patients was imaged using anterior segment single scan protocol of Visante OCT (model 1000; Carl Zeiss Meditec) by the same technician under dark-room conditions. The anterior segment single scan mode of the Visante OCT was composed of 256 A-scans per B-scan (image acquisition speed of 2000 A-scans per second) and axial resolution of 18  $\mu$ m. The scan dimension was 16  $\times$  6 mm and the image acquisition procedure was similar to that of Cirrus HD-OCT. In brief, a seated subject was directed to an internal fixation and upper and lower eyelids were drawn out for imaging of superior and inferior quadrants.

### Image Analysis of Cirrus and Visante OCT Images

Two graders (TAT and MB), masked to clinical and gonioscopic results, sat together and graded all Cirrus and Visante images in a random fashion. Any contact of the iris to cornea anterior to the scleral spur (SS) was defined as a closed angle in a quadrant. If the SS was not visible but the TM was, any contact between the trabecular meshwork (TM) and the iris was diagnosed as a closed angle in that quadrant.<sup>15</sup> The grading with TM in Visante images was not feasible because the TM was not clearly visible. An eye was defined as having a closed angle if two or more closed quadrants were closed.

### Statistical Analysis

Statistical analyses were performed using MedCalc (Windows v16.4.3; Mariakerke, Ostend, Belgium). Continuous variables were described as the mean and SD. We used the kappa statistic to assess the agreement between categorical variables; however, the  $\kappa$  statistic is affected by the prevalence of the disease under consideration,<sup>15,16</sup> therefore we used AC1 statistics to deal with the limitation of kappa. The AC1 is based on the similar formula as kappa but the probability of agreement by chance is estimated in a different way.<sup>16,17</sup> We used the area under the curve (AUC) of receiver operating characteristic (ROC) and 95% confidence interval (CI) to calculate the diagnostic performance of Cirrus HD-OCT using gonioscopy as the reference standard. The sensitivity, specificity, positive likelihood ratio (+LR), and negative likelihood ratio (-LR) for the different closed-angle definitions were reported. Statistical significance was set at  $P < 0.05$ .

## RESULTS

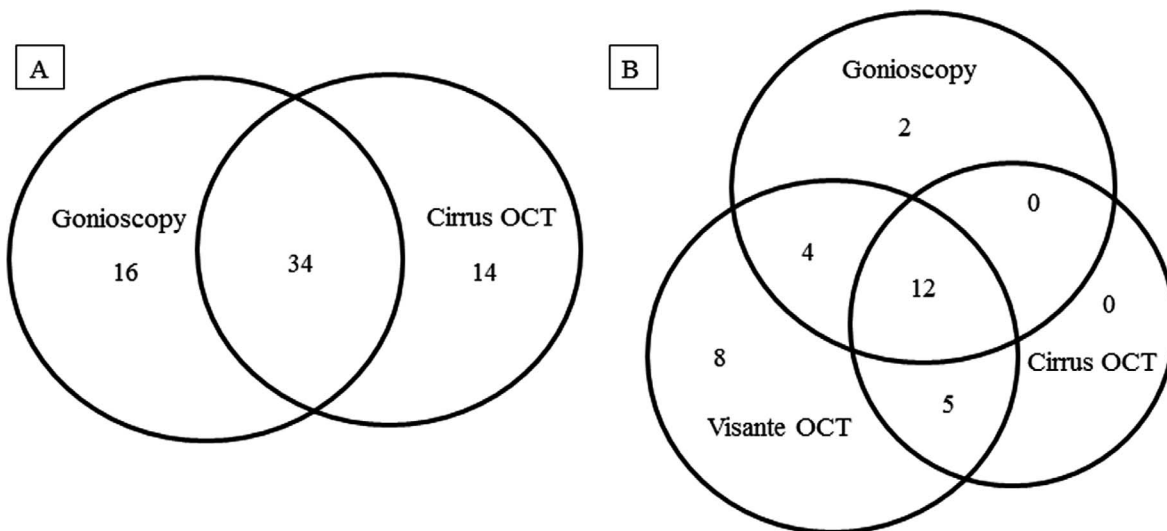
### Comparison of Cirrus HD-OCT With Gonioscopy

Of the 202 subjects examined, most were Chinese (170/202, 84.2%) and female ( $n = 113$ , 55.9%) with a mean age of 62.26  $\pm$  9.7 years (Table 1). We excluded 10 images due to indeterminate TM and SS locations. The TM was used as a landmark in 24 quadrants in Cirrus HD-OCT images to detect the closed angles because the SS was not clearly determined. There were 34 primary angle closure suspects (19 had no LPI, 22 primary angle closure, 12 primary angle-closure glaucoma, 70 primary open-angle glaucoma, and 64 healthy subjects). Of the original angle closure eyes, 18 had open angles after LPI and were included in the open angle group.

Of the 50 eyes classified as having a closed angle by gonioscopy, 34 (68%) were correctly classified by Cirrus HD-OCT (Fig. 3A). The iris insertion at the tip of the angle recess region was difficult to identify in 351 (45.7%) of the Cirrus HD-OCT images (Fig. 1C); however, the TM or SS was clearly visible to grade the angle. We found that the visibility of iris insertion was significantly higher in closed-angle eyes when compared with that of open-angle eyes (68.75% vs. 51.4%,  $P = 0.0003$ ).

Table 2 shows the agreement between Cirrus HD-OCT and gonioscopy in detecting a closed angle depending on the definition. The  $\kappa$  agreement between Cirrus and gonioscopy in detecting eyes with a closed angle was fair to moderate. The agreement between Cirrus and gonioscopy in detecting a closed angle in the superior, inferior, temporal, and nasal quadrants was as follows: based on  $\kappa$ , 0.59, 0.4, 0.28, and 0.48, respectively; based on the AC1 statistics, 0.65, 0.71, 0.78, and 0.79, respectively. The AC1 shows substantial agreement between Cirrus HD-OCT and gonioscopy in different quadrants.





**FIGURE 3.** Venn diagram showing distribution of closed angles detected by gonioscopy, and Visante and Cirrus OCT. (A) Diagram shows the distribution of closed angles detected by gonioscopy ( $n = 50$ ) and Cirrus OCT ( $n = 48$ ); (B) diagram shows the distribution of closed angles detected by gonioscopy ( $n = 18$ ), Visante ( $n = 29$ ), and Cirrus OCT ( $n = 17$ ).

Using gonioscopy as the reference standard, the kappa agreement of closed-angle detection by the vertical scan of Cirrus HD-OCT was 0.52 (95% CI 0.43–0.61) and that by the horizontal scan was 0.39 (95% CI 0.27–0.5). Using the definition of two or more quadrants gonioscopic closure, the AUC for Cirrus was 0.86 (95% CI 0.8–0.9). The sensitivity and specificity of Cirrus HD-OCT for the above-mentioned definition were 83.33 and 77.78, respectively (Fig. 4); +LR and –LR were 3.75 and 0.21, respectively (Table 3).

**Comparison of Cirrus and Visante OCT Using Gonioscopy as the Reference**

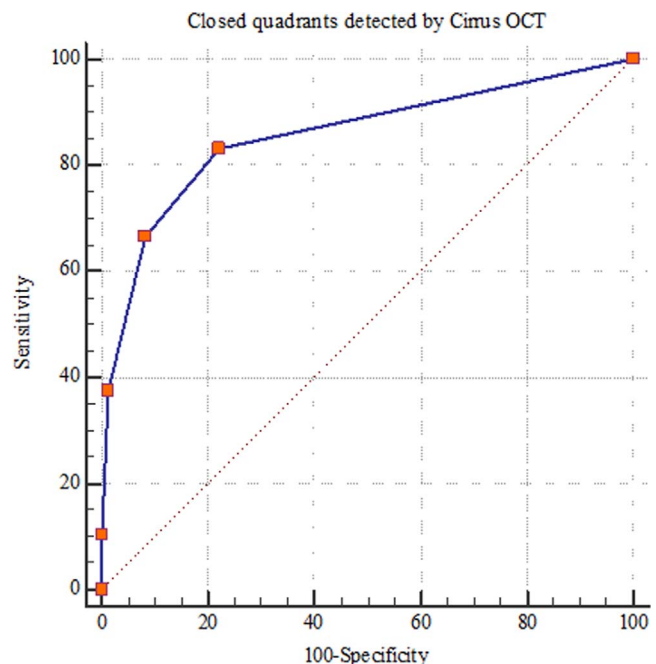
One eye each from 85 subjects were included for this subanalysis. Of 85 eyes, 18 (21.2%) eyes were diagnosed as a closed angle by gonioscopy, whereas Cirrus HD-OCT identified 17 (20%) and Visante identified 29 (34.1%) eyes with a closed angle. Cirrus and Visante OCTs identified 6 (8.8%) and 2 (3.6%) eyes as an open angle but those were diagnosed as closed by gonioscopy. The false negative detected by Cirrus was higher than that of Visante, but the difference was not statistically significant (8.8% vs. 3.6%,  $P = 0.52$ ). There were 67 eyes diagnosed as open by gonioscopy. Cirrus and Visante OCTs identified 5 (7.5%) and 13 (19.4%) eyes, respectively, as eyes

with closed angles, which were diagnosed as open-angle eyes by gonioscopy (Fig. 3B). The false positive detected by Cirrus was significantly lower than that by Visante (7.5% vs. 19.4%,  $P = 0.04$ ).

The agreement between Visante and Cirrus OCT in detection of closed angles is shown in Table 4. The agreement between Cirrus and Visante in detecting closed angle in the superior, inferior, temporal, and nasal quadrants was as follows: based on  $\kappa$ , 0.64, 0.59, 0.63, and 0.69, respectively; based on the AC1 statistics, 0.69, 0.75, 0.91, and 0.91, respectively. The  $\kappa$  agreement between Cirrus and Visante was moderate to good, whereas the AC1 statistics was substantial to almost perfect (in temporal and nasal quadrants) (Table 4). Using the definition of two or more closed quadrants for closed angle,

**TABLE 2.** Agreement Between Cirrus HD-OCT and Gonioscopy: Quadrant-wise and Definitions of Closure ( $n = 202$ )

Agreement Between Cirrus HD-OCT and Gonioscopy	$\kappa$ (95% CI)	AC1
<b>Quadrant-wise closure</b>		
Inferior quadrants	0.4 (0.24–0.55)	0.71
Superior quadrants	0.59 (0.47–0.7)	0.65
Temporal quadrants	0.28 (0.11–0.45)	0.78
Nasal quadrants	0.48 (0.32–0.63)	0.79
Vertical quadrants (superior + inferior)	0.52 (0.43–0.61)	0.68
Horizontal quadrants (nasal + temporal)	0.39 (0.27–0.5)	0.78
<b>Definition of closure</b>		
1 or more quadrants closed	0.57 (0.46–0.69)	0.6
2 or more quadrants closed	0.59 (0.45–0.72)	0.76
3 or more quadrants closed	0.49 (0.32–0.66)	0.84



**FIGURE 4.** Receiver operating characteristic curve analysis comparing Cirrus OCT and gonioscopy ( $n = 202$ ).

**TABLE 3.** Receiver Operating Characteristic Curve (ROC) Analysis to Compare Cirrus HD-OCT and Gonioscopy for Various Definitions of Closed Angle ( $n = 202$ )

Definition of Closure	AUC (95%CI)	Sensitivity (95%CI)	Specificity (95%CI)	+LR (95%CI)	-LR (95%CI)
1 or more quadrants closed	0.8 (0.74-0.86)	68.6 (57.7-78.2)	87.74 (79.9-93.3)	5.59 (3.3-9.5)	0.36 (0.3-0.5)
2 or more quadrants closed	0.86 (0.79-0.92)	83.33 (69.8-92.5)	77.78 (70.1-84.3)	3.75 (2.7-5.2)	0.21 (0.1-0.4)
3 or more quadrants closed	0.88 (0.81-0.95)	76.47 (58.8-89.3)	88.61 (82.6-93.1)	6.71 (4.2-10.8)	0.27 (0.1-0.5)

AUC was based on DeLong et al.<sup>21</sup>

the AUC for Cirrus was 0.87 (95% CI 0.78-0.94) and Visante was 0.90 (95% CI 0.81-0.95). The diagnostic performance of Cirrus OCT was not significantly different from that of Visante OCT in detecting of closed angles using gonioscopy as the reference standard ( $P = 0.51$ ) (Fig. 5).

## DISCUSSION

In this study, we found that the recently introduced anterior segment angle-to-angle scan mode of Cirrus HD-OCT provides anterior segment images analogous to those obtained by Visante OCT. The agreement between Cirrus and Visante OCT in detecting eyes with a closed angle was moderate to good. The diagnostic performance of Cirrus and Visante OCT was comparable, using gonioscopy as the reference standard; however, the agreement between Cirrus HD-OCT and gonioscopy in detecting eyes with closed angles was moderate.

The disadvantages, such as lack of anterior segment information and not using primary gaze position, make the previous version of the Cirrus HD-OCT hard to supplant the Visante for diagnostic or opportunistic screening applications in clinics. Now, with the assistance of the hardware (the external adaptor) and the software (overlapping of the source and mirror image), the new version 8 of Cirrus HD-OCT has the ability to image the entire cross-sectional image of the anterior segment of an eye like what the Visante does. This new version of Cirrus HD-OCT enhances the image quality by averaging 20 consecutive B-scans. Thus, the Cirrus HD-OCT may replace Visante TD-OCT in the near future because both posterior and anterior segment imaging can be achieved by a single device.

Hu et al.<sup>18</sup> reported that the previous version of Cirrus HD-OCT identified 28% and the Visante identified 34% of the quadrants that were diagnosed as a closed angle by gonioscopy. The agreement among the three devices was fair ( $\kappa$  from 0.15 to 0.31); however, in our study, we identified 34 (68%) closed-angle eyes with the Cirrus anterior segment angle-to-angle scans of 50 eyes diagnosed by gonioscopy (Fig. 3A), and the agreement between the new version of Cirrus and gonioscopy

in our study was moderate. A previous study<sup>19</sup> also reported that the agreement between gonioscopy and precedent Cirrus HD-OCT scans in detection of closed angles was good ( $\kappa = 0.65$ ). They reported further that Visante OCT identified 8 eyes and precedent Cirrus HD-OCT scans identified 7 eyes of 11 eyes that were diagnosed by gonioscopy as a closed-angle eye. In our study, 18 eyes were identified with closed angles by gonioscopy, 29 eyes by Visante and 17 eyes by Cirrus OCT in a subset of 85 eyes that underwent imaging with both OCT devices. In this subset, 5 eyes (7.5% of 67 gonioscopic open angles) that were classified as closed angles by Cirrus HD-OCT and 13 eyes (19.4%) by Visante OCT were diagnosed as an open angle by gonioscopy (Fig. 3B). Thus, the false positives detected by Cirrus HD-OCT were significantly lower when compared with Visante OCT, using gonioscopy as the reference standard (7.5% vs. 19.4%,  $P = 0.04$ ).

The SS is used as an anatomic landmark to classify a closed angle in OCT images, whereas TM is used for gonioscopy; therefore, it is possible that OCT may detect more closed angles (false positive) than gonioscopy because any short irido-corneal contact just anterior to the SS in OCT images was classified as a closed angle, which is defined as open by gonioscopy.<sup>17,20</sup> In our study, the false-positive rate detected by Cirrus HD-OCT was lower than that detected by the Visante OCT, but the false-negative rate between two OCT devices was comparable (8.8% vs. 3.6%,  $P = 0.52$ ). Hence, this new version of Cirrus HD-OCT may likely address the shortcoming (overdiagnosis of closed angles) of Visante while having similar sensitivity in closed-angle detection.

A radiolucent gap at the tip of the angle recess region is present in 45.7% of Cirrus HD-OCT images and it is more prominent in the eyes with a relatively large anterior chamber depth (Figs. 1C, 2). This radiolucent gap causes difficulty in identification of the iris insertion on the Cirrus HD-OCT images and we found that the visibility of iris insertion was significantly higher in closed-angle eyes. Thus, the angle recess area may not be feasible to calculate quantitatively on some Cirrus HD-OCT images. Moreover, the lower border of the irides was also not clearly visible on some Cirrus images so the quantitative measures of iris such as iris thickness, area, and volume may not be feasible to assess with this new version of Cirrus HD-OCT when compared with Visante.

Our study has a few limitations. There may be a systematic bias in angle grading because a single observer performed gonioscopy; however, the grader has more than 10 years of experience in performing gonioscopy. The angle evaluation in each quadrant by Cirrus and Visante OCT was based on a single meridional image, but gonioscopy findings represented the entire quadrant. The OCT uses infrared light and is a noncontact procedure, so that the possible drawbacks of gonioscopy, such as inadvertent indentation, distortion of the angle configuration, and the illumination effect on iris constriction were avoided, leading to disagreement.<sup>17,20</sup> The subjects in this study were recruited from a glaucoma clinic where the prevalence of the disease is high. Thus, the positive and negative predictive values of ROC were not reported in our

**TABLE 4.** Agreement Between Visante and Cirrus OCT: Quadrant-wise and Definitions of Closure ( $n = 85$ )

Agreement Between Visante and Cirrus OCT	$\kappa$ (95% CI)	AC1
Quadrant-wise closure		
Inferior quadrants	0.59 (0.41-0.78)	0.75
Superior quadrants	0.64 (0.48-0.8)	0.69
Temporal quadrants	0.63 (0.37-0.9)	0.91
Nasal quadrants	0.69 (0.46-0.92)	0.91
Vertical quadrants (superior + inferior)	0.62 (0.5-0.74)	0.72
Horizontal quadrants (nasal + temporal)	0.66 (0.49-0.84)	0.91
Definition of closure		
1 or more quadrant closed	0.66 (0.5-0.81)	0.69
2 or more quadrant closed	0.65 (0.48-0.82)	0.77
3 or more quadrant closed	0.53 (0.3-0.76)	0.82

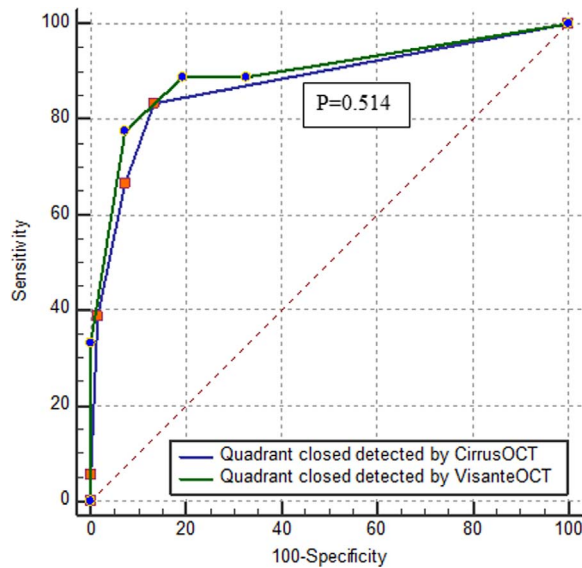


FIGURE 5. Receiver operating characteristic curve analysis comparing Visante and Cirrus OCT using gonioscopy as a reference ( $n = 85$ ).  $P$  value shows that the diagnostic performance between Visante and Cirrus OCT is comparable using gonioscopy as a reference.

study because these predictive values might be influenced by prevalence of the disease.

In summary, this is the first study demonstrating that novel anterior segment angle-to-angle scan of Cirrus HD-OCT is a reliable tool in the evaluation of the anterior chamber angle of an eye. The diagnostic performance of Cirrus HD-OCT was comparable with that of the Visante OCT and both devices were interchangeable in detection of eyes with closed angles. Although the diagnostic performance of Cirrus HD-OCT anterior segment angle-to-angle scan was good, the agreement between Cirrus HD-OCT and gonioscopy, the reference standard in detecting of closed angles, was moderate.

### Acknowledgments

Supported by a STaR grant from National Medical Research Council (NMRC/STAR/0023/2014).

Disclosure: **T.A. Tun**, None; **M. Baskaran**, None; **S.S. Tan**, None; **S.A. Perera**, None; **T. Aung**, Carl Zeiss Meditec, (F, R); **R. Husain**, None

### References

1. Foster PJ, Oen FTS, Machin D, et al. The prevalence of glaucoma in Chinese residents of Singapore: a cross-sectional population survey of the Tanjong Pagar District. *Arch Ophthalmol*. 2000;118:1105-1111.
2. Foster PJ. The epidemiology of primary angle closure and associated glaucomatous optic neuropathy. *Semin Ophthalmol*. 2002;17:50-58.
3. Friedman DS, He M. Anterior chamber angle assessment techniques. *Surv Ophthalmol*. 2008;53:250-273.

4. Fujimoto JG. Optical coherence tomography for ultrahigh resolution in vivo imaging. 2003;21:1361-1367.
5. Dorairaj S, Liebmann JM, Ritch R. Quantitative evaluation of anterior segment parameters in the era of imaging. *Trans Am Ophthalmol Soc*. 2007;105:99-108; discussion 108-110.
6. Choma M, Sarunic M, Yang C, Izatt J. Sensitivity advantage of swept source and Fourier domain optical coherence tomography. *Opt Express*. 2003;11:2183-2189.
7. Leung CK-S, Weinreb RN. Anterior chamber angle imaging with optical coherence tomography. *Eye (Lond)*. 2011;25:261-267.
8. Sharma R, Sharma A, Arora T, et al. Application of anterior segment optical coherence tomography in glaucoma. 2014; 59:311-327.
9. Rodrigues EB, Johanson M, Penha FM. Anterior segment tomography with the cirrus optical coherence tomography. 2012;2012:806989.
10. Schuman JS. Spectral domain optical coherence tomography for glaucoma (an AOS thesis). *Trans Am Ophthalmol Soc*. 2008;106:426-458.
11. Fujimoto JG, Brezinski ME, Tearney GJ, et al. Optical biopsy and imaging using optical coherence tomography. *Nat Med*. 1995;1:970-972.
12. Quek DT, Narayanaswamy AK, Tun TA, et al. Comparison of two spectral domain optical coherence tomography devices for angle-closure assessment. *Invest Ophthalmol Vis Sci*. 2012;53:5131-5136.
13. Perera SA, Ho CL, Aung T, et al. Imaging of the iridocorneal angle with the RTVue spectral domain optical coherence tomography. *Invest Ophthalmol Vis Sci*. 2012;53:1710-1713.
14. Schacknow PN, Samples JR. *The Glaucoma Book: A Practical, Evidence-Based Approach to Patient Care*. New York, NY: Springer; 2010.
15. Viera AJ, Garrett JM. Understanding interobserver agreement: the kappa statistic. *Fam Med*. 2005;37:360-363.
16. Chan YH. Biostatistics 104: correlation analysis. *Singapore Med J*. 2003;44:614-619.
17. Sakata LM, Lavanya R, Friedman DS, et al. Comparison of gonioscopy and anterior segment ocular coherence tomography in detecting angle closure in different quadrants of the anterior chamber angle. *Ophthalmology*. 2008;115:769-774.
18. Hu CX, Mantravadi A, Zangalli C, et al. Comparing gonioscopy with Visante and Cirrus optical coherence tomography for anterior chamber angle assessment in glaucoma patients. *J Glaucoma*. 2016;25:177-183.
19. Wong H-T. High-definition optical coherence tomography imaging of the iridocorneal angle of the eye. *Arch Ophthalmol*. 2009;127:256.
20. Nolan WP, See JL, Chew PTK, et al. Detection of primary angle closure using anterior segment optical coherence tomography in Asian eyes. *Ophthalmology*. 2007;114:33-39.
21. DeLong ER, DeLong DM, Clarke-Pearson DL. Comparing the areas under two or more correlated receiver operating characteristic curves: a nonparametric approach. *Biometrics*. 1988;44:837-845.