

# Subretinal Injection for Gene Therapy Does Not Cause Clinically Significant Outer Nuclear Layer Thinning in Normal Primate Foveae

G. Alex Ochakovski,<sup>1,2</sup> Tobias Peters,<sup>3</sup> Stylianos Michalakis,<sup>4</sup> Barbara Wilhelm,<sup>3</sup> Bernd Wissinger,<sup>2</sup> Martin Biel,<sup>4</sup> K. Ulrich Bartz-Schmidt,<sup>1</sup> and M. Dominik Fischer<sup>1-3,5</sup>; for the RD-CURE Consortium

<sup>1</sup>University Eye Hospital, Centre for Ophthalmology, University Hospital Tübingen, Tübingen, Germany

<sup>2</sup>Institute for Ophthalmic Research, Centre for Ophthalmology, University Hospital Tübingen, Tübingen, Germany

<sup>3</sup>STZ eyetrial at the Centre for Ophthalmology, University Hospital Tübingen, Tübingen, Germany

<sup>4</sup>Center for Integrated Protein Science Munich CiPSM at the Department of Pharmacy-Center for Drug Research, Ludwig-Maximilians-University of Munich, Munich, Germany

<sup>5</sup>Nuffield Laboratory of Ophthalmology, University of Oxford, Oxford, United Kingdom

Correspondence: M. Dominik Fischer, Centre for Ophthalmology, University Hospital Tübingen, Elfriede-Aulhorn-Straße 7, 72076 Tübingen, Germany; Dominik.Fischer@uni-tuebingen.de.

See the appendix for the members of the RD-CURE Consortium.

Submitted: June 11, 2017

Accepted: July 13, 2017

Citation: Ochakovski GA, Peters T, Michalakis S, et al. Subretinal injection for gene therapy does not cause clinically significant outer nuclear layer thinning in normal primate foveae. *Invest Ophthalmol Vis Sci.* 2017;58:4155-4160. DOI:10.1167/iops.17-22402

**PURPOSE.** Despite ever-growing adoption of subretinal (SRI) and intravitreal injections (IVTi) in ocular gene therapy trials, concerns regarding possible deleterious effects of the SRI on the outer retina are yet to be addressed. SRI offers several advantages over IVTi, such as a better photoreceptor transduction efficiency and a limited off-target exposure. We assessed structural changes in the outer retina in nonhuman primates following either SRI or IVTi of a gene therapeutic or control solution and compared both techniques in a noninferiority analysis.

**METHODS.** In a toxicology study, 22 cynomolgus monkeys underwent single intraocular injections with rAAV2/8 or vehicle; 18 animals received SRI, 4 animals received IVTi. Outer nuclear layer (ONL) thickness change on optical coherence tomography was used for a noninferiority analysis. Preservation of the physiological foveal bulge was used as a secondary outcome measure.

**RESULTS.** The average ONL change from baseline after 2 weeks was  $-6.54 \pm 5.16$  (mean  $\pm$  SD  $\mu\text{m}$ ) and  $+1.50 \pm 4.36$  for SRI and IVTi groups accordingly. At 13 weeks, the SRI group maintained a difference of  $-6.54 \pm 9.66$  while IVTi group gained  $+1.00 \pm 4.24$ . The ellipsoid zone line was transiently lost after SRI and completely recovered by 13 weeks in 77% of eyes. One SRI case resulted in subfoveal pigment accumulation and 39% ONL thinning.

**CONCLUSIONS.** Despite limited ONL thinning following SRI, the observed effect was under the predefined clinical significance threshold. The SRI has proven not to be inferior to the IVTi in terms of ONL thickness loss and estimated loss of visual acuity.

**Keywords:** subretinal surgery, gene therapy, noninferiority, outer nuclear layer

As encouraging results of ocular gene therapy trials for hereditary degenerative diseases of the retina continue to emerge,<sup>1-3</sup> gene therapy development proceeds with the next retinal target-diseases. The success of a gene therapy trial depends, among other aspects, on the choice of the most suitable surgical approach for the disease and vector in question. Subretinal (SRI) and intravitreal injections (IVTi) are currently the two surgical approaches used in clinical retinal gene therapy trials. Each approach brings a unique set of advantages and drawbacks that should be considered in the context of each specific disease.<sup>4</sup>

The unique advantages of the SRI in gene therapy, such as increased target cell transduction efficiency in the outer retinal layers, anatomic targeting of specific areas (e.g., macula) and favorable virus-shedding parameters, position the SRI as the preferred choice for therapeutic vector delivery in a group of retinal genetic diseases in which the photoreceptor and/or RPE cells are involved, especially when the target tissue is locally confined, such as a remaining central island in the macula.

Contrary to IVTi, the SRI is not as frequently used method in clinical practice and therefore lacks the vast amount of safety data (e.g., complication rates) that IVTi has. Although many gene therapy trials that involve administration by SRI concentrate on assessing the safety of the vector, they are not designed to assess possible deleterious effects of the surgical technique per se, as they typically lack controls (SRI versus IVTi delivery, vector versus vehicle). Concerns regarding SRI effect on the retina were raised by Jacobson et al.<sup>5</sup> based largely on a single case of persistent outer nuclear layer (ONL) thinning after subretinal injection. In this case, the retinotomy was performed right at the fovea, which predictably resulted in central ONL thinning. In a preclinical study of RPE65 mutant dogs, 4 of 27 eyes had statistically significant ONL thinning. Cases of iatrogenic macular hole after SRI also have been reported in independent studies.<sup>5-7</sup>

Although independent reports suggest some degree of ONL loss after SRI, the degree to which they affect visual outcome clinically is still unclear. Loss of ONL thickness and visual acuity



(VA) as outcome measure demonstrate a high correlation ( $r_s = 0.59$ ,  $P < 0.001$ ).<sup>8</sup> We have therefore used the data from Matsumoto et al.<sup>8</sup> to calculate the structural equivalent of a three-line VA loss and defined this as a clinical significance threshold. We then applied optical coherence tomography (OCT) analysis in a longitudinal study in nonhuman primates following SRi or IVTi of gene therapeutic compounds or vehicle to calculate changes in ONL thickness and assess noninferiority of SRi to IVTi in a study fully compliant with good laboratory practice.

## MATERIALS AND METHODS

### Animals and Animal Welfare

Cynomolgus monkeys (*Macaca fascicularis*), ages 4 to 5 years, 11 males and 11 females, were kept in pair or group housing in a climate-controlled room and fed twice daily with certified laboratory diet (LabDiet 5048; PMI Nutritional International, Inc., Saint Paul, MN, USA) supplemented with fresh fruits and vegetables. Housing included stainless still mirrors, wooden chips, colored plastic tools, and balls. All procedures involving animals were performed in adherence to the ARVO Statement for the Use of Animals in Ophthalmic and Vision Research, in compliance with good laboratory practice regulations and with approval from the relevant local regulatory authority (Regierungspräsidium, Düsseldorf, Germany).

### Intravitreal and Subretinal Injections

SRi with balanced salt solution (BSS; Alcon Pharma GmbH, Freiburg, Germany) or good manufacturing practice-grade vector (AAV2/8) were performed in 18 monkeys and IVT injections of the same vector were performed in four monkeys. Before either surgical procedure, animals were anesthetized by general anesthesia with isoflurane, followed by a thorough cleaning of the periorbital regions with Povidine iodine and application of sterile surgical drapes. After applying a pediatric lid speculum to the left eye, pars plana location was confirmed by transillumination, three sclerotomies were made approximately 1 to 2 mm posterior to the limbus using valved 23G trocars (Retilock; FCI S.A.S., Paris, France). The posterior hyaloid was detached and a near-complete vitrectomy was performed while sparing the lens using the PentaSys vitrectomy machine (Ruck GmbH, Eschweiler, Germany).

For the SRi, a two-step approach was used. First BSS (Alcon) was injected using an extendible 41-gauge cannula (DORC 1270.EXT; Dutch Ophthalmic Research Center [International] B.V., Zuidland, The Netherlands) to create a localized retinal detachment bleb. In a second step, a subretinal injection of BSS (vehicle) or rAAV vector solution of up to 0.2 mL into the induced bleb was performed using 1 to 2 psi positive pressure on the silicon oil infusion program of the PentaSys system.<sup>9</sup> For the IVTi, the vector solution was given directly into the vitreous cavity without subretinal surgery. Postoperatively, Vigamox (0.5% moxifloxacin; Novartis Pharma GmbH, Nuernberg, Germany) and Pred forte (1% prednisolone; Eurimpharm Arzneimittel GmbH, Saaldorf-Surheim, Germany) eye drops were instilled three times daily in the left eye prophylactically. Systemic prednisone 1 mg/kg was given from day -2 until day 5 by intramuscular injection.

### Optical Coherence Tomography

Spectral-domain OCT B-scans of the fovea were obtained using Spectralis HRA + OCT (Heidelberg Engineering, Heidelberg, Germany) at three time points: predose, and 2 and 13 weeks

after injection (see Supplementary Fig. S1). During the acquisition, the animals were under light sedation with ketamine hydrochloride and diazepam, as described previously.<sup>10</sup> Both eyes were instilled with mydriatic eye drops (phenylephrine and tropicamide) and the corneal surface protected with methylcellulose eye drops while lids were held open using pediatric lid specula.

### Structural Analysis of Outer Retina

For structural analysis measurement, injection bleb was located during surgery (performed by authors MDF and KUBS) and confirmed by infrared and red-free recordings using scanning laser ophthalmoscopy (SLO; see Supplementary Fig. S2). Animals' eyes in which the injection bleb failed to reach the fovea were excluded from further analysis ( $n = 3$ ). ONL thickness was measured in the foveola using the virtual ruler tool in the Heidelberg Eye Explorer Software (version 1.9.13.0; Heidelberg Engineering). The built-in follow-up function in Heidelberg Eye Explorer was used to relocate the exact position of the fovea in consequent acquisitions.

Foveal bulge is a term used to describe a slight protrusion of the ellipsoid zone (EZ) line toward the inner retinal layers at the center of the fovea that can be seen on OCT. The bulge corresponds anatomically to the elongated outer segments of the foveolar cone photoreceptors.<sup>11</sup> Hence, it is not surprising that the foveal bulge has been significantly correlated with better VA in occult macular dystrophy, branch retinal vein occlusion, and retinal detachment repair.<sup>12-15</sup> Correspondingly, the foveal bulge was found to be absent in most albino and amblyopic eyes with poor vision.<sup>15,16</sup> In our study, we used presence/absence of foveal bulge as secondary outcome measure in the animals at baseline and 13 weeks as described elsewhere.<sup>17</sup>

Preservation of the EZ line in the fovea, located between the external limiting membrane (ELM) and RPE layer was assessed at baseline, and 2 and 13 weeks. Interrupted, irregular, or absent EZ lines in the central fovea were considered as missing.

### Statistical Analysis

To compare the SRi and IVTi methods in terms of ONL loss, a noninferiority approach was adapted. The M1 threshold of clinically significant ONL loss was set to 24  $\mu\text{m}$ , which corresponds to a vision loss equivalent to three lines of VA loss based on the correlation study of Matsumoto et al.<sup>8</sup> The null hypothesis was that the difference between SRi and IVTi in terms of ONL loss is 24  $\mu\text{m}$  (M1) or more, implying that SRi is inferior to IVTi. The primary endpoint result is presented as the difference of ONL thickness loss between SRi and IVTi groups. The 95% confidence intervals (CIs) of this difference were reported and if the upper limit of difference was greater than 24  $\mu\text{m}$ , the null hypothesis could not be rejected. All statistical analysis was performed in SPSS version 24 (IBM Corp., New York, NY, USA), Excel v.1706 (Microsoft Corp., Redmond, WA, USA), and JMP 13.0.0 (SAS Institute Inc., Cary, NC, USA).

## RESULTS

The goal of this study was to investigate whether SRi is associated with significant damage to the outer retina in the context of subretinal versus intravitreal drug delivery. To make this more relevant for the clinical application, we

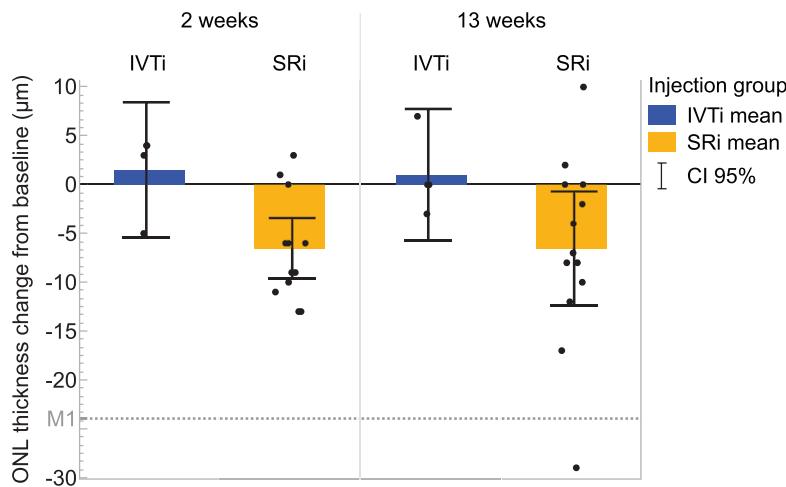


FIGURE 1. ONL thickness change from baseline at two postintervention timepoints in SRi and IVTi groups. Error bars correspond to 95% CI. M1 line is the noninferiority margin (24 μm).

studied the effects in nonhuman primates and tried to mimic a clinical scenario using the identical surgical approach and means of follow-up. All animals were successfully treated following recording of baseline characteristics. There were no adverse events other than two animals (SRi group) in which cataract developed due to inadvertent lens touch during vitrectomy. The opacification in the lens precluded these animals from quantitative analysis of the defined structural endpoints. An additional three cases from the SRi group were excluded from the noninferiority analysis, in which the induced detachment did not include the foveola. The repeatability coefficient for foveolar ONL thickness measurement on OCT based on baseline and 2-week follow-up measurements in control eyes ( $n = 22$ ) was  $5.71 \mu\text{m}$  (see Supplementary Fig. S3). The average foveolar ONL thickness measured at baseline was  $75.27 \pm 3.74 \mu\text{m}$  (mean  $\pm$  95% CI;  $n = 22$ ). In the designated SRi group, the average ONL was  $73.39 \pm 3.88 \mu\text{m}$  ( $n = 18$ ) and the animals in the IVTi group featured an average ONL thickness of  $83.75 \pm 5.81 \mu\text{m}$  ( $n = 4$ ) before surgery. Figure 1 shows relative change of ONL thickness (normalized for baseline measurements) in the treated eyes per group and time point. As expected, mean ONL thickness did not change significantly from baseline following IVTi ( $+1.50 \pm 4.36 \mu\text{m}$  at 2 weeks and  $+1.00 \pm 4.24 \mu\text{m}$  at 13 weeks after surgery). In contrast, SRi was followed by a slight loss of ONL thickness at 2 weeks ( $-6.54 \pm 5.16 \mu\text{m}$ ; corresponding to a mean loss of 8.91% from the average ONL thickness at baseline), which was persistent throughout week 13 ( $-6.54 \pm 9.66 \mu\text{m}$ ). The difference between average ONL loss between SRi and IVTi groups (Fig. 2) was  $-8.04 \mu\text{m}$  (95% CI  $-2.93$  to  $-13.15$ ) at 2 weeks and

$-7.54 \mu\text{m}$  (95% CI 1.7 to  $-16.78$ ) at 13 weeks (see Supplementary Fig. S1). Neither the mean nor the CIs reached the predefined significance threshold M1 ( $-24 \mu\text{m}$  ONL). No cystoid edema or similar abnormalities that could have influenced OCT measurement were observed in any of the animals at any time.

The foveal bulge describes the elongation of cone outer segments in the foveola, which results in an elevation of the ELM and EZ line in the rod free foveal center.<sup>17</sup> Previous studies have shown a correlation between this anatomic configuration and visual function<sup>17,15</sup> and preservation rates of between 28% and 42% following rhegmatogenous retinal detachment (RRD) repair surgery.<sup>17,18</sup> In our study, the foveal bulge was initially present in all animals at baseline and later found to be preserved in 9 (69%) of 13 eyes in the SRi group and in 3 (75%) of 4 eyes in the IVTi group at 13 weeks.

The integrity of the EZ line, which is located at the inner segment/outer segment (IS/OS) interface of the photoreceptors, between the RPE and ELM lines, has been shown to correlate to variable degrees with VA in several retinal interventions, including RRD,<sup>19</sup> epiretinal membrane,<sup>20</sup> and macular hole<sup>21</sup> repair surgeries. In our study, EZ line was preserved in the foveae of all (four of four) IVTi eyes. In the SRi group, a transient alteration of the EZ line has been observed. At week 2, the EZ line was missing in 92.3% (12 of 13) of the cases. By week 13, the EZ line had recovered to its normal state in 76.9% (10 of 13) of the SRi cases. The remaining three SRi cases have shown various degrees of improvement from week 2 but failed to completely recover by week 13 (see Supplementary Fig. S4).

DISCUSSION

The study results demonstrate that the SRi was not inferior to IVTi in terms of ONL thickness loss. The chosen endpoint is clinically relevant, as other studies have shown a high degree of correlation between ONL thickness and VA outcome after retinal surgery.<sup>19</sup> Although some differences in ONL thickness change could be observed between the two cohorts, the magnitude of the change including its 95% CIs were well below the predefined clinically significance threshold (M1 margin). Our results seem also to align with multifocal ERG outcomes of a previous SRi study on three cynomolgus

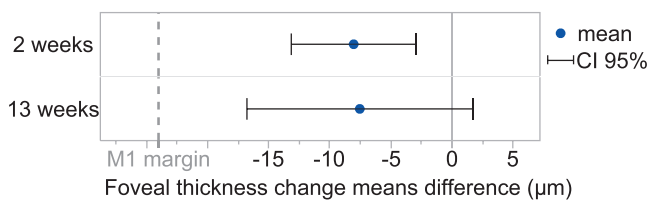


FIGURE 2. The difference in ONL mean change from baseline between SRi and IVTi groups postinjection. The dashed M1 line corresponds to the noninferiority margin of 24 μm. Error bars correspond to 95% CI.

monkeys,<sup>22</sup> in which amplitudes almost completely recovered 90 days postinjection.

Although most observed ONL changes in the SRi group were within the 95% CI range, in two cases thickness loss was beyond that range, with  $-17\ \mu\text{m}$  and  $-29\ \mu\text{m}$  thickness loss. Both animals demonstrated a unique feature in the follow-up analysis, namely substantial subfoveal pigment clumping. In the worst of the two cases, RPE clumping was especially pronounced and caused a substantial loss of  $29\ \mu\text{m}$ , which was beyond our noninferiority threshold. No other animals have shown such a prominent pigment accumulation precisely beneath the fovea. It must be stated, however, that both outlier cases belong to the high injection-dose group.

Inducing a bleb with a vector solution between the RPE and photoreceptor layer, as is currently done in SRi gene therapy, could be compared to some extent with a short-lasting RRD. Nevertheless, SRi differs from RRD in several aspects, such as the controlled fashion in which a bleb is induced in SRi, the fast spontaneous resolution of the bleb (usually within 24 hours), vitrectomy being routinely performed before SRi, a repair surgery that takes place only after RRD, and underlying differences in health status of the retina with different pathologic conditions in SRi as compared with relatively healthy retinas in RRD. Those differences should be considered when attempting to translate safety concerns or prognosis of RRD and its repair surgery outcomes into SRi in the context of gene therapy. Indeed, the findings of foveal bulge preservation in our study somewhat contrast with the foveal bulge preservation rates in RRD repair outcome in clinical studies. This suggests that the deleterious effects of a macula-off RRD are not to be expected from a careful subretinal injection even if it entails the fovea and support the notion that subretinal delivery with temporary detachment of the fovea is a viable option with limited effects on outer retinal anatomy.

Based on previous experimental RRD<sup>22,23</sup> and RRD repair<sup>24</sup> studies, detaching the neuroretina occasionally involves loss of some photoreceptor outer segments (POSS) in primates, especially in prolonged detachment.<sup>23</sup> After reattachment, POSS usually regenerate unless RPE cells proliferate extensively and inhibit the natural tendency to synthesize POSS.<sup>23</sup> The regenerated outer segments appear almost normal in light and electron microscopes except for the increased spacing between adjacent POSS.<sup>23</sup> This increased spacing is believed to cause the decreased reflectivity of the EZ line on OCT of recently reattached retinas. Other studies found that some cells in the photoreceptor layer stain with apoptotic marker (TUNEL positive) 1 to 3 days after SRi in rabbits,<sup>25</sup> cats,<sup>26</sup> and rats.<sup>27</sup> Despite these alterations, the interdigitation with regenerated RPE processes recovers and the phagocytic activity of the RPE has been shown to restore in primates.<sup>23</sup> Most SRi group animals (92.3%) in our study have also demonstrated an intermittent EZ line disappearance that has subsequently recovered in all but 3 cases by week 13, suggesting that POS loss is reversible also under presence of adeno-associated virus (AAV) vector. One of the animals that failed to recover the EZ line was also an outlier ( $-29\ \mu\text{m}$ ) in ONL thickness loss, whereas the other ONL outlier case ( $-17\ \mu\text{m}$ ) has recovered the EZ line.

Interestingly, one animal in the IVTi group demonstrated a loss of foveal bulge (see Supplementary Fig. S5), which was not associated with EZ line changes or with ONL thickness loss. In that case, the foveal bulge was initially minimally pronounced at baseline and later failed to meet the predefined cutoff criteria at week 13 by merely  $2\ \mu\text{m}$ . We have concluded that

this can be explained by the variability of the follow-up and evaluation methods.

As opposed to the healthy primates' retinas in our study, the retinas of gene therapy patients are often altered due to the underlying disease. The effects of the hereditary disease on relevant structural and functional properties of the retina, such as its biomechanical fragility, susceptibility to cell death or damage after detachment, and altered retinal adhesiveness, play an important role in the decision-making process to select the most suitable surgical delivery, as we have reviewed in detail elsewhere.<sup>4</sup>

The risk versus benefit assessment of SRi needs to be considered in the context of the underlying disease, the individual stage and prognosis of the disease, as well as the level of efficacy by gene therapy and the availability of alternative treatment strategies. Although the IVTi alternative has been shown to have a relatively good safety profile in the clinical setting, in the context of efficacy, it has proven to be much less efficient in terms of AAV transduction rates of photoreceptors and RPE cells in comparison with SRi. To compensate this inefficiency, higher vector doses would be needed for IVTi to yield similar efficacy. However, exposure of off-target tissue, systemic biodistribution, and shedding of genetically modified AAV particles are inherently greater after IVTi versus SRi even at comparable doses (Seitz IP, et al. *IOVS* 2017;58:ARVO E-Abstract 4025). Although SRi has been shown to cause some limited ONL thickness decrease (8.91%), this change correlates to approximately one line of visual loss. In this context, a limited loss of ONL thickness can be considered appropriate, especially when compensated by a potential rescue effect of the therapy and even more so in the setting of poor prognosis and no alternative treatment strategy. Developments in surgical robotics (Meenink, et al. *IOVS* 2017;58:ARVO E-Abstract 5808). and improvements in SRi technique may further improve SRi safety in the future, but even in its current state, our data suggest that SRi causes only clinically nonsignificant ONL changes in normal primate retinas.

As the study was primarily designed as a safety study for application of gene therapy, using the results in our noninferiority analysis context had some limitations in terms of flexibility of optimizing the test subjects' number and their optimal allocation into study groups. Also, VA as a primary endpoint was not available for obvious reasons. We therefore decided to indirectly estimate the impact of the SRi on the visual outcome by using ONL thickness loss as a surrogate marker for that purpose. Despite the high correlation between ONL thickness and VA, using an anatomic marker as surrogate for visual function has its limitations. For example, ONL thickness in the foveola might be thinner or thicker compared with an adjacent area with dramatic consequences for VA, which is a much more integrative measure of visual function. On the other hand, ONL thickness is an objective measure directly affected by the surgery, whereas VA is subject to a number of influences that are not necessarily linked to the impact of surgery, such as attention and optic qualities of the anterior segment. We defined our clinical significance margin (M1) to a  $24\text{-}\mu\text{m}$  loss based on a previous correlation study of ONL loss and VA, which was performed in clinical settings of surgery for RRD. Although the ONL-VA correlation was found to be high ( $r_s = 0.59$ ;  $P < .001$ )<sup>8</sup> in that study, it still limits the precision of our M1 estimation. Moreover, applying association data from a clinical study to preclinical settings might have limits. To estimate the limits of this factor, we compared the average ONL thickness we measured in monkeys with the one

measured in the clinical association study<sup>8</sup> (75.27 vs. 74.6  $\mu\text{m}$ , accordingly) and found it to be very similar.

Despite the encouraging results of this study, future comparative studies that focus on the functional parameters of vision loss could provide additional information. Moreover, future studies should also address the question of whether the tissue in retinal dystrophy patients might react differently from the healthy primate retina investigated in this report. Additionally, future studies should consider investigating retinal changes using adaptive optics (AO) methods, such as AO-SLO and AO-OCT to examine changes on the cellular level. In our study, significant eye movements in our animals due to light sedation would have made AO imaging very challenging, yet continuous technological improvement in eye-tracking and acquisition speeds might help overcome these limitations.<sup>28</sup> Also, we believe that investigating ways to further reduce retinal stress and cellular damage by optimizing the SRi surgical approach could prove beneficial not only to reduce direct damage to photoreceptors in weaker, disease-affected retinas, but could also by minimizing disruption of the blood-retina barrier and proinflammatory effects of retinal damage.<sup>29</sup> Further optimization of the surgical approach should contribute to the overall safety and efficacy of target cell transduction and long-term transgene expression in the context of gene therapy.

### Acknowledgments

The authors thank Apostolos Bezirgiannidis (University Eye Hospital Tuebingen), Sven Korte and Joerg Luft (both Covance Laboratories GmbH) for their help in the animal study, and Philipp Berens (Institute for Ophthalmic Research) for advice on the statistical analysis.

Supported by the Tistou und Charlotte Kerstan Stiftung.

Disclosure: **G.A. Ochakovski**, None; **T. Peters**, None; **S. Michalakakis**, P; **B. Wilhelm**, None; **B. Wissinger**, None; **M. Biel**, P; **K.U. Bartz-Schmidt**, None; **M.D. Fischer**, Bayer (F, R), Nightstar Ltd. (C, F, R), Regenxbio, Inc. (C, R), EyeServe GmbH (C, R), STZeyetrial (C, R), Novartis (R)

### References

- MacLaren RE, Groppe M, Barnard AR, et al. Retinal gene therapy in patients with choroideremia: initial findings from a phase 1/2 clinical trial. *Lancet*. 2014;383:1129-1137.
- Bennett J, Ashtari M, Wellman J, et al. AAV2 gene therapy readministration in three adults with congenital blindness. *Sci Transl Med*. 2012;4:120ra15.
- Jacobson SG, Cideciyan AV, Ratnakaram R, et al. Gene therapy for Leber congenital amaurosis caused by RPE65 mutations: safety and efficacy in 15 children and adults followed up to 3 years. *Arch Ophthalmol*. 2012;130:9-24.
- Ochakovski GA, Bartz-Schmidt KU, Fischer MD. Retinal gene therapy: surgical vector delivery in the translation to clinical trials. *Front Neurosci*. 2017;11:174.
- Campochiaro PA, Lauer AK, Sohn EH, et al. Lentiviral vector Gene Transfer of Endostatin/Angiostatin for Macular Degeneration (GEM) Study. *Hum Gene Ther*. 2016;28:99-111.
- Maguire AM, Simonelli F, Pierce EA, et al. Safety and efficacy of gene transfer for Leber's congenital amaurosis. *N Engl J Med*. 2008;358:2240-2248.
- Edwards TL, Jolly JK, Groppe M, et al. Visual acuity after retinal gene therapy for choroideremia. *N Engl J Med*. 2016; 374:1996-1998.
- Matsumoto H, Sato T, Kishi S. Outer nuclear layer thickness at the fovea determines visual outcomes in resolved central serous chorioretinopathy. *Am J Ophthalmol*. 2009;148:105-110.e1.
- Fischer MD, Hickey DG, Singh MS, MacLaren RE. Evaluation of an optimized injection system for retinal gene therapy in human patients. *Hum Gene Ther Methods*. 2016;27:150-158.
- Fischer MD, Zobor D, Keliris GA, et al. Detailed functional and structural characterization of a macular lesion in a rhesus macaque. *Doc Ophthalmol*. 2012;125:179-194.
- Yuodelis C, Hendrickson A. A qualitative and quantitative analysis of the human fovea during development. *Vision Res*. 1986;26:847-855.
- Hasegawa T, Ueda T, Okamoto M, Ogata N. Presence of foveal bulge in optical coherence tomographic images in eyes with macular edema associated with branch retinal vein occlusion. *Am J Ophthalmol*. 2014;157:390-396.e1.
- Thomas MG, Kumar A, Mohammad S, et al. Structural grading of foveal hypoplasia using spectral-domain optical coherence tomography a predictor of visual acuity? *Ophthalmology*. 2011;118:1653-1660.
- dell'Omo R, Viggiano D, Giorgio D, et al. Restoration of foveal thickness and architecture after macula-off retinal detachment repair. *Invest Ophthalmol Vis Sci*. 2015;56:1040-1050.
- Al-Haddad CE, Mollayess GME, Mahfoud ZR, Jaafar DF, Bashshur ZF. Macular ultrastructural features in amblyopia using high-definition optical coherence tomography. *Br J Ophthalmol*. 2013;97:318-322.
- Mohammad S, Gottlob I, Kumar A, et al. The functional significance of foveal abnormalities in albinism measured using spectral-domain optical coherence tomography. *Ophthalmology*. 2011;118:1645-1652.
- Hasegawa T, Ueda T, Okamoto M, Ogata N. Relationship between presence of foveal bulge in optical coherence tomographic images and visual acuity after rhegmatogenous retinal detachment repair. *Retina*. 2014;34:1848-1853.
- Kobayashi M, Iwase T, Yamamoto K, et al. Association between photoreceptor regeneration and visual acuity following surgery for rhegmatogenous retinal detachment photoreceptor regeneration and VA after RRD surgery. *Invest Ophthalmol Vis Sci*. 2016;57:889-898.
- Gharbiya M, Grandinetti F, Scavella V, et al. Correlation between spectral-domain optical coherence tomography findings and visual outcome after primary rhegmatogenous retinal detachment repair. *Retina*. 2012;32:43-53.
- Itoh Y, Inoue M, Rii T, Hirota K, Hirakata A. Correlation between foveal cone outer segment tips line and visual recovery after epiretinal membrane surgery. *Invest Ophthalmol Vis Sci*. 2013;54:7302-7308.
- Ooka E, Mitamura Y, Baba T, Kitahashi M, Oshitari T, Yamamoto S. Foveal microstructure on spectral-domain optical coherence tomographic images and visual function after macular hole surgery. *Am J Ophthalmol*. 2011;152:283-290.e1.
- Nork TM, Murphy CJ, Kim CBY, et al. Functional and anatomic consequences of subretinal dosing in the cynomolgus macaque. *Arch Ophthalmol*. 2012;130:65-75.
- Guérin CJ, Anderson DH, Fariss RN, Fisher SK. Retinal reattachment of the primate macula. Photoreceptor recovery after short-term detachment. *Invest Ophthalmol Vis Sci*. 1989;30:1708-1725.
- Wakabayashi T, Oshima Y, Fujimoto H, et al. Foveal microstructure and visual acuity after retinal detachment repair: imaging analysis by Fourier-domain optical coherence tomography. *Ophthalmology*. 2009;116:519-528.
- Kawaji T, Hirata A, Inomata Y, Koga T, Tanihara H. Morphological damage in rabbit retina caused by subretinal injection of indocyanine green. *Graefes Arch Clin Exp Ophthalmol*. 2004;42:158-164.
- Cook B, Lewis GP, Fisher SK, Adler R. Apoptotic photoreceptor degeneration in experimental retinal detachment. *Invest Ophthalmol Vis Sci*. 1995;36:990-996.

27. Zacks DN, Hänninen V, Pantcheva M, Ezra E, Grosskreutz C, Miller JW. Caspase activation in an experimental model of retinal detachment. *Invest Ophthalmol Vis Sci.* 2003;44:1262-1267.
28. Sheehy CK, Tiruveedhula P, Sabesan R, Roorda A. Active eye-tracking for an adaptive optics scanning laser ophthalmoscope. *Biomed Opt Express.* 2015;6:2412-2423.
29. Miller B, Miller H, Patterson R, Ryan SJ. Retinal wound healing: cellular activity at the vitreoretinal interface. *Arch Ophthalmol.* 1986;104:281-285.

## APPENDIX

### RD-CURE Consortium

Bernd Wissinger, Martin Biel, Eberhart Zrenner, Karl Ulrich Bartz-Schmidt, M. Dominik Fischer, Susanne Kohl, Stylianos Michalakis, Francois Paquet-Durand, Tobias Peters, Mathias Seeliger, Marius Ueffing, Nicole Weisschuh, Barbara Wilhelm, Ditta Zobor, Stephen Tsang, Laura Kühlewein, Christian Johannes Glöckner, and Nadine A. Kahle.