

# Plateau Iris Distribution Across Anterior Segment Optical Coherence Tomography Defined Subgroups of Subjects With Primary Angle Closure Glaucoma

Sushma Verma,<sup>1</sup> Monisha E. Nongpiur,<sup>1,2</sup> Hnin H. Oo,<sup>3</sup> Eray Atalay,<sup>1</sup> David Goh,<sup>1</sup> Tina T. Wong,<sup>1</sup> Shamira A. Perera,<sup>1</sup> and Tin Aung<sup>1-3</sup>

<sup>1</sup>Singapore Eye Research Institute, Singapore National Eye Centre, Singapore

<sup>2</sup>Duke-NUS Medical School, Singapore

<sup>3</sup>Department of Ophthalmology, Yong Loo Lin School of Medicine, National University of Singapore, Singapore

Correspondence: Tin Aung, Singapore National Eye Centre, 11 Third Hospital Avenue, Singapore 168751; [aung.tin@singhealth.com.sg](mailto:aung.tin@singhealth.com.sg).

Submitted: June 6, 2017

Accepted: August 25, 2017

Citation: Verma S, Nongpiur ME, Oo HH, et al. Plateau iris distribution across anterior segment optical coherence tomography defined subgroups of subjects with primary angle closure glaucoma. *Invest Ophthalmol Vis Sci.* 2017;58:5093-5097. DOI: 10.1167/iovs.17-22364

**PURPOSE.** We previously identified three distinct subgroups of patients with primary angle closure glaucoma (PACG) based on anterior segment optical coherence tomography (ASOCT) imaging. Group 1 was characterized by a large iris area with deepest anterior chambers, group 2 by a large lens vault (LV) and shallow anterior chamber depth (ACD), and group 3 displayed intermediate values across iris area, LV, and ACD. The purpose of the present study was to determine the distribution of plateau iris in these subgroups using ultrasound biomicroscopy (UBM) features.

**METHODS.** UBM images of the 210 subjects who were previously enrolled for the ASOCT subgrouping analysis and had undergone laser peripheral iridotomy were assessed and graded by a single glaucoma fellowship trained clinician. Plateau iris was defined as the presence of all the following UBM criteria in at least two quadrants: anteriorly directed ciliary body, absent ciliary sulcus, iris angulation, flat iris plane, and iridoangle touch.

**RESULTS.** Of 210 subjects, 23 were excluded due to poor-quality images. Based on standardized UBM criteria, the overall prevalence of plateau iris was 36.9% ( $n = 187$ ). The proportion of plateau iris was similar across the three groups (subgroup 1:35.4% ( $n = 29$ ); subgroup 2:39.0% ( $n = 32$ ); subgroup 3:34.8% ( $n = 8$ ),  $P = 0.87$ ). On multiple logistic regression analysis, iris thickness at 750  $\mu\text{m}$  from the scleral spur (IT750) was the only variable associated with plateau iris (odds ratio: 1.5/100  $\mu\text{m}$  increase in iris thickness [IT],  $P = 0.04$ ).

**CONCLUSIONS.** The proportion of plateau iris was similar across the three ASOCT-based PACG subgroups and more than one-third of subjects with PACG were diagnosed with plateau iris based on standardized UBM criteria. In addition, we noted that eyes with increased peripheral IT have an increased likelihood of plateau iris.

**Keywords:** plateau iris, anterior chamber depth, primary angle closure glaucoma, ultrasound biomicroscopy

Nonpupil block mechanisms, such as plateau iris, are described to play an important role in the pathogenesis of primary angle closure glaucoma (PACG).<sup>1-3</sup> Plateau iris is traditionally defined as the presence of occludable angles on gonioscopy, with a flat iris plane and a relatively deep central anterior chamber.<sup>4</sup> However, there are conflicting reports on the association of anterior chamber depth (ACD) with plateau iris. Recent studies have shown that eyes with plateau iris have significantly shallower ACD compared with those with pupil block and normal eyes.<sup>5,6</sup> Shallower ACD in these eyes was attributed to the anterior rotation of the ciliary body producing forward movement of the lens.<sup>5,6</sup>

We recently identified three distinct subgroups of PACG based on anterior segment optical coherence tomography (ASOCT) imaging and clustering analysis.<sup>7</sup> An ability to subcategorize angle closure based on the likely underlying mechanism rather than to lump all patients with angle closure into one group of eyes may lead to a better understanding of the condition and may help guide in individualized treatment of

PACG subjects. Notably, in the ASOCT subgrouping analysis,<sup>7</sup> the ACD was significantly different among the three groups. Subgroup 1 was characterized by a larger iris area with deepest anterior chambers, subgroup 2 by a large lens vault (LV) and shallowest ACD, whereas subgroup 3 displayed intermediate values across iris area, LV, and ACD.<sup>7</sup> Given the variable associations of plateau iris and ACD, we therefore aimed to assess the proportion of plateau iris across the three PACG subgroups. We hypothesize that the eyes categorized to subgroup 1,<sup>7</sup> characterized by significantly deeper ACD, would have the highest proportion of plateau iris, as plateau iris is conventionally defined to have a relatively deep central anterior chamber.<sup>4</sup> The presence of plateau iris was determined using standardized ultrasound biomicroscopy (UBM) criteria.<sup>2</sup>

## MATERIALS AND METHODS

Approval for the study was granted by the Institutional Review Board of the Singapore National Eye Centre and the Singapore



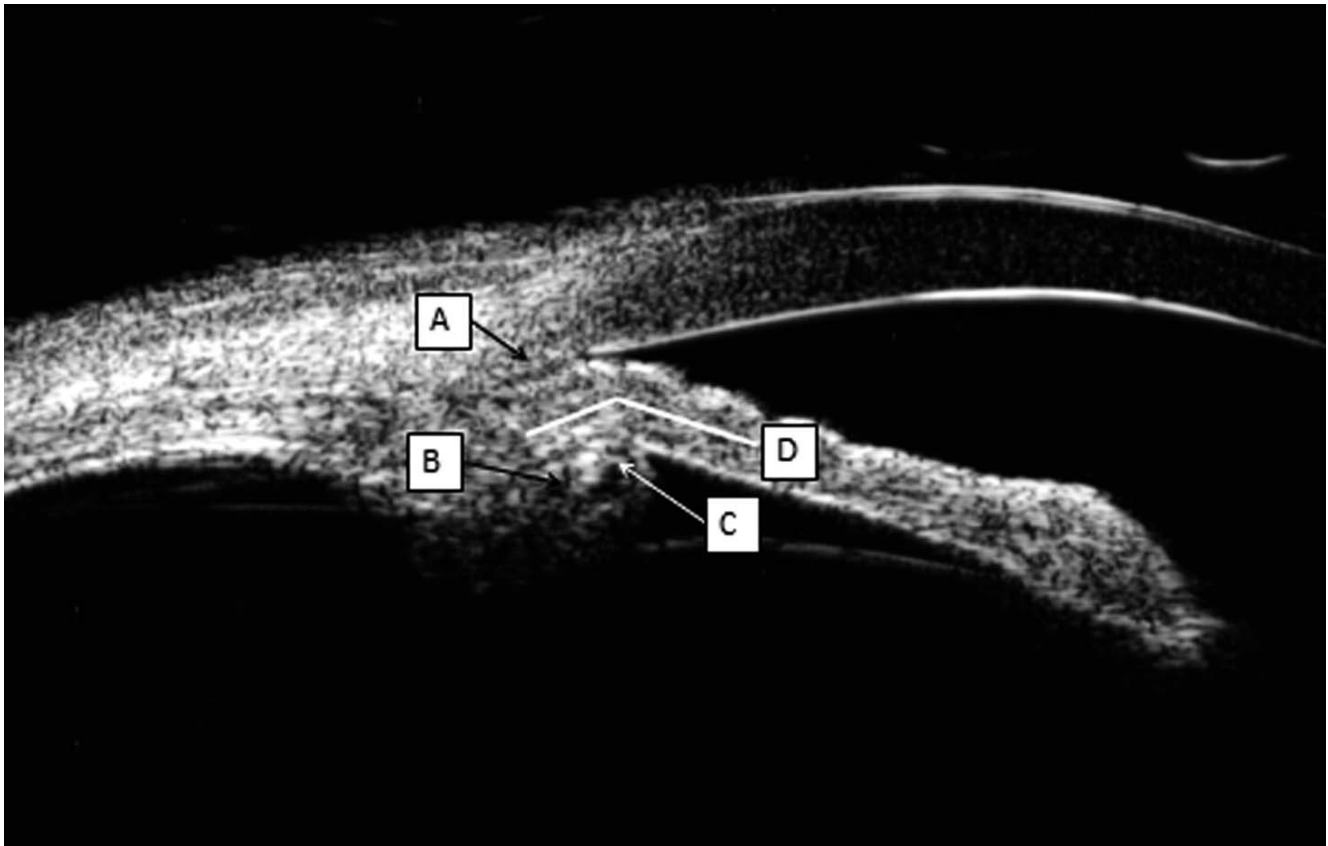


FIGURE. UBM image of a quadrant of a PACG eye with plateau iris showing iridoangle contact (A), anteriorly directed ciliary process (B), absent ciliary sulcus (C), and iris angulation and flat iris plane (D).

Eye Research Institute. The study was conducted in accordance with the tenets of the Declaration of Helsinki, and written informed consent was obtained from all subjects before enrollment into the study. In this study, UBM images of the 210 subjects who were evaluated for the ASOCT-based subgrouping of PACG were assessed. Details of the study have been described previously.<sup>7</sup> In brief, subjects aged 40 years and older and diagnosed with PACG were recruited from glaucoma clinics of the Singapore National Eye Centre. All subjects had previously undergone laser peripheral iridotomy (LPI) before recruitment into the study.

All subjects underwent a standardized ophthalmic examination that included visual acuity testing, slitlamp examination, IOP measurement with Goldmann applanation tonometry, stereoscopic evaluation of the optic disc, visual field testing (Humphrey Visual Field Analyzer II; Carl Zeiss Meditec, Dublin, CA, USA, using the standard Swedish interactive threshold algorithm with a 24-2 test pattern). Static gonioscopy was performed using a Goldmann 2-mirror lens by an experienced examiner under dark conditions at high magnification ( $\times 16$ ). Indentation gonioscopy with a Sussman 4-mirror lens was used to establish the presence or absence of peripheral anterior synechiae (PAS). PACG was defined as the presence of glaucomatous optic neuropathy (defined as loss of neuroretinal rim with a vertical cup-disc ratio [CDR] of  $>0.7$  and/or notching with nerve fiber layer defect attributable to glaucoma) with compatible visual field loss, in association with a closed angle (presence of at least  $180^\circ$  angle in which the posterior trabecular meshwork was not visible on gonioscopy with presence of PAS).

Details of the ASOCT grading has been described previously.<sup>7</sup> In brief ASOCT (Visante; Carl Zeiss Meditec) imaging was

performed for all participants under standardized dark conditions (0 lux) by a single operator. The scans were centered on the pupil and a single cross-sectional horizontal image (nasal-temporal angles at 0-180 degrees) was obtained and evaluated for each subject. The only observer input was to determine the position of the scleral spurs. The images were processed using customized software, the Zhongshan Angle Assessment Program (ZAAP, Guangzhou, China) by a single experienced observer (MEN) who was masked to clinical data. The algorithm then automatically calculated the anterior segment parameters.

Ultrasound biomicroscopy was performed in darkroom conditions using a 50-MHz transducer (Paradigm Medical Instruments, Salt Lake City, UT, USA, and Suowei Electronic Technology, Tianjin, China), by a single examiner. Patients were examined in the supine position, with the probe held perpendicular to the ocular surface, such that the scleral spur, ciliary body, and angle were visualized. Due care was taken to prevent compression of the globe from eyecup causing changes to the angle configuration. Radial scans were performed in the inferior, temporal, superior, and nasal quadrants. One scan in each quadrant per eye was recorded for analysis. Ultrasound biomicroscopy images were graded qualitatively in all quadrants by a single glaucoma fellowship trained observer (SV), masked to the ASOCT-based grouping and clinical examinations. Plateau iris was defined as the presence of all the following UBM criteria in at least two quadrants<sup>2</sup> (Fig.):

1. The ciliary process was anteriorly directed, supporting the peripheral iris so that it was parallel to the trabecular meshwork.

**TABLE 1.** Proportion of Plateau Iris in the ASOCT-Defined Subgroups of PACG ( $N = 187$ )

Subgroups	Patients With Plateau Iris, $n$ (%)	Patients With No Plateau Iris, $n$ (%)	$P$
Subgroup 1	29 (35.4)	53 (64.6)	0.87
Subgroup 2	32 (39.0)	50 (61.0)	0.87
Subgroup 3	8 (34.8)	15 (65.2)	0.87
Overall	69 (36.9)	118 (63.1)	-

- The iris root had a steep rise from its point of insertion, followed by a downward angulation from the corneoscleral wall.
- Presence of a central flat iris plane.
- An absent ciliary sulcus.
- Iridoangle contact (above the level of the scleral spur) in the same quadrant.

Statistical analysis was performed using a commercially available statistical software package (SPSS for Windows, version 22.0; IBM-SPSS, Chicago, IL, USA). Proportion of plateau iris was assessed across the subgroups by  $\chi^2$  test. We performed a logistic regression analysis to determine the ASOCT-defined variables associated with plateau iris. Univariable and multivariable analyses were adjusted for age and sex. Statistical significance was set at  $P < 0.05$ .

## RESULTS

UBM images of the 210 PACG subjects who were previously enrolled for the ASOCT subgrouping analysis were evaluated. The mean age (SD) of the 210 subjects was 67.9 (9.2) years, 53.3% were female, and 91.4% were of Chinese ethnicity. Mean visual field mean deviation (MD) and CDR of the overall sample were  $-12.5 \pm 9.0$  dB and  $0.8 \pm 0.1$ , respectively. There were no significant differences in the mean age ( $P > 0.05$ ), visual field MD ( $P > 0.05$ ), pattern standard deviation ( $P > 0.05$ ) and vertical CDR ( $P > 0.05$ ) among the three subgroups.

Of 210 subjects, 23 were excluded due to poor-quality images in at least one quadrant, leaving 187 subjects for final analysis. Based on standardized UBM criteria, the overall prevalence of plateau iris was 36.9% ( $n = 187$ ). Table 1 shows the proportion of plateau iris across the three subgroups. The proportion of plateau iris was similar across the three groups:

subgroup 1: 35.4%,  $n = 29$ ; subgroup 2: 39.0%,  $n = 32$ ; subgroup 3: 34.8%,  $n = 8$ ,  $P = 0.87$ . If less-stringent UBM criteria for the plateau iris was considered, with all but excluding flat iris plane criteria, then overall prevalence of plateau iris was 38.5% ( $n = 72$ ). Likewise, when the other four criteria (excluding iridotrabecular contact) were considered, the prevalence of plateau iris was 54.0% ( $n = 101$ ). Table 2 presents univariate and multivariable logistic regression analysis of the biometric parameters associated with "plateau iris" after adjusting for age and sex. After including variables with  $P < 0.2$  in the univariate analysis, iris thickness (IT) at 750  $\mu$ m from the scleral spur (IT750) was the only variable associated with plateau iris (odds ratio 1.5 per 100- $\mu$ m increase in IT750, 95% confidence interval 1.01–2.24,  $P = 0.04$ ).

## DISCUSSION

In this observational study using standardized UBM criteria, the overall prevalence of plateau iris was 36.9%. Interestingly, although the ACD was deepest in subgroup 1,<sup>7</sup> however, we noted that the proportion of plateau iris was similar across the three PACG subgroups. Increased peripheral IT was associated with an increased likelihood of plateau iris.

The proportion of plateau iris among our predominantly Chinese subjects is comparable to the estimated prevalence of 30% plateau iris by Kumar et al.<sup>3</sup> in their Singapore PACG cohort (which was different from our subject cohort) and the prevalence of 30% in the Indian population by Kumar et al.<sup>8</sup> Despite the presence of a patent LPI, some eyes with primary angle closure disease display residual angle closure and elevated IOP, suggesting the involvement of mechanisms other than pupil block.<sup>9</sup> In a study evaluating the progress of PACG in a Sino-Mongoloid population, Wang et al.<sup>10</sup> showed that pure pupillary block accounted for only 38% of angle closure in Chinese individuals, whereas 54% had combined mechanisms. This suggests that non-pupil block mechanisms such as plateau iris and/or combined mechanisms play a significant role in angle closure pathogenesis in this population.

Conventionally, plateau iris is defined as the presence of an occludable angle on gonioscopy, with a flat iris plane and a relatively deep central anterior chamber.<sup>4</sup> This is in sync with the definition in the Liwan Eye Study, wherein relatively deep central anterior chamber and a centrally flat iris plane were used to characterize the plateau iris profile gonioscopically.<sup>11</sup> Interestingly, Baek et al.<sup>12</sup> identified two distinct subgroups of

**TABLE 2.** Logistic Regression Analysis of Determinants of Plateau Iris

Predictor Variable	Univariable Logistic Regression			Multivariable Logistic Regression		
	OR	95% CI	$P$	OR	95% CI	$P$
Axial length, per mm increase	0.90	0.66–1.23	0.51			
Spherical equivalent, per diopter increase	1.09	0.93–1.28	0.31			
Lens thickness, per mm increase	1.01	0.73–1.39	0.95			
Lens position	0.92	0.51–1.65	0.78			
IT750, per 0.1-mm increase	1.54	1.04–2.29	0.03	1.51	1.01–2.25	0.04
Iris area	0.83	0.23–2.99	0.78			
Iris curvature	0.08	0.002–4.16	0.21			
ACD, per 0.1-mm decrease	0.66	0.25–1.73	0.40			
ACW	1.20	0.58–2.48	0.63			
ACA	0.94	0.84–1.05	0.27			
ACV	0.99	0.97–1.00	0.12	0.99	0.98–1.00	0.16
LV, per 0.1-mm increase	1.00	0.99–1.00	0.76			
Anterior vault, per 0.1-mm decrease	1.00	0.99–1.00	0.76			

Multivariate model adjusted for age, sex, and variables, with  $P < 0.2$  in the univariate model. ACA, anterior chamber area; ACV, anterior chamber volume; ACW, anterior chamber width; CI, confidence interval; OR, odds ratio.

PAC/PACG in Korean subjects; they hypothesized that plateau iris configuration or thick peripheral iris may be a contributing factor for angle closure in one of their subgroups that was characterized by relatively deeper ACD. However, they did not specifically examine the presence of plateau iris features. Based on this conventional concept of a relatively deep ACD in plateau iris, we hypothesized that the eyes categorized to subgroup 1,<sup>7</sup> characterized by significantly deeper ACD, would have the highest proportion of plateau iris. However, we noted that the proportion of plateau iris was similar across the subgroups irrespective of the differences in ACD. Our findings confirm the recent studies that have shown that eyes with plateau iris may have relatively shallower ACD.<sup>5,6</sup> Mansoori et al.<sup>5</sup> evaluated the prevalence of plateau iris in 262 PACG patients after LPI using UBM-defined criteria. Plateau iris was present in 83 (31.68%) of 262, and these eyes were noted to have significantly shallower central ACD compared with those with pupillary block and normal eyes. In a study of 91 Japanese angle closure patients using UBM, the estimated prevalence of plateau iris was 17.6%; and, interestingly, plateau iris was noted in patients with an ACD significantly shallower than that in the healthy controls.<sup>13</sup> Likewise, Mandell et al.<sup>6</sup> reported that the plateau iris group showed an ACD significantly shallower than that of the healthy control group and the pupil block group in their cohort of 318 patients diagnosed by UBM as either pupillary block or plateau iris. They postulated that the shallow anterior chamber in plateau iris may be explained by the anterior position of the ciliary processes that produces an anterior position of the lens. However, they further hypothesized that an anteriorly positioned lens may also lead to pupillary block, and it is likely that the two conditions frequently coexist. Mandell and colleagues<sup>6</sup> speculate that the lack of forward bowing of the iris in plateau iris gives a clinical impression of deeper ACD; although the axial distance of the lens from the cornea is relatively small.

Increased peripheral IT has been associated with PACG.<sup>14</sup> As the peripheral iris is in close proximity to the anterior chamber angles, therefore, a thicker peripheral iris may contribute to development of angle closure.<sup>14</sup> We found that eyes with greater peripheral IT were modestly associated with having plateau iris. It is likely that the eyes in which plateau iris and thick peripheral iris coexist are more inclined toward an increased risk for angle closure. However, the presence of PAS may have an effect on the IT750 measurements, and this may in turn impact the modest association of iris thickness with plateau iris. Further, although we had excluded eyes with software delineation errors,<sup>7</sup> there is still a possibility that some eyes may have had errors in measurements due to unclear delineation of the posterior iris surface with ASOCT. This may have also affected the relatively small association of IT with plateau iris.

The relatively high proportion of plateau iris among patients with PACG warrants a need for a more optimum and specific management for the condition. Several treatment approaches have been evaluated, each with varying efficacy. Some studies have described the use of pilocarpine, which produces iris thinning and facilitates opening of the anterior chamber angles by pulling the iris away from the trabecular meshwork.<sup>15</sup> However, pilocarpine-induced myopia and miosis, along with the relatively short duration of action, limits its therapeutic application. Prostaglandin analogues have been found to be effective in lowering IOP in eyes with PACG<sup>16,17</sup>; however, their efficacy in plateau iris needs to be elucidated. Ritch et al.<sup>18</sup> demonstrated the long-term effectiveness of argon laser peripheral iridoplasty (ALPI) in eliminating residual appositional closure after LPI for a small cohort of subjects diagnosed with plateau iris by gonioscopy. Nonetheless, reports of ALPI as an effective treatment for plateau iris is

still limited. Despite the available management options, there is still a need for more studies to determine the optimal and effective treatment modality for plateau iris.

The high incidence of plateau iris in these PACG eyes also underlies the importance of post-LPI gonioscopy in the clinical assessment of the angle, which can guide further investigation with UBM, if indicated, to accurately categorize these eyes and offer the appropriate management.

One of the limitations of this study is that the occurrence of plateau iris was based on a single cross-sectional image in each quadrant; variations in the quadrant may be missed by a single image representing a quadrant. Furthermore, the presence of PAS cannot be accurately assessed from UBM images, and it may have an effect on IT estimation. Second, UBM images were not gradable/available in approximately 11% of the subjects, and it is not known how they would have influenced the present results. UBM images were taken supine, and the ASOCT was taken sitting. This may have led in predisposed subjects to more movement of the lens. Also, it is unknown whether the ciliary body rotation causes the lens to be more anteriorly placed or whether the more anteriorly positioned lens (due to other factors, including increased vitreous pressure) may make the ciliary body appear anteriorly placed. Additionally, the ASOCT subgroups were categorized from parameters obtained from horizontal scans, whereas categorization of plateau iris was based on the assessment of all four quadrants of UBM images. Image analysis of vertical ASOCT scans (by the customized ZAAP software) is often not possible because simultaneous image acquisition of both quadrants is usually not possible in vertical scans. It is therefore not known whether similar subgroups arise if parameters from vertical scans were obtained. Furthermore, as the UBM may have inadvertently caused some compression, it may have changed the anterior chamber parameters from how they were measured on ASOCT.

In conclusion, the proportion of plateau iris was similar across the three ASOCT-based PACG subgroups and more than one-third of subjects with PACG were diagnosed with plateau iris based on standardized UBM criteria. In addition, we noted that eyes with increased peripheral IT have an increased likelihood of plateau iris.

### Acknowledgments

Supported by the Singapore National Medical Research Council under its Singapore Translational Research Investigator Award (NMRC/STAR/0023/2014).

Disclosure: **S. Verma**, None; **M.E. Nongpiur**, None; **H.H. Oo**, None; **E. Atalay**, None; **D. Goh**, None; **T.T. Wong**, None; **S.A. Perera**, None; **T. Aung**, None

### References

1. He M, Foster PJ, Johnson GJ, Khaw PT. Angle-closure glaucoma in East Asian and European people. Different diseases? *Eye*. 2006;20:3-12.
2. Kumar RS, Baskaran M, Chew PT, et al. Prevalence of plateau iris in primary angle closure suspects an ultrasound biomicroscopy study. *Ophthalmology*. 2008;115:430-434.
3. Kumar RS, Tantisevi V, Wong MH, et al. Plateau iris in Asian subjects with primary angle closure glaucoma. *Arch Ophthalmol*. 2009;127:1269-1272.
4. Ritch R. Plateau iris is caused by abnormally positioned ciliary processes. *J Glaucoma*. 1992;1:23-26.
5. Mansoori T, Sarvepally VK, Balakrishna N. Plateau iris in primary angle closure glaucoma: an ultrasound biomicroscopy study. *J Glaucoma*. 2016;25:e82-e86.

6. Mandell MA, Pavlin CJ, Weisbrod DJ, Simpson ER. Anterior chamber depth in plateau iris syndrome and pupillary block as measured by ultrasound biomicroscopy. *Am J Ophthalmol*. 2003;136:900-903.
7. Nongpiur ME, Atalay E, Gong T, et al. Anterior segment imaging-based subdivision of subjects with primary angle-closure glaucoma. *Eye*. 2017;31:572-577.
8. Kumar G, Bali SJ, Panda A, Sobti A, Dada T. Prevalence of plateau iris configuration in primary angle closure glaucoma using ultrasound biomicroscopy in the Indian population. *Indian J Ophthalmol*. 2012;60:175-178.
9. Alsagoff Z, Aung T, Ang LP, Chew PT. Long-term clinical course of primary angle-closure glaucoma in an Asian population. *Ophthalmology*. 2000;107:2300-2304.
10. Wang N, Wu H, Fan Z. Primary angle closure glaucoma in Chinese and Western populations. *Chin Med J (Engl)*. 2002;115:1706-1715.
11. He M, Friedman DS, Ge J, et al. Laser peripheral iridotomy in primary angle-closure suspects: biometric and gonioscopic outcomes: the Liwan Eye Study. *Ophthalmology*. 2007;114:494-500.
12. Baek S, Sung KR, Sun JH, et al. A hierarchical cluster analysis of primary angle closure classification using anterior segment optical coherence tomography parameters. *Invest Ophthalmol Vis Sci*. 2013;54:848-853.
13. Mizoguchi T, Ozaki M, Wakiyama H, Ogino N. Plateau iris in Japanese patients with primary angle closure and primary angle closure glaucoma. *Clin Ophthalmol*. 2015;9:1159-1163.
14. Wang BS, Narayanaswamy A, Amerasinghe N, et al. Increased iris thickness and association with primary angle closure glaucoma. *Br J Ophthalmol*. 2011;95:46-50.
15. Pavlin CJ, Foster FS. Plateau iris syndrome: changes in angle opening associated with dark, light, and pilocarpine administration. *Am J Ophthalmol*. 1999;128:288-291.
16. Chew PT, Aung T, Aquino MV, Rojanapongpun P; for the EXACT Study Group. Intraocular pressure-reducing effects and safety of latanoprost versus timolol in patients with chronic angle-closure glaucoma. *Ophthalmology*. 2004;111:427-434.
17. Aung T, Chan YH, Chew PT; for the EXACT Study Group. Degree of angle closure and the intraocular pressure-lowering effect of latanoprost in subjects with chronic angle-closure glaucoma. *Ophthalmology*. 2005;112:267-271.
18. Ritch R, Tham CC, Lam DS. Long-term success of argon laser peripheral iridoplasty in the management of plateau iris syndrome. *Ophthalmology*. 2004;111:104-108.