

Vitreous Fibronectin and Fibrinogen Expression Increased in Eyes With Proliferative Diabetic Retinopathy After Intravitreal Anti-VEGF Therapy

Qiaoling Wei,^{1,2} Ting Zhang,^{1,2} Rui Jiang,^{1,2} Qing Chang,^{1,2} Yanqiong Zhang,^{1,2} Xin Huang,^{1,2} Xing Gao,³ Hong Jin,³ and Gezhi Xu^{1,2}

¹Department of Ophthalmology, Eye and ENT Hospital, Shanghai Medical College, Fudan University, Shanghai, China

²Shanghai Key Laboratory of Visual Impairment and Restoration, Fudan University, Shanghai, China

³Institutes of Biomedical Sciences, Fudan University, Shanghai, China

Correspondence: Gezhi Xu, Department of Ophthalmology, Eye and ENT Hospital, Shanghai Medical College, Fudan University, No. 83 Fenyang Road, Xuhui District, Shanghai 200031, China; drxugezhi@163.com.

QW and TZ contributed equally to the work presented here and should therefore be regarded as equivalent authors.

Submitted: June 2, 2017

Accepted: October 5, 2017

Citation: Wei Q, Zhang T, Jiang R, et al. Vitreous fibronectin and fibrinogen expression increased in eyes with proliferative diabetic retinopathy after intravitreal anti-VEGF therapy. *Invest Ophthalmol Vis Sci.* 2017;58:5783–5791. DOI:10.1167/iops.17-22345

PURPOSE. To evaluate vitreous humor (VH) protein expression profiles in patients with proliferative diabetic retinopathy (PDR), with and without intravitreal injection (IVI) of anti-vascular endothelial growth factor (anti-VEGF) before vitrectomy.

METHODS. We enrolled consecutive PDR patients who needed pars plana vitrectomy (PPV) with or without IVI or pan-retinal photocoagulation (PRP). Visual acuity, duration, and treatment of diabetes mellitus, ocular treatment history, and fundus examinations were recorded. VH samples were collected without artificial humor infusion. Label-free quantitative proteomics analysis was performed to determine the protein expression profiles of VH samples. Enzyme-linked immunosorbent assays were performed to validate the proteomics results.

RESULTS. PDR patients who underwent IVI at a mean of 5.8 days (range, 3–8 days) before PPV (IVI group, $n = 12$) were younger than PDR patients with a history of PRP (PRP group, $n = 29$) and untreated PDR patients (control group, $n = 21$). The duration of diabetes mellitus was similar in the three groups. Label-free quantitative proteomics analysis showed that the signal intensities for fibronectin, fibrinogen α chain, fibrinogen β chain, fibrinogen γ chain, VEGF receptor 1 (VEGFR1), and VEGFR2 were significantly greater in the IVI group than in the other two groups. Enzyme-linked immunosorbent assays validated the results for fibronectin and fibrinogens, but found no significant differences in VEGF or VEGFR2 concentrations. VEGFR1 expression was significantly greater in the IVI and PRP groups than in the control group.

CONCLUSIONS. VH fibronectin and fibrinogen concentrations were highest in the IVI patients, which may promote fibrin-fibronectin complexation and fibrosis in eyes with PDR.

Keywords: anti-vascular endothelial growth factor injection, proliferative diabetic retinopathy, label-free quantitative proteomics, vitreous fibrosis, pan-retinal photocoagulation

Diabetic retinopathy (DR) is the leading cause of blindness in adults aged 20 to 74 years in industrialized countries.¹ In untreated eyes, neovascularization and fibrosis ultimately lead to vision loss due to tractional retinal detachment (TRD).² Remarkable advances in the treatment of DR have been made in recent decades. In particular, intravitreal vascular endothelial growth factor (VEGF) inhibitors and corticosteroids have advanced the treatment goal from stabilizing vision to improving vision. Intravitreal anti-VEGF drugs, including ranibizumab, bevacizumab, and conbercept, can reduce iridial and retinal neovascularization, and improve visual acuity in eyes with diabetic macular edema.^{3–7} In recent years, intravitreal anti-VEGF injection (IVI) has been performed as an adjunct to vitreoretinal surgery in patients with proliferative diabetic retinopathy (PDR). IVI facilitates surgery by limiting intraoperative bleeding from new vessels and minimizing bleeding while peeling the fibrovascular membranes in eyes with TRD. Bevacizumab was also shown to reduce early postoperative vitreous hemorrhage.^{8–13}

Despite these benefits of IVI, an increasing number of studies have provided evidence that IVI may increase the

severity of fibrosis in patients with proliferative vitreoretinopathy or exudative age-related macular degeneration, thus deteriorating visual acuity.^{9,14–18} Consistent with a prior study, we have recently observed the development of retinoschisis after IVI for the treatment of choroidal neovascularization in several patients with myopic retinoschisis (Wei Q, unpublished data, 2017). Progression of TRD involving the macula may cause serious vision loss even after successful anatomic retinal detachment repair. However, the molecular mechanism linking IVI to the initiation of fibrosis or changes in the contractile force of the vitreous body or the inner limiting membrane is still unclear.

Unlike the continuously replenished fluid-like aqueous humor in the anterior chamber of the eye, the gel-like vitreous humor (VH) is quite stagnant.¹⁹ Additionally, the VH is the first site in the eye where anti-VEGF drugs elicit their biological effects. Accordingly, changes in VH proteomics might represent the ocular effects of IVI. To our knowledge, however, there have been no comprehensive studies examining the effects of IVI or pan-retinal photocoagulation (PRP) on VH protein expression profiles in PDR patients.



Many studies have demonstrated that label-free quantitative proteomics analysis is capable of detecting low-abundance proteins in the VH and permits comprehensive comparisons of the protein expression profiles among different cell and tissue types.^{20–22} Thus, to explore VH protein expression, we performed label-free quantitative proteomics analysis to identify the differentially expressed proteins among three groups of patients with PDR: patients without prior treatment (untreated control group), patients with a history of PRP (PRP group), and patients with a history of IVI (IVI group).

METHODS

Subjects

We performed a cross-sectional, observational study of consecutive PDR patients who underwent surgical treatment at the Eye Department of the Eye and ENT Hospital, Fudan University Hospital, Shanghai, China, between September 2015 and May 2016. Patients with other retinal diseases (e.g., age-related macular degeneration), patients with a history of ocular surgery (including cataract extraction), patients who had received more than one IVI or if the injections occurred ≥ 7 days before surgery, and patients who underwent photodynamic therapy were excluded. The eligible patients were divided into three groups: patients without prior treatment (untreated control group), patients with a history of PRP (PRP group), and patients with a history of IVI with ranibizumab or conbercept (IVI group).

The present study was conducted in accordance with the principles of the Declaration of Helsinki and was approved by the Institutional Review Board and Ethical Committee of the Eye and ENT Hospital. All patients provided signed informed consent before enrollment. All patients underwent comprehensive preoperative eye examinations by the recruiting surgeons. Clinical data, including the medical history and treatment of diabetes mellitus, were collected. Eye examinations included measurement of visual acuity, intraocular pressure, axial length, biomicroscopy of the anterior and posterior segments of the eye, and fundus optical coherence tomography.

VH Sample Collection

VH samples (up to 1000 μ L) were collected before conventional three-port pars plana vitrectomy (PPV; 25G; Constellation; Alcon Instruments, Inc., Fort Worth, TX, USA) without artificial humor infusion. A 25-gauge trocar was introduced into the inferior temporal sclera, and a closed infusion tube was inserted. The stopcock of the vitrector aspiration line was opened and a 5-mL sterile syringe was attached. The vitrector was inserted into a superior temporal port. By active cutting combined with syringe suction, 500 μ L to 1 mL dry vitreous was aspirated into the syringe, the aspiration line was closed, and infusion was initiated to stabilize the intraocular pressure. The samples were transferred into sterile 1.5-mL microcentrifuge tubes, snap frozen, and stored at -80°C until further analysis.

Sample Preparation and Liquid Chromatography–Mass Spectrometry (LC-MS)

VH samples were prepared as previously described.²² In brief, the samples were centrifuged at 21,000g for 15 minutes at 4°C to remove cells or cell debris. A bicinchoninic acid (BCA) protein assay kit (Pierce; Thermo Scientific, Waltham, MA, USA) was used to measure the total protein concentration in

each sample. An aliquot of each VH sample was diluted in sterile water before measurement to achieve dilutions ranging from 1:30 to 1:50 in the BCA reaction mix to minimize any effects of blood (iron) or other interfering substances. Finally, we pooled 100 μ L VH samples within each patient group for LC-MS analysis to yield pooled samples for each of the three groups.

For LC-MS analysis, samples containing 200 μ g total protein were reduced with 10 mM dithiothreitol, alkylated with 20 mM iodoacetamide, and subjected to trypsin digestion with sequencing-grade modified trypsin (Promega, Madison, WI, USA) in the presence of 1 M urea. Tryptic peptides were purified using C18 microspin columns (Nest Group, Southborough, MA, USA).

LC-MS/MS Data Acquisition

The mixed peptides were separated by nano-high-performance liquid chromatography (Eksigent Technologies, Fudan University Shanghai, China) on a secondary reverse phase analytical column (Eksigent Technologies; C18, 3 μ m, 150 mm \times 75 μ m). Peptides were subsequently eluted using the following gradient conditions with phase B (98% acetonitrile with 0.1% formic acid) and increasing from 5% B to 45% B (5–70 minutes). The flow rate was set at 300 nL/minutes. The electrospray voltage was 2.3 kV relative to the MS inlet. The Triple TOF 4600 MS was operated in data-dependent mode to switch automatically between MS and MS/MS acquisition. MS spectra were acquired across the mass range of 350 to 1250 m/z with an accumulation time of 250 ms per spectrum. Tandem MS scans were performed across the mass range of 100 to 1250 m/z with a rolling collision energy setting. The 20 most intense precursors were selected for fragmentation per cycle with a dynamic exclusion time of 9 seconds.

Validation Using Enzyme-Linked Immunosorbent Assays (ELISA)

The concentrations of fibronectin, fibrinogens, VEGF, vascular endothelial growth factor receptor 1 (VEGFR1), and VEGFR2 were measured using sandwich ELISAs (Abcam, Cambridge, MA, USA) in eight randomly selected samples from each group. The vitreous samples were diluted by 11 times for fibronectin, 20 times for fibrinogens, 2 times for VEGF, 5 times for VEGFR1, and 6.7 times for VEGFR2. Quantification was conducted spectrophotometrically at a wavelength of 450 nm. The lowest limits of detection were 0.7 μ g/mL, 1.0 ng/mL, 10 pg/mL, 0.15 ng/mL, and 70 pg/mL for fibronectin, fibrinogen, VEGF, VEGFR1, and VEGFR2, respectively.

Label-Free Quantification

All raw data were processed using MaxQuant software (version 1.5.3.30; MaxQuant, Max Planck Institute of Biochemistry, Munich, Germany). Proteins were identified using the Andromeda search engine on the Human UniProtKB/Swiss-Prot database (Release 2015_10, with 20210 sequences; www.uniprot.org, in the public domain), which was expanded to include common environmental contaminants. The enzymatic condition was Trypsin/P, and a maximum of two missed cleavage sites was allowed. The mass tolerance was 20 ppm for fragmented ions. Carbamidomethylation of cysteine was defined as a fixed modification, while protein N-terminal acetylation and methionine oxidation were included as variable modifications. The cutoff false discovery rate for peptide and protein identification was set to 0.01. Label-free quantification was performed using MaxQuant software (version Max-

TABLE 1. Clinical Severity Grades of the Patients

Group	Type 1/Type 2 Diabetes Mellitus	Vitreous Hemorrhage Grade*	Fibrovascular Proliferation Severity Grade†
IVI group, <i>n</i> = 12	4/8	Grades 0/1/2: <i>n</i> = 0/5/7	Grades 0/1/2/3: <i>n</i> = 4/3/0/5
Control group, <i>n</i> = 21	1/20	Grades 0/1/2: <i>n</i> = 0/4/17	Grades 0/1/2/3: <i>n</i> = 13/0/0/8
PRP group, <i>n</i> = 29	1/28	Grades 0/1/2: <i>n</i> = 0/6/23	Grades 0/1/2/3: <i>n</i> = 18/0/1/10

* Vitreous hemorrhage grades: 0, none; 1, detectable/perioperatively visible vitreous hemorrhage; and 2, fundus-obscuring vitreous hemorrhage.

† Fibrovascular proliferation grades: 0, none; 1, visible fibrovascular proliferation; 2, significant fibrovascular proliferation without tractional retinal detachment; and 3, tractional retinal detachment.

Quant_1.5.3.30), and the iBAQ values in MaxQuant were used to quantify protein expression.

Data Processing and Statistical Analysis

Perseus software (Max Planck Institute of Biochemistry) was used to impute missing values from a normal distribution for statistical analysis. IBAQ values were used to compare the signal intensities among the three groups and assess the statistical significance. One-way analysis of variance was used to compare the age, duration of diabetes mellitus, and the signal intensities or protein concentrations among the three groups. Pearson's correlation analysis was used to test correlations among differentially expressed proteins. A difference in abundance with a *P* value of ≤ 0.05 was considered statistically significant.

RESULTS

Patient Characteristics

To identify the impact of IVI on VH protein expression profiles, we collected 62 VH samples from 59 patients with PDR. The patients were divided into three groups: untreated control group, PRP group, and IVI group. Vitreous hemorrhage and fibrovascular proliferation were graded according to fundus examinations and B-scan ultrasonography. The vitreous hemorrhage grades were as follows: 0: none; 1: detectable/perioperatively visible vitreous hemorrhage; and 2: fundus-obscuring vitreous hemorrhage. Fibrovascular proliferation was categorized into the following four grades: 0: none; 1: visible fibrovascular proliferation; 2: significant fibrovascular proliferation without TRD; and 3: TRD (Table 1). Additional patient characteristics are shown in Table 2. The mean patient age was significantly lower in the IVI group than in the PRP and control groups (Table 2). The IVI patients were characterized by a relatively young age, dense and active

vitreous hemorrhage, and a short postoperative recovery to allow them to return to work as soon as possible; these were the main reasons that the surgeons suggested IVI treatment prior to surgery for these patients. Unlike the IVI patients, the control and PRP patients were retired, and likely refused to receive IVI treatment before the surgery due to treatment expense; some even had active vitreous hemorrhage, similar to the IVI patients. However, no significant difference was found in the vitreous hemorrhage or fibrovascular proliferation grade among the three groups (Supplementary Table S1).

The duration of diabetes mellitus was not significantly different among the three groups. The total protein concentrations in eight randomly selected VH samples from each group were 1.49 ± 0.28 , 1.92 ± 0.91 , and 1.34 ± 0.06 $\mu\text{g}/\mu\text{L}$ in the control, PRP, and IVI groups, respectively (Table 2). The VH protein concentrations were not significantly different among the three groups.

VH Proteome in Eyes With PDR

In total, 196 differentially expressed proteins were detected in the VH samples (Supplementary Table S2). Most of these proteins belonged to a limited number of enriched protein families and groups, including 29 immunoglobulins, 12 complement components and factors, 10 apolipoproteins, 6 hemoglobins, 6 cytokeratins, 4 α -glycoproteins, fibronectin, 3 fibrinogens, 4 protease inhibitors of the interalpha-trypsin family, and 3 spectrin chains. We also found differential expression in $\alpha 2$ -macroglobulin, vitamin D-binding protein, and prostaglandin-H2 D-isomerase, which were previously referred to as biomarkers for diabetes mellitus.²²⁻²⁷ In addition, the proteins ceruloplasmin, α -synuclein, flavin reductase, glutathione peroxidase-3, catalase, and peroxiredoxin-2 were differentially expressed among the three groups. The signal intensities for the differentially expressed proteins are shown in Supplementary Table S3.

TABLE 2. Patient Characteristics

Characteristics	Control Group	PRP Group	IVI Group
Vitreous sample, <i>n</i>	21	29	12
Sex, male/female	10/11	14/15	8/4
Age, y, mean, range	58.9, 44-72	53.1, 28-76	41.4, 26-63
Duration of diabetes mellitus, y, mean, range	12.5, 1.5-32	12.7, 0.5-30	6.8, 0.5-16
Patients on subcutaneous insulin therapy/total patients	10/21	18/29	6/12
Diagnosis of tractional retinal detachment/total patients	12/21	10/29	6/12
Retinal laser frequency, mean, range	0	3.5, 1-6	2.1, 0-7
Days between IVI and surgery, mean, range	-	-	5.8, 3-8
Vitreous total protein concentration, $\mu\text{g}/\mu\text{L}$	1.49 ± 0.28	1.92 ± 0.91	1.34 ± 0.06

Values represent the number of patients, or mean, range. Control group, proliferative diabetic retinopathy (PDR) patients without treatment; PRP group, PDR patients with pan-retinal photocoagulation (PRP); IVI group, PDR patients with anti-vascular endothelial growth factor (VEGF) injection (IVI).

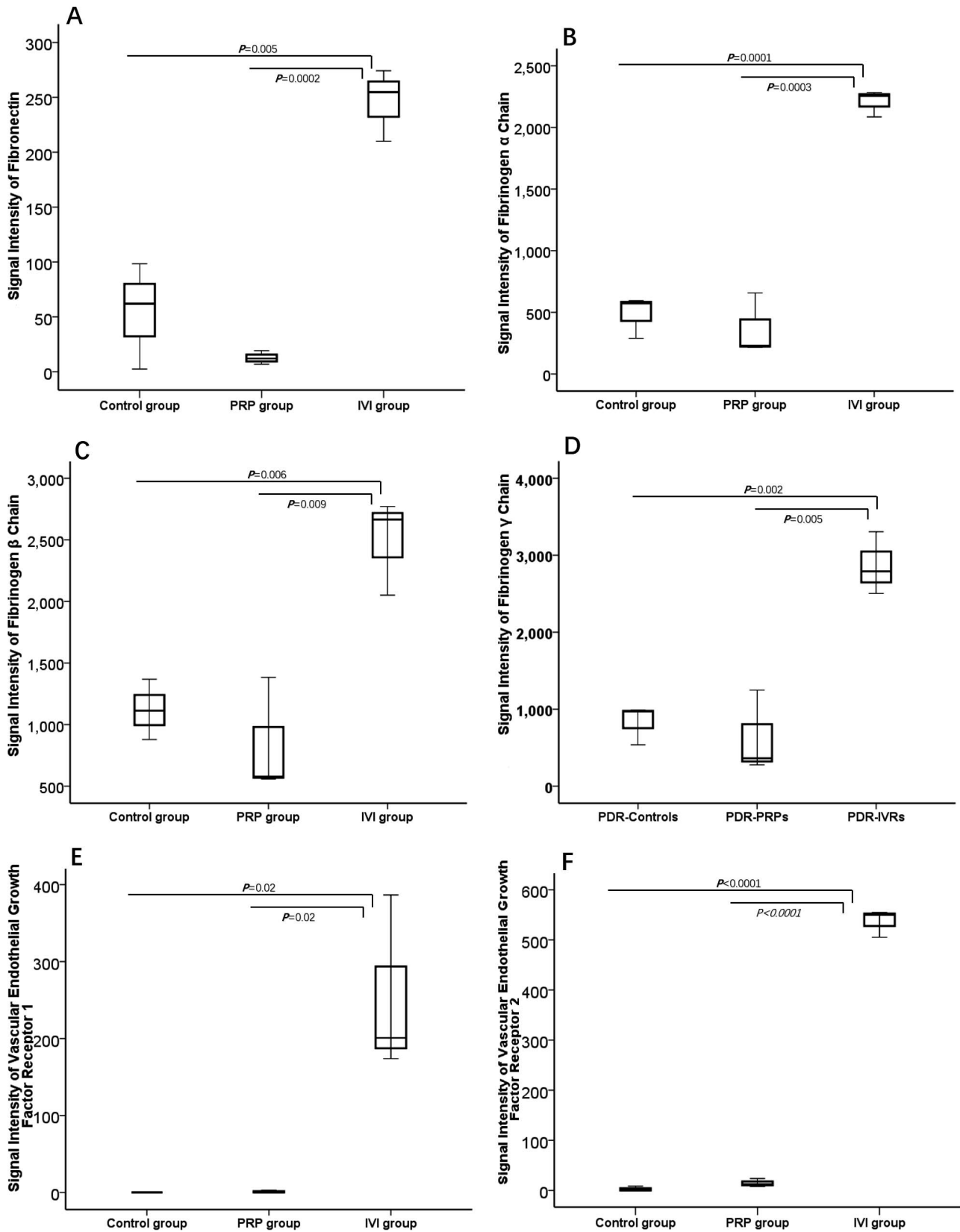


FIGURE 1. Comparison of signal intensities among three groups of patients with proliferative diabetic retinopathy: untreated patients (control group), patients treated with pan-retinal photocoagulation (PRP group), and patients treated with intravitreal anti-vascular endothelial growth factor injections (IVI group). (A) Signal intensity of fibronectin, (B) signal intensity of fibrinogens α chain, (C) signal intensity of fibrinogens β chain, (D) signal intensity of fibrinogens γ chain, (E) signal intensity of vascular endothelial growth factor receptor 1, (F) signal intensity of vascular endothelial growth factor receptor 2. Signal intensities were determined by label-free quantitative proteomics analysis. One-way analysis of variance was used, and $P < 0.05$ was considered statistically significant.

TABLE 3. Protein Concentrations in Vitreous Humor Measured by Enzyme-Linked Immunosorbent Assay

Proteins	Control Group	PRP Group	IVI Group	P Value*
Fibronectin, $\mu\text{g/mL}$	4.04 ± 2.94	4.51 ± 2.94	12.72 ± 8.94	0.007
Fibrinogens, $\mu\text{g/mL}$	1.22 ± 0.12	1.33 ± 0.16	1.71 ± 0.27	0.0001
VEGF, ng/mL	0.19 ± 0.08	0.14 ± 0.09	0.52 ± 0.61	0.09
VEGFR1, ng/mL	3.44 ± 1.83	13.07 ± 5.69	13.86 ± 12.24	0.03
VEGFR2, ng/mL	1.87 ± 0.89	1.99 ± 1.06	1.31 ± 0.66	0.28

Values represent the mean \pm standard deviation. Control group, proliferative diabetic retinopathy (PDR) patients without treatment; PRP group, PDR patients with pan-retinal photocoagulation (PRP); IVI group, PDR patients with anti-vascular endothelial growth factor (VEGF) injection (IVI).

* Determined by 1-way analysis of variance, with $P < 0.05$ considered statistically significant.

VH Proteome in Eyes With PDR

When comparing the signal intensities between the IVI group and the other groups, we found that the signal intensities for five immunoglobulins, three complement components, and apolipoprotein A-I were significantly greater in the IVI group. It is also notable that signal intensities for fibronectin and fibrinogen α , β , and γ chains were greatest in the IVI group (Figs. 1A–D). The signal intensities for VEGFR1 and VEGFR2 were greatest in the IVI group and were weak in the control and PRP groups (Figs. 1E, 1F). In addition, the signal intensities for carbonic anhydrase-2, erythroid α -spectrin, and small subunit processome component 20 homolog were greater in the IVI group than in the other groups.

Most of the patients in the PRP group underwent PRP 1 year before PPV, and 22/29 patients underwent retinal laser therapy more than three times. The signal intensities for 17 proteins were significantly lower in the PRP group than in the other groups. These proteins are listed in Supplementary Table S3.

ELISA Validation of the Proteomics Analysis

To validate the results of the MS proteomic analysis, we used ELISAs to measure the protein concentrations in eight randomly selected VH samples from each group (detailed in Supplementary Table S4). The results of the ELISAs are shown in Table 3 and Figures 2A through 2F. ELISA results and clinical characteristics of the patients in the IVI group are shown in Tables 4 and 5. The concentrations of fibronectin and fibrinogens were significantly greater in the IVI group than in the PRP and control groups. However, there were no significant differences in VEGF or VEGFR2 concentrations among the three groups (Table 3). VEGFR1 expression was markedly lower in the control group than in the IVI and PRP groups.

DISCUSSION

The aim of this study was to investigate and compare the VH protein expression profile among patients with untreated PDR, patients who underwent PRP, and patients who underwent IVI. To achieve this, we performed label-free quantitative proteomics analysis. The VH concentrations of VEGF have been reported to be correlated with the severity of DR.²⁸ We observed no significant differences in VEGF concentrations among the three groups, which indicates a lower likelihood of selection bias among our groups. We also found significant positive correlations between fibronectin and VEGF concentrations in our study, consistent with a prior study.²⁸ All of the IVI patients underwent surgery within 1 week after IVI, and none of them experienced detectable, secondary TRD after IVI.

Our study identified 196 differentially expressed proteins in 62 VH samples from patients with PDR. Of note, we found increased expression of several proteins, including α 2-macroglobulin, vitamin D-binding protein, and prostaglandin-H2 D-isomerase, which have been proposed as biomarkers for diabetes mellitus.^{22–27}

In recent years, there has been accumulating evidence showing that IVI increases the risk of TRD in patients with severe PVR.^{9,14–18} However, the molecular mechanism underlying the profibrotic effects of anti-VEGF drugs is not fully understood. Elucidation of the complex cellular and molecular mechanisms involved in the progression of fibrosis after anti-VEGF treatment in PDR patients may help us to improve the outcomes of this treatment.

Earlier studies revealed that the balance between connective tissue growth factor (CTGF) and VEGF is implicated in the switch from angiogenesis to fibrosis in intraocular fibrosis.^{29–31} However, the label-free proteomics analysis used here did not detect CTGF expression but did show upregulation of fibronectin and fibrinogen α , β , and γ chains in the IVI group; these results were validated by the ELISA test.

Fibronectin increased in human eyes with intraocular fibrosis associated with proliferative vitreoretinopathy.^{32,33} Fibrinogen α , β , and γ chains polymerize to form an insoluble fibrin matrix. Extravascular fibrin and fibronectin deposits precede collagen formation or fibrosis. It was reported that the fibrin–fibronectin complex is the main factor that directly promotes the progression of fibrosis, while CTGF augments tissue fibrosis by enhancing the affinity of fibronectin to fibrin in pathologic conditions.³⁴ Thus, we suggest that fibrin–fibronectin complex formation is a molecular mechanism underlying the development of TRD following IVI. This might explain why the patients diagnosed with dense vitreous hemorrhage or preexisting TRD are more likely to develop severe TRD after IVI.^{9,14–18}

Our label-free proteomics analysis showed that the expression levels of VEGFR1 and VEGFR2 were much greater in the IVI group than in the control and PRP groups. However, these results were not fully verified by the ELISA results. The results of the ELISA and proteomics analyses were consistent for VEGFR1, and showed that VEGFR1 expression was greatest in the IVI group and lowest in the control group. So far, the specific function of VEGFR1 in DR has not been fully established.³⁵ A prior study revealed that VEGFR1 blockade prevented vascular leakage, retinal leukostasis, degeneration, and disorganization of the tight junction protein zonula occludens-1 and the adhesion molecule vascular endothelial cadherin in DR. In general, VEGFR1 plays dual roles in terms of stimulating or inhibiting angiogenesis according to the pathophysiological microenvironment, while activation of VEGFR2 is believed only to promote angiogenesis.³⁵ VEGFR2 plays an essential role in VEGF-induced endothelial mitogenesis and permeability by activating its downstream kinases, including mitogen-activated protein

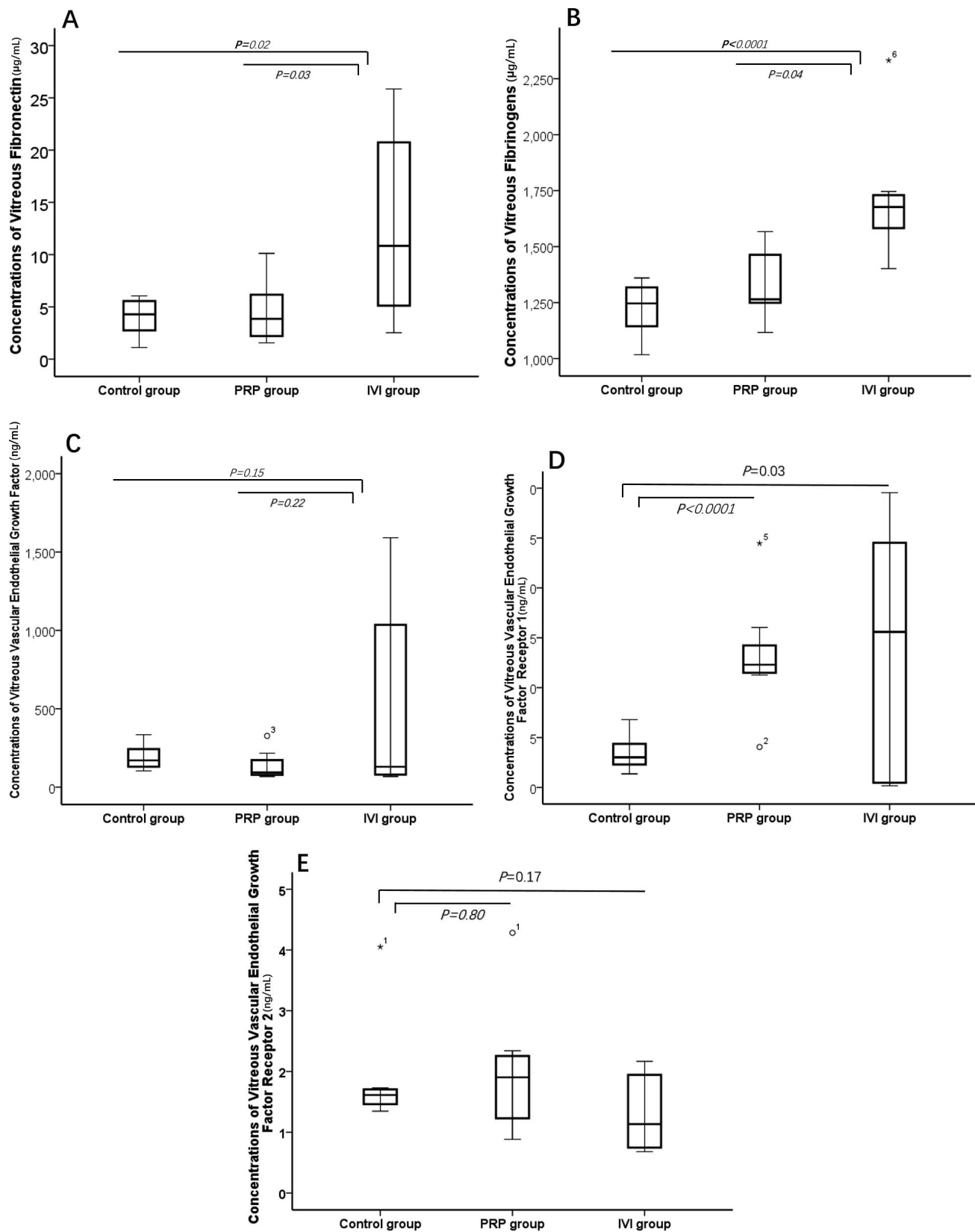


FIGURE 2. Comparison of the vitreous humor protein concentrations among three groups of patients with proliferative diabetic retinopathy: untreated patients (control group), patients treated with pan-retinal photocoagulation (PRP group), and patients treated with intravitreal anti-vascular endothelial growth factor injections (IVI group). (A) Concentrations of vitreous fibronectin, (B) concentrations of vitreous fibrinogens, (C) concentrations of vitreous vascular endothelial growth factor, (D) concentrations of vitreous vascular endothelial growth factor receptor 1, (E) concentrations of vitreous vascular endothelial growth factor receptor 2. Concentrations were determined by enzyme-linked immunosorbent assays. One-way analysis of variance was used, and $P < 0.05$ was considered statistically significant.

TABLE 4. ELISA Results and Clinical Characteristics of the Patients in the IVI Group

Patients	VEGF Concentration, pg/mL	Sex	Age, y	Diabetes Mellitus Type	Diabetes Duration, y	HbA1c
Patient 4	1589.96	2	26	1	10	5.7
Patient 2	1093.08	2	37	2	7	6.2
Patient 10	977.02	2	55	2	16	7.5
Patient 11	169.86	1	30	2	0.8	7.2
Patient 8	89.66	2	50	2	6	7.5
Patient 9	89.66	2	44	2	2	8.5
Patient 3	70.46	2	30	1	7	4.9
Patient 1	67.4	1	46	2	1	6.1

kinases (ERK1/2, p38, JNK), phosphoinositide 3-kinase/Akt, and endothelial nitric oxide synthase.³⁶ However, the ELISA for VEGFR2 revealed no significant difference ($P = 0.13$) in VEGFR2 concentrations among the three groups, and showed that the VEGFR2 concentration was numerically greater in the control group (2.33 ± 1.87 ng/mL) than in the PRP group (1.97 ± 1.00 ng/mL) and IVI group (1.21 ± 0.66 ng/mL). Possible mechanisms causing downregulation of VEGFR2 by IVI should be assessed in a larger number of samples from PDR patients, ideally in a randomized controlled fashion, with or without IVI.

PRP, which is usually considered the first choice of treatment for PDR, suppresses VEGF expression, blocks growth of new vessels, and can stabilize the patient's visual acuity.^{2,37} Most of the patients in the PRP group underwent PRP 1 year before vitreous surgery. The label-free proteomics analysis revealed that the signal intensities of carbonic anhydrase-1 and -2 in the VH were lower in the PRP and IVI groups. Carbonic anhydrase rapidly converts carbon dioxide to bicarbonate and protons, and carbonic anhydrase inhibitors have been used for many years to lower intraocular pressure. Some studies have suggested that these inhibitors reduce vascular leakage and macular edema.³⁸ Therefore, downregulation of carbonic anhydrase-1 and -2, as induced by IVI and PRP, may represent a treatment mechanism for DR.³⁹

Additionally, we found that the expression of osteopontin, which has proinflammatory effects and promotes endothelial cell migration enhancer,⁴⁰ was significantly greater in the control group than in the PRP group ($P = 0.021$). Taken together, these findings suggest that downregulation of osteopontin and carbonic anhydrase-1 and -2 are involved in the mechanisms of PRP for treating DR.

Finally, we found that catalase, which protects cells from the toxic effects of hydrogen peroxide,⁴¹ and hemoglobin subunit β , which is involved in transporting oxygen from the lung to peripheral tissues,⁴² were downregulated in the PRP group. These findings suggest that PRP disturbs the normal physiological status of the VH.

Our study used a proteomics approach to screen for molecular signatures in patients who had previously undergone PRP or IVI. We divided the patients into three groups based on their history of PRP and anti-VEGF treatment, or absence of either treatment. We found some clear differences in the VH protein expression profiles among the control, PRP, and IVI groups. The patients selected to receive IVI prior to surgery exhibited increased expression of fibronectin and fibrinogen α , β , and γ chains compared with the other two groups. The increased expression either was induced by IVI or was a preexisting shared feature among those patients selected for IVI. Therefore, we should consider the possibility of TRD following IVI in patients with severe PDR, especially in patients with dense vitreous hemorrhage, and a timely surgical approach should be considered after IVI. Considering our results, we think it would be beneficial to explore the effects of combined administration of anti-VEGF and anti-fibrin-fibronectin complex-forming drugs in patients selected for IVI with indications similar to those of our patients. The limitations of the current study include the small sample size of the IVI group and unmatched patients in terms of age and type of diabetes mellitus between the IVI group and the other two groups. Large-scale clinical studies and in vitro experiments are necessary to investigate the relationship between IVI and fibrosis in the future.

TABLE 5. ELISA Results and Clinical Characteristics of the Patients in the IVI Group

Patients	VEGF Concentration, pg/mL	Vitreous Hemorrhage Grade	Fibrovascular Proliferation Grade	Laser Photocoagulation	Intraocular Drugs	Intraocular Injection Frequency	Days Between IVI and Surgery	Other Systemic Diseases
Patient 4	1589.96	1	1	0	2	1	5	2
Patient 2	1093.08	2	0	1	1	1	7	0
Patient 10	977.02	1	1	0	1	1	6	1
Patient 11	169.86	1	3	0	1	1	6	0
Patient 8	89.66	2	3	0	1	1	7	1+2
Patient 9	89.66	1	1	2	1	1	5	1
Patient 3	70.46	2	3	0	2	1	7	0
Patient 1	67.4	2	0	0	1	1	5	0

Vitreous hemorrhage: 0, none; 1, detectable/perioperatively visible vitreous hemorrhage; 2, fundus-obscuring vitreous hemorrhage. Fibrovascular proliferation: 0, none; 1, visible fibrovascular proliferation; 2, significant fibrovascular proliferation without tractional retinal detachment; 3, tractional retinal detachment. Intraocular drugs: 0, none; 1, ranibizumab; 2, conbercept. Laser photocoagulation: 0, none; 1, partial pan-retinal photocoagulation (frequency < 4); 2, total pan-retinal photocoagulation (frequency ≥ 4). Other systemic diseases: 0, none; 1, hypertension; 2, diabetic nephropathy.

Acknowledgments

Supported by the National Natural Science Foundation of China (81570854) and the Foundation for the Shanghai Key Laboratory of Visual Impairment and Restoration (12DZ2260500).

Disclosure: **Q. Wei**, None; **T. Zhang**, None; **R. Jiang**, None; **Q. Chang**, None; **Y. Zhang**, None; **X. Huang**, None; **X. Gao**, None; **H. Jin**, None; **G. Xu**, None

References

- Cheung N, Mitchell P, Wong TY. Diabetic retinopathy. *Lancet*. 2010;376:124–136.
- Diabetic Retinopathy Study Research Group. Photocoagulation treatment of proliferative diabetic retinopathy: clinical application of Diabetic Retinopathy Study (DRS) findings, DRS report number 8. *Ophthalmology*. 1981;88:583–600.
- Bressler SB, Beaulieu WT, Glassman AR, et al. Factors associated with worsening proliferative diabetic retinopathy in eyes treated with panretinal photocoagulation or ranibizumab. *Ophthalmology*. 2017;124:431–439.
- Parikh RN, Traband A, Kolomeyer AM, et al. Intravitreal bevacizumab for the treatment of vitreous hemorrhage due to proliferative diabetic retinopathy. *Am J Ophthalmol*. 2017;176:194–202.
- Su L, Ren X, Wei H, et al. Intravitreal conbercept (kh902) for surgical treatment of severe proliferative diabetic retinopathy. *Retina*. 2016;36:938–943.
- Elman MJ, Aiello LP, Beck RW, et al.; for the Diabetic Retinopathy Clinical Research Network. Randomized trial evaluating ranibizumab plus prompt or deferred laser or triamcinolone plus prompt laser for diabetic macular edema. *Ophthalmology*. 2010;117:1064–1077.
- Ip MS, Domalpally A, Hopkins JJ, et al. Long-term effects of ranibizumab on diabetic retinopathy severity and progression. *Arch Ophthalmol*. 2012;130:1145–1152.
- Avery RL, Pearlman J, Pieramici DJ, et al. Intravitreal bevacizumab (avastin) in the treatment of proliferative diabetic retinopathy. *Ophthalmology*. 2006;113:1695.
- di Lauro R, De Ruggiero P, di Lauro R, et al. Intravitreal bevacizumab for surgical treatment of severe proliferative diabetic retinopathy. *Graefes Arch Clin Exp Ophthalmol*. 2010;248:785–791.
- Ahmadieh H, Shoeibi N, Entezari M, et al. Intravitreal bevacizumab for prevention of early postvitrectomy hemorrhage in diabetic patients: a randomized clinical trial. *Ophthalmology*. 2009;116:1943–1948.
- Smith JM, Steel DH. Anti-vascular endothelial growth factor for prevention of postoperative vitreous cavity haemorrhage after vitrectomy for proliferative diabetic retinopathy. *Cochrane Database Syst Rev*. 2011;5:CD008214.
- Chen E, Park CH. Use of intravitreal bevacizumab as a preoperative adjunct for tractional retinal detachment repair in severe proliferative diabetic retinopathy. *Retina*. 2006;26:699–700.
- El-Sabagh HA, Abdelghaffar W, Labib AM, et al. Preoperative intravitreal bevacizumab use as an adjuvant to diabetic vitrectomy: histopathologic findings and clinical implications. *Ophthalmology*. 2011;118:636–641.
- van der Reis MI, La Heij EC, De Jong-Hesse Y, et al. A systematic review of the adverse events of intravitreal anti-vascular endothelial growth factor injections. *Retina*. 2011;31:1449–1469.
- Zhang M, Chu S, Zeng F, et al. Bevacizumab modulates the process of fibrosis in vitro. *Clin Exp Ophthalmol*. 2015;43:173–179.
- Arevalo JF, Maia M, Flynn HW Jr, et al. Tractional retinal detachment following intravitreal bevacizumab (Avastin) in patients with severe proliferative diabetic retinopathy. *Br J Ophthalmol*. 2008;92:213–216.
- Jonas JB, Schmidbauer M, Rensch F. Progression of tractional retinal detachment following intravitreal bevacizumab. *Acta Ophthalmol*. 2009;87:571–572.
- Batman C, Ozdamar Y. The relation between bevacizumab injection and the formation of subretinal fibrosis in diabetic patients with panretinal photocoagulation. *Ophthalmic Surg Lasers Imaging*. 2010;41:190–195.
- Gisladdottir S, Loftsson T, Stefansson E. Diffusion characteristics of vitreous humor and saline solution follow the Stokes Einstein equation. *Graefes Arch Clin Exp Ophthalmol*. 2009;247:1677–1684.
- Levin Y, Schwarz E, Wang L, et al. Label-free LC-MS/MS quantitative proteomics for large-scale biomarker discovery in complex samples. *J Sep Sci*. 2007;30:2198–2203.
- Megger DA, Bracht T, Meyer HE, et al. Label-free quantification in clinical proteomics. *Biochim Biophys Acta*. 2013;1834:1581–1590.
- Loukovaara S, Nurkkala H, Tamene F, et al. Quantitative proteomics analysis of vitreous humor from diabetic retinopathy patients. *J Proteome Res*. 2015;14:5131–5143.
- Gray RS, James K, Merriman J, et al. Alpha 2-macroglobulin and proliferative retinopathy in type 1 diabetes. *Horm Metab Res*. 1982;14:389–392.
- James K, Merriman J, Gray RS, et al. Serum alpha 2-macroglobulin levels in diabetes. *J Clin Pathol*. 1980;33:163–166.
- Takada T, Kodera Y, Matsubara M, et al. Serum monomeric alpha2-macroglobulin as a clinical biomarker in diabetes. *Atherosclerosis*. 2013;228:270–276.
- Ouchi M, West K, Crabb JW, et al. Proteomic analysis of vitreous from diabetic macular edema. *Exp Eye Res*. 2005;81:176–182.
- Kim SJ, Kim S, Park J, et al. Differential expression of vitreous proteins in proliferative diabetic retinopathy. *Curr Eye Res*. 2006;31:231–240.
- Aiello LP, Avery RL, Arrigg PG, et al. Vascular endothelial growth factor in ocular fluid of patients with diabetic retinopathy and other retinal disorders. *N Engl J Med*. 1994;331:1480–1487.
- Van Geest RJ, Lesnik-Oberstein SY, Tan HS, et al. A shift in the balance of vascular endothelial growth factor and connective tissue growth factor by bevacizumab causes the angiofibrotic switch in proliferative diabetic retinopathy. *Br J Ophthalmol*. 2012;96:587–590.
- Kuiper EJ, Van Nieuwenhoven FA, de Smet MD, et al. The angio-fibrotic switch of VEGF and CTGF in proliferative diabetic retinopathy. *PLoS One*. 2008;3:2675.
- Klaassen I, van Geest RJ, Kuiper EJ, et al. The role of CTGF in diabetic retinopathy. *Exp Eye Res*. 2015;133:37–48.
- Campochiaro PA, Jerdan JA, Glaser BM, et al. Vitreous aspirates from patients with proliferative vitreoretinopathy stimulate retinal pigment epithelial cell migration. *Arch Ophthalmol*. 1985;103:1403–1405.
- Connor TB Jr, Roberts AB, Sporn MB, et al. Correlation of fibrosis and transforming growth factor-beta type 2 levels in the eye. *J Clin Invest*. 1989;83:1661–1666.
- Yoshida K, Munakata H. Connective tissue growth factor binds to fibronectin through the type I repeat modules and enhances the affinity of fibronectin to fibrin. *Biochim Biophys Acta*. 2007;1770:672–680.
- Shibuya M. Differential roles of vascular endothelial growth factor receptor-1 and receptor-2 in angiogenesis. *J Biochem Mol Biol*. 2006;39:469–478.
- Huang X, Zhou G, Wu W, et al. Editing VEGFR2 blocks VEGF-induced activation of Akt and tube formation. *Invest Ophthalmol Vis Sci*. 2017;58:1228–1236.

37. The Diabetic Retinopathy Study Research Group. Indications for photocoagulation treatment of diabetic retinopathy: Diabetic Retinopathy Study Report No. 14. *Int Ophthalmol Clin.* 1987;27:239-253.
38. Huckfeldt RM, Comander J. Management of cystoid macular edema in retinitis pigmentosa. *Semin Ophthalmol.* 2017;32:43-51.
39. Gao BB, Clermont A, Rook S, et al. Extracellular carbonic anhydrase mediates hemorrhagic retinal and cerebral vascular permeability through prekallikrein activation. *Nat Med.* 2007;13:181-188.
40. Ahmed M, El-Asrar A, Nawaz MI, et al. Osteopontin and other regulators of angiogenesis and fibrogenesis in the vitreous from patients with proliferative vitreoretinal disorders. *Mediators Inflamm.* 2012;2012:493043.
41. Takeuchi A, Miyamoto T, Yamaji K, et al. A human erythrocyte-derived growth-promoting factor with a wide target cell spectrum: identification as catalase. *Cancer Res.* 1995;55:1586-1589.
42. Kidd RD, Russell JE, Watmough NJ, et al. The role of beta chains in the control of the hemoglobin oxygen binding function: chimeric human/mouse proteins, structure, and function. *Biochemistry.* 2001;40:15669-15675.