

Comparison of Foveal, Macular, and Peripapillary Intraretinal Thicknesses Between Autism Spectrum Disorder and Neurotypical Subjects

José Javier García-Medina,¹⁻⁴ María García-Piñero,⁵ Mónica del-Río-Vellosillo,⁶ Jesarán Fares-Valdivia,¹ Ana Belén Ragel-Hernández,⁷ Salvador Martínez-Saura,⁸ María Dolores Cárcel-López,⁷ Vicente Zanon-Moreno,^{3,4,9} María Dolores Pinazo-Duran,^{3,4,10} and María Paz Villegas-Pérez^{1,2,4}

¹General University Hospital Reina Sofía, Murcia, Spain

²Department of Ophthalmology, Optometry, Otolaryngology and Pathology. School of Medicine, University of Murcia, Spain

³Ophthalmic Research Unit “Santiago Grisolia”, Valencia, Spain

⁴Spanish Net of Ophthalmic Pathology OFTARED, Institute of Health Carlos III, Madrid, Spain

⁵Faculty of Biology, University of Murcia, Spain

⁶University Hospital Virgen de la Arrixaca, Murcia, Spain

⁷Integral Formation Center “Gabriel Perez Carcel”, Murcia, Spain

⁸Asociación para la atención de personas con trastornos generalizados del desarrollo de la región de Murcia (ASTRADE), Murcia, Spain

⁹Department of Preventive Medicine and Public Health, School of Medicine, University of Valencia, Valencia, Spain

¹⁰Department of Ophthalmology, School of Medicine, University of Valencia, Spain

Correspondence: José Javier García-Medina, Department of Ophthalmology, General University Hospital Reina Sofía, Avenida Intendente Jorge Palacios, 1, 30003 Murcia, Spain; josegarciam@yahoo.com, jj.garciamedina@um.es.

Submitted: May 16, 2017

Accepted: October 5, 2017

Citation: García-Medina JJ, García-Piñero M, del-Río-Vellosillo M, et al. Comparison of foveal, macular, and peripapillary intraretinal thicknesses between autism spectrum disorder and neurotypical subjects. *Invest Ophthalmol Vis Sci.* 2017;58:5819-5826. DOI:10.1167/iovs.17-22238

PURPOSE. To compare thicknesses of intraretinal layers segmented by spectral-domain optical coherence tomography (SD-OCT) between autism spectrum disorder (ASD) and neurotypical (NT) individuals.

METHODS. We performed 2 scans on 108 eyes from 54 participants (27 high-functioning ASD and 27 age- and sex-matched NT subjects): macular fast volume and peripapillary retinal nerve fiber layer (pRNFL). Macula was automatically segmented. The mean foveal and macular thickness of nine different layers and the thickness of nine pRNFL sectors were considered. Data from the right and left eyes were averaged for each participant. The results were compared between the ASD and NT groups. Associations between the Kaufman brief intelligence test (K-BIT), head circumference and SD-OCT results were also investigated in ASD individuals.

RESULTS. ASD subjects showed greater foveal thickness at total retina, total inner retina, inner plexiform and inner nuclear layers, and greater macular thickness at total retina and total inner retina. Inferior, nasal inferior and temporal inferior sectors of pRNFL were also thicker in the ASD participants than in the controls ($P < 0.05$, unpaired t -test). Significant correlations were found between some K-BIT results and temporal inferior and inferior pRNFL thicknesses in the ASD group ($P < 0.05$, Spearman's rank correlation). No associations were seen between head circumference and OCT parameters.

CONCLUSIONS. There are intraretinal thickenings at different locations in ASD subjects when compared to NT controls. This fact should be taken into account when interpreting SD-OCT examinations in ASD individuals. Plus, some pRNFL thicknesses present positive correlations with scores of cognitive status in ASD.

Keywords: autism, optical coherence tomography, neurotypical, thickness, retina

Autism spectrum disorder (ASD) comprises various types of lifelong disabilities characterized by impaired social interactions, difficulties with verbal and nonverbal communication, stereotyped patterns of behavior, and restricted interests.¹ Its prevalence is around 1% of the population and its incidence is increasing.^{2,3} Recently, it has been estimated that 1 in 68 children in the United States has been identified with ASD.⁴ The etiology of ASD still remains unknown. However, it has been found that gray and white matter in the brains of ASD

individuals present different regional change patterns of volume, thickness, and structure compared with controls. Abnormalities of interconnectivity among cerebral regions in ASD subjects have also been reported.⁵⁻⁷

The retina is an extension of the central nervous system. Thus, it shows a relationship and resemblance with the brain in terms of embryology, anatomy, physiology, and histopathology. Similarly to the brain, the retina has the equivalent of white matter (plexiform and nerve fiber layers) and gray matter



(nuclear and ganglion cell layers).⁸ Based on these analogies, we hypothesized that the retina may also be altered in ASD.

Spectral domain optical coherence tomography (SD-OCT) has recently permitted the identification in vivo of individual retina layers and the estimation of their thicknesses by different segmentation algorithms.⁹ Not surprisingly, some central nervous system disorders, such as Parkinson's disease,¹⁰ Alzheimer's disease,¹¹ multiple sclerosis,¹² or schizophrenia¹³ showed thinning of the intraretinal layers.

However, very little is known about retinal thicknesses in ASD. To the best of our knowledge, only one study has studied ASD subjects by SD-OCT.¹⁴ The authors compared the peripapillary retinal nerve fiber layer (pRNFL) between the ASD and neurotypical (NT) groups, and found a reduced pRNFL in the former group. Nevertheless, as far as we know, the thickness of the retinal layers in the macula has not previously been investigated in ASD. Therefore, this research intended to evaluate the thicknesses of segmented macular layers in ASD and to assess pRNFL measurements. In addition, it correlated the thickness of the retinal layers with the cognitive abilities and head circumference of the ASD subjects.

METHODS

Recruitment

This was a prospective, observational, cross-sectional study. Young ASD subjects were recruited from two specialized formation centers: Integral Formation Center "Gabriel Pérez Carcel" and ASTRADE, both located in Murcia, Spain. All the examinations were performed between September 2015 and March 2016 in the General University Hospital Reina Sofía, Murcia, Spain. The study included two groups of patients: ASD and NT subjects. Inclusion criteria for ASD subjects were: (1) Caucasian race; (2) aged under 21 years; (3) diagnosis of ASD with the *Diagnostic and Statistical Manual of Mental Disorders*, Fifth Edition (DSM-5) criteria¹⁵ confirmed at least by two different specialists; (4) refractive error of less than 6 spherical diopters and 2.5 cylinder diopters; (5) best corrected visual acuity (BCVA) of 20/40 or better; (6) no signs or history of ocular diseases (including ocular surgery); (7) no systemic disease that may alter OCT measurements; (8) adequate collaboration to perform good quality and correctly segmented SD-OCT scans without artifacts (see below) so only high-functioning ASD cases could be included.

Control NT subjects were selected age- and sex-matched with ASD subjects. The inclusion criteria for the NT group were the same as the criteria used for the ASD group except for criterion number 3. An additional inclusion criterion for the NT subjects was to have no family relationship with ASD subjects. The control group was recruited from healthy volunteers who attended routine ophthalmic check-ups at General University Hospital Reina Sofía, Murcia, Spain.

Parents/guardians' consent was signed for all the participants aged under 18. Older subjects signed the consent themselves or, alternatively, parents/guardians' consent was obtained. The study was conducted in accordance with the tenets of the Declaration of Helsinki and had been previously approved by the hospital's Ethics Committee.

Ophthalmic Examinations

All the ASD and NT subjects underwent complete ophthalmic examination, which included the following and in this order: autorefractometry, BCVA, air-puff tonometry, and funduscopy. The data of these examinations were taken into account for the inclusion/exclusion criteria.

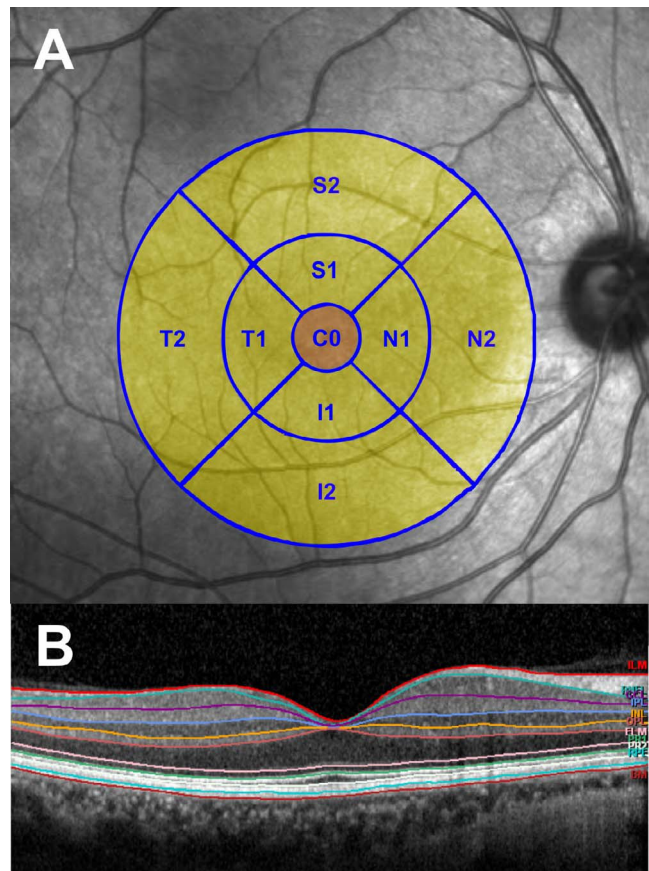


FIGURE 1. Macular examination. (A) ETDRS macular grid. The thickness of all sectors (C0, S1, S2, N1, N2, T1, T2, I1, and I2) was averaged to obtain macular thickness values. Thickness in the central circle (C0) was considered the foveal measurement. (B) Automatic segmentation of the different intraretinal layers in macula.

SD-OCT examinations were performed with an OCT device (Spectralis software version 6.0; Heidelberg Engineering, Heidelberg, Germany), which had an automatic eye tracking system (TruTrack Active Eye Tracking) to compensate eye movements. Two examinations were done in both eyes of each subject: a macular fast volume scan and a standard pRNFL thickness scan.

A macular fast volume scan comprised 25 horizontal scans with an area of 666 mm² centered at the fovea. In this examination, mean retinal thicknesses were estimated in microns in the sectors that correspond to the Early Treatment Diabetic Retinopathy Study (ETDRS) grid (Fig. 1A). Macular layers were automatically segmented using the prototype software of the commercial device (Segmentation Technology; Heidelberg Engineering; Fig. 1B). The following macular segmentations were considered herein: total retina, nerve fiber layer (mRNFL); ganglion cell layer (GCL); inner plexiform layer (IPL); inner nuclear layer (INL); outer plexiform layer (OPL); outer nuclear layer (ONL); and photoreceptors. The sums of all the total inner (mRNFL + GCL + IPL + INL) and total outer (OPL + ONL + photoreceptors) retinal layers were also calculated for this study. OPL and ONL layers were not considered independently to avoid automatic segmentation errors due to Henle's fiber orientation.¹⁶ Thus, the thicknesses of these two layers were considered together (OPL + ONL). The mean thickness values of the nine resulting sectors (C0, S1, S2, N1, N2, T1, T2, I1, I2) of the ETDRS grid were averaged and this value was considered to be the macular thickness for each

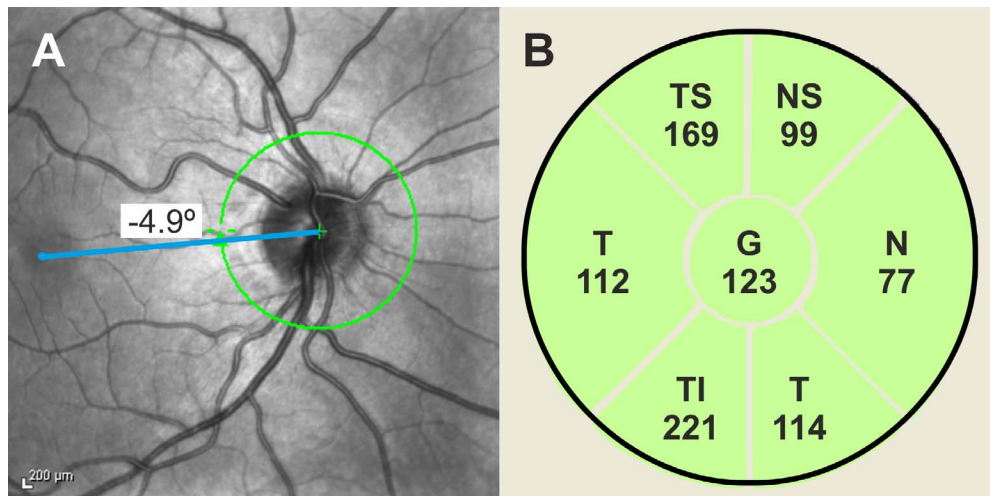


FIGURE 2. Peripapillary examination. (A) Thickness of the RNFL layer is automatically estimated in a 12° in diameter circle (white circle) around the optic disc, divided in sectors. Fovea-to-disc line is represented (blue line). (B) Representation of the different sectors obtained from the device. The sectors are: T, TS, TI, N, NS, and NI. Global (G) values represent the mean thickness of all the sectors. The numbers indicate the mean values of the thickness in microns for each sector.

segmentation. The inner 1-mm diameter circle (C0) thickness was considered the foveal thickness (Fig. 1A).

In the pRNFL thickness scan, the thickness of the pRNFL was automatically estimated in a 12° in diameter circle around the optic disc. Fovea-to-disc adjustment (FoDI system) was used in all eyes. With this strategy, the reference line of the papillomacular bundle was delineated (Fig. 2A) if the patient had a foveal fixation. This line is considered to lie in the middle of the temporal quadrant and, with this reference, all the other sectors were determined by the device. If the subject was unable to maintain foveal fixation as a result of poor collaboration, the foveal position of the axis could be changed.¹⁷ In this study the foveal position of all the examinations was assessed, and corrected, if necessary, by the same experienced operator (JJGM).

The thickness of pRNFL was determined globally and in six different sectors: temporal; temporal superior (TS); temporal inferior (TI); nasal; nasal superior (NS); and nasal inferior (NI) (Fig. 2B). The superior and inferior quadrant values were also calculated by averaging the TS-NS and TI-NI sectors, respectively.

Poor quality images (signal strength under 20) were not included. All the scans were checked by the same experienced operator (JJGM) to exclude any images with segmentation errors, decentrations of the macular ETDRS grid or the pRNFL circle, or any other artifacts. Scans were repeated in such cases.

Cognitive Abilities Assessment

All the ASD subjects underwent the Kaufman brief intelligence test (K-BIT) by the same experienced psychologist (ABRH). This was a quick test that makes a reliable intelligence assessment in persons aged between 4 and 90 years.¹⁸ The test was made up of two subtests: a nonverbal (matrices) and a verbal subtest. The nonverbal subtest consisted of items that contain pictures and abstract symbols, rather than words, and measured the ability to solve problems through relationships and analogies. The verbal subtest is a questionnaire that determined knowledge of words and their meanings. The K-BIT test provided three intelligence quotient (IQ) scores: nonverbal, verbal, and composite IQ. These three scores had a mean of 100 points and a standard deviation of 15 in the normal population. Nonverbal IQ-verbal IQ discrepancy

(NVIQ-VIQD), calculated as the nonverbal score minus the verbal score, was considered for the analysis in this study because it has been suggested that the nonverbal IQ is generally higher than the verbal IQ in ASD, although this fact has not been universally observed.^{19,20}

Head Circumference Measurements

All ASD individuals underwent head circumference measurement. Measurements were taken by the same operator with an inextensible and flexible tape around the widest circumference of the head (above the eyebrow to the most prominent part of the occipital bone). Three measurements were taken and the largest value was considered for each patient.

Sample Size Calculation

To detect a difference of at least $5 \mu\text{m}$ (threshold of SD-OCT technology)²¹ in the global RNFL thickness between groups, and by assuming a standard deviation of $6.2 \mu\text{m}$,¹⁴ for a statistical power of 80% and a significance level of 5% at least 24 patients in each group had to be included.

Statistical Analysis

Data were exported from the OCT device (Heidelberg Engineering) in a spreadsheet program (Excel version 2016; Microsoft Corp., Redmond, WA, USA) and were analyzed with commercial software (SPSS version 22.0; SPSS, Inc., Chicago, IL, USA) and R statistical software (version 3.3.1, The R Foundation for Statistical Computing, Vienna, Austria). The values of the right and the left eyes of each participant and for each concrete location were averaged.

The normality of all the data distributions was assessed by inspecting histograms and using a Shapiro-Wilks test. An unpaired Student's *t*-test was used to compare the foveal, macular, and peripapillary thicknesses between both groups. The Benjamini-Hochberg method was used to adjust the results for multiple comparisons.²²

OCT thickness parameters were chosen to be correlated with the K-BIT results and head circumference, but only if they accomplished two criteria: (1) a statistically significant difference for the Student's *t*-test between the ASD and NT

TABLE 1. Comparisons of Foveal Measurements

Segmented Layer	ASD Subjects, mean ± SD	NT subjects, mean ± SD	Difference of Means, ASD-NT (% change)	Independent T-Test, P-Value
Total retina	279.16 ± 20.57	268 ± 17.84	11.16 (4.16)	<0.01*
Total inner retina	191.98 ± 19.96	181.07 ± 18.51	10.91 (6.02)	<0.01*
RFNL	13 ± 2.08	12.22 ± 1.59	0.78 (6.38)	0.06
Ganglion cell	19.09 ± 5.08	17 ± 4.18	2.09 (12.29)	0.07
Inner plexiform	23.09 ± 3.63	21.50 ± 3.33	1.59 (7.39)	0.04**
Inner nuclear	20.75 ± 5.07	18.37 ± 5.03	2.38 (12.95)	0.03**
Total outer retina	219.96 ± 9.90	217.01 ± 9.62	2.94 (1.35)	0.09
Outer plexiform + nuclear	117.18 ± 9.50	114.11 ± 9.49	3.07 (2.69)	0.11
Photoreceptors	71.29 ± 2.78	71.09 ± 2.76	0.20 (0.28)	0.26

* Significance at the 0.01 level. Significance after Benjamini-Hochberg adjustment is indicated in bold.

** Significance at the 0.05 level.

groups; (2) this difference is greater than 5 µm, which is the threshold of SD-OCT technology.²¹ Exceptionally, correlations with the global pRNFL thickness were also obtained to compare our results with the results by Emberti Gialloreti¹⁴ (see below). Spearman’s correlations were calculated between these selected thickness parameters, the cognitive parameters and head circumference in the ASD group.

Data were expressed as mean ± SD. A P value less than 0.05 was considered statistically significant.

RESULTS

Initially, 32 ASD subjects were selected for the study, but 5 were excluded due to poor collaboration for SD-OCT. Finally, 27 ASD subjects and then 27 age- and sex-matched NT controls were included. Each group was made up of 23 men and 4 women, whose mean age was 13.70 ± 3.03 (range: 7-20 years). Thus, 54 eyes from each group (108 eyes in all) were included for the analysis.

The comparisons showed greater foveal thickness of the total retina, total inner retina, IPL, and INL in the ASD group (Table 1). In contrast, macular thicknesses only statistically differed between both groups at the total retina and total inner retina layers (Table 2). When comparing the pRNFL results, the TI, NI, and inferior sectors appeared to be significantly thicker in the ASD group than in the NT group (Table 3). The general trends toward thicker segmentations in the foveal, macular, and pRNFL thicknesses in the ASD group compared to the NT controls were remarkable (Tables 1-3).

The K-BIT scores in the ASD group were 85.88 ± 21.04 (range: 46-123) for the nonverbal IQ, 79.92 ± 20.92 (range: 40-112) for the verbal IQ, 78.70 ± 21.93 (range: 40-115) for the composite IQ and 5.96 ± 13.13 (range: -30 to 35) for the

NVIQ-VIQ D. The correlations of the selected thickness parameters and the K-BIT obtained in the ASD group demonstrated a moderate positive association between the TI sector of pRNFL and three IQs: nonverbal, verbal, and composite IQ (Table 4). The inferior pRNFL also showed a positive association with the composite IQ, which came close to statistical significance for the nonverbal and verbal IQs (Table 4). Scatterplots of the significant correlations were represented in Figure 3.

Head circumference in ASD group was 56.48 ± 3.31 cm (range: 52-66 cm). There were no significant correlations between head circumference and the selected thickness parameters measured by OCT (Table 4).

DISCUSSION

The present research is the first to investigate macular and foveal thicknesses in combination with pRNFL thicknesses in the ASD individuals. We documented a general trend toward thicker foveal, macular, and peripapillary parameters in ASD subjects with significant differences only at some locations, unlike the effect that neurodegenerative diseases have on retinal structures.¹⁰⁻¹³ The pRNFL, the paradigm of white matter in the retina, was significantly thicker in the inferior sectors in the ASD group. However, the layers that represent gray matter did not seem to present this disparity (except for the foveal INL). The behavior of the inner retinal layers (altered in ASD) also differed from the outer retinal layers at the fovea.

Our results contrasted with those obtained by Emberti Gialloreti et al.,¹⁴ who performed the only research that has compared pRNFL between ASD and NTs published to date. Briefly, these authors concluded that young ASD adults (n = 24) presented lower nasal pRNFL thickness values than the

TABLE 2. Comparisons of Macular Measurements

Segmented Layer	ASD Subjects, mean ± SD	NT Subjects, mean ± SD	Difference of Means, ASD-NT (% change)	Independent T-Test, P-Value
Total retina	320.02 ± 11.98	315.48 ± 10.57	4.54 (1.43)	0.04*
Total inner retina	239.77 ± 10.43	235.35 ± 11.46	4.42 (1.87)	0.04*
RFNL	26.25 ± 2.22	26.42 ± 2.61	-0.17 (0.64)	0.82
Ganglion cell	42.25 ± 2.92	41.25 ± 4.30	1 (2.42)	0.20
Inner plexiform	34.85 ± 1.77	34.42 ± 1.76	0.43 (1.24)	0.26
Inner nuclear	36.66 ± 2.63	35.84 ± 2.41	0.81 (2.26)	0.09
Total outer retina	192.22 ± 7.98	190.48 ± 9.02	0.81 (0.42)	0.19
Outer plexiform + nuclear	98.47 ± 6.23	96.48 ± 7.13	1.99 (2.06)	0.12
Photoreceptors	67.22 ± 1.02	67.22 ± 1.19	0 (0)	0.70

* Significance at the 0.05 level.

TABLE 3. Comparisons of pRNFL Measurements

Location	ASD Subjects, mean ± SD	NT Subjects, mean ± SD	Difference of Means, ASD-NT (% change)	Independent T-Test, P-Value
Global	104.13 ± 11.29	100.38 ± 11.31	3.74 (3.72)	0.09
Temporal	75.81 ± 11.76	73.88 ± 13.45	1.92 (2.59)	0.45
Temporal Superior	146.35 ± 22.21	143.63 ± 24.59	2.72 (1.89)	0.58
Temporal Inferior	152.00 ± 25.19	140.70 ± 26.46	11.29 (8.02)	0.03*
Nasal	73.85 ± 15.21	75.24 ± 12.02	-0.38 (1.83)	0.63
Nasal Superior	118.83 ± 24.58	114.24 ± 16.13	4.59 (4.01)	0.29
Nasal Inferior	115.92 ± 22.11	104.55 ± 22.50	11.37 (10.87)	0.01*
Superior	132.59 ± 21.32	128.94 ± 17.95	3.65 (2.83)	0.36
Inferior	133.76 ± 19.36	121.46 ± 19.09	12.3 (10.12)	<0.01**

* Significance at the 0.05 level.

** Significance at the 0.01 level. Significance after Benjamini-Hochberg adjustment is indicated in bold.

matched NT subjects. They also divided the ASD subjects into two subcategories: high-functioning autism (HFA; $n = 11$) and Asperger syndrome (AS; $n = 13$). They found thinner global, nasal, and inferior pRNFL in the HFA group and thinner nasal pRNFL in the AS compared to the controls. Our study considered all the ASD patients since *DSM-5* merged all the subcategories into one: ASD. No clinical or research evidence exists for separating AS from ASD.¹⁵

The differences between the results of Emberti Gialloreti¹⁴ et al. and ours may be related, at least in part, to one important methodologic reason. They used the Spectralis OCT software, version 5.1, while we used version 6.0. Thus their version did not include fovea-to-disc adjustment (the FoDI system is available from software version 5.3). This is relevant because this correction reduces variability due to the individual disc-fovea angle, cyclotorsion, and patient head tilt so that scans can be accurately compared point-by-point with the normative database or between individuals. It has been demonstrated that fovea-to-disc misalignment was capable of erroneously changing pRNFL thickness measurements in each sector by as much as 46 μm .¹⁷ This fact is particularly important when considering that the collaboration of ASD subjects for OCT can be suboptimal.

We found in this study that ASD individuals presented greater thickness of some intraretinal layers. This result was consistent with the results of other studies that had shown increased thickness or volume in ASD of different structures of the visual pathway such as the thalamus^{23,24} and visual cortex.^{25,26} More recently, larger relative gray matter volume in the visual network in ASD subjects than in controls has been found.²⁷

The cause of the increased retinal thicknesses in ASD shown in this study could be due to atypical parenchyma overgrowth,²⁸ but could also be related to neuroinflammatory changes in ASD, such as microglia activation.²⁹

Neuroinflammation is also believed to play an important role in schizophrenia,²⁹ but in contrast, the macular and peripapillary thicknesses were found to be reduced in this disorder.¹³ Considering that ASD and schizophrenia share some clinical and genetic components, although age of onset in each disorder is different, some other different factors must be involved in the development of these two alterations.²⁹

One of these factors could be that ASD subjects may present an altered programmed cell death (i.e., altered physiologic apoptosis) of the brain and the retina during development, which could lead to neuroanatomic abnormalities.³⁰⁻³² This fact is thought to be related with an early enlargement of the brain and increase in head circumference in ASD individuals in relation to NT controls between the ages of 2 and 4 years that persists between the ages of 5 and 6 years, after which no significant difference is detected.⁶ We did not find any significant correlation between head circumference and selected retinal thicknesses in ASD subjects. To the best of our knowledge, this is the first study dealing with these associations in ASD. It should be taken into account that the ages of the patients in our sample ranged from 7 to 20 years and that this study is cross-sectional. Future longitudinal studies are necessary to better know the relationship between several biometric parameters, including head circumference, and retinal thicknesses in ASD.

Another question that arises is whether these structural differences between ASD individuals and NT controls may be related to the atypical visual function in autism.³³ On the one hand, ASD subjects exhibited superior performance during static visual tasks,³⁴⁻³⁶ but ASD individuals showed inferior performance during dynamic visual tasks.³⁷ It has also been demonstrated recently that the visual field was narrower in ASD patients than in NT controls³⁸ and that ASD subjects presented atypical electroretinograms.³⁹ Further studies are

TABLE 4. Spearman's Rho Correlations Between Selected Thickness Parameters (microns), K-BIT Results, and Head Circumference (cm) in ASD

Segmented Layer	Location	Nonverbal IQ	Verbal IQ	Discrepancy Performance/Verbal IQ	Composite IQ	Head Circumference
Total retina	Fovea	-0.23 (0.24)	-0.14 (0.48)	-0.12 (0.52)	-0.14 (0.46)	0.11 (0.58)
Total inner retina	Fovea	-0.24 (0.22)	-0.15 (0.45)	-0.13 (0.50)	-0.13 (0.50)	0.13 (0.51)
Peripapillary RNFL	Global	0.26 (0.17)	0.22 (0.26)	0.07 (0.70)	0.27 (0.16)	0.29 (0.88)
Peripapillary RNFL	Temporal inferior	0.50 (<0.01)**	0.55 (<0.01)**	-0.07 (0.70)	0.58 (<0.01)**	0.21 (0.29)
Peripapillary RNFL	Nasal inferior	0.12 (0.55)	0.15 (0.45)	0.28 (0.89)	0.18 (0.37)	-0.14 (0.47)
Peripapillary RNFL	Inferior	0.34 (0.07)	0.36 (0.06)	-0.31 (0.87)	0.40 (0.03)*	0.34 (0.86)

Expressed as correlation coefficient (ρ).

* Significance at the 0.05 level.

** Significance at the 0.01 level.

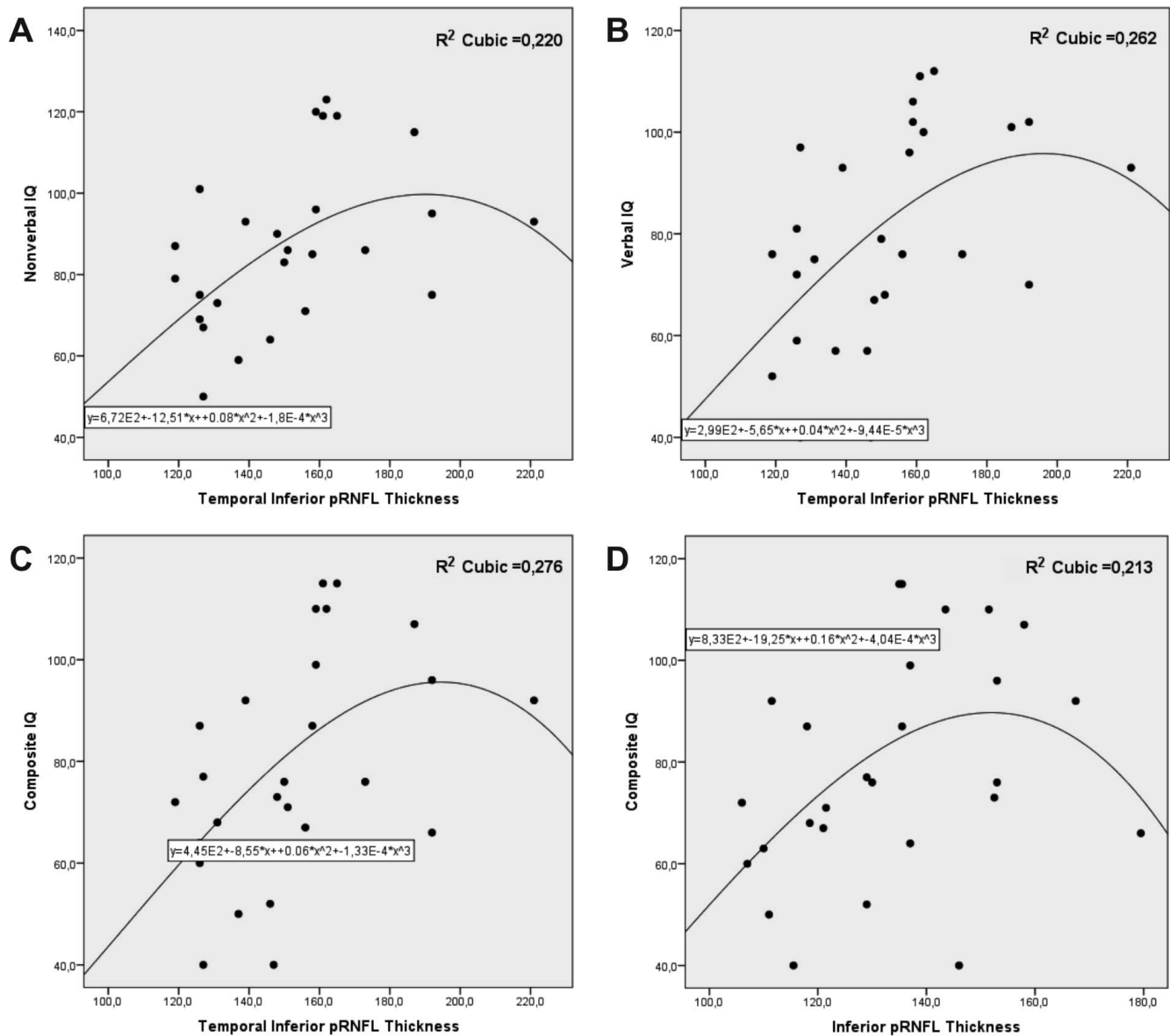


FIGURE 3. Scatterplots representing significant associations between pRNFL thicknesses and K-BIT results in ASD group. (A) Temporal inferior pRNFL thickness versus nonverbal IQ. (B) TI pRNFL thickness versus verbal IQ. (C) TI pRNFL thickness versus composite IQ. (D) Inferior peripapillary RNFL thickness versus composite IQ. Thickness is indicated in microns. Cubic regression best fit the sets of data. R^2 values and regression equations are included.

needed to explore whether these functional differences are related to the structural differences.

The differences found in this work also suggest that the normative database of SD-OCT for NT subjects may not be exactly applicable to ASD subjects. Thus, the interpretation of SD-OCT results in ASD individuals should be cautious when studying or suspecting another ocular or neuro-ophthalmic disease (such as glaucoma, papilledema, optic disk drusen, etc.) in order not to draw false positive or negative conclusions. This fact is especially remarkable for inferior pRNFL sectors because the mean thickenings in ASD subjects at these locations were 11.29, 11.37, and 12.30 μm for temporal inferior, nasal inferior, and inferior sectors, respectively (Table 3).

One may argue that adjustments for multiple comparisons should be applied in this study. This is a controversial issue⁴⁰ because the risk of false-negative results increases. However, even after Benjamini-Hochberg adjustment,²² thickness of total

retina and total inner layer at the fovea, and thickness of inferior pRNFL remained statistically greater in ASD group (Tables 1–3).

A positive association between pRNFL thickness and the scores of cognitive tests has been found in NT individuals by some authors.^{41,42} Additionally, Emberti Gialloreti et al.¹⁴ found a positive correlation between NVIQ-VIQ D and global pRNFL thickness in ASD. We were unable to reproduce this association in the present study. Instead, we found positive correlations, but only moderate ones, between inferior pRNFL thicknesses and IQs. These findings suggest that the relationship of pRNFL and cognitive abilities in ASD may be of clinical applicability.

Our study has some limitations. First, the number of individuals included is relatively small. However, we obtained significant results with this sample size. Second, our ASD group was made up of young, high-functioning ASD subjects. So extrapolating the results cannot be done to another age range

or to low-functioning ASD individuals. Third, our study is cross-sectional and consequently we cannot establish whether the differences between the ASD and NT groups will be stable or change over time. Longitudinal studies are warranted to answer this question.

In conclusion, we found greater retinal thickness in ASD subjects than in the NT controls at some foveal, macular, and peripapillary locations as measured by SD-OCT. This fact should be taken into account when interpreting SD-OCT examinations in ASD subjects. Significant positive associations between pRNFL thicknesses and cognitive scores were found. Considering that SD-OCT is a noninvasive, quick and affordable examination, our results suggest that this in vivo diagnosis technique may be promising to study different aspects of ASD such as cognitive status.

Acknowledgments

This work is derived from a poster presented at the American Academy of Ophthalmology Annual Meeting, 2016 (Chicago, IL, USA), and developed by members of the RETICS RD16-0008 "Prevention, Early Detection, and Treatment of the Prevalent Degenerative and Chronic Ocular Pathology" from the Instituto de Salud Carlos III from the Ministerio de Economía, Industria y Competitividad, Spain.

The authors thank Guadalupe Ruiz-Merino (from the Department of Statistics, FFIS-IMIB, Murcia, Spain) for her statistical support in this study, and Jose Manuel Tamarit (from Heidelberg Engineering) for his technical support with SD-OCT.

Supported in part by the PN I+D+i 2008–2011, the ISCIII-Subdirección General de Redes y Centros de Investigación Cooperativa, and the European Regional Development Fund (FEDER).

Disclosure: **J.J. García-Medina**, None; **M. García-Piñero**, None; **M. del-Río-Vellosillo**, None; **J. Fares-Valdivia**, None; **A.B. Ragel-Hernández**, None; **S. Martínez-Saura**, None; **M.D. Cárcel-López**, None; **V. Zanon-Moreno**, None; **M.D. Pinazo-Duran**, None; **M.P. Villegas-Pérez**, None

References

- Wing L. The autistic spectrum. *Lancet*. 1997;350:1761-1766.
- Baird G, Simonoff E, Pickles A, et al. Prevalence of disorders of the autism spectrum in a population cohort of children in South Thames: the Special Needs and Autism Project (SNAP). *Lancet*. 2006;368:210-215.
- Murphy CM, Wilson CE, Robertson DM, et al. Autism spectrum disorder in adults: diagnosis, management, and health services development. *Neuropsychiatr Dis Treat*. 2016;12:1669-1686.
- Christensen DL, Baio J, Van Naarden Braun K, et al. Prevalence and characteristics of autism spectrum disorder among children aged 8 years—Autism and Developmental Disabilities Monitoring Network, 11 Sites, United States, 2012. *MMWR Surveill Summ*. 2016;65:1-23.
- Ecker C, Bookheimer SY, Murphy DG. Neuroimaging in autism spectrum disorder: brain structure and function across the lifespan. *Lancet Neurol*. 2015;14:1121-1134.
- Ecker C. The neuroanatomy of autism spectrum disorder: An overview of structural neuroimaging findings and their translatability to the clinical setting. *Autism*. 2017;21:18-28.
- Ecker C, Andrews D, Dell'Acqua F, et al. Relationship between cortical gyrification, white matter connectivity, and autism spectrum disorder. *Cereb Cortex*. 2016;26:3297-3309.
- Yanoff M, Sassani JW. Neural (sensory) retina. In: Yanoff M, Sassani JW, eds. *Ocular Pathology*. 7th ed. London: Saunders, 2015:351-425.
- Gupta S, Zivadinov R, Ramanathan M, Weinstock-Guttman B. Optical coherence tomography and neurodegeneration: are eyes the windows to the brain? *Expert Rev Neurother*. 2016;16:765-775.
- García-Martin E, Larrosa JM, Polo V, et al. Distribution of retinal layer atrophy in patients with Parkinson disease and association with disease severity and duration. *Am J Ophthalmol*. 2014;157:470-478.
- García-Martin E, Bambo MP, Marques ML, et al. Ganglion cell layer measurements correlate with disease severity in patients with Alzheimer's disease. *Acta Ophthalmol*. 2016;94:e454-e459.
- Martínez-Lapiscina EH, Arnow S, Wilson JA, et al. Retinal thickness measured with optical coherence tomography and risk of disability worsening in multiple sclerosis: a cohort study. *Lancet Neurol*. 2016;15:574-584.
- Lee WW, Tajunisah I, Sharmilla K, Peyman M, Subrayan V. Retinal nerve fiber layer structure abnormalities in schizophrenia and its relationship to disease state: evidence from optical coherence tomography. *Invest Ophthalmol Vis Sci*. 2013;54:7785-7792.
- Emberti Gialloreti L, Pardini M, Benassi F, et al. Reduction in retinal nerve fiber layer thickness in young adults with autism spectrum disorders. *J Autism Dev Disord*. 2014;44:873-882.
- American Psychiatric Association. *Diagnostic and Statistical Manual of Mental Disorders (DSM-5)*. Washington, DC: American Psychiatric Association; 2013:1-991.
- Lujan BJ, Roorda A, Croskrey JA, et al. Directional optical coherence tomography provides accurate outer nuclear layer and Henle fiber layer measurements. *Retina*. 2015;35:1511-1520.
- Valverde-Megías A, Martínez-de-la-Casa JM, Serrador-García M, Larrosa JM, García-Feijoo J. Clinical relevance of foveal location on retinal nerve fiber layer thickness using the new FoDi software in Spectralis optical coherence tomography. *Invest Ophthalmol Vis Sci*. 2013;54:5771-5776.
- Kaufman AS, Kaufman NL. *Kaufman Brief Intelligence Test (KBIT) Manual*. Spanish Adaption. Cordero A, Calonge I, eds. 2nd ed. Madrid: Tea Ediciones; 2000:1-100.
- Chapman NH, Estes A, Munson J, et al. Genome-scan for IQ discrepancy in autism: evidence for loci on chromosomes 10 and 16. *Human Genetics*. 2011;129:59-70.
- Ankenman K, Elgin J, Sullivan K, Vincent L, Bernier R. Nonverbal and verbal cognitive discrepancy profiles in autism spectrum disorders: influence of age and gender. *Am J Intellect Dev Disabil*. 2014;119:84-99.
- Adhi M, Duker JS. Optical coherence tomography—current and future applications. *Curr Opin Ophthalmol*. 2013;24:213-221.
- Benjamini Y, Hochberg Y. Controlling the false discovery rate: a practical and powerful approach in multiple testing. *J R Stat Soc Series B Stat Methodol*. 1995;57:289-300.
- Ecker C, Suckling J, Deoni SC, et al. Brain anatomy and its relationship to behavior in adults with autism spectrum disorder: a multicenter magnetic resonance imaging study. *Arch Gen Psychiatry*. 2012;69:195-209.
- Lin HY, Ni HC, Lai MC, Tseng WY, Gau SS. Regional brain volume differences between males with and without autism spectrum disorder are highly age-dependent. *Mol Autism*. 2015;216:29.
- Hyde KL, Samson F, Evans AC, Mottron L. Neuroanatomical differences in brain areas implicated in perceptual and other core features of autism revealed by cortical thickness analysis and voxel-based morphometry. *Hum Brain Mapp*. 2010;31:556-566.
- Nickl-Jockschat T, Habel U, Michel TM, et al. Brain structure anomalies in autism spectrum disorder—a meta-analysis of

- VBM studies using anatomic likelihood estimation. *Hum Brain Mapp.* 2012;33:1470-1489.
27. Watanabe T, Rees G. Anatomical imbalance between cortical networks in autism. *Sci Rep.* 2016;6:31114.
 28. Bigler ED, Abildskov TJ, Petrie JA, et al. Volumetric and voxel-based morphometry findings in autism subjects with and without macrocephaly. *Dev Neuropsychol.* 2010;35:278-295.
 29. Nakagawa Y, Chiba K. Involvement of neuroinflammation during brain development in social cognitive deficits in autism spectrum disorder and schizophrenia. *J Pharmacol Exp Ther.* 2016;358:504-515.
 30. Vecino E, Hernández M, García M. Cell death in the developing vertebrate retina. *Int J Dev Biol.* 2004;48:965-974.
 31. Valenciano AI, Boya P, de la Rosa EJ. Early neural cell death: numbers and cues from the developing neuroretina. *Int J Dev Biol.* 2009;53:1515-1528.
 32. Wei H, Alberts I, Li X. The apoptotic perspective of autism. *Int J Dev Neurosci.* 2014;36:13-18.
 33. Bakroon A, Lakshminarayanan V. Visual function in autism spectrum disorders: a critical review. *Clin Exp Optom.* 2016;99:297-308.
 34. Dakin S, Frith U. Vagaries of visual perception in autism. *Neuron.* 2005;48:497-507.
 35. Simmons DR, Robertson AE, McKay LS, Toal E, McAleer P, Pollick FE. Vision in autism spectrum disorders. *Vis Res.* 2009;49:2705-2739.
 36. Samson F, Mottron L, Soulières I, Zeffiro TA. Enhanced visual functioning in autism: an ALE meta-analysis. *Hum Brain Mapp.* 2012;33:1553-1581.
 37. Grinter EJ, Maybery MT, Badcock DR. Vision in developmental disorders: is there a dorsal stream deficit? *Brain Res Bull.* 2010;82:147-160.
 38. Song Y, Hakoda Y, Sanefuji W, Cheng C. Can they see it? The functional field of view is narrower in individuals with autism spectrum disorder. *PLoS One.* 2015;10:e0133237.
 39. Constable PA, Gaigg SB, Bowler DM, Jägle H, Thompson DA. Full-field electroretinogram in autism spectrum disorder. *Doc Ophthalmol.* 2016;132:83-99.
 40. Rothman KJ. No adjustments are needed for multiple comparisons. *Epidemiology.* 1990;1:43-46.
 41. van Koolwijk LME, Despriet DDG, Van Duijn CM, et al. Association of cognitive functioning with retinal nerve fiber layer thickness. *Invest Ophthalmol Vis Sci.* 2009;50:4576-4580.
 42. Khawaja AP, Chan MP, Yip JL, et al. Retinal nerve fiber layer measures and cognitive function in the EPIC-Norfolk Cohort Study. *Invest Ophthalmol Vis Sci.* 2016;57:1921-1926.