

# Evaluation of Retinal Nerve Fiber Layer Thinning in Myopic Glaucoma: Impact of Optic Disc Morphology

Kyeong Ik Na,<sup>1</sup> Won June Lee,<sup>2</sup> Young Kook Kim,<sup>2</sup> Ki Ho Park,<sup>2</sup> and Jin Wook Jeoung<sup>2</sup>

<sup>1</sup>Department of Ophthalmology, Kangdong Sacred Heart Hospital, Hallym University College of Medicine, Seoul, Korea

<sup>2</sup>Department of Ophthalmology, Seoul National University Hospital, Seoul National University College of Medicine, Seoul, Korea

Correspondence: Jin Wook Jeoung, Department of Ophthalmology, Seoul National University Hospital, Seoul National University College of Medicine, 101 Daehak-ro, Jongno-gu, Seoul 110-744, Korea; neuroprotect@gmail.com.

Submitted: July 2, 2017

Accepted: November 9, 2017

Citation: Na KI, Lee WJ, Kim YK, Park KH, Jeoung JW. Evaluation of retinal nerve fiber layer thinning in myopic glaucoma: impact of optic disc morphology. *Invest Ophthalmol Vis Sci.* 2017;58:6265–6272. DOI:10.1167/iov.17-22534

**PURPOSE.** The purpose of this study was to investigate the role of optic disc torsion on the rate of progressive retinal nerve fiber layer (RNFL) thinning in patients with myopic open-angle glaucoma.

**METHODS.** We included 102 patients with myopic open-angle glaucoma accompanied by glaucomatous damage confined to a single hemiretina who were followed up over a 5-year period. We divided the subjects into three groups according to the presence or absence of optic disc torsion and the correspondence between the direction of optic disc torsion and the location of glaucomatous damage: torsion with reverse correspondence group (eyes showing inferior optic disc torsion with glaucomatous damage in the superior quadrant or eyes showing superior torsion with damage in the inferior quadrant), no torsion group, and torsion with correspondence group (eyes showing inferior optic disc torsion with glaucomatous damage in the inferior quadrant or eyes showing superior torsion with damage in the superior quadrant). Changes in the peripapillary RNFL thickness (pRNFLT), evaluated using linear mixed model analysis, were compared among the three groups to determine the relationship between optic disc torsion and pRNFLT changes.

**RESULTS.** Among the total of 102 subjects, 13 eyes (12.7%) exhibited optic disc torsion with reverse correspondence, 59 (57.8%) did not exhibit optic disc torsion, and 30 (29.4%) exhibited optic disc torsion with correspondence. pRNFLT thinning in the quadrant with glaucomatous damage was significantly faster in the torsion with correspondence group ( $-1.66 \mu\text{m}/\text{y}$ ) than those in the no torsion ( $-1.14 \mu\text{m}/\text{y}$ ;  $P = 0.032$ ) and torsion with reverse correspondence ( $-0.50 \mu\text{m}/\text{y}$ ;  $P < 0.001$ ) groups.

**CONCLUSIONS.** Our results suggest that the optic disc torsion–glaucomatous damage correspondence is an important prognostic factor for patients with myopic open-angle glaucoma.

**Keywords:** myopic open-angle glaucoma, optic disc torsion, retinal nerve fiber layer

Several studies, including population-based studies, have demonstrated a relatively high prevalence of glaucoma in patients with myopia. However, despite a well-known epidemiologic relationship between myopia and open-angle glaucoma, the underlying mechanisms related to glaucomatous damage in patients with myopia remain unclear.<sup>1–12</sup>

In patients with myopia, the optic disc undergoes morphologic changes such as torsion, tilt, and peripapillary atrophy.<sup>13–15</sup> Of late, the morphologic features of the optic disc have been considered potential causes for the high prevalence of glaucoma in patients with myopia.<sup>16–22</sup> Among these, optic disc torsion has garnered increased attention in the glaucoma community, because it can be associated with the location of the glaucomatous damage and visual field (VF) defects in patients with myopic open-angle glaucoma.<sup>18–20</sup>

In optic disc torsion, the optic disc appears to be elliptical and rotated about the sagittal plane. It is a common ocular condition found in myopic eyes. Although the exact mechanism underlying the onset of optic disc torsion remains controversial, it has been suggested that asymmetrical posterior sclera expansion in either the superior or inferior region relative to the optic disc may result in superior or inferior disc

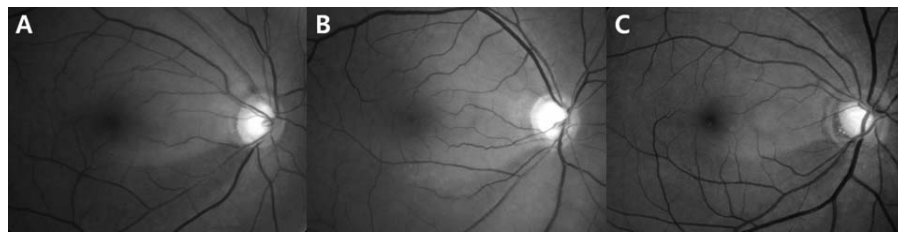
torsion during the course of myopia development.<sup>18,19,23–26</sup> Several mechanisms have been suggested for the association between optic disc torsion and glaucomatous damage.<sup>14,18,19,25,24,27</sup> For example, inferior torsion could place stress on the inferior nerve axons, resulting in inferior retinal nerve fiber layer (RNFL) damage that presents with superior VF defects.<sup>14,18,19,27</sup>

Although the glaucomatous damage occurring as a consequence of optic disc torsion has been documented in cross-sectional studies, the mechanism by which optic disc torsion can affect the progression of glaucoma has been not well investigated. Accordingly, we conducted the present study to investigate the effects of optic disc torsion on the rate of progressive RNFL thinning in patients with myopic open-angle glaucoma.

## METHODS

This study was approved by the Institutional Review Board of Seoul National University Hospital, and informed consent was obtained from all patients. The study design followed the tenets of the Declaration of Helsinki for biomedical research.





**FIGURE 1.** Red-free fundus photographs showing an inferotemporal wedge-shaped retinal nerve fiber layer defect with (A) optic disc torsion with reverse correspondence, (B) no optic disc torsion, and (C) optic disc torsion with correspondence.

## Subjects

We consecutively recruited patients with open-angle glaucoma and myopia who visited the glaucoma clinic at Seoul National University Hospital (Seoul, Korea) from January 2009 to December 2009.

At baseline, each subject underwent ophthalmologic examinations, including the measurement of best-corrected visual acuity and refraction, slit-lamp biomicroscopy, Goldmann applanation tonometry, gonioscopy, stereoscopic examination of the optic disc, color disc and red-free RNFL photography (TRC-50IX; Topcon Corporation, Tokyo, Japan), Humphrey VF examination using the Swedish interactive threshold algorithm standard 30-2 test (Carl Zeiss Meditec, Dublin, CA, USA), measurement of the corneal thickness (Pocket II Pachymeter Echo graph; Quantel Medical, Clermont-Ferrand, France), axial length (Axis II PR; Quantel Medical), and evaluation of peripapillary RNFL thickness (pRNFLT) using Cirrus optical coherence tomography (OCT) (Carl Zeiss Meditec).

The diagnosis of open-angle glaucoma was based on the presence of glaucomatous optic neuropathy and normal anterior chamber angles on slit-lamp biomicroscopy and gonioscopy. Eyes were diagnosed with glaucomatous VF defects if they met two of the following three criteria as confirmed by more than one reliable test performed after the first VF test: a cluster of three points with a probability of <5% on the pattern deviation map in at least one hemifield, with at least one point with a probability of <1%; a glaucoma hemifield test result outside normal limits; and a pattern standard deviation outside 95% of the normal limits. A reliable VF was defined as that with a false-positive error of <15%, a false-negative error of <15%, and a fixation loss of <20%. A glaucomatous optic nerve head was defined by a vertical cup-to-disc ratio of 0.7, an asymmetry of >0.2 between the vertical cup-to-disc ratios of the two eyes, the presence of focal neural rim notching, or generalized loss of the neural rim on color disc and red-free RNFL photography. Glaucomatous damage was defined as a glaucomatous VF defect consistent with the glaucomatous optic nerve head.

The inclusion criteria for the study were as follows: open-angle glaucoma with glaucomatous damage confined to a single hemiretina; myopia with a spherical equivalent of <−2.00 diopter (D) or an axial length of >24.00 mm; reliable VFs and a mean deviation better than −12.00 dB at baseline; and a pRNFLT of  $\geq 60$   $\mu\text{m}$  in the superior and inferior quadrants with glaucomatous damage, as observed on baseline OCT, to eliminate the floor effect of advanced glaucoma. Patients were excluded on the basis of any of the following criteria: a segmentation error on baseline OCT; a history of any retinal disease, including diabetic or hypertensive retinopathy; a history of eye trauma or surgery, with the exception of uncomplicated cataract surgery; optic nerve diseases other than glaucoma; and a history of systemic or neurologic diseases

that may affect VF. When both eyes of a patient met the inclusion criteria, one eye was randomly selected for evaluation.

We followed-up all participants in an identical manner, usually at 6-month intervals, and performed OCT examinations approximately once a year. IOP was measured at every follow-up visit, and the mean follow-up IOP was calculated by averaging the obtained values. IOP fluctuation was defined as the SD, and the peak follow-up IOP was defined as the highest value among all measurements obtained during the follow-up period.

## Optic Disc Tilt and Torsion

We acquired color disc and red-free RNFL photographs under standard settings using a nonmydriatic retinal camera. Two independent glaucoma specialists (WJL and YKK) measured optic disc tilt and torsion from these photographs using the National Institutes of Health image analysis software (ImageJ version 1.50i; National Institutes of Health, Bethesda, MD, USA; available at <https://imagej.nih.gov/ij/index.html>). We used the average of the values recorded by the two examiners and excluded subjects whose torsion angles measured by the two examiners differed by more than 5°.

Optic disc tilt was identified by the tilt ratio, defined as the ratio between the longest and shortest diameters of the optic disc. Optic disc torsion was identified and defined as the deviation of the long axis of the optic disc from the vertical meridian. The vertical meridian was identified as a vertical line perpendicular to a horizontal line connecting the fovea, which is 2° to 6° below the optic disc, to the center of the optic disc. The degree between the long axis of the optic disc and the vertical meridian was named the torsion degree. A positive torsion degree value indicated inferior torsion, whereas a negative value indicated superior torsion.<sup>14,19,27,28</sup>

We diagnosed optic disc torsion when the torsion degree was  $>+15^\circ$  or  $<-15^\circ$ . On the other hand, we considered optic disc torsion to be absent when the torsion degree was  $>-15^\circ$  and  $<+15^\circ$ . We further divided the optic disc torsion group into two groups according to the correspondence between the direction of torsion and the location of glaucomatous damage: torsion with correspondence group, which included eyes exhibiting inferior optic disc torsion with glaucomatous damage in the inferior quadrant or eyes exhibiting superior torsion with damage in the superior quadrant, and torsion with reverse correspondence group, which included eyes exhibiting inferior optic disc torsion and glaucomatous damage in the superior quadrant or eyes exhibiting superior torsion with damage in the inferior quadrant (Fig. 1).

In each eye with disc torsion, the superior or inferior quadrant located in the direction of torsion was defined as the torsion-affected quadrant, whereas the quadrant opposite to the direction of torsion was defined as the torsion-unaffected quadrant.

**TABLE 1.** Clinical and Demographic Characteristics of Subjects With Myopic Open-Angle Glaucoma

Variables	Description
Patients, no.	102
Age at baseline examination, y	57.17 ± 10.43
Male, no. (%)	65 (63.7)
Systemic factors	
Diabetes mellitus, no. (%)	6 (5.9)
Hypertension, no. (%)	17 (16.7)
Glaucoma	
Normal-tension glaucoma, no. (%)	88 (86.3)
Primary open-angle glaucoma, no. (%)	14 (13.7)
Spherical equivalent refractive error, D	-5.26 ± 2.03
Axial length, mm	25.72 ± 1.06
Central corneal thickness, μm	541.21 ± 35.63
Optic disc torsion	
Optic disc torsion degree, °	-0.76 ± 19.57
Superior optic disc torsion, no. (%) <sup>o</sup>	23 (22.5)/-25.80 ± 1.88
No optic disc torsion, no. (%) <sup>o</sup>	59 (57.8)/-0.54 ± 0.89
Inferior optic disc torsion, no. (%) <sup>o</sup>	20 (19.6)/27.38 ± 3.21
Optic disc torsion with reverse correspondence, no. (%)	13 (12.7)
Optic disc torsion with correspondence, no. (%)	30 (29.4)
Follow-up duration, mo	73.21 ± 12.81
Follow-up OCT, no.	5.80 ± 1.24

## OCT Imaging

We used Cirrus OCT to acquire optic disc scans using the Optic Disc Cube 200 × 200 protocol, which included optic nerve head and RNFL analyses. Cirrus OCT variables included the following: disc area; rim area; average cup-to-disc ratio; vertical cup-to-disc ratio; cup volume; pRNFLT in the superior, nasal, inferior, and temporal quadrants; and the average pRNFLT.

## Statistical Analysis

Clinical and demographic characteristics were compared among the torsion with reverse correspondence group, no torsion group, and torsion with correspondence group using 1-way ANOVA or the Kruskal-Wallis test for continuous variables and the  $\chi^2$  test or Fisher's exact test for categorical variables.

ANOVA or the Kruskal-Wallis test was used to evaluate differences in the baseline pRNFLT among the three groups. A paired *t*-test was used to assess differences in the baseline pRNFLT between the torsion-affected and torsion-unaffected quadrants in each eye in the optic disc torsion group. Student's *t*-test was used to evaluate differences in the baseline pRNFLT in the quadrant with glaucomatous damage between eyes with superior correspondence and those with inferior correspondence in the torsion with correspondence group.

The rate of pRNFLT changes was determined from the serial OCT measurements using linear mixed model analysis. Models were fitted with fixed coefficients (fixed effects) of age, sex, systemic factors (diabetic mellitus, hypertension), type of glaucoma (normal-tension glaucoma and primary open angle glaucoma), spherical equivalent refractive error, axial length, central corneal thickness, follow-up duration (months), baseline optic disc characteristics (disc area, rim area, average cup-to-disc ratio, vertical cup-to-disc ratio, cup volume,  $\beta$ -zone peripapillary atrophy, optic disc tilt ratio), baseline VF mean deviation, baseline VF pattern standard deviation, mean follow-up IOP, IOP fluctuation, peak follow-up IOP, and optic disc hemorrhage, accepting random intercepts and coefficients

(random effects) for all eyes when analyzing the effect of time. The rate of pRNFLT changes was compared among groups through testing of the interaction term in the linear mixed models.

$P < 0.05$  was considered statistically significant. SPSS software for Windows version 21.0.0 (SPSS, Inc., Chicago, IL, USA) was used for all statistical analyses.

## RESULTS

In total, 102 eyes of 102 patients with myopic open-angle glaucoma that met the inclusion and exclusion criteria were included in the present study.

### Clinical and Demographic Characteristics of Participants

Table 1 shows the clinical and demographic characteristics of the study subjects. The mean age was 57.17 ± 10.43 years. In total, there were 65 men and 37 women. The mean spherical equivalent refractive error and axial length were -5.26 ± 2.03 D and 25.72 ± 1.06 mm, respectively. Overall, the mean number of OCT examinations per eye was 5.80 ± 1.24 during a mean follow-up period of 73.21 ± 12.81 months.

Of the 102 eyes, 13 (12.7%), 59 (57.8%), and 30 (29.4%) eyes were included in the torsion with reverse correspondence, no torsion, and torsion with correspondence groups, respectively. The three groups showed no significant differences with regard to the baseline systemic and ocular characteristics, follow-up duration, and number of follow-up OCT images (Table 2).

### Comparison of pRNFLT Changes According to the Presence or Absence of Optic Disc Torsion and the Optic Disc Torsion–Glaucomatous Damage Correspondence

The torsion with reverse correspondence, no torsion, and torsion with correspondence groups exhibited no significant differences with regard to baseline RNFL characteristics. pRNFLT thinning in the quadrant with glaucomatous damage was significantly faster in the torsion with correspondence group (-1.66 μm/y) than those in the no torsion (-1.14 μm/y;  $P = 0.032$ ) and torsion with reverse correspondence (-0.50 μm/y;  $P < 0.001$ ) groups, whereas it was significantly faster in the no torsion group than that in the torsion with reverse correspondence group ( $P = 0.037$ ). Average pRNFLT thinning was significantly faster in the torsion with correspondence group (-0.95 μm/y) than that in the torsion with reverse correspondence group (-0.49 μm/y;  $P = 0.040$ ; Table 3).

Figure 2 illustrates pRNFLT and VF changes in the left eye of a 61-year-old man exhibiting optic disc torsion with reverse correspondence, whereas Figure 3 illustrates pRNFLT and VF changes in the left eye of a 61-year-old man exhibiting optic disc torsion with correspondence.

### Comparison of pRNFLT Changes Between Torsion-Affected and Torsion-Unaffected Quadrants

We compared the rate of pRNFLT changes between the torsion-affected quadrant and torsion-unaffected quadrant in each eye in the torsion group ( $n = 42$ ), without consideration of glaucomatous damage. Table 4 shows that pRNFLT thinning was significantly faster in the torsion-affected quadrant (-1.56 μm/y) than that in the torsion-unaffected quadrant (-0.76 μm/y;  $P = 0.030$ ).

**TABLE 2.** Comparison of Clinical and Demographic Characteristics of Subjects With Myopic Open-Angle Glaucoma According to the Presence or Absence of Optic Disc Torsion and Correspondence Between the Direction of Optic Disc Torsion and the Location of Glaucomatous Damage

Variables	Torsion With Reverse Correspondence	No Torsion	Torsion With Correspondence	P Value
Patients, no.	13	59	30	
Age at baseline examination, y	58.46 ± 6.89	58.05 ± 11.3	54.87 ± 9.61	0.357*
Male, no. (%)	10 (76.9)	35 (59.3)	20 (66.7)	0.452†
Systemic factors				
Diabetes mellitus, no. (%)	0 (0)	5 (8.5)	1 (3.3)	0.585‡
Hypertension, no. (%)	2 (15.4)	9 (15.3)	6 (20.0)	0.865†
Glaucoma				
Normal-tension glaucoma, no. (%)	12 (92.3)	50 (84.7)	26 (86.7)	0.920‡
Primary open-angle glaucoma, no. (%)	1 (7.7)	9 (15.3)	4 (13.3)	0.920‡
Spherical equivalent refractive error, D	-5.65 ± 2.61	-4.97 ± 1.93	-5.65 ± 1.98	0.353*
Axial length, mm	25.47 ± 0.84	25.60 ± 1.10	26.09 ± 1.01	0.152*
Central corneal thickness, μm	545.67 ± 25.47	540.08 ± 37.30	541.43 ± 36.94	0.888*
Follow-up duration, mo	71.69 ± 11.47	75.05 ± 12.37	70.27 ± 13.94	0.227*
Follow-up OCT, no.	5.92 ± 1.32	5.78 ± 1.31	5.80 ± 1.10	0.948§
Baseline optic disc characteristics				
Disc area, mm <sup>2</sup>	1.87 ± 0.51	1.81 ± 0.42	1.82 ± 0.40	0.905*
Rim area, mm <sup>2</sup>	0.94 ± 0.21	0.91 ± 0.21	0.88 ± 0.15	0.786§
Average CDR	0.67 ± 0.10	0.68 ± 0.12	0.71 ± 0.09	0.469§
Vertical CDR	0.68 ± 0.12	0.69 ± 0.12	0.71 ± 0.09	0.806§
Cup volume, mm <sup>3</sup>	0.31 ± 0.19	0.33 ± 0.20	0.42 ± 0.26	0.326§
β-Zone PPA, no. (%)	10 (76.9)	38 (64.4)	26 (86.7)	0.078†
Optic disc tilt ratio	0.81 ± 0.11	0.80 ± 0.10	0.83 ± 0.12	0.421§
Baseline VF examination				
VF MD, dB	-3.05 ± 3.22	-3.74 ± 3.48	-2.77 ± 2.48	0.439§
VF PSD, dB	5.11 ± 3.98	5.75 ± 4.22	4.28 ± 3.06	0.365§
Superior VF defect, no. (%)	10 (76.9)	37 (62.7)	17 (56.7)	0.473†
Inferior VF defect, no. (%)	3 (23.1)	22 (37.3)	13 (43.3)	0.473†
IOP				
Mean follow-up IOP, mm Hg	12.70 ± 1.60	13.04 ± 1.81	13.79 ± 1.97	0.146§
IOP fluctuation, mm Hg	1.30 ± 0.88	1.41 ± 0.55	1.45 ± 0.60	0.267§
Peak follow-up IOP, mm Hg	14.69 ± 2.53	15.17 ± 2.38	16.10 ± 2.72	0.202§
Optic disc hemorrhage, no. (%)	4 (30.8)	15 (25.4)	2 (6.2)	0.073†

CDR, cup-to-disc ratio; PPA, peripapillary atrophy; MD, mean deviation; PSD, pattern SD.

\* One-way ANOVA.

†  $\chi^2$  test.

‡ Fisher's exact test.

§ Kruskal-Wallis test.

**TABLE 3.** Comparison of Changes in Peripapillary RNFL Thickness in Subjects With Myopic Open-Angle Glaucoma According to the Presence or Absence of Optic Disc Torsion and Correspondence Between the Direction of Optic Disc Torsion and the Location of Glaucomatous Damage

Variables	Torsion With Reverse Correspondence	No Torsion	Torsion With Correspondence	P Value
Patients, no.	13	59	30	
Baseline RNFL characteristics				
Average pRNFLT, μm	82.15 ± 6.91	78.07 ± 8.81	78.23 ± 7.51	0.261*
Superior quadrant pRNFLT, μm	104.00 ± 15.85	94.80 ± 14.92	93.90 ± 15.47	0.110*
Inferior quadrant pRNFLT, μm	89.69 ± 21.94	88.05 ± 17.63	87.83 ± 15.98	0.947*
Glaucomatous damaged quadrant pRNFLT, μm	82.92 ± 12.76	81.98 ± 13.75	81.60 ± 12.14	0.890†
Rate of pRNFLT changes‡				
Rate of average pRNFLT changes (μm/y)	-0.49 ( <i>P</i> = 0.007)	-0.70 ( <i>P</i> < 0.001)	-0.95 ( <i>P</i> < 0.001)	0.261§ 0.040   0.082¶
Rate of superior pRNFLT changes (μm/y)	-0.91 ( <i>P</i> = 0.004)	-1.02 ( <i>P</i> < 0.001)	-1.48 ( <i>P</i> < 0.001)	0.662§ 0.189   0.127¶
Rate of inferior pRNFLT changes (μm/y)	-0.83 ( <i>P</i> = 0.001)	-1.20 ( <i>P</i> < 0.001)	-1.16 ( <i>P</i> = 0.004)	0.146§ 0.435   0.996¶
Rate of glaucomatous damaged quadrant pRNFLT changes (μm/y)	-0.50 ( <i>P</i> = 0.142)	-1.14 ( <i>P</i> < 0.001)	-1.66 ( <i>P</i> < 0.001)	0.037§ <0.001   0.032¶

\* One-way ANOVA.

† Kruskal-Wallis test.

‡ Linear mixed model.

§ Linear mixed model, torsion with reverse correspondence group versus no torsion group.

|| Linear mixed model, torsion with reverse correspondence group versus torsion with correspondence group.

¶ Linear mixed model, no torsion group versus torsion with correspondence group.



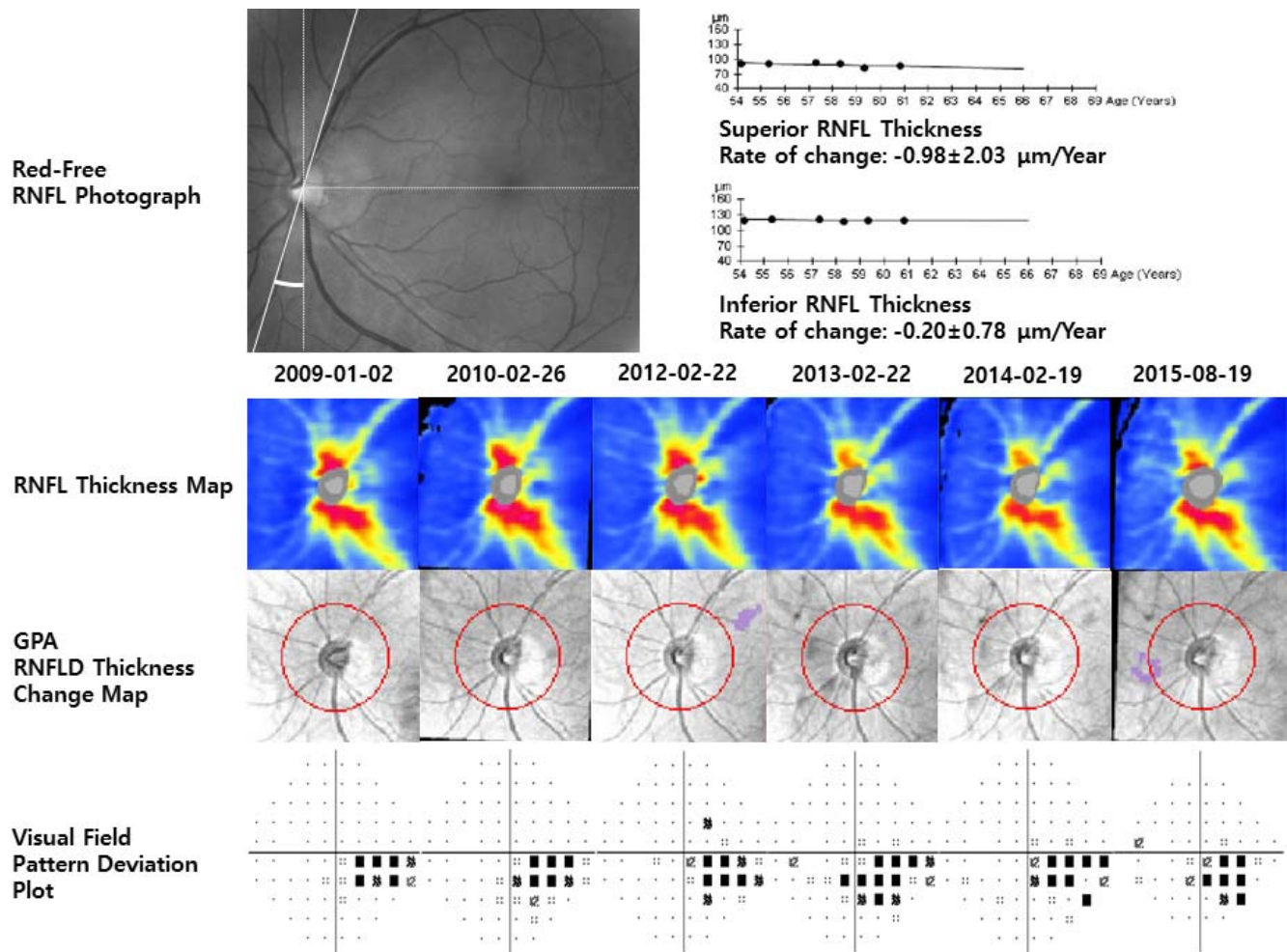


FIGURE 2. Representative case of a 61-year-old man exhibiting inferior optic disc torsion and superior glaucomatous damage (optic disc torsion with reverse correspondence). During baseline examinations (January 2, 2009), a superotemporal wedge-shaped RNFL defect can be detected on a red-free RNFL photograph and an inferonasal visual field defect can be detected on a pattern deviation plot. The optic disc shows inferior torsion; the torsion degree is  $+16.8^\circ$ . Therefore, this case is considered a case of optic disc torsion with reverse correspondence. The rate of peripapillary RNFL thickness changes in the superior quadrant is  $-0.98 \pm 2.03 \mu\text{m}/\text{y}$  analyzed by linear regression, and the RNFL thickness change map shows no red color (likely loss) or orange color (possible loss) during the follow-up period.

**Comparison of pRNFLT Changes Between Eyes With Superior Correspondence and Those With Inferior Correspondence**

We further divided the torsion with correspondence group ( $n = 30$ ) into a superior correspondence group and an inferior correspondence group according to the direction of correspondence between optic disc torsion and glaucomatous damage (Table 5). Thirteen (43.3%) subjects showed superior correspondence and 17 (56.7%) showed inferior correspondence. There were no significant differences in the rate of pRNFLT changes in the quadrant with glaucomatous damage between the superior correspondence and inferior correspondence groups.

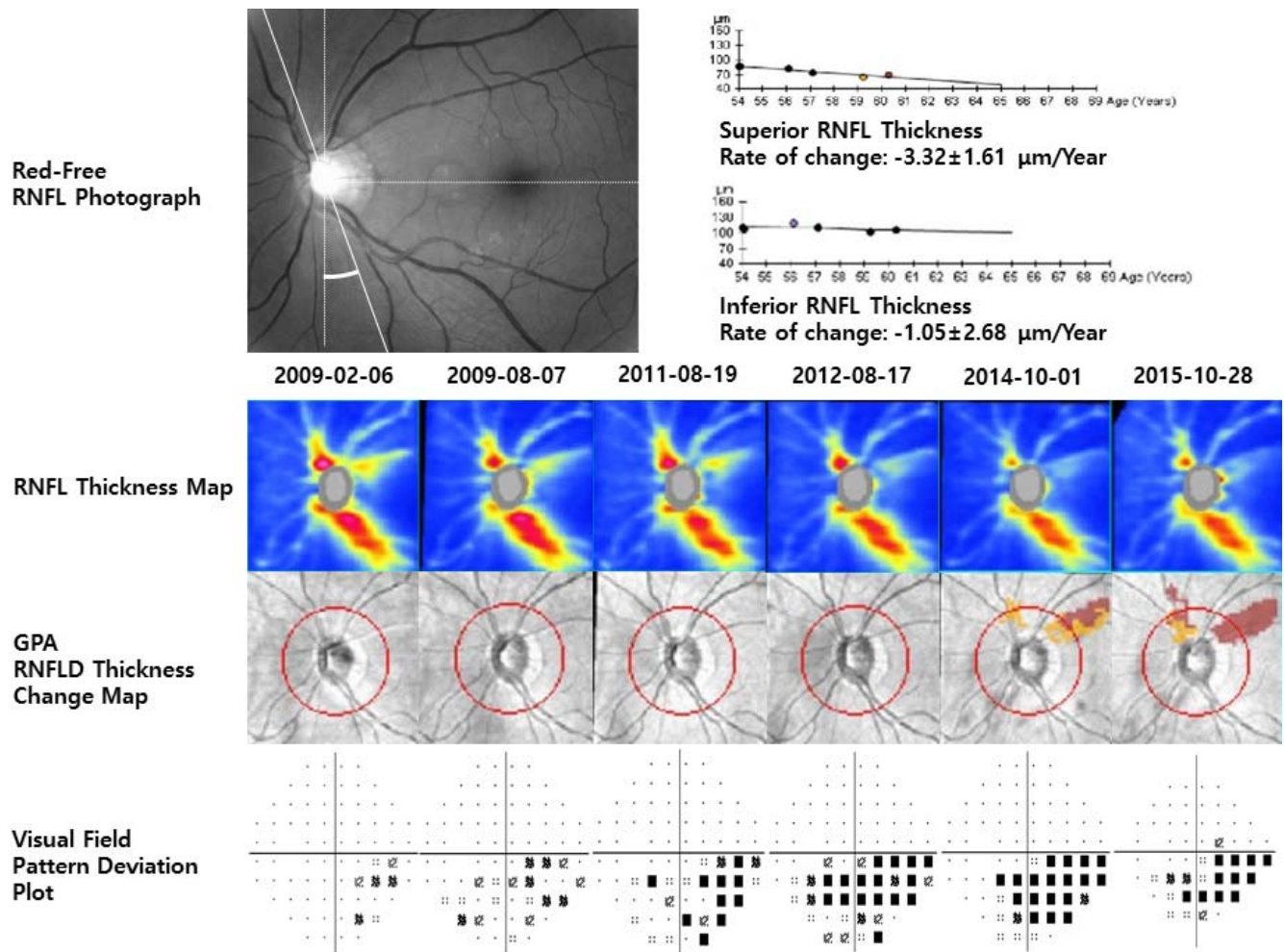
**DISCUSSION**

In the present study, we investigated the relationship between the direction of optic disc torsion and glaucoma progression. For this purpose, we only included eyes with glaucomatous damage confined to a single hemiretina. We found that the optic disc torsion–glaucomatous damage correspondence was

an important factor associated with glaucoma progression in patients with myopic open-angle glaucoma.

The correlation between the direction of optic disc torsion and the location of glaucomatous damage has been demonstrated in previous studies.<sup>19,20,29</sup> Park et al.<sup>19</sup> reported that the direction of optic disc torsion predicts the location of glaucomatous damage in patients with myopic normal-tension glaucoma. They concluded that the nerve fiber bundle located in the direction of optic disc torsion may be damaged. In another study, Lee et al.<sup>29</sup> reported that the RNFL defect was located in the same direction of the optic disc torsion in 60.2% cases of primary open-angle glaucoma ( $P = 0.029$ ). It is hypothesized that optic disc torsion can exert stress on certain axons through a mechanical twisting effect.

However, only a few studies have assessed the correlation between optic disc torsion and glaucoma progression. Sung et al.<sup>30</sup> investigated the relationship between optic disc torsion and VF progression in patients with myopic normal-tension glaucoma and found that eyes in the group without correspondence exhibited greater VF progression compared with eyes in the group with correspondence. However, in the present study, pRNFLT thinning in the quadrant with glaucomatous damage was faster in the torsion with correspondence



**FIGURE 3.** Representative case of a 61-year-old man exhibiting superior optic disc torsion and superior glaucomatous damage (optic disc torsion with correspondence). During baseline examinations (February 6, 2009), a superotemporal wedge-shaped RNFL defect is detected on a red-free fundus photograph and an inferonasal visual field defect is detected on a pattern deviation plot. The optic disc shows superior torsion; the degree of torsion is  $-19.9^\circ$ . Therefore, this case is considered a case of optic disc torsion with correspondence. The rate of peripapillary RNFL thickness changes in the superior quadrant is  $-3.32 \pm 1.61 \mu\text{m}/\text{y}$  analyzed by linear regression, and the RNFL thickness change map shows red color (likely loss) and orange color (possible loss) approximately 68 months after the baseline examination.

**TABLE 4.** Comparison of Changes in Peripapillary RNFL Thickness Between the Optic Disc Torsion-Affected Quadrant and the Torsion-Unaffected Quadrant in the Optic Disc Torsion Group ( $n = 43$ )

Variables	Optic Disc Torsion, Affected Quadrant	Optic Disc Torsion, Unaffected Quadrant	P Value
Baseline quadrant pRNFLT, $\mu\text{m}$	$90.42 \pm 18.97$	$94.93 \pm 15.52$	0.274*
Rate of pRNFLT changes ( $\mu\text{m}/\text{y}$ )	$-1.56 (P < 0.001)$	$-0.76 (P = 0.014)$	0.030†

\* Paired *t*-test.  
† Linear mixed model.

**TABLE 5.** Comparison of Changes in Peripapillary RNFL Thickness in the Quadrant With Glaucomatous Damage Between Eyes With Superior Correspondence and Those With Inferior Correspondence in the Torsion With Correspondence Group ( $n = 30$ )

Variables	Superior Correspondence	Inferior Correspondence	P Value
Patients, no.	13	17	
Baseline quadrant pRNFLT, $\mu\text{m}$	$85.69 \pm 12.99$	$78.47 \pm 10.79$	0.721*
Rate of glaucomatous damaged quadrant pRNFLT changes ( $\mu\text{m}/\text{y}$ )	$-1.51 (P = 0.003)$	$-1.20 (P = 0.001)$	0.580†

\* Student's *t*-test.  
† Linear mixed model.

group than in the no torsion group and the torsion with reverse correspondence group. There can be several reasons for the differences in results between the two studies.

First, in the previous study, the mean age of the subjects was  $37.83 \pm 10.89$  years, whereas that in our study was  $57.17 \pm 10.43$  years. Sung et al.<sup>30</sup> suggested that, although optic disc torsion plays a role in RNFL damage and VF defects in myopic eyes, these structural and functional changes may be static and not progressive. We speculate that optic disc torsion may affect glaucomatous changes in two steps. In the first step, myopia progresses and morphologic changes occur in the optic nerve head during adolescence. This can affect glaucoma susceptibility and result in glaucomatous damage. If myopia no longer progresses after this period, the morphology of the optic nerve head does not change and glaucomatous changes do not occur. In the second step, as the individual ages and becomes vulnerable to glaucoma, either glaucomatous changes can occur in the hemiretina affected by optic disc torsion or the glaucomatous damage can progress. Kwun et al.<sup>31</sup> reported that optic disc tilt and torsion were significantly associated with focal lamina cribrosa defects and suggested that the tilt and torsion could increase the vulnerability of the lamina cribrosa to glaucomatous damage.

Second, the time course of changes during glaucoma progression differs between VF and RNFL. RNFL damage generally occurs first and is closely followed by optic nerve head changes. VF begins to show defects only in later stages. The baseline mean deviations in the previous study and our study were  $-4.15 \pm 3.26$  and  $-3.37 \pm 3.19$  dB, respectively. The subjects of both studies were patients with relatively early glaucoma. Therefore, there may be a difference between the detection of glaucoma progression on the basis of VF changes and that on the basis of RNFL changes. Because of different subjects and study designs, we cannot perform direct comparisons between our study and the study by Sung et al.<sup>30</sup>

A previous study reported pRNFL thinning and thinning of the macular ganglion cell inner plexiform layer in healthy myopic discs, suggesting that the inferior RNFL is more vulnerable to mechanical stress compared with the superior RNFL.<sup>30</sup> In the present study, we subdivided the torsion with correspondence group into a superior correspondence group and an inferior correspondence group and compared pRNFLT changes between the two groups to evaluate the vulnerability of RNFL according to the direction of optic disc torsion. There was no significant difference in the rate of pRNFLT changes between the superior correspondence and inferior correspondence groups. Additional studies on this topic may be necessary for a further understanding of differences in the susceptibility to mechanical stress between the superior and inferior RNFLs.

In patients with early to moderate glaucoma, OCT is useful for monitoring the progression of optic neuropathies. In advanced stages, however, OCT is less clinically useful because of the "floor effect" of RNFLT. With advanced loss, pRNFLT becomes level and rarely decreases to  $<40 \mu\text{m}$  in thickness because of the assumed presence of residual glial or non-neural tissue including blood vessels.<sup>32,33</sup> In the present study, we eliminated the floor effect by excluding patients with advanced glaucoma accompanied by a mean deviation of  $<-12.00$  dB and pRNFL thinning to  $<60 \mu\text{m}$  in the superior or inferior quadrant observed on baseline OCT.

In the present study, we compared pRNFLT changes between optic disc torsion-affected and optic disc torsion-unaffected quadrants in each eye in the optic disc torsion group and found that pRNFL thinning was faster in the former than in the latter. However, this analysis has a limitation. The torsion group included a greater number of eyes with correspondence ( $n = 30$ ) compared with the number of eyes

with reverse correspondence ( $n = 13$ ). Therefore, the number of quadrants with glaucomatous damage was greater among the optic disc torsion-affected quadrants than among the optic disc torsion-unaffected quadrants. This may have affected the analysis of pRNFLT changes. Despite this limitation, a thinner baseline pRNFLT and faster pRNFL thinning in the optic disc torsion-affected quadrant than in the unaffected quadrant may be a clinically meaningful finding.

This study has some limitations. First, all study subjects were Asian, and the effects of optic disc torsion on pRNFLT changes may be different in other study populations. Second, most of the study subjects had myopic open-angle glaucoma with a normal baseline intraocular pressure (86.3%). Therefore, the characteristics of the included subjects may have affected the results of this study. Third, image acquisition using plain photography and OCT can be affected by the patient's eye and head positions,<sup>54</sup> leading to discrepancies between photographs and OCT images as well as inconsistencies between follow-up OCT images. To minimize such discrepancies, we always ensured that the patient was examined in the seated position with the forehead and chin exactly anchored to the device. The head position was confirmed by checking whether the imaginary line connecting both ears was parallel to the border of the table. We also compared the images and confirmed the alignment between the photographs and OCT images. Fourth, a large variability in what clinicians perceive as the disc margin could make a considerable difference in the measured parameters for a myopic optic disc. Therefore, to minimize subjectivity and variability, we used the average of values recorded by two independent glaucoma specialists and excluded subjects whose torsion angles measured by the two examiners differed by more than  $5^\circ$ .

In summary, we demonstrated a relationship between optic disc torsion and changes in pRNFLT over a long period of time in patients with myopic open-angle glaucoma. Optic disc torsion exhibited a significant association with the rate of RNFL thinning. Our findings suggest that the optic disc torsion-glaucomatous damage correspondence may be an important prognostic factor for patients with myopic open-angle glaucoma.

### Acknowledgments

Presented at the annual meeting of the Association for Research in Vision and Ophthalmology, Baltimore, Maryland, United States, May 2017. The authors alone are responsible for the content and writing of the paper.

Disclosure: **K.I. Na**, None; **W.J. Lee**, None; **Y.K. Kim**, None; **K.H. Park**, None; **J.W. Jeoung**, None

### References

- Casson RJ, Gupta A, Newland HS, et al. Risk factors for primary open-angle glaucoma in a Burmese population: the Meiktila Eye Study. *Clin Exp Ophthalmol*. 2007;35:739-744.
- Grodum K, Heijl A, Bengtsson B. Refractive error and glaucoma. *Acta Ophthalmol Scand*. 2001;79:560-566.
- Jiang X, Varma R, Wu S, et al. Baseline risk factors that predict the development of open-angle glaucoma in a population: the Los Angeles Latino Eye Study. *Ophthalmology*. 2012;119:2245-2253.
- Kuzin AA, Varma R, Reddy HS, Torres M, Azen SP; for the Los Angeles Latino Eye Study Group. Ocular biometry and open-angle glaucoma: the Los Angeles Latino Eye Study. *Ophthalmology*. 2010;117:1713-1719.
- Leske MC, Connell AM, Wu SY, Hyman LG, Schachat AP. Risk factors for open-angle glaucoma. The Barbados Eye Study. *Arch Ophthalmol*. 1995;113:918-924.



6. Mastropasqua L, Lobefalo L, Mancini A, Ciancaglini M, Palma S. Prevalence of myopia in open angle glaucoma. *Eur J Ophthalmol*. 1992;2:33-35.
7. Mitchell P, Hourihan F, Sandbach J, Wang JJ. The relationship between glaucoma and myopia: the Blue Mountains Eye Study. *Ophthalmology*. 1999;106:2010-2015.
8. Perera SA, Wong TY, Tay WT, Foster PJ, Saw SM, Aung T. Refractive error, axial dimensions, and primary open-angle glaucoma: the Singapore Malay Eye Study. *Arch Ophthalmol*. 2010;128:900-905.
9. Suzuki Y, Iwase A, Araie M, et al. Risk factors for open-angle glaucoma in a Japanese population: the Tajimi Study. *Ophthalmology*. 2006;113:1613-1617.
10. Wong TY, Klein BE, Klein R, Knudtson M, Lee KE. Refractive errors, intraocular pressure, and glaucoma in a white population. *Ophthalmology*. 2003;110:211-217.
11. Xu L, Wang Y, Wang S, Wang Y, Jonas JB. High myopia and glaucoma susceptibility the Beijing Eye Study. *Ophthalmology*. 2007;114:216-220.
12. Yoshida M, Okada E, Mizuki N, et al. Age-specific prevalence of open-angle glaucoma and its relationship to refraction among more than 60,000 asymptomatic Japanese subjects. *J Clin Epidemiol*. 2001;54:1151-1158.
13. Doshi A, Kreidl KO, Lombardi L, Sakamoto DK, Singh K. Nonprogressive glaucomatous cupping and visual field abnormalities in young Chinese males. *Ophthalmology*. 2007;114:472-479.
14. How AC, Tan GS, Chan YH, et al. Population prevalence of tilted and torped optic discs among an adult Chinese population in Singapore: the Tanjong Pagar Study. *Arch Ophthalmol*. 2009;127:894-899.
15. Samarawickrama C, Mitchell P, Tong L, et al. Myopia-related optic disc and retinal changes in adolescent children from Singapore. *Ophthalmology*. 2011;118:2050-2057.
16. Choi JA, Park HY, Shin HY, Park CK. Optic disc tilt direction determines the location of initial glaucomatous damage. *Invest Ophthalmol Vis Sci*. 2014;55:4991-4998.
17. Lee JE, Sung KR, Lee JY, Park JM. Implications of optic disc tilt in the progression of primary open-angle glaucoma. *Invest Ophthalmol Vis Sci*. 2015;56:6925-6931.
18. Lee KS, Lee JR, Kook MS. Optic disc torsion presenting as unilateral glaucomatous-appearing visual field defect in young myopic Korean eyes. *Ophthalmology*. 2014;121:1013-1019.
19. Park HY, Lee K, Park CK. Optic disc torsion direction predicts the location of glaucomatous damage in normal-tension glaucoma patients with myopia. *Ophthalmology*. 2012;119:1844-1851.
20. Park HY, Lee KI, Lee K, Shin HY, Park CK. Torsion of the optic nerve head is a prominent feature of normal-tension glaucoma. *Invest Ophthalmol Vis Sci*. 2015;56:156-163.
21. Teng CC, De Moraes CG, Prata TS, et al. The region of largest beta-zone parapapillary atrophy area predicts the location of most rapid visual field progression. *Ophthalmology*. 2011;118:2409-2413.
22. Teng CC, De Moraes CG, Prata TS, Tello C, Ritch R, Liebmann JM. Beta-Zone parapapillary atrophy and the velocity of glaucoma progression. *Ophthalmology*. 2010;117:909-915.
23. Kim TW, Kim M, Weinreb RN, Woo SJ, Park KH, Hwang JM. Optic disc change with incipient myopia of childhood. *Ophthalmology*. 2012;119:21-26.
24. Lee KM, Lee EJ, Kim TW. Lamina cribrosa configuration in tilted optic discs with different tilt axes: a new hypothesis regarding optic disc tilt and torsion. *Invest Ophthalmol Vis Sci*. 2015;56:2958-2967.
25. Park HY, Shin HY, Park CK. Imaging the posterior segment of the eye using swept-source optical coherence tomography in myopic glaucoma eyes: comparison with enhanced-depth imaging. *Am J Ophthalmol*. 2014;157:550-557.
26. Witmer MT, Margo CE, Drucker M. Tilted optic disks. *Surv Ophthalmol*. 2010;55:403-428.
27. Vongphanit J, Mitchell P, Wang JJ. Population prevalence of tilted optic discs and the relationship of this sign to refractive error. *Am J Ophthalmol*. 2002;133:679-685.
28. Giuffre G. Chorioretinal degenerative changes in the tilted disc syndrome. *Int Ophthalmol*. 1991;15:1-7.
29. Lee CE, Kim YK, Jeoung JW, et al. Topographic correlation between optic nerve head characteristics and retinal nerve fibre layer defect in primary open-angle glaucoma patients: Korea National Health and Nutrition Examination Survey. *Acta Ophthalmol*. 2016;94:e98-e104.
30. Sung MS, Kang YS, Heo H, Park SW. Optic disc rotation as a clue for predicting visual field progression in myopic normal-tension glaucoma. *Ophthalmology*. 2016;123:1484-1493.
31. Kwun Y, Han G, Choy YJ, Han JC, Kee C. Optic disc characteristics and visual field progression in normal tension glaucoma patients with tilted optic discs. *J Glaucoma*. 2016;25:901-907.
32. Chan CK, Miller NR. Peripapillary nerve fiber layer thickness measured by optical coherence tomography in patients with no light perception from long-standing nonglaucomatous optic neuropathies. *J Neuroophthalmol*. 2007;27:176-179.
33. Hood DC, Kardon RH. A framework for comparing structural and functional measures of glaucomatous damage. *Prog Retin Eye Res*. 2007;26:688-710.
34. Hwang YH, Lee JY, Kim YY. The effect of head tilt on the measurements of retinal nerve fibre layer and macular thickness by spectral-domain optical coherence tomography. *Br J Ophthalmol*. 2011;95:1547-1551.