

Patchy Chorioretinal Atrophy Changes at the Posterior Pole After Ranibizumab for Myopic Choroidal Neovascularization

Mariacristina Parravano,¹ Fabio Scarinci,¹ Marta Gilardi,¹ Lea Querques,² Monica Varano,¹ Francesco Oddone,¹ Francesco Bandello,² and Giuseppe Querques^{1,2}

¹Fondazione G.B. Bietti-IRCCS, Rome, Italy

²Department of Ophthalmology, IRCCS San Raffaele Scientific Institute, University Vita-Salute San Raffaele, Milan, Italy

Correspondence: Giuseppe Querques, Department of Ophthalmology, IRCCS San Raffaele Scientific Institute, University Vita-Salute San Raffaele, Via Olgettina 60, 20132, Milan, Italy; giuseppe.querques@hotmail.it

Submitted: July 18, 2017

Accepted: November 14, 2017

Citation: Parravano M, Scarinci F, Gilardi M, et al. Patchy chorioretinal atrophy changes at the posterior pole after ranibizumab for myopic choroidal neovascularization. *Invest Ophthalmol Vis Sci.* 2017;58:6358–6364. DOI:10.1167/iovs.17-22633

PURPOSE. To investigate the potential role of ranibizumab treatment on the development or enlargement of chorioretinal atrophy (CRA) at the posterior pole in eyes with myopic choroidal neovascularization (mCNV).

METHODS. This observational case series included patients having high myopia spherical equivalent refractive error ≥ -6.00 diopters, axial length (AxL) ≥ 26.0 mm in both eyes, and mCNV treated with ranibizumab 0.5 mg in one eye, who were retrospectively enrolled. Areas of CRA in treated and fellow eyes were measured on fundus autofluorescence images at baseline, 12, and 24 months. The CRA hypoautofluorescent lesions were divided in two groups: perilesional atrophy, corresponding to area around the mCNV, and patchy extralesional atrophy, corresponding to CRA between the temporal vascular arcades.

RESULTS. Thirty-six eyes of 18 patients were included. The mean perilesional CRA size significantly increased from baseline to 12 months (3.5 ± 10.6 mm², $P = 0.02$) and 24 months (4.4 ± 11.7 mm², $P = 0.038$) in the treated eye. In treated and not treated eyes, patchy extralesional CRA at the posterior pole increased significantly from baseline to 12 and 24 months follow-up. None of the fellow eyes developed mCNV. No significant relationship was found between the number of injections, AxL, age, and perilesional and patchy extralesional CRA in the treated and not treated eyes ($P > 0.05$).

CONCLUSIONS. In eyes with pathologic myopia and mCNV, intravitreal injections of ranibizumab should not be considered as a contributing risk factor worsening the natural course of CRA, even though the risk of the perilesional CRA enlargement should be taken into account.

Keywords: pathologic myopia, choroidal neovascularization, ranibizumab

The axial elongation and deformity of the eye, as well as the presence of myopic maculopathy and posterior staphyloma, are specific findings of pathologic myopia. These anatomic alterations of the globe can cause several complications that lead to visual impairment.^{1–3} Pathologic myopia per se is a disease with a different clinical manifestation and progression, depending on the age of the onset and duration, as well as the mechanical stretching of the retina from axial elongation.⁴

Myopic maculopathy, including myopic choroidal neovascularization (mCNV) and chorioretinal atrophy (CRA) is the primary cause of vision loss associated with pathologic myopia and often affects patients during their most productive years.^{5–7} Importantly, it has been found that the most common cause of CNV in patients younger than 50 years is pathologic myopia with a prevalence up to 40% in highly myopic patients.⁸ Although the long-term visual prognosis of mCNV is considered to be poor, with a high proportion of patients having a significant loss of visual acuity,^{9,10} the use of intravitreal anti-VEGF therapy is considered the standard care of treatment. Of note, whereas several studies with 1-year follow-up have shown significant visual acuity improvement after anti-VEGF therapy,^{11–15} in other reports with 2-year follow-up the overall outcomes seem to be less predictable, with conflicting results.^{16–23} Several factors might influence the long-term

visual prognosis after anti-VEGF treatment in myopic patients, including worsening of the CRA, as well as staphyloma and lacquer crack formation.⁶

The aim of this study is to explore if the anti-VEGF treatment could accelerate and worsen the development or enlargement of CRAs in eyes with mCNV treated with intravitreal injection of ranibizumab with follow-up at 2 years.

METHODS

A retrospective chart review identified patients affected by pathologic myopia (myopic refractive error ≥ 6 diopters [D]), who were diagnosed with subfoveal, juxtafoveal, or extrafoveal mCNV at the Ophthalmology Department of Fondazione G.B. Bietti-IRCCS from January 1, 2008, through January 1, 2015. The local institutional review board approved this research protocol, and written informed consent was obtained from all patients.

The inclusion criteria were (1) high myopia, defined by a spherical equivalent (SE) refractive error equal or greater than 6.00 D and/or axial length (AxL) equal or superior to 26.0 mm in both eyes and the difference in AxL between the eyes no greater than 2 mm; (2) mCNV treated with ranibizumab 0.5 mg



in one eye; (3) at least 2 years posttreatment follow-up; (4) fellow eye that never developed mCNV.

The exclusion criteria included myopic eyes with diffuse CRA and other ocular disorders such as glaucoma, diabetic retinopathy, or other retinal vascular diseases, or history of vitreoretinal surgery. Also, patients who received any treatments for myopic lesions, which might have worsened the natural course of myopic retinopathy, including laser photocoagulation, surgical treatment, and photodynamic therapy for mCNV were excluded.

At baseline, diagnosis of mCNV was based on a complete ophthalmological evaluation, which included best-corrected visual acuity (BCVA) measurement with Early Treatment Diabetic Retinopathy Study (ETDRS) charts, fundus examination, fundus autofluorescence, and fluorescein angiography (FA) (TRC-50X; Topcon Instrument Corp., Tokyo, Japan). Measurement of AxL was also recorded at baseline (IolMaster; Carl Zeiss Meditec AG, Jena, Germany).

Patients diagnosed with mCNV were treated with a single intravitreal injection of 0.5 mg/0.05 mL ranibizumab and retreated according to predefined criteria.^{24–26}

Patients were evaluated to identify the need for retreatment with ranibizumab during the monthly follow-up. During follow-up, retreatment criteria were either a decrease of BCVA >5 ETDRS letters or presence of retinal hemorrhage or signs of mCNV activity on FA.

The number of ranibizumab intravitreal injections was evaluated at baseline, 12, and 24 months. The fellow non-treated eye was used as control.

Retinal fundus photography (FP), fundus autofluorescence (FAF), and FA were evaluated at baseline, 12, and 24 months to obtain a longitudinal analysis of the posterior pole, including optic disc, macular view, and upper and lower temporal arcade from both eyes.

Areas of CRA in treated and fellow eye were measured on FAF images at baseline and at 12 and 24 months. The measurements included the posterior pole area between the temporal vascular arcades.

A dedicated software (Draw Region, HRA and Measure Image, IMAGEnet; Topcon Medical Systems, Inc., Oakland, NJ, USA) was used to assess the extension of CRA in square millimeters, and all measurements were performed by two masked experienced investigators (MP and MG).

The hypoautofluorescent lesions, corresponding to CRA measured in the FAF image, were divided in two groups: perilesional atrophy, which corresponded to area around the mCNV, and patchy extralesional atrophy, which corresponded to areas between the temporal vascular arcades.

At baseline the peripapillary atrophy area shown on FAF was outlined. For patients in whom the CRA areas at the posterior pole merged with peripapillary atrophy over time, the peripapillary atrophy area at the baseline was subtracted from the whole CRA area measured at 1- and 2-year follow-ups.

All CRA areas that merged during the 2 years of follow-up were summed for the measurements and considered as one area.

The degree of CRA changes around the perilesional and patchy extralesional CRA was expressed as the difference between the CRA area at each follow-up time point and the CRA area at baseline.

Statistical Analysis

Statistical analysis was performed using analysis software (GraphPad Prism ver. 6.0; GraphPad Software, San Diego, CA, USA). Continuous data were described as mean \pm standard deviation and categorical data as frequencies. Multivariate analysis of variance for repeated measures was used to

compare the effect of the interaction between time and treatment over the follow-up between the groups. Post hoc between-group comparison was analyzed using the Mann-Whitney test. Linear regression analysis was used to explore the relationship between variables. A *P* value < 0.05 was considered statistically significant.

A bivariate correlation between variables has been performed by Pearson correlation coefficient or Spearman's ρ correlation coefficient in case of nonparametric distributions to explore the relationship between the growth of patchy atrophy at the posterior pole as a mean change in treated and untreated eyes in each individual patient over 2 years of follow-up.

RESULTS

Patient Demographic Data

Among 132 screened patients, 18 met the inclusion criteria (12 females and 6 males, mean age 62.2 ± 16.7 years), and thus 36 eyes were analyzed. Mean AxL was 28.9 ± 2.3 mm in the treated and 28.4 ± 2.1 mm in the fellow eyes (*P* = 0.57).

Demographic and clinical data are shown in Table 1. During the study period (24 months) patients treated with ranibizumab received a mean of 2.6 ± 1.7 intravitreal injections (1.7 ± 1.8 [range, 1–4] in the first year and 0.9 ± 1.1 [range, 0–3] in the second year). None of the fellow eyes developed mCNV, and no eyes underwent cataract surgery during the study period.

Characterization and Progression of Myopic Maculopathy

In the treated eye, mCNVs were classified as subfoveal in 27.7% (5/18) of eyes, juxtafoveal in 50% (9/18) of eyes, and extrafoveal in 22.2% (4/18) of eyes.

Perilesional CRA was present at baseline in 38.9% (7/18) of eyes; patchy extralesional CRA at the posterior pole was present in 72.2% (13/18) of treated eyes and in 61.1% (11/18) of fellow eyes.

The mean perilesional CRA size significantly increased from baseline (3.1 ± 10.2 mm²) to 12 months (3.5 ± 10.6 mm², *P* = 0.02) and 24 months (4.4 ± 11.7 mm², *P* = 0.038) during anti-VEGF treatment (Fig. 1).

Among those eyes with absence of perilesional CRA at baseline (61.1%, 11/18), 55.5% (10/18) did not develop atrophy during 24-months follow-up, while one eye showed the presence of perilesional CRA after 12 months (1.6 mm²) that enlarged after 24 months (3.3 mm²).

In the treated eyes, patchy extralesional CRA at the posterior pole increased significantly from baseline (3.9 ± 10.6 mm²) at 12 (6.4 ± 14.3 mm², *P* = 0.037) and 24 (8.3 ± 16.4 mm², *P* = 0.019) months of follow-up (Fig. 1); similarly, in the nontreated eyes patchy extralesional CRA at the posterior pole increased significantly from baseline (7.5 ± 11.6 mm²) at 12 (8.4 ± 12.4 mm², *P* = 0.035) and 24 (8.9 ± 12.9 mm², *P* = 0.006) months of follow-up without any difference between groups (*P* = 0.09) (Fig. 2).

Development of new areas at 24 months did not significantly differ between treated and fellow eyes.

In the treated eyes, two patients showed posterior pole CRA merging with peripapillary atrophy over the 2 years of follow-up. However, as indicated in the method, because the value of the peripapillary atrophy area at the baseline was subtracted from the whole CRA area measured at 1- and 2-year follow-up, these changes did not influence the final measurements obtained.

TABLE 1. Main Demographics and Clinical Data

Pt No.	Sex	Age	VA Baseline Treated Eyes	VA Baseline Fellow Eyes	AxL Treated Eyes	AxL Fellow Eyes	Lens Status Treated Eyes*	Lens Status Fellow Eyes	mCNV Location
1	F	47	70	35	31.27	30.15	0	0	JUXTA
2	F	71	74	0	28.38	28.89	1	1	SUB
3	F	22	69	69	28.35	29.01	0	0	SUB
4	M	60	83	85	33.94	31.98	0	0	SUB
5	M	84	79	77	29.03	29.07	1	1	EXTRA
6	F	62	82	85	26.96	26.87	1	1	JUXTA
7	F	73	60	70	29.91	30.02	1	1	JUXTA
8	M	80	71	0	27.15	26.88	0	0	EXTRA
9	F	54	71	60	33.31	32.15	0	0	JUXTA
10	M	39	85	85	26.12	27.34	0	0	JUXTA
11	F	65	58	74	28.89	26.99	0	0	JUXTA
12	F	72	69	5	28.42	26.47	0	0	JUXTA
13	F	85	76	5	26.43	26.21	1	1	SUB
14	F	58	56	35	30.89	31.05	1	1	SUB
15	M	50	63	73	26.50	26.06	0	0	EXTRA
16	F	49	80	79	28.14	26.62	0	0	JUXTA
17	M	77	51	90	29.99	29.85	1	1	JUXTA
18	F	72	66	70	26.71	26.13	1	1	EXTRA

Pt No., patient number; VA, visual acuity; SUB, subfoveal; JUXTA, juxtafoveal; EXTRA, extrafoveal.

* 1, pseudophakia; 0, phakia.

Progression of CRA in both the treated and fellow eyes at 12 and 24 months is presented in detail in Tables 2, 3, and 4.

A significant correlation of moderate strength was found between 2 years mean change of patchy atrophy at the posterior pole in treated and fellow eyes (Spearman's ρ correlation coefficient: R^2 0.56, $P = 0.016$). This finding corroborates our results of a similar growth of patchy atrophy at the posterior pole in treated and untreated eyes; this seems not to be influenced by anti-VEGF treatment.

Within-group analysis revealed that the patients treated with ranibizumab experienced a stabilization of the mean BCVA from baseline, which was evident since the first follow-up visit (70.2 ± 9.8 vs. 68.4 ± 14.8 letters, $P = 0.4$), and maintained up to the last visit at 24 months (68.4 ± 14.8 vs. 66.05 ± 15.3 letters, $P = 0.07$). Six (33.3%) of 18 treated eyes showed an improvement of BCVA (range, 1–8 letters). Eleven (61.1%) out of 18 treated eyes experienced visual loss (range, 3–29 letters), with two eyes losing more than two lines because of the greater extension of perilesional CRA in the macular area.

BCVA in the fellow eyes remained stable during 24 months in most of the patients (64.7 ± 5.1 vs. 63.9 ± 5.8 letters, $P = 0.07$). Only one (5.5%) out of 18 fellow eyes experienced a

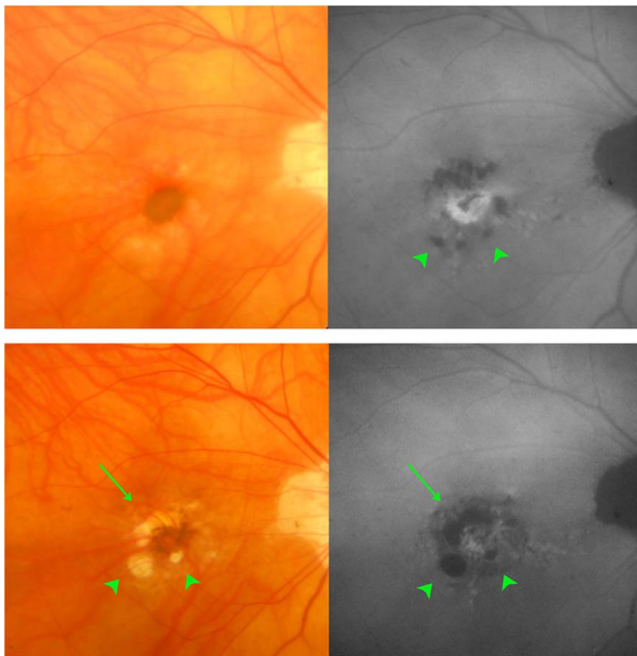


FIGURE 1. CRA changes in eyes with mCNV. Fundus color photograph and autofluorescence of patient 2 in the tables diagnosed with mCNV showing the enlargement of perilesional (arrow) as well as patchy extrasional (arrowhead) CRA from baseline (top left–top right) to 24 months follow-up (bottom left–bottom right).

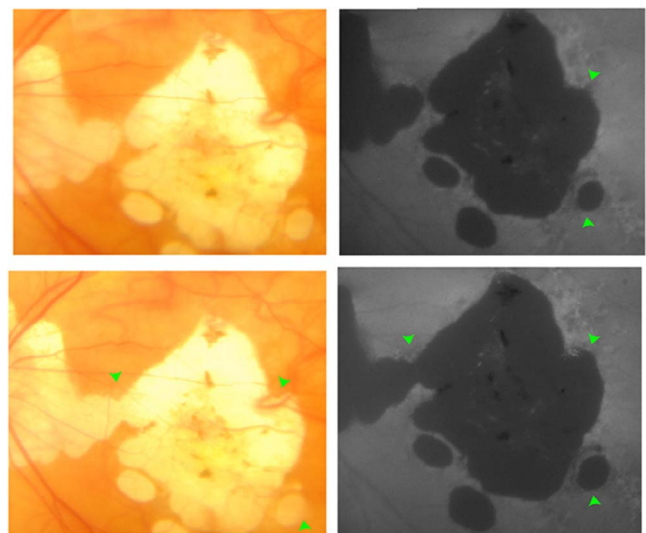


FIGURE 2. CRA changes in the fellow eyes with pathologic myopia without CNV. Fundus color photograph and autofluorescence of patient 2 (in the tables) with high myopia showing the enlargement of patchy (arrowhead) CRA in the fellow nontreated eye from baseline (top left–top right) to 24 months follow-up (bottom left–bottom right).

TABLE 2. Progression of Perilesional CRA and Number of Intravitreal Injections in the Treated Eyes at Baseline, 12, and 24 Months

Pt No.	Treated Eyes	CRA		Mean Change		Mean Change		Mean Change		IV Inj, 1 y	IV Inj, 2 y	IV Inj Total
		Baseline	CRA, 1 y	CRA, 1 y	CRA, 2 y	CRA, 2 y	CRA, 1–2 y					
1	LE	3.302	5.205	1.903	7.110	3.808	1.905	4	0	4		
2	RE	0.567	0.694	0.127	0.775	0.208	0.081	4	3	7		
3	LE	0	0	0	0	0	0	1	0	1		
4	LE	0	0	0	0	0	0	2	0	2		
5	LE	0	0	0	0	0	0	1	1	2		
6	RE	0	0	0	0	0	0	1	1	2		
7	LE	0.173	1.614	1.441	8.170	7.997	6.556	4	0	4		
8	LE	0	0	0	0	0	0	2	1	3		
9	LE	0	0	0	0	0	0	1	0	1		
10	RE	7.568	8.281	0.713	9.064	1.496	0.783	1	0	1		
11	RE	0	0	0	0	0	0	1	1	2		
12	LE	0	0	0	0	0	0	1	3	4		
13	RE	0.760	0.844	0.084	1.040	0.280	0.196	3	3	6		
14	LE	0.332	0.385	0.053	0.426	0.094	0.041	1	0	1		
15	RE	0	0	0	0	0	0	1	2	3		
16	RE	0	0	0	0	0	0	1	0	1		
17	RE	0	1.600	1.600	3.274	3.274	1.674	1	1	2		
18	RE	43.462	44.882	1.420	49.819	6.357	4.937	1	1	2		

LE, left eye; RE, right eye; IV Inj, intravitreal injection.

visual loss of seven letters from the baseline because of the enlargement of CRA in the macula area.

No significant relationship was found between the number of injections and visual acuity change in the treated eyes and between the number of injections and perilesional CRA change at 24 months (R^2 0.08, $P = 0.2$).

No significant relationship was found between AxL and age and patchy extralesional CRA in the treated and not treated eyes nor between AxL and age and perilesional CRA in the treated eye (data not shown).

DISCUSSION

Our results showed that under anti-VEGF intravitreal injection with ranibizumab in highly myopic eyes with mCNV the perilesional size of CRA increased, whereas the treatment did not influence the development or enlargement of the patchy

extralesional CRA areas at the posterior pole as compared to fellow eyes (not treated) over 2 years of follow-up.

Patchy extralesional CRA at the posterior pole increased significantly from baseline in both the treated and fellow (not treated) eyes at 12 and 24 months of follow-up without any difference between groups.

Chorioretinal atrophy represents the end stage of progressive photoreceptor and RPE cell death causing a dramatic loss of visual acuity, especially when the fovea and perifovea are involved. However, in addition to the well-known natural progression pattern of pathologic myopia, the prevalence of structural changes, including the development of new CRA areas and their enlargement, may be influenced by several factors such as age, AxL, the presence of staphyloma, and choroidal thickness.^{5,7,27–29} Moreover, natural history of pathologic myopia is characterized by progression of CRA in eyes with mCNV either treated or untreated.³⁰

It has been shown that 40% of the highly myopic eyes have progression of myopic maculopathy over a mean follow-up of

TABLE 3. Progression of Patchy Extralesional CRA at the Posterior Pole in the Treated Eyes at Baseline, 12, and 24 Months

Pt No.	Treated Eye	CRA		Mean Change		Mean Change		Mean Change	
		Baseline	CRA, 1 y	CRA, 1 y	CRA, 2 y	CRA, 2 y	CRA, 1–2 y		
1	LE	2.054	4.217	2.163	6.395	4.341	2.178		
2	RE	1.682	4.885	3.203	6.004	4.322	1.119		
3	LE	0	0	0	3.854	3.854	3.854		
4	LE	1.202	2.532	1.33	3.927	2.725	1.395		
5	LE	2.369	3.084	0.715	4.099	1.73	1.015		
6	RE	0	0	0	0	0	0		
7	LE	4.001	11.178	7.177	21.645	17.644	10.467		
8	LE	0	0	0	0	0	0		
9	LE	0.244	0.421	0.177	0.492	0.248	0.071		
10	RE	0	0	0	0.155	0.155	0.155		
11	RE	44.913	57.205	12.292	64.636	19.723	7.431		
12	LE	0.148	0.41	0.262	0.921	0.773	0.511		
13	RE	0	0	0	0	0	0		
14	LE	11.261	27.171	15.91	32.703	21.442	5.532		
15	RE	1.797	2.545	0.748	2.565	0.768	0.02		
16	RE	0.266	0.289	0.023	0.330	0.064	0.064		
17	RE	0.190	0.573	0.383	0.887	0.697	0.697		
18	RE	0.888	0.987	0.099	1.008	0.12	0.021		

TABLE 4. Progression of Patchy Extralesional CRA at the Posterior Pole in the Fellow (Not Treated) Eyes at Baseline, 12, and 24 Months

Pt No.	Fellow Eye	CRA		Mean Change		Mean Change	
		Baseline	CRA, 1 y	CRA, 1 y	CRA, 2 y	CRA, 2 y	CRA, 1–2 y
1	RE	21.087	26.784	5.697	27.489	6.402	0.705
2	LE	30.514	32.011	1.497	34.747	4.233	2.736
3	RE	0	0.858	0.858	1.775	1.775	0.917
4	RE	0	0	0	0	0	0
5	RE	0	0.181	0.181	0.196	0.196	0.015
6	LE	0.477	0.62	0.143	0.706	0.229	0.086
7	RE	16.764	19.583	2.819	19.798	3.034	0.215
8	RE	33.977	34.092	0.115	35.288	1.311	1.196
9	RE	0	0	0	0.417	0.417	0.417
10	LE	0	0	0	0.253	0.253	0.253
11	LE	1.095	1.471	0.376	1.517	0.422	0.046
12	RE	19.129	19.148	0.019	20.705	1.576	1.557
13	LE	0.397	0.479	0.082	0.689	0.292	0.21
14	RE	12.145	14.911	2.766	15.03	2.885	0.119
15	LE	0	0	0	0	0	0
16	LE	0.089	0.105	0.016	0.127	0.038	0.022
17	LE	0.311	0.526	0.215	0.731	0.420	0.205
18	LE	0	0	0	0	0	0

12.7 years; eyes with tessellated fundus, lacquer cracks, and diffuse atrophy, as well as patchy atrophy, at the first visit progressed to the development of CNV, while eyes with CNV developed macular atrophy with time.⁶

Moreover, eyes with patchy atrophy and eyes with CNV showed a higher progression of the myopic maculopathy compared to the other myopic retinal findings, and in the presence of the patchy atrophy, the most frequent progression pattern was an enlargement of the area followed by fusion with other patchy atrophy originated from diffuse atrophy or patchy atrophy along the staphyloma.⁶

In our group of patients, only two eyes showed the fusion of the diffuse atrophy or patchy atrophy at the posterior pole with the peripapillary atrophy.

Of note, Hayashi et al.³¹ reported that 96.3% of untreated eyes with mCNV developed macular atrophy due to natural progression of the disease after 5 years of follow-up.

On the other hand, in line with our results, Calvo-Gonzalez et al.³² also found that after 2 years of treatment with intravitreal injection, 70.2% of the myopic eyes with mCNV developed atrophy around the regressed lesion. More recently, Oishi et al.³³ showed the development/enlargement of CRA in 72.7% of the eyes with mCNV treated with bevacizumab after 4 years of follow-up. However, since we used ranibizumab to treat the mCNV, we believe the results cannot be directly compared.

In a previous study,³⁴ we have found that in eyes with mCNV treated with either photodynamic therapy or ranibizumab the mean perilesional size of CRA increased at the final visit. Interestingly, the group treated with photodynamic therapy showed higher CRA values in comparison with the ranibizumab group (82.6% vs. 52.6%, respectively).

There is a little information on the possible effect and mechanism of anti-VEGF treatment in pathologic myopia, not only around the mCNV lesion but also at the posterior pole. Furthermore, studies have found that ranibizumab could have a stronger effect on the macular atrophy formation than bevacizumab in patients with AMD.^{35,36}

While anti-VEGF treatments are important to reduce and inhibit the disease activity in patients with mCNV, the VEGF inhibition might influence its expression in RPE cell,^{37–39} which is fundamental for RPE cells and choriocapillaris integrity. This in turn would result in the enlargement of

perilesional CRA, but not of patchy extralesional CRA at the posterior pole, as demonstrated in our study. The similar extension of patchy extralesional CRA, between treated and untreated eyes, suggests limited or no role of anti-VEGF treatments in the development and progression of atrophy and allows us to hypothesize that the enlargement of perilesional CRA simply represents the natural progression of atrophy and fibrosis related to mCNV.

In keeping with this possible effect of anti-VEGF treatment, McLeod et al.⁴⁰ found that choriocapillaris dropout in areas surrounding CNV may explain the higher growth of geographic atrophy close to CNV in AMD.

On the other hand, one could discuss the possibility that intravitreal injection in one eye may have an effect on the fellow eye, even though, to date, this concept remains uncertain. Indeed, especially in patients with diabetic macular edema, a compromised blood-retinal barrier caused by the disease could facilitate the anti-VEGF effect in both eyes.⁴¹ We believe that the effect of intravitreal treatment in the fellow eye is less likely to happen in patients with pathologic myopia, especially when the latter is not affected by any vascular changes. Finally, we cannot totally exclude that intravitreal ranibizumab may reach the fellow eye via the systemic circulation.

While the correlation between the number of injection and atrophy has been studied in several studies in patients with AMD, the results in patients with mCNV are still controversial.^{35,36,42–44} In patients with AMD, several studies concluded that there was no correlation between the number of injections and macular atrophy.^{35,36,44,45}

In our cohort of patients, the number of treatments did not influence CRA changes over time, even in eyes with mCNV. However, since we used a *pro re nata* regimen, we cannot extend this conclusion to other regimens of treatment, where the dose-response effect could be higher.

Limitations include the retrospective design of the study as well as the relatively small number of eyes. Future prospective, longitudinal studies with longer period of follow-up are needed to confirm our results.

In conclusion, we showed that in eyes with pathologic myopia and mCNV, intravitreal injections of ranibizumab should not be considered as a contributing risk factor to worsening of the natural course of CRA areas at the posterior

pole, even though the risk of the perilesional CRA enlargement, which possibly represents the natural progression of atrophy and fibrosis related to mCNV, should be taken into account.

Acknowledgments

Supported by Italian Ministry of Health and Fondazione Roma. The funders had no role in study design, data collection and analysis, decision to publish, or preparation of the manuscript.

Disclosure: **M. Parravano**, Allergan (S), Bayer (S); Novartis (S); **F. Scarinci**, None; **M. Gilardi**, None; **L. Querques**, Allergan (S); **M. Varano**, Allergan (S), Bayer (S); Novartis (S); **F. Oddone**, Allergan (S), Glaucoom (S), Omikron (S), Santen (S); **F. Bandello**, Allergan (S), Alimera (S), Bayer (S), Farmila-Thea (S), Novartis (S), Thrombogenics (S); **G. Querques**, Allergan (S), Alimera (S), Bayer (S), Novartis (S), Heidelberg (C), Zeiss (S), Sandoz (S), KHB (S)

References

- Green JS, Bear JC, Johnson GJ. The burden of genetically determined eye disease. *The Br J Ophthalmol*. 1986;70:696-699.
- Cotter SA, Varma R, Ying-Lai M, Azen SP, Klein R. Causes of low vision and blindness in adult Latinos: the Los Angeles Latino Eye Study. *Ophthalmology*. 2006;113:1574-1582.
- Buch H, Vinding T, Nielsen NV. Prevalence and causes of visual impairment according to World Health Organization and United States criteria in an aged, urban Scandinavian population: the Copenhagen City Eye Study. *Ophthalmology*. 2001;108:2347-2357.
- Ohno-Matsui K, Lai TY, Lai CC, Cheung CM. Updates of pathologic myopia. *Prog Retin Eye Res*. 2016;52:156-187.
- Shih YF, Ho TC, Hsiao CK, Lin LL. Visual outcomes for high myopic patients with or without myopic maculopathy: a 10 year follow up study. *Br J Ophthalmol*. 2006;90:546-550.
- Hayashi K, Ohno-Matsui K, Shimada N, et al. Long-term pattern of progression of myopic maculopathy: a natural history study. *Ophthalmology*. 2010;117:1595-1611.
- Wang NK, Lai CC, Chu HY, et al. Classification of early dry-type myopic maculopathy with macular choroidal thickness. *Am J Ophthalmol*. 2012;153:669-677.
- Hotchkiss ML, Fine SL. Pathologic myopia and choroidal neovascularization. *Am J Ophthalmol*. 1981;91:177-183.
- Tabandeh H, Flynn HW Jr, Scott IU, et al. Visual acuity outcomes of patients 50 years of age and older with high myopia and untreated choroidal neovascularization. *Ophthalmology*. 1999;106:2063-2067.
- Yoshida T, Ohno-Matsui K, Ohtake Y, et al. Long-term visual prognosis of choroidal neovascularization in high myopia: a comparison between age groups. *Ophthalmology*. 2002;109:712-719.
- Chan WM, Lai TY, Liu DT, Lam DS. Intravitreal bevacizumab (Avastin) for myopic choroidal neovascularisation: 1-year results of a prospective pilot study. *Br J Ophthalmol*. 2009;93:150-154.
- Varano M, Tedeschi M, Oddone F, Perillo L, Coppe AM, Parravano M. Microperimetric retinal changes in myopic choroidal neovascularization treated with intravitreal ranibizumab. *Retina*. 2010;30:413-417.
- Gharbiya M, Giustolisi R, Allievi F, et al. Choroidal neovascularization in pathologic myopia: intravitreal ranibizumab versus bevacizumab—a randomized controlled trial. *Am J Ophthalmol*. 2010;149:458-464.
- Konstantinidis L, Mantel I, Pournaras JA, Zografos L, Ambresin A. Intravitreal ranibizumab (Lucentis) for the treatment of myopic choroidal neovascularization. *Graefes Arch Clin Exp Ophthalmol*. 2009;247:311-318.
- Silva RM, Ruiz-Moreno JM, Rosa P, et al. Intravitreal ranibizumab for myopic choroidal neovascularization: 12-month results. *Retina*. 2010;30:407-412.
- Gharbiya M, Cruciani F, Parisi F, Cuzzo G, Altamari S, Abdolrahimzadeh S. Long-term results of intravitreal bevacizumab for choroidal neovascularisation in pathological myopia. *Br J Ophthalmol*. 2012;96:1068-1072.
- Baba T, Kubota-Taniai M, Kitahashi M, Okada K, Mitamura Y, Yamamoto S. Two-year comparison of photodynamic therapy and intravitreal bevacizumab for treatment of myopic choroidal neovascularisation. *Br J Ophthalmol*. 2010;94:864-870.
- Gharbiya M, Allievi F, Conflitti S, et al. Intravitreal bevacizumab for treatment of myopic choroidal neovascularization: the second year of a prospective study. *Clin Ter*. 2010;161:e87-93.
- Chen CH, Wu PC, Chen YJ, Liu YC, Kuo HK. Intravitreal injection of 2.5 mg bevacizumab for treatment of myopic choroidal neovascularization in treatment-naive cases: a 2-year follow-up. *J Ocul Pharmacol Ther*. 2011;27:395-400.
- Nakanishi H, Tsujikawa A, Yodoi Y, et al. Prognostic factors for visual outcomes 2-years after intravitreal bevacizumab for myopic choroidal neovascularization. *Eye*. 2011;25:375-381.
- Ikuno Y, Nagai Y, Matsuda S, et al. Two-year visual results for older Asian women treated with photodynamic therapy or bevacizumab for myopic choroidal neovascularization. *Am J Ophthalmol*. 2010;149:140-146.
- Ruiz-Moreno JM, Montero JA. Intravitreal bevacizumab to treat myopic choroidal neovascularization: 2-year outcome. *Graefes Arch Clin Exp Ophthalmol*. 2010;248:937-941.
- Franqueira N, Cachulo ML, Pires I, et al. Long-term follow-up of myopic choroidal neovascularization treated with ranibizumab. *Ophthalmologica*. 2012;227:39-44.
- Photodynamic therapy of subfoveal choroidal neovascularization in age-related macular degeneration with verteporfin: one-year results of 2 randomized clinical trials—TAP report. Treatment of age-related macular degeneration with photodynamic therapy (TAP) Study Group. *Arch Ophthalmol*. 1999;117:1329-1345.
- Bressler NM. Photodynamic therapy of subfoveal choroidal neovascularization in age-related macular degeneration with verteporfin: two-year results of 2 randomized clinical trials—tap report 2. *Arch Ophthalmol*. 2001;119:198-207.
- Verteporfin In Photodynamic Therapy Study Group. Verteporfin therapy of subfoveal choroidal neovascularization in age-related macular degeneration: two-year results of a randomized clinical trial including lesions with occult with no classic choroidal neovascularization—verteporfin in photodynamic therapy report 2. *Am J Ophthalmol*. 2001;131:541-560.
- Gozum N, Cakir M, Gucukoglu A, Sezen F. Relationship between retinal lesions and axial length, age and sex in high myopia. *Eur J Ophthalmol*. 1997;7:277-282.
- Curtin BJ, Karlin DB. Axial length measurements and fundus changes of the myopic eye. I. The posterior fundus. *Trans Am Ophthalmol Soc*. 1970;68:312-334.
- Ohsugi H, Ikuno Y, Oshima K, Yamauchi T, Tabuchi H. Morphologic characteristics of macular complications of a dome-shaped macula determined by swept-source optical coherence tomography. *Am J Ophthalmol*. 2014;158:162-170.
- Oishi A, Yamashiro K, Tsujikawa A, et al. Long-term effect of intravitreal injection of anti-VEGF agent for visual acuity and chorioretinal atrophy progression in myopic choroidal neovascularization. *Graefes Arch Clin Exp Ophthalmol*. 2013;251:1-7.

31. Hayashi K, Ohno-Matsui K, Shimada N, et al. Long-term results of photodynamic therapy for choroidal neovascularization in Japanese patients with pathologic myopia. *Am J Ophthalmol*. 2011;151:137-147.
32. Calvo-Gonzalez C, Reche-Frutos J, Donate J, Fernandez-Perez C, Garcia-Feijoo J. Intravitreal ranibizumab for myopic choroidal neovascularization: factors predictive of visual outcome and need for retreatment. *Am J Ophthalmol*. 2011;151:529-534.
33. Oishi A, Hata M, Shimozono M, Mandai M, Nishida A, Kurimoto Y. The significance of external limiting membrane status for visual acuity in age-related macular degeneration. *Am J Ophthalmol*. 2010;150:27-32.
34. Parravano M, Ricci F, Oddone F, Missiroli F, De Felici C, Varano M. Long-term functional and morphologic retinal changes after ranibizumab and photodynamic therapy in myopic choroidal neovascularization. *Retina*. 2014;34:2053-2062.
35. Grunwald JE, Daniel E, Huang J, et al. Risk of geographic atrophy in the comparison of age-related macular degeneration treatments trials. *Ophthalmology*. 2014;121:150-161.
36. Grunwald JE, Pistilli M, Ying GS, Maguire MG, Daniel E, Martin DE. Growth of geographic atrophy in the comparison of age-related macular degeneration treatments trials. *Ophthalmology*. 2015;122:809-816.
37. Sarks J, Tang K, Killingsworth M, Arnold J, Sarks S. Development of atrophy of the retinal pigment epithelium around disciform scars. *Br J Ophthalmol*. 2006;90:442-446.
38. Saint-Geniez M, Kurihara T, Sekiyama E, Maldonado AE, D'Amore PA. An essential role for RPE-derived soluble VEGF in the maintenance of the choriocapillaris. *Proc Natl Acad Sci U S A*. 2009;106:18751-18756.
39. Ford KM, Saint-Geniez M, Walshe T, Zahr A, D'Amore PA. Expression and role of VEGF in the adult retinal pigment epithelium. *Invest Ophthalmol Vis Sci*. 2011;52:9478-9487.
40. McLeod DS, Grebe R, Bhutto I, Merges C, Baba T, Luty GA. Relationship between RPE and choriocapillaris in age-related macular degeneration. *Invest Ophthalmol Vis Sci*. 2009;50:4982-4991.
41. Hanhart J, Tiosano L, Averbukh E, Banin E, Hemo I, Chowers I. Fellow eye effect of unilateral intravitreal bevacizumab injection in eyes with diabetic macular edema. *Eye*. 2014;28:646-653.
42. Chakravarthy U, Harding SP, Rogers CA, et al. Alternative treatments to inhibit VEGF in age-related choroidal neovascularisation: 2-year findings of the IVAN randomised controlled trial. *Lancet*. 2013;382:1258-1267.
43. Lois N, McBain V, Abdelkader E, Scott NW, Kumari R. Retinal pigment epithelial atrophy in patients with exudative age-related macular degeneration undergoing anti-vascular endothelial growth factor therapy. *Retina*. 2013;33:13-22.
44. Cho HJ, Yoo SG, Kim HS, et al. Risk factors for geographic atrophy after intravitreal ranibizumab injections for retinal angiomatous proliferation. *Am J Ophthalmol*. 2015;159:285-292.
45. Tanaka E, Chaikitmongkol V, Bressler SB, Bressler NM. Vision-threatening lesions developing with longer-term follow-up after treatment of neovascular age-related macular degeneration. *Ophthalmology*. 2015;122:153-161.