

The Ocular Glymphatic System and Idiopathic Intracranial Hypertension: Author Response to “Hypodense Holes and the Ocular Glymphatic System”

The proposal that there exists a paravascular transport system within the eye, similar and likely continuous with the glymphatic system in the central nervous system (CNS), is an exciting development with implications to the pathogenesis of a number of common ocular diseases, and one that may

open up new targets for treatment. We are delighted to see in this most recent correspondence how Wostyn and colleagues¹ present further evidence to support the existence of such a system in the optic nerve and its potential relevance to the pathogenesis of glaucoma. Building on our initial hypothesis reported in *Investigative Ophthalmology & Visual Science*,² we have now made important progress in identifying its relevance to another sight-threatening condition with a fluid-dynamic component, idiopathic intracranial hypertension (IIH). We believe that these observations corroborate the most recent findings of Wostyn and colleagues,¹ and provide

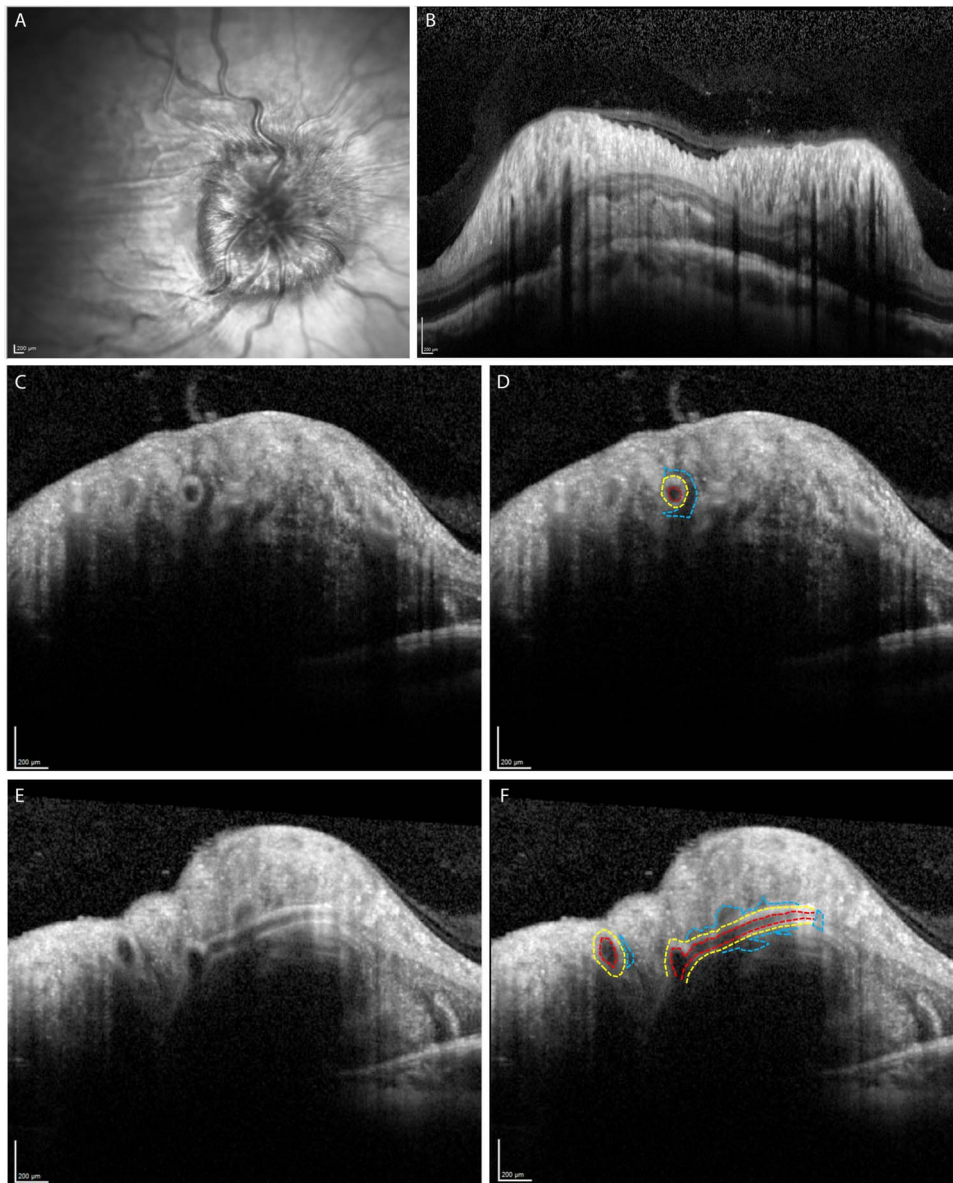


FIGURE 1. Imaging for a patient with Frisen grade 3 papilloedema secondary to idiopathic intracranial hypertension. (A) Infrared image of the swollen optic disc. (B) Spectral-domain (SD) OCT retinal nerve fibre layer (RNFL) scan showing the retinal vessels with a dark area of penumbra around them. (C) Spectral-domain OCT cross-section through the optic nerve head. The central vessel has a thickened wall with a hyporeflective area superiorly, nasally and inferiorly. (D) The image shown in (C) is highlighted to demarcate the vessel lumen (red), vessel wall (yellow), and the paravascular hyporeflective area (blue). (E, F) Additional SD-OCT cross-section showing two transverse sections and one longitudinal section, with (F) highlighting key features as previously.

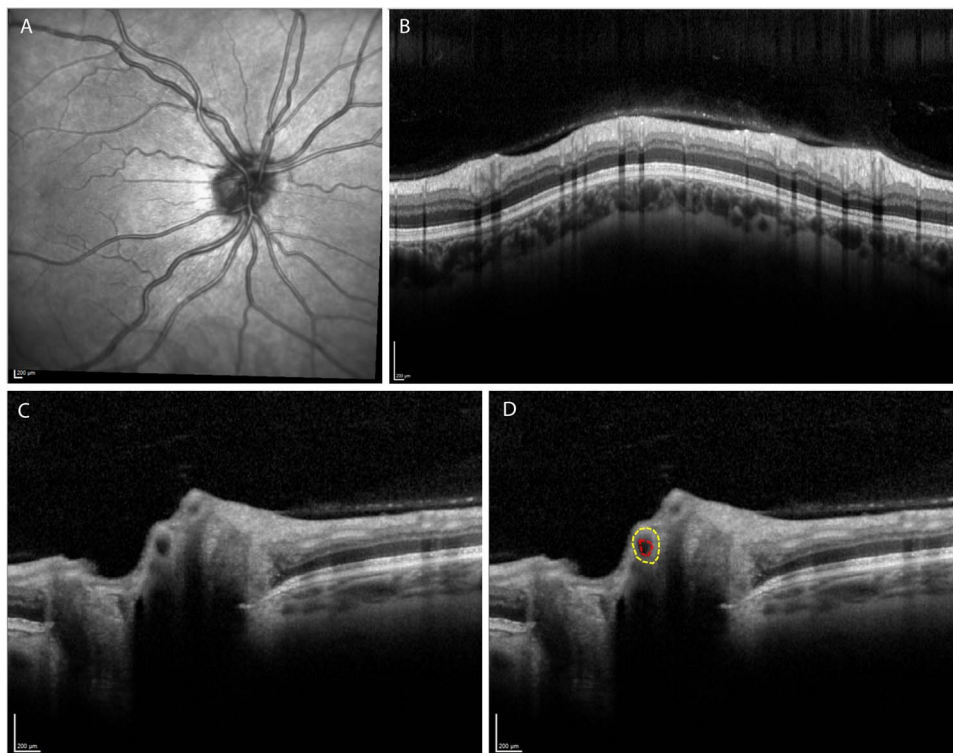


FIGURE 2. Imaging for a healthy individual (control). (A) Infrared image of the optic disc, showing normal appearance with no papilloedema; (B) SD-OCT RNFL scan. (C) Spectral-domain OCT cross-section showing the central retinal vessels as they emerge at the optic nerve head. (D) The image shown in (C) is highlighted to demarcate the vessel lumen (red) and wall (yellow); note that no paravascular hyporeflective area is seen in this case or any of our other healthy control patients.

further support for the importance of the glymphatic system across a range of important eye diseases.

In this most recent correspondence, Wostyn and colleagues¹ report on the presence of paravascular “black holes” in the optic nerve vasculature in patients with glaucoma. We too have identified these features, but in patients with papilloedema secondary to raised intracranial pressure. We can report here that systematic spectral-domain OCT imaging of our cohort of patients with IIH has revealed a number of structural differences not seen in healthy controls, including the presence of these “black holes.”

In papilloedema, it is evident there is increased thickness of both the arterial and venous wall diameter (Fig. 1). This appears to have an increased hyperreflectivity in the whole circumference of the vessel wall. This is different to observations in healthy eyes where there is only increased reflectivity seen above and below the cross section of the vessels.³ However, the most striking feature is the size of the “black hole” noted as a hyporeflective (darkened) perivascular penumbra around the vessel wall (Fig. 1). We hypothesize that this represents dilated ocular perivascular glymphatic channels occurring as a result of raised intracranial pressure. This can be observed both at the optic nerve head and within the retinal nerve fiber layer scan (Figs. 1B–E). There appears to be a relationship between the degree of papilloedema and the extent of the changes observed. In those without papilloedema we do not observe these features (Fig. 2).

In the setting of raised intracranial pressure, what we observe at the optic nerve head may be analogous to what has been described in the brain. Papayannis et al.⁴ observed enlarged perivascular glymphatic spaces associated with raised intracranial pressure in hydrocephalus possibly as a result of

stasis in the extracellular fluid. Local inflammation, with resultant increased vascular permeability may also drive expansion of the perivascular spaces akin to what is described in the central nervous system in traumatic brain injury⁵

Ocular perivascular glymphatic channels may, in part, be relevant in explaining the delayed visual dysfunction that we see in chronic papilloedema in IIH. We speculate that over time the accumulation of toxic metabolites in these ocular glymphatic perivascular channels due to stasis, may cause axonal loss and impact optic nerve function.⁶

Quantification of these observations seen in papilloedema would be of interest. Furthermore, prospective evaluation of the changes in these parameters observed over the clinical course of papilloedema and relating this to visual outcome would be potentially instructive.

Alastair K. Denniston^{1,2}

*Pearse A. Keane*³

*Anuriti Aojula*⁴

*Alex J. Sinclair*⁵

Susan P. Mollan^{4,5}

¹Department of Ophthalmology, Queen Elizabeth Hospital Birmingham, University Hospitals Birmingham NHS Foundation Trust, Birmingham, United Kingdom; ²Institute of Inflammation and Ageing, University of Birmingham, Birmingham, United Kingdom; ³NIHR Biomedical Research Centre for Ophthalmology, Moorfields Eye Hospital NHS Foundation Trust and UCL Institute of Ophthalmology, London, United Kingdom; ⁴Birmingham Neuro-Ophthalmology Unit, Department of Ophthalmology, Queen Elizabeth Hospital Birmingham, University Hospitals Birmingham NHS Foundation Trust, Birmingham, United Kingdom; and the ⁵Institute of Metabolism and Systems

Research, University of Birmingham, Birmingham, United Kingdom.
E-mail: a.denniston@bham.ac.uk

References

1. Wostyn P, De Groot V, Van Dam D, Audenaert K, De Deyn PP, Killer HE. "Hypodense holes" and the ocular glymphatic system: author response: "black holes" and the ocular glymphatic system *Invest Ophthalmol Vis Sci.* 2017;58:1132-1133.
2. Denniston AK, Keane PA. Paravascular pathways in the eye: is there an 'ocular glymphatic system'? *Invest Ophthalmol Vis Sci.* 2015;56:3955-3956.
3. Ouyang Y, Shao Q, Scharf D, Jousseaume AM, Heussen FM. An easy method to differentiate retinal arteries from veins by spectral domain optical coherence tomography: retrospective, observational case series. *BMC Ophthalmol.* 2014;14:66.
4. Papayannis CE, Saidon P, Rugilo CA, et al. Expanding Virchow Robin spaces in the midbrain causing hydrocephalus. *AJNR Am J Neuroradiol.* 2003;24:1399-1403
5. Inglese M, Bomsztyk E, Gonen O, Mannon LJ, Grossman RI, Rusinek H. Dilated perivascular spaces: hallmarks of mild traumatic brain injury. *AJNR Am J Neuroradiol.* 2005;26:719-724.
6. Bakker EN, Bacskai BJ, Arbel-Ornath M, et al. Lymphatic clearance of the brain: perivascular, paravascular and significance for neurodegenerative diseases. *Cell Mol Neurobiol.* 2016; 36:181-194.

Citation: *Invest Ophthalmol Vis Sci.* 2017;58:1134-1136.
doi:10.1167/iovs.17-21479