

Choriocapillaris Flow in Myopia

I read with interest the article “Quantitative OCT Angiography of the Retinal Microvasculature and the Choriocapillaris in Myopic Eyes” by Al-Sheikh et al.¹ In this article, the authors stated that they obtained a 10- μm -thick slab containing the choriocapillaris, thresholded this by the Otsu’s method, and then counted the number of areas with no flow signal, which they called flow voids. (These areas have also been called signal voids.) The authors calculated the mean defect was 20 pixels and used that as a cutoff. They then calculated mean values for the flow voids above 20 pixels. In addition, they stated they used the Kolmogorov-Smirnov test to evaluate the normal distribution. The results presented did not seem to abide by what has been published before.²⁻⁴ I took the liberty of analyzing the images they showed in their Figure 1 to gain further insight into possible reasons for any observed differences.

The image of the choriocapillaris and the segmentation thickness is shown in Figure 1A. The fovea measured 85 pixels thick, and the distance between the two segmentation lines in the choroid was 13 pixels. Assuming a fovea thickness of 240 μm , the distance between the two segmentation lines would be approximately 37 μm . Using a different estimate of the foveal thickness anywhere near the physiologic range would not produce a separation of the segmentation lines of 10 μm .

Perhaps the authors made a mistake in preparing Figure 1 compared with the acquisition of the data in the first place. In addition, the segmentation slab does not fit the curve of the RPE/Bruch’s membrane on the far left and right sides of the scan (arrows). It is common to have segmentation errors in high myopes.

I then used the choriocapillaris image provided, rescaled it to 304×304 pixels, and masked out the overlays shown in the image (Fig. 1B). I used Otsu’s method as per the authors. It is important to deselect the box “white objects on a black background” in the FIJI program (<http://imagej.nih.gov/ij/>; provided in the public domain by the National Institutes of Health, Bethesda, MD, USA) so that the signal voids are thresholded. The authors did not mention whether they took this step. The image was analyzed with the count particles command. The resultant data was analyzed in Excel (Microsoft Corporation, Redmond, WA, USA) and IBM-SPSS (version 21; IBM Corporation, New York, NY, USA). The sizes of the flow voids ranged from 1 to more than 50,000 pixels, and a graph of number of flow voids was highly skewed (Fig. 1C). There were 308 signal voids of any size, of which 272 were 20 pixels or smaller. Thus, more than 88% of the signal voids would be excluded by the requirement to use only those greater than 20 pixels, which is an arbitrary cutoff that has no imaging or physiologic justification. Previous studies have shown that there is a power law relationship between the flow void size

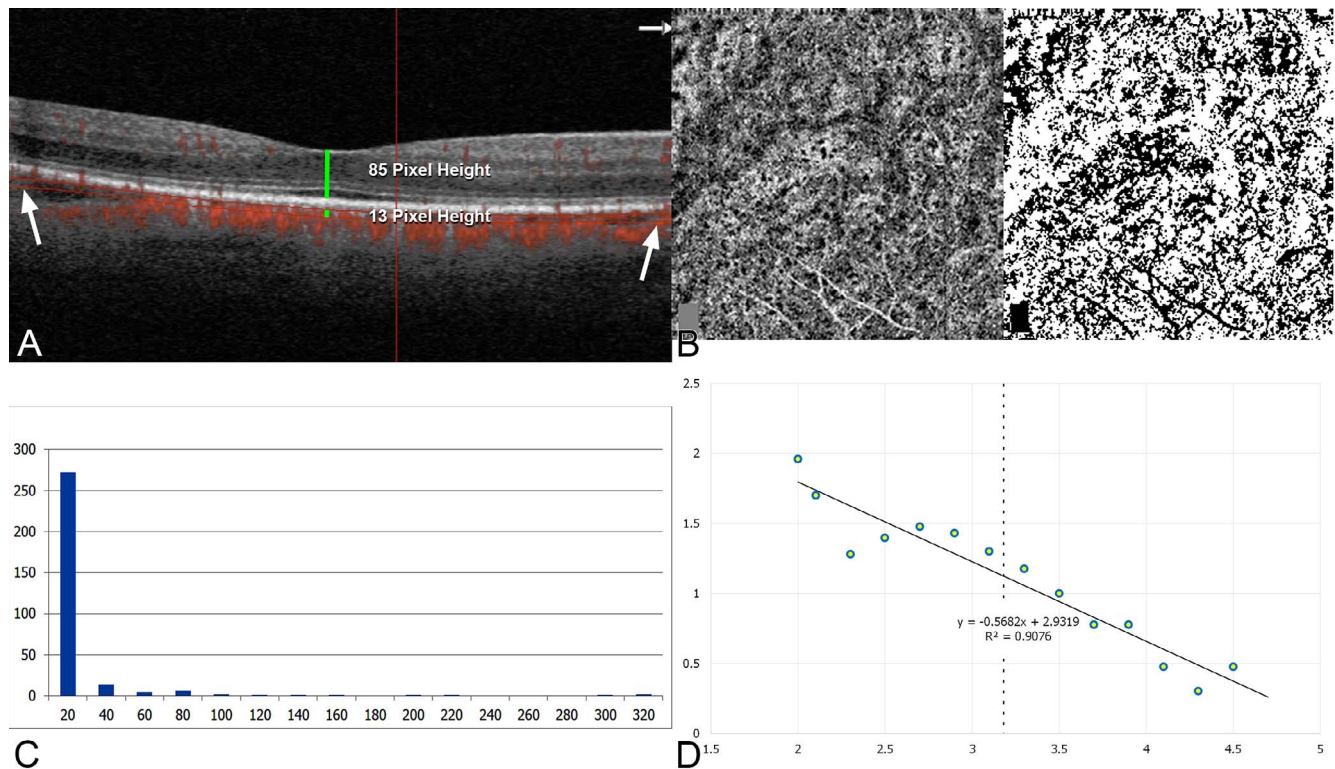


FIGURE 1. Reanalysis of images presented in reference 1. (A) The foveal thickness was 85 pixels, and the segmentation slab, stated to be 10 μm thick, measured 13 pixels thick. By similar proportions, a fovea thickness in the physiologic range would suggest a slab thickness more than three times what the authors stated. Note the segmentation defects at the sides of the image (arrows). (B) Left is the image from Figure 1 of the choriocapillaris with the overlays masked in neutral gray. Right is the segmentation following the Otsu method as per the authors. (C) The number of flow voids as binned in 20 pixel increments shows a highly skewed distribution. The graph stops at 320 pixels, although there were voids much larger than this. (D) When the log flow voids were plotted against the log of the size of the flow voids, a linear relationship was seen. The dashed line shows the cutoff used by the authors.



and number. To evaluate this possibility, a log-log graph was made (Fig. 1D), which showed a linear relationship between the variables ($R^2 = 0.91$). This implies the underlying relationship is consistent with a power law relationship. This is inconsistent with the idea that the data are normally distributed. I analyzed the flow voids above 20 pixels in size as per the authors' methods and found the null hypothesis, that the distribution is normal, was rejected with $P < 0.001$ using the Kolmogorov-Smirnov test. Perhaps the other patients analyzed by the authors do follow a normal distribution, but that would be not in keeping with other reported subjects and the authors' own Figure 1.

Calculating mean sizes doesn't make much sense from a mathematical standpoint because the underlying distribution is so skewed. A clue to this is the data are bounded on the lower side, and the SD is many times greater than the mean. As such, the larger flow voids sizes contained in the authors' own data essentially would be statistically impossible. A similar analysis of the mean and SDs of cities in the United States would show cities the size of New York or Los Angeles for all practical purposes are statistically impossible, as the number versus population relationship in cities follows a power law curve.^{5,6}

The idea that the choriocapillaris is not the same as in normal eyes was shown in animal models by Hirata and Negi.⁷ We certainly can see a difference by simple inspection of OCT angiograms. However, forcing data that are clearly not normally distributed into an analysis that makes an assumption of a normal distribution is not a way to prove this. Easy often is not correct. The plot of the data and the Kolmogorov-Smirnov test highlight the challenges posed by the data distribution. Computing a mean implies a central tendency, but this is not applicable to highly skewed distributions of which a power law relationship is just one example. There is no typical value as is implied by a mean, and there is no symmetric proportion of the population of flow void sizes around a central measure either.

The final two comments concern thresholding. Otsu's method seeks to maximize interclass variance. The inherent assumption is that there are two classes of pixels: those belonging to the object of interest and the rest belonging to the background.⁸ Thus, there is a bimodal curve of gray scale values, and Otsu's method uses a discriminant criterion to optimally separate the two peaks. However, if the grayscale histogram of Optovue's output is inspected, for most patients there is only one peak, generally centered in the middle of the histogram. This has two implications. First, although the method is robust, the underlying data do not meet the assumptions underlying Otsu's method. Second, and more importantly, to get a relatively uniform histogram output for varying patients, there is an implication that Optovue's software modifies the grayscale values, perhaps to make them more uniform or to fit in a specific range. If this is true, comparisons between patients may not be accurate, because we do not know the processing used in Optovue's software.

Although it was not mentioned in my papers,²⁻⁴ this is the reason I did not use a similar metric.

In summary, the segmentations used by the authors should be clarified because the one shown in their Figure 1 is incorrect in two different ways, the distributions of the flow voids are not normally distributed as suggested by the authors, and the cutoff of 20 pixels has no justification based in biology, mathematics, or physics, establishing that value by calculating a mean does not make sense, and the mathematical treatment of the resultant data was incorrect in multiple ways.

Richard F. Spaide

Vitreous, Retina, Macula Consultants of New York, New York, New York, United States.

E-mail: rickspaide@gmail.com

Acknowledgments

Supported by the Macula Foundation, New York, NY, USA.

Disclosure: **R.F. Spaide**, Topcon Medical Systems (C), Heidelberg Engineering (C), DORC (C)

References

1. Al-Sheikh M, Phasukkijwatana N, Dolz-Marco R, et al. Quantitative OCT angiography of the retinal microvasculature and the choriocapillaris in myopic eyes. *Invest Ophthalmol Vis Sci*. 2017;58:2063-2069.
2. Spaide RF. Choriocapillaris flow features follow a power law distribution: implications for characterization and mechanisms of disease progression. *Am J Ophthalmol*. 2016;170:58-67.
3. Spaide RF. Choriocapillaris signal voids in maternally inherited diabetes and deafness and in pseudoxanthoma elasticum. [published online ahead of print January 3, 2017]. *Retina*. doi:10.1097/IAE.0000000000001497.
4. Spaide RF. Ising model of choriocapillaris flow. [published online ahead of print February 6, 2017]. *Retina*. doi:10.1097/IAE.0000000000001517.
5. Bak P. *How Nature Works: The Science of Self-Organised Criticality*. New York, NY: Copernicus Press; 1996.
6. Barabási AL. *Linked*. Cambridge, MA: Perseus Publishing; 2002.
7. Hirata A, Negi A. Morphological changes of choriocapillaris in experimentally induced chick myopia. *Graefes Arch Clin Exp Ophthalmol*. 1998;36:132-137.
8. Otsu N. A threshold selection method from gray-level histograms. *IEEE Trans Sys Man Cyber*. 1979;9:62-66.

Citation: *Invest Ophthalmol Vis Sci*. 2017;58:3563-3564.
doi:10.1167/iovs.17-22042