

Choroidal Structural Changes Correlate With Neovascular Activity in Neovascular Age Related Macular Degeneration

Alessandro Invernizzi,^{1,2} Eleonora Benatti,³ Mariano Cozzi,¹ Stefano Erba,¹ Shiva Vaishnavi,⁴ Kiran Kumar Vupparaboina,⁴ Giovanni Staurengi,¹ Jay Chhablani,⁴ Mark Gillies,² and Francesco Viola³

¹Eye Clinic, Department of Biomedical and Clinical Science “Luigi Sacco”, Luigi Sacco Hospital, University of Milan, Milan, Italy

²Save Sight Institute, Sydney Eye Hospital, University of Sydney, Sydney, Australia

³Department of Clinical Sciences and Community Health, University of Milan, Ophthalmological Unit, IRCCS-Cà Granda Foundation – Ospedale Maggiore Policlinico, Milan, Italy

⁴L V Prasad Eye Institute, Hyderabad, India

Correspondence: Alessandro Invernizzi, Eye Clinic, Department of Biomedical and Clinical Science “Luigi Sacco,” Luigi Sacco Hospital, University of Milan, Via G.B. Grassi 74, 20157 Milan, Italy; alessandro.invernizzi@gmail.com.

Submitted: January 26, 2018

Accepted: May 30, 2018

Citation: Invernizzi A, Benatti E, Cozzi M, et al. Choroidal structural changes correlate with neovascular activity in neovascular age related macular degeneration. *Invest Ophthalmol Vis Sci*. 2018;59:3836–3841. <https://doi.org/10.1167/iovs.18-23960>

PURPOSE. To correlate changes in choroidal thickness and vascularity index with disease activity in patients with neovascular age-related macular degeneration (nAMD).

METHODS. Eyes diagnosed with AMD that had two sequential visits within 12 months and that had no choroidal neovascularization (CNV) or had inactive CNV at the first visit were included. Those that had active CNV at follow-up were enrolled as cases. Eyes that did not develop a CNV or that were still inactive at the second visit were enrolled as controls. Disease activity was based on optical coherence tomography (OCT) and fluorescein angiography findings. Subfoveal choroidal thickness (SCT), mean choroidal thickness (MCT), and choroidal vascularity index (CVI) were assessed on enhanced depth imaging OCT and compared between the baseline and follow-up visit. Subgroup analysis accounting for lesion type and previous treatment, if any, were performed.

RESULTS. Sixty-five eyes from 60 patients (35 females) and 50 age- and sex-matched controls were included. At the active visit, cases had an increase from $164 \pm 67 \mu\text{m}$ to $175 \pm 70 \mu\text{m}$ in mean \pm SD SCT and from $144 \pm 45 \mu\text{m}$ to $152 \pm 45 \mu\text{m}$ in MCT (both $P < 0.0001$). The mean CVI also increased at from $54.5\% \pm 3.3\%$ to $55.4\% \pm 3.8\%$ ($P = 0.04$). Controls did not show significant changes in choroidal measurements between the two visits. Mean SCT, MCT, and CVI values were similar for previously treated and treatment-naïve eyes.

CONCLUSIONS. Choroidal thickness and CVI significantly increased with active disease in nAMD eyes. Changes in choroidal thickness may predict CNV development or recurrence before they are otherwise evident clinically.

Keywords: choroid, neovascular age related macular degeneration, EDI-OCT, choroidal vascularity index, CNV activity

The blood flow within the choroid is influenced by several physiological processes and pathological conditions.^{1,2} An increase in choroidal flow may be due to purely mechanical processes induced by systemic hemodynamic changes or from a local response to various locally or systemically generated chemical stimuli.³

A strong correlation exists between ageing and choroidal thinning, most likely due to progressive loss of tissue and vascular narrowing.⁴ This process, along with the reduced Bruch's membrane permeability that is found with increasing age, impairs the oxygen supply to the retina.⁵ Retinal and retinal pigment epithelial cells release vascular endothelial growth factor (VEGF) to dilate the choroidal vessels and increase the blood flow, but this may also lead to choroidal neovascularization (CNV).^{6–8} The association of intraocular VEGF levels and choroidal blood flow is further supported by the choroidal thinning that is detected in eyes receiving intravitreal anti-VEGF therapy for neovascular age-related macular degeneration (nAMD).^{9,10}

Choroidal thickening may, therefore, occur in the active phase of nAMD due to increased levels of VEGF and other proinflammatory factors together with hydrostatic variation in the blood flow within the newly formed vessels.¹¹ We propose that choroidal thickness might be a useful marker to predict the development of new CNV or reactivation of CNVs which have been rendered inactive with treatment, before they are otherwise evident clinically.

The aim of this study was to correlate changes in choroidal thickness and vascularity index, a reliable method to calculate the ratio between the intravascular space and the choroidal stroma,^{6,12} with disease activity in patients with nAMD.¹³

MATERIALS AND METHODS

The clinical records from patients diagnosed with intermediate AMD (drusen and retinal pigment epithelium mottling only) or nAMD and followed at two tertiary centers in the north of Italy (Eye Clinic, Luigi Sacco Hospital, University of Milan, and



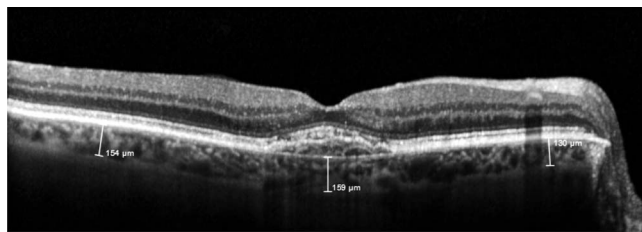


FIGURE 1. Choroidal thickness analysis in a patient with inactive CNV due to nAMD. Choroidal thickness was assessed with the OCT software (Eye Explorer version 1.9.10.0, Heidelberg Engineering) embedded caliper tool at three different locations: underneath the fovea, 3 mm nasally, and 3 mm temporally. The central measurement was considered in the analysis as SCT, whereas the mean of the three measurements was calculated to obtain an averaged measure of the choroidal thickness across the posterior pole (MCT).

Ophthalmological Unit, IRCCS-Cà Granda Foundation-Ospedale Maggiore Policlinico, Milan) between January 2015 and December 2016 were reviewed. Institutional Review Board/Ethics Committee approval was obtained for the study prior to its commencement. The study adhered to the tenets of the Declaration of Helsinki.

Eyes had to have two consecutive visits within 12 months with no signs of neovascular activity at the first visit (baseline) to be included. Absence of neovascular activity was defined as no history of CNV (i.e., drusen or retinal pigment epithelium only) or presence of a CNV that had received no treatment for 3 months and still had no signs of activity on OCT (no intraretinal/subretinal fluid) and on fundus fluorescein angiography (no leakage or blood). The 3-month interval was established on the basis of the pharmacokinetics of anti-VEGF agents in the eye¹⁴ and the levels of circulating VEGF following intravitreal anti-VEGF treatments¹⁵ in order to minimize drugs effect on the choroid.

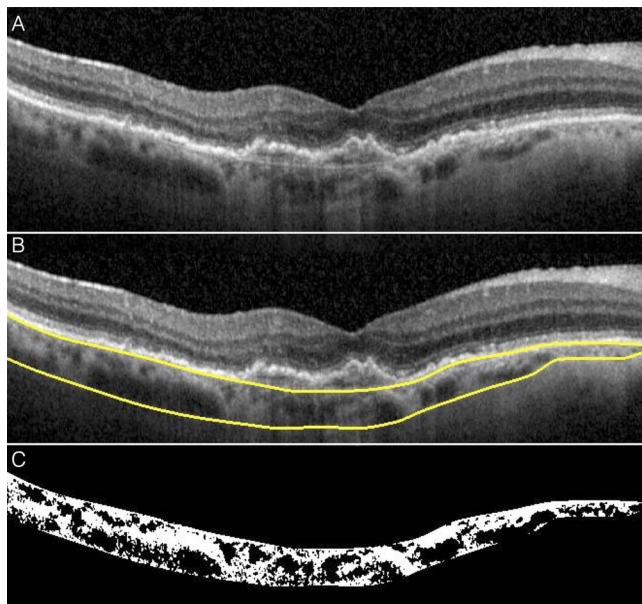


FIGURE 2. CVI calculation in a patient affected by AMD. Multimodal images were exported from the Eye Explorer Software and cropped in order to obtain single EDI-OCT scans (A). Choroidal boundaries were automatically identified (yellow lines). Manual corrections were applied in case of segmentations artifacts (B). The selected part of the image, corresponding to the choroid, was then binarized (C). This process allowed to calculate a black/white ratio representing the CVI.

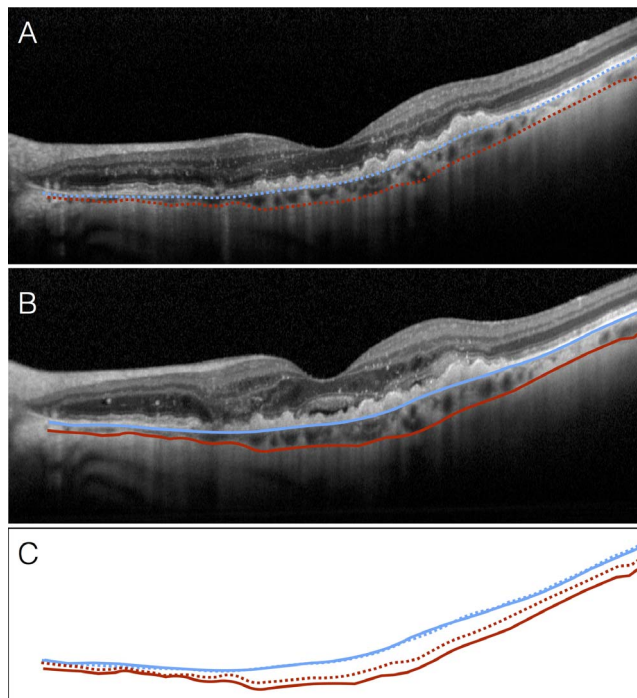


FIGURE 3. Choroidal thickness changes in a patient affected by nAMD at different phases of disease activity. At baseline (A) the disease appears inactive. The inner choroidal boundary (Bruch's membrane) is marked with a blue dotted line. The outer choroidal boundary (choroido-scleral interface) is marked with a red dotted line. At follow-up visit (B) subretinal and intraretinal fluid is visible as a sign of active disease. At this time the inner and outer choroidal boundaries are marked with a blue and a red continuous line, respectively. In a graphic representation overlapping the lines tracked along the Bruch's membrane at baseline and follow-up visit (C), it is evident how the red continuous line representing the outer boundary of the choroid during the active stages of the disease lays underneath the baseline one. The gap between the two corresponds to the choroidal thickening occurred along with the choroidal neovascular membrane reactivation.

Eyes that developed a new CNV or showed a re-activation of the pre-existing CNV (activity was defined as presence of fluid on OCT and/or leakage or blood on fundus fluorescein angiography) at the second visit (follow-up) were enrolled as cases. Eyes that were still inactive at follow-up visit were enrolled as controls.

The patients had to have the same (true-track based) enhanced depth optical coherence tomography (EDI-OCT) horizontal single line scan (Heidelberg Engineering, Heidelberg, Germany) encompassing the fovea at inactive and active disease visits to be included. EDI-OCT images were collected all between 9.00 AM and 12.00 AM as part of the standard clinical evaluation, thus limiting the effect of circadian rhythm on choroidal thickness.¹

EDI-OCT images were used to perform two different evaluations of the choroid: choroidal thickness analysis and choroidal vascularity index (CVI) calculation.

Choroidal thickness was assessed by two independent skilled operators (EB and MC) with the OCT software (Eye Explorer version 1.9.10.0, Heidelberg Engineering) embedded caliper tool at three different locations: underneath the fovea, 3 mm nasally, and 3 mm temporally (Fig. 1). Interobserver agreement was calculated, and measurements from the first operator (EB) were used for the study analysis.

The CVI, defined as the ration of luminal area an total choroidal area, was calculated using a previously described

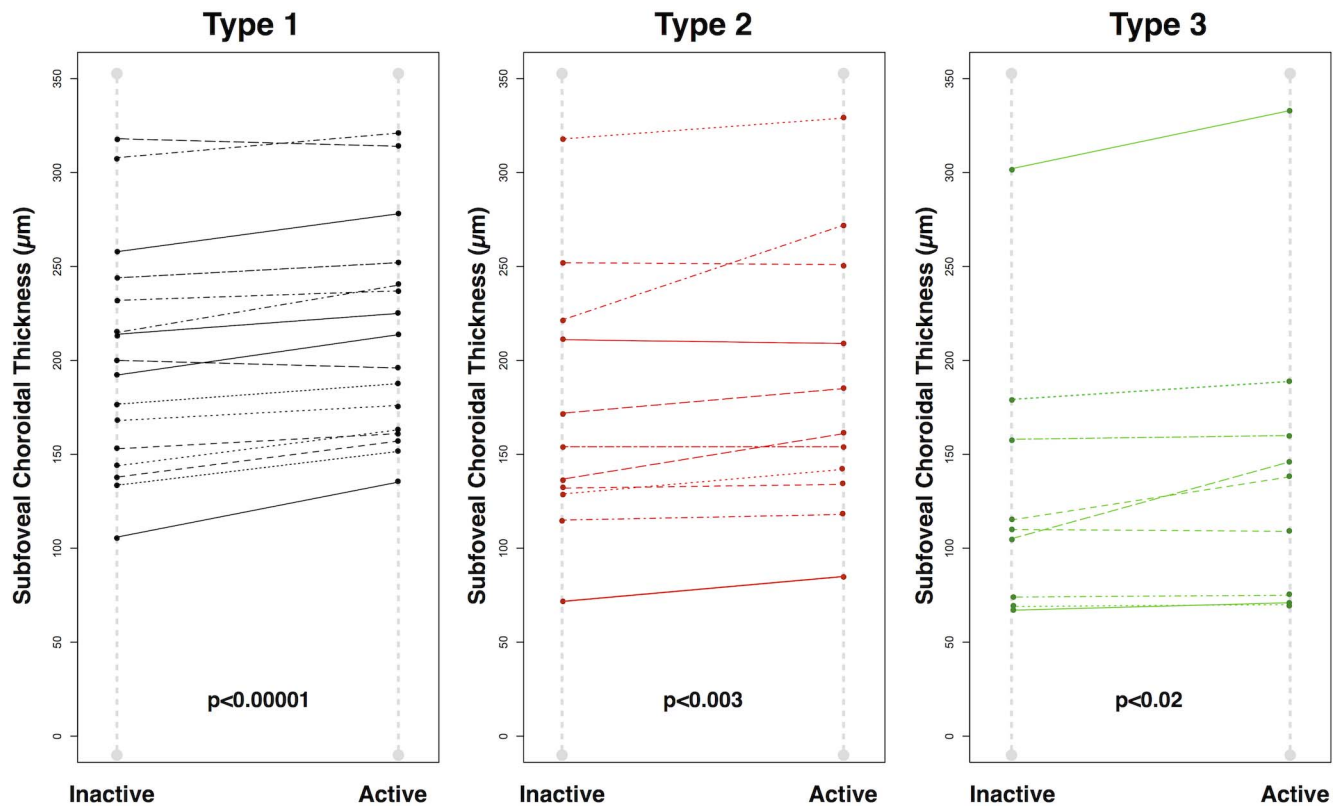


FIGURE 4. Graphical representation of SCT change according to disease activity in patients affected by AMD divided by lesion type. SCT (mean \pm SD) significantly increased in the entire population from $164 \pm 67 \mu\text{m}$ to $175 \pm 70 \mu\text{m}$ on average ($P < 0.0001$). Subgroup analysis based on lesion type showed a significant increase in SCT in all three groups with CNVs type 1 having the most significant increase.

algorithm.¹⁶ Briefly, choroidal stroma and vessel area analysis involved (1) automated binarization of a high definition horizontal 6-mm OCT B-scan and (2) automated segmentation of the binarized choroid layer as reported previously. The task of automated binarization in turn involved (a) preprocessing, (b) exponential and nonlinear enhancement, and (c) thresholding (Fig. 2).

Measurements were performed on the images collected at inactive and active stage and then compared with each other. Patients were subsequently grouped according to CNV type (classified into type 1, type 2, or type 3 according to fundus fluorescein angiography (FFA) and OCT appearance).^{17,18} Minimally classic CNVs were grouped into type 1 lesions, whereas predominantly classic were considered as type 2. Treatment previously received was also recorded (treatment naïve, ranibizumab, aflibercept) for further subanalysis.

Statistical Analysis

Interobserver agreement for choroidal thickness measurements was assessed using an intraclass correlation coefficient (ICC). Mean choroidal thickness (MCT; average of the three measurements), subfoveal choroidal thickness (SCT), and CVI values were compared between baseline and follow-up visits by paired *t*-test both in cases and controls. The same analysis was performed in each CNV type subgroup and in pretreatment-based subgroups.

MCT, SCT, and CVI at baseline (inactive) and follow-up (active) visits were compared among the patients diagnosed with different CNV types in the cases group through pairwise comparisons. The same analysis was also performed to compare patients who had received different treatments. The

possible effect of time interval between the two visits on the change in choroidal measurements was tested using linear regression model.

Both eyes of the same patient could be enrolled in the study in case they both met the inclusion criteria. For this reason, the entire analysis was repeated after one of the two eyes from each of the subject that contributed with both eyes had been randomly excluded. Statistical analysis was performed using R statistical package version 3.3.1 (R Project—The R Foundation for Statistical Computing; <http://www.R-project.org>). A *P* value < 0.05 was considered to be statistically significant.

RESULTS

Sixty-five eyes from 60 patients (35 females) were included in the study as cases. The mean \pm standard deviation (SD) age was 80.5 ± 6.4 (range, 66–93) years. There were 32 type 1, 17 type 2, and 16 type 3 CNV lesions. At the designated inactive visits, 22 eyes had intermediate dry AMD with no history of CNV. Among the 43 that had a CNV with no sign of activity, 34 had previously received ranibizumab and nine had received aflibercept.

The control group comprised 50 patients (28 females), mean age 78.8 ± 7.2 (range, 60–95) years. In this group, 27 had no sign of CNV (drusen and retinal pigment epithelium mottling only) and 23 had inactive CNV at both visits.

The ICC for interobserver agreement for choroidal thickness measurements was 0.89 (confidence interval, 0.86–0.90).

In the cases group, the baseline (inactive) visit mean \pm SD SCT was $164 \pm 67 \mu\text{m}$ and mean \pm SD MCT was $144 \pm 45 \mu\text{m}$. These measurements increased to $175.1 \pm 70 \mu\text{m}$ and $152.3 \pm$

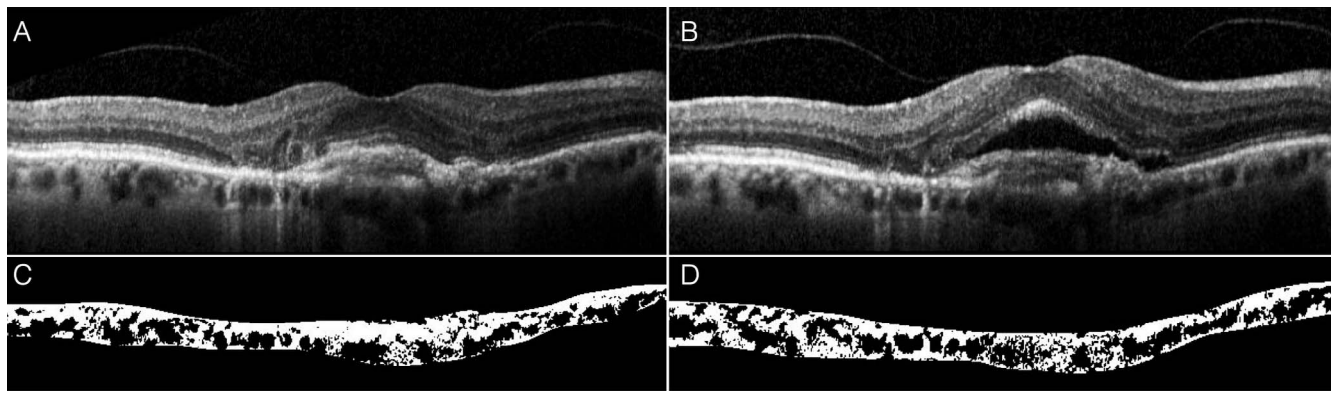


FIGURE 5. CVI changes in a patient affected by AMD during the inactive and active phases of the disease. Baseline EDI-OCT scan (A) showed the presence of an inactive CNV under the fovea. The EDI-OCT scan of the same patient during the follow-up visit demonstrating subretinal fluid as a sign of activity is reported (B). Corresponding binarized images of the choroid during the inactive (C) and the active/recurrent (D) stage of the disease are reported. CVI resulting from the ration between black/white pixels changed from 43% at baseline to 48% at follow-up examination.

45 μm , respectively, at the follow-up (active) visit (both $P < 0.0001$) (Figs. 3, 4; Supplementary Video S1). The mean \pm SD CVI also increased in the cases group from $54.5\% \pm 3.3\%$ in inactive eyes to $55.4\% \pm 3.8\%$ in active CNVs ($P = 0.04$) (Fig. 5). The same measurements did not change significantly from baseline to follow-up visit in the controls group. Detailed data about choroidal measurements at the baseline and follow-up visit in both cases and controls are presented in Table 1. The mean \pm SD interval between the baseline and the follow-up visit was 113 ± 68 (range, 28–328) days among the cases and 142 ± 75 (range, 52–350) in the controls. There was no significant effect of the time interval on the variation of any of the choroidal measurements (all $P > 0.45$).

There was no significant difference in terms of SCT, MCT, and CVI between treatment naïve, ranibizumab, or aflibercept treated patients (all $P > 0.05$) both at the inactive and active visits. Mean SCT and MCT significantly increased at the active visits regardless of whether or not eyes had received treatment before or which agent had been used if they had. CVI increased at the active visit in all the three treatment groups, but this change was only statistically significant for the treatment-naïve group ($P = 0.02$). Detailed data on choroidal measurements according to treatment previously received are presented in Table 2.

Type 3 lesions had a significantly thinner mean SCT and MCT compared with type 1 CNVs at both the inactive and active visits. There was no difference in CVI among the different lesions types. The change in SCT and MCT from inactive to active visits was statistically significant for all the three lesion types. Only type 1 lesions showed a significant increase in CVI from the inactive to the active visits ($P = 0.02$).

Detailed data on choroidal measurements according to CNV type are presented in Table 3.

The sensitivity analysis performed repeating the tests after removing one eye from each patient that contributed with both eyes to the study did not give significantly different results from the ones reported above.

DISCUSSION

In this study we analyzed changes in the choroid of eyes diagnosed with nAMD before and after the development or reactivation of CNV and in a group of control eyes that did not develop a CNV or that had a persistently inactive disease. We found that the presence of an active CNV was associated with an increase in SCT, MCT, and vascularity index regardless of the lesion type or whether or not the eye had been treated in the past. These changes were not seen in controls.

Several studies have reported choroidal thinning during anti-VEGF therapy.^{9,10,19} Kim et al.²⁰ demonstrated that, after the initial shrinkage caused by anti-VEGF treatment, the choroidal thickness progressively increases as the drug wears off and then thins again with further anti-VEGF administration. A recent study also demonstrated that eyes receiving anti-VEGF therapy with a pro re nata regimen 1 year after starting the treatment have thinner choroids compared with baseline.⁹ However, limited data are available on the choroidal changes occurring before an active CNV becomes clinically evident. Treatment naïve eyes in the present analysis had increased choroidal flow after the CNV had been diagnosed, whereas no changes in the choroidal measurements were identified in the eyes that did not

TABLE 1. Choroidal Measurements in Patients Diagnosed With nAMD With Inactive and Active Disease

Cases, $n = 65$	Inactive	Active	Change	<i>P</i> Value*
SCT, mean \pm SD	164 \pm 67 μm	175 \pm 70 μm	12 \pm 12 μm	<0.0001
MCT, mean \pm SD	144 \pm 45 μm	152 \pm 45 μm	10 \pm 8 μm	<0.0001
CVI, mean \pm SD	54.5% \pm 3.3%	55.4% \pm 3.8%	0.9% \pm 3.5%	0.04
Controls, $n = 50$	Baseline	Follow-up	Change	<i>P</i> Value*
SCT, mean \pm SD	175 \pm 70 μm	174 \pm 70 μm	−0.8 \pm 7 μm	0.42
MCT, mean \pm SD	156 \pm 44 μm	155 \pm 45 μm	−0.4 \pm 6 μm	0.63
CVI, mean \pm SD	55.8% \pm 3.4%	55.4% \pm 3.6%	−0.3% \pm 2.9%	0.58

Statistically significant *P* values are reported in bold.

* Paired *t*-test.

TABLE 2. Choroidal Measurements in Patients Diagnosed With nAMD With Inactive and Active Disease Divided by Previously Received Treatment

	Naïve, <i>n</i> = 22	Ranibizumab, <i>n</i> = 34	<i>P</i> Value*	Aflibercept, <i>n</i> = 9	<i>P</i> Value*	<i>P</i> Value†
Inactive SCT, mean ± SD	152 ± 49 μm	165 ± 73 μm	0.77	190 ± 79 μm	0.33	0.58
Active SCT, mean ± SD	163 ± 54 μm	175 ± 76 μm	0.81	206 ± 77 μm	0.27	0.46
<i>P</i> value‡	0.002	<0.0001		0.01		
Inactive MCT	138 ± 33 μm	145 ± 50 μm	0.81	154 ± 50 μm	0.63	0.86
Active MCT	147 ± 35 μm	153 ± 51 μm	0.89	164 ± 53 μm	0.62	0.78
<i>P</i> value‡	<0.0001	<0.0001		0.05		
Inactive CVI	52.7% ± 3.6%	55.49% ± 2.9%	0.08	54.9% ± 2.4%	0.20	0.88
Active CVI	54.9% ± 3.3%	55.7% ± 4.4%	0.74	55.5% ± 2.6%	0.92	0.98
<i>P</i> value‡	0.02	0.6		0.4		

Statistically significant *P* values are reported in bold.

* Pairwise comparisons analysis (*P* values are referred to comparisons with treatment naïve eyes).

† Pairwise comparisons analysis (*P* values are referred to comparisons with eyes that had been treated with ranibizumab).

‡ Paired *t*-test comparing inactive and active visit.

develop a CNV. This offers a new insight in the pathophysiology of the disease and in a possible role of choroidal parameters in the earlier diagnosis of CNV lesions.

We included eyes that had received anti-VEGF agents in the past for CNV. We prespecified a minimum 3 months treatment-free interval, based on the pharmacokinetics of the current VEGF inhibitors,¹⁴ before the inactive visit as an inclusion criterion to minimize the effect of pretreatment on our results. We did not find any difference in choroidal thickness at inactive or at active visits between treatment naïve patients and those that had previously received ranibizumab or aflibercept. Since it has been reported that VEGF inhibitors thin the choroid, it appears that the effect of previous treatment had worn off at the inactive (baseline) examination. These findings suggest that the choroidal thickening that we observed at the active visits depended more on the reactivation of the CNV rather than on a decrease in the concentration of the drug within the eye.

We performed three different measurements to assess the changes in the choroidal perfusion indirectly, all of which showed a significant increase from the inactive to the active visits. The subfoveal thickness measurement demonstrated the most significant shift during the active phase of the disease in the entire cohort. This might be expected, since most of the CNVs in nAMD are located within the central macula.²¹ The vasculature located in this area, as a consequence, experiences maximal exposure to the mechanical variations in the blood flow occurring within the newly formed vessels. The levels of inflammatory cytokines and VEGF are also likely to be highest close to the CNV. However, CVI and MCT reflect changes in the choroidal vasculature across the whole posterior pole and they

also increased when the CNV was active. We are unable to say whether the vascular changes involve just the area around the CNV or the entire choroid.¹²

We found significant choroidal thickening in all CNV types, but only type 1 lesions showed significant changes in CVI from the inactive to the active phase of the disease. Perhaps this is because the neovascular network of type 1 CNVs is beneath the RPE,¹⁷ which may limit the diffusion of inflammatory mediators and VEGFs toward the retina, thereby enhancing their concentration within the choroid.²² This speculation is supported by the fact that type 3 lesions showed less obvious changes compared to the other CNV types in all the choroidal parameters we assessed. In these eyes with type 3 CNV, the anastomosis between the retinal and the choroidal vasculature could in fact favor the drainage of blood through the retinal vessels, thereby decreasing cytokines levels and the vascular congestion within the choroid.²³

Reduced choroidal thickness has been reported in patients with type 3 lesions compared with age-matched controls.⁸ Interestingly, we found patients with type 3 CNVs had thinner choroids than the other CNV types regardless of the disease activity, which was statistically significant when comparing them to patients with type 1 CNVs. Patients developing type 3 lesions are usually older,²³ which might explain our finding since age and choroidal thickness are known to be negatively correlated.⁴ Choroidal hypo-perfusion has been previously reported in type 3 CNVs.²⁴ Hypo-perfusion would be expected to induce choroidal thinning, further supporting our findings.

Ahn et al.¹⁹ described a progressive thickening of the choroid before the CNV reactivation in a longitudinal study on

TABLE 3. Choroidal Measurements in Patients Diagnosed With nAMD With Inactive and Active Disease Divided by Lesion Type

	Type 1 CNV, <i>n</i> = 32	Type 2 CNV, <i>n</i> = 17	<i>P</i> Value*	Type 3 CNV, <i>n</i> = 16	<i>P</i> Value*	<i>P</i> Value†
Inactive SCT, mean ± SD	178 ± 71 μm	173 ± 66 μm	0.96	126 ± 43 μm	0.02	0.09
Active SCT, mean ± SD	189 ± 73 μm	184 ± 69 μm	0.95	137 ± 50 μm	0.03	0.12
<i>P</i> value‡	<0.0001	0.003		0.02		
Inactive MCT	153 ± 48 μm	150 ± 45 μm	0.97	120 ± 26 μm	0.04	0.12
Active MCT	160 ± 48 μm	161 ± 45 μm	0.99	126 ± 30 μm	0.03	0.06
<i>P</i> value‡	0.0007	0.0004		0.04		
Inactive CVI	54.6% ± 3.2%	55.2% ± 2.7%	0.82	53.4% ± 3.9%	0.46	0.26
Active CVI	56% ± 3.9%	54.8% ± 4.1%	0.57	54.9% ± 3.2%	0.66	0.99
<i>P</i> value‡	0.02	0.6		0.1		

Statistically significant *P* values are reported in bold.

* Pairwise comparisons analysis (*P* values are referred to comparisons with type 1 CNV).

† Pairwise comparisons analysis (*P* values are referred to comparisons with type 2 CNV).

‡ Paired *t*-test comparing inactive and active visit.

myopic CNVs treated with anti-VEGF. In our study we had only two time points when the choroid was measured and we did not find any effect of the time interval between the visits on the choroidal changes magnitude. A possible explanation is that the CNV had already reactivated when the second visit was performed in our study. As a consequence, the shift in the choroidal measurements was always measured at its peak with the increase not necessarily being directly correlated with the time to re-activation. A longitudinal study is needed to track progressive changes of the choroidal indices before the CNV reactivates.¹⁹

We wish to acknowledge several limitations of this study. Its retrospective nature limited the regularity of follow-up examinations, which were therefore not conducted at the same time. The relatively small sample size precluded a multivariate analysis that might have accounted for factors such as the patients' age or gender. Finally, the choroidal thickness was measured manually. Despite good interobserver agreement, this method can still be affected by the operator skills.

To conclude, we have demonstrated that the choroid increases in thickness as well as vascularity in patients with nAMD as CNV develop or reactivate. Choroidal thickening and increasing CVI reflect an increase in choroidal blood flow, which may have different causes. Further studies are needed to confirm our findings and to assess the possible role of choroidal changes as earlier predictors of new or reactivating CNV in nAMD.

Acknowledgments

Disclosure: **A. Invernizzi**, Allergan (R); **E. Benatti**, None; **M. Cozzi**, Zeiss (R), Heidelberg Engineering (R); **S. Erba**, None; **S. Vaishnavi**, None; **K.K. Vupparaboina**, None; **G. Staurenghi**, Novartis (C), Bayer (C), Heidelberg Engineering (C), Allergan (C), Genentech (R), Roche (R), Zeiss (R), Quantel (R), Boehringer (R), Centervue (R), Alcon (R), Optos (S), Optovue (S), P; **J. Chhablani**, None; **M. Gillies**, Bayer (C, R), Novartis (C, R), Allergan (C, R), Opthea (C, R); **F. Viola**, Novartis (R), Allergan (R), Bayer (R)

References

- Usui S, Ikuno Y, Akiba M, et al. Circadian changes in subfoveal choroidal thickness and the relationship with circulatory factors in healthy subjects. *Invest Ophthalmol Vis Sci*. 2012;53:2300-2307.
- Bill A, Sperber GO. Control of retinal and choroidal blood flow. *Eye (Lond)*. 1990;4:319-325.
- Delaey C, Van De Voorde J. Regulatory mechanisms in the retinal and choroidal circulation. *Ophthalmic Res*. 2000;32:249-256.
- Margolis R, Spaide RF. A pilot study of enhanced depth imaging optical coherence tomography of the choroid in normal eyes. *Am J Ophthalmol*. 2009;147:811-815.
- Bhutto I, Luty G. Understanding age-related macular degeneration (AMD): relationships between the photoreceptor/retinal pigment epithelium/Bruch's membrane/choriocapillaris complex. *Mol Aspects Med*. 2012;33:295-317.
- Koh LH, Agrawal R, Khandelwal N, Sai Charan L, Chhablani J. Choroidal vascular changes in age-related macular degeneration. *Acta Ophthalmologica*. 2017;95:e597-e601.
- Fujiwara T, Imamura Y, Margolis R, Slakter JS, Spaide RF. Enhanced depth imaging optical coherence tomography of the choroid in highly myopic eyes. *Am J Ophthalmol*. 2009;148:445-450.
- Yamazaki T, Koizumi H, Yamagishi T, Kinoshita S. Subfoveal choroidal thickness in retinal angiomatous proliferation. *Retina*. 2014;34:1316-1322.
- Yamazaki T, Koizumi H, Yamagishi T, Kinoshita S. Subfoveal choroidal thickness after ranibizumab therapy for neovascular age-related macular degeneration: 12-month results. *Ophthalmology*. 2012;119:1621-1627.
- Koizumi H, Kano M, Yamamoto A, et al. Short-term changes in choroidal thickness after aflibercept therapy for neovascular age-related macular degeneration. *Am J Ophthalmol*. 2015;159:627-633.
- Bhisitkul RB. Vascular endothelial growth factor biology: clinical implications for ocular treatments. *Br J Ophthalmol*. 2006;90:1542-1547.
- Wei X, Ting DSW, Ng WY, Khandelwal N, Agrawal R, Cheung CMG. Choroidal vascularity index: a novel optical coherence tomography based parameter in patients with exudative age-related macular degeneration. *Retina*. 2017;37:1120-1125.
- Agrawal R, Chhablani J, Tan KA, Shah S, Sarvaiya C, Banker A. Choroidal vascularity index in central serous chorioretinopathy. *Retina*. 2016;36:1646-1651.
- Niwa Y, Kakinoki M, Sawada T, Wang X, Ohji M. Ranibizumab and aflibercept: intraocular pharmacokinetics and their effects on aqueous VEGF level in vitrectomized and non-vitrectomized macaque eyes. *Invest Ophthalmol Vis Sci*. 2015;56:6501-6505.
- Avery RL, Castellarin AA, Steinle NC, et al. Systemic pharmacokinetics and pharmacodynamics of intravitreal aflibercept, bevacizumab, and ranibizumab. *Retina*. 2017;37:1847-1858.
- Vupparaboina KK, Nizampatnam S, Chhablani J, Richhariya A, Jana S. Automated estimation of choroidal thickness distribution and volume based on OCT images of posterior visual section. *Comput Med Imaging Graph*. 2015;46:315-327.
- Cohen SY, Creuzot-Garcher C, Darmon J, et al. Types of choroidal neovascularisation in newly diagnosed exudative age-related macular degeneration. *Br J Ophthalmol*. 2007;91:1173-1176.
- Olsen TW, Feng X, Kasper TJ, Rath PP, Steuer ER. Fluorescein angiographic lesion type frequency in neovascular age-related macular degeneration. *Ophthalmology*. 2004;111:250-255.
- Ahn SJ, Park KH, Woo SJ. Subfoveal choroidal thickness changes following anti-vascular endothelial growth factor therapy in myopic choroidal neovascularization. *Invest Ophthalmol Vis Sci*. 2015;56:5794-5800.
- Kim YK, Park SJ, Woo SJ, Park KH. Choroidal thickness change after intravitreal anti-vascular endothelial growth factor treatment in retinal angiomatous proliferation and its recurrence. *Retina*. 2016;36:1516-1526.
- Shao J, Choudhary MM, Schachat AP. Neovascular age-related macular degeneration. *Dev Ophthalmol*. 2016;55:125-136.
- Strauss O. Pharmacology of the retinal pigment epithelium, the interface between retina and body system. *Eur J Pharmacol*. 2016;787:84-93.
- Tsai ASH, Cheung N, Gan ATL, et al. Retinal angiomatous proliferation. *Surv Ophthalmol*. 2017;62:462-492.
- Koizumi H, Iida T, Saito M, Nagayama D, Maruko I. Choroidal circulatory disturbances associated with retinal angiomatous proliferation on indocyanine green angiography. *Graefes Arch Clin Exp Ophthalmol*. 2008;246:515-520.

SUPPLEMENTARY MATERIAL

SUPPLEMENTARY VIDEO. Choroidal thickness increase during the active stage of nAMD. Sequential OCT scans encompassing the foveal region in an eye affected by nAMD are presented in the form of a movie. The sequence allows one to appreciate the increased choroidal thickness characterizing the active stage of the disease.