

Systemic Levels of Interleukin-6 Correlate With Progression Rate of Geographic Atrophy Secondary to Age-Related Macular Degeneration

Marie Krogh Nielsen,^{1,2} Yousif Subhi,^{1,2} Christopher Rue Molbech,^{1,2} Mads Krüger Falk,^{1,2} Mogens Holst Nissen,^{2,3} and Torben Lykke Sørensen^{1,2}

¹Clinical Eye Research Division, Department of Ophthalmology, Zealand University Hospital, Roskilde, Denmark

²Faculty of Health and Medical Science, University of Copenhagen, Copenhagen, Denmark

³Eye Research Unit, Department of Immunology and Microbiology, University of Copenhagen, Copenhagen, Denmark

Correspondence: Marie Krogh Nielsen, Clinical Eye Research Division, Department of Ophthalmology, Zealand University Hospital, Vestermarksvej 23, Roskilde DK-4000, Denmark; mrrm@regionsjaelland.dk.

Submitted: October 1, 2018

Accepted: December 6, 2018

Citation: Krogh Nielsen M, Subhi Y, Molbech CR, Falk MK, Nissen MH, Sørensen TL. Systemic levels of interleukin-6 correlate with progression rate of geographic atrophy secondary to age-related macular degeneration. *Invest Ophthalmol Vis Sci*. 2019;60:202–208. <https://doi.org/10.1167/iovs.18-25878>

PURPOSE. Geographic atrophy (GA) is a clinical phenotype of late age-related macular degeneration (AMD) with no current treatment available. In this study, we investigated markers of chronic inflammation in plasma of patients with GA and how these relate to progression rate.

METHODS. We prospectively included 42 patients with GA, 41 patients with neovascular AMD, and 27 healthy controls. We quantified levels of interleukin (IL)-1 β , IL-6, IL-8, tumor necrosis factor (TNF) receptor 2, and C-reactive protein (CRP). We adapted an inflammation summary score to cluster conceptually related markers of chronic inflammation. Enlargement rate of the atrophic lesion was measured from fundus autofluorescence images performed at baseline and after 1 year.

RESULTS. Patients with GA showed an increase in proinflammatory markers of IL-6 ($P = 0.009$), TNF receptor 2 ($P = 0.013$), and CRP ($P = 0.017$) compared to healthy controls. We found that IL-8 levels were markedly higher in patients with GA when compared to patients with neovascular AMD ($P = 0.013$). The inflammation summary score was high in patients with neovascular AMD ($P = 0.024$), but even higher in patients with GA (<0.001), when compared to healthy controls. GA enlargement was measured in 36 patients, who completed follow-up. Plasma levels of IL-6 had a moderate but significant correlation with GA enlargement rate ($R^2 = 0.23$, $P = 0.0035$).

CONCLUSIONS. Markers of chronic inflammation strongly associates with presence of GA secondary to AMD. Plasma IL-6 possesses predictive ability of progression and constitutes the first known plasma biomarker of disease activity in GA. These findings shed light into a poorly understood clinical phenotype of AMD and highlights the important role of chronic inflammation in GA.

Keywords: geographic atrophy, age-related macular degeneration, chronic inflammation, interleukin 6

Age-related macular degeneration (AMD) is an acquired disease of the macula, characterized by late-onset neurodegeneration of the photoreceptors and underlying retinal pigment epithelium (RPE) cells.¹ The earliest signs of AMD are the presence of abnormalities and accumulation of lipoproteinaceous debris between the basal lamina of the RPE and the underlying Bruch's membrane.² Features of late stage AMD includes choroidal neovascularization (CNV) in which newly formed vessels in the choroid protrude through the Bruch's membrane and into the retinal tissue, causing leakage and destruction of photoreceptors. This subtype of late AMD, neovascular AMD, is well-studied and treatment using inhibitors of vessel formation (antibodies against vascular endothelial growth factor) have significantly improved the clinical prognosis. Another prevalent, but poorly understood subtype of late AMD is the atrophic form. Here, geographic atrophy (GA) is described as demarcated areas of neuroretinal atrophy and of the RPE that gradually progresses with time. The two late stages

are generally considered two distinct entities, although they can occur in the same eye. Each year, 7% of patients with GA develop CNV.³ Pure GA, without any CNV, accounts for approximately 40% of cases with late AMD in the Caucasian population.⁴ There are currently no treatment options for GA—patients and doctors are bystanders in devastating gradual destruction of the retina leading to impaired visual functioning and life quality (Fig. 1).

GA growth takes place at very different rates among the individuals affected. Studies of GA natural history find that: (1) former progression rate predicts future rate; (2) rapid progression in one eye tends to reflect in the other eye of an individual affected bilaterally; (3) larger atrophic lesions expands faster than smaller; (4) multifocal lesions grow faster than unifocal lesions; (5) the finding of autofluorescent accumulated lipofuscin patterns surrounding the atrophy indicates accelerated progression.⁵ These clinical studies provide insight into clinical progression. However, GA remains



poorly understood from an etiological point of view and it remains unknown what causes the disease and what sets the progression rate.

Chronic low-grade inflammation is thought to play a central role in AMD. Cross-sectional studies find higher levels of proinflammatory markers in patients with neovascular AMD.⁶⁻⁸ This partly reflects an aging process—low-grade, nonsymptomatic, sustained chronic inflammation is a well-documented normal aging phenomenon, coined inflammaging,⁹ and an acceleration of this process is thought explain why some elderly are more likely to develop diseases where inflammation play an important role. An imbalance between proinflammatory and anti-inflammatory factors in the blood is not only associated with AMD, but also several other age-related chronic diseases, such as diabetes, cardiovascular diseases, and other neurodegenerative disorders, such as Parkinson's and Alzheimer's disease.¹⁰ The etiology of chronic inflammation is not fully understood, but is linked to a combination of persistent activation of immune cells in chronic viral infections (e.g., cytomegalovirus),¹¹ and a cellular senescence-induced transformation of tissue microenvironment, into a senescence-associated secretory phenotype releasing proinflammatory cytokines, such as interleukin (IL)-6, tumor necrosis factor (TNF)- α , IL-1 β , and C-reactive protein (CRP).^{12,13}

In this study, we investigated the relationship between markers of chronic inflammation and GA secondary to AMD. In a relatively large sample of 42 patients with pure GA without any co-presence of CNV, we investigated association to plasma markers of inflammation and whether these markers possess any predictive ability to progression rate. We demonstrate, for the first time, that a systemic biomarker positively and significantly predicts GA progression rate. Our findings provide a basis for future interventions in patients with GA that are targeted chronic inflammation.

METHODS

Study Design

This was a prospective cohort study conducted at the Department of Ophthalmology, Zealand University Hospital, Denmark. We included patients with pure GA from the retinal clinic. As control group we included patients with neovascular AMD and patients' spouses accompanying them in the clinic were invited to participate as healthy controls.

Study Participants and Inclusion

The content, rationale, and purpose of the study was explained to all participants. Oral and written informed consent was obtained prior to inclusion. The study followed the tenets of the Declaration of Helsinki and was approved by the Regional Ethics Committee (reference number: SJ-385).

All participants were subjected to a structured interview and questioned about medical history, current medication use, tobacco, and alcohol consumption. Physical activity was assessed using a single-sentence question previously validated in patients with AMD.^{14,15} Height and weight was used to calculate body mass index.

Inclusion Criteria. GA secondary to AMD, neovascular AMD, or no retinal disease.

Exclusion Criteria. Any other retinal disease than AMD, optic opacities (e.g., cataract), acute inflammatory or infectious disease, cancer, or use of any immune modulating medication (e.g., methotrexate, steroids in any form).

Participants were excluded post hoc in cases of CRP above 15 mg/L, due to suspected acute inflammation.¹⁶

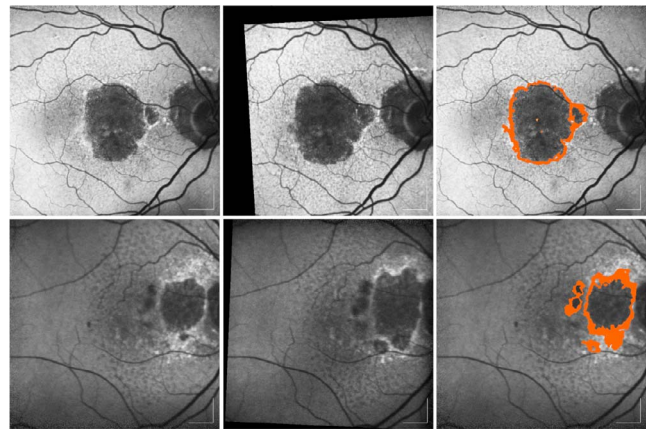


FIGURE 1. Examples of atrophy enlargement over 1 year in patients with GA secondary to AMD based on FAF image. Each case is presented horizontally with baseline FAF image (*left*), follow-up FAF image (*middle*), and progression area outlined on baseline-image (*right*). *Top*: right eye of an 86-year-old man with 7.4 mm² unifocal lesion. Progression rate was 1.2 mm² in 1 year. *Bottom*: right eye of 80-year-old woman with 3.2 mm² multifocal lesion. Progression rate was 2.0 mm² in 1 year.

Retinal Examination and Definition of GA

Trained specialist performed comprehensive ocular examination in all cases to secure diagnosis. This examination included best-corrected visual acuity, slit-lamp biomicroscopy, digital fundus photography, spectral-domain optical coherence tomography, and fundus autofluorescence (FAF) imaging. Retinal angiography using fluorescein and indocyanine green was performed in cases with suspected neovascularization.

GA was defined as one or more well-defined areas of depigmentation of the RPE, corresponding to reduced FAF signal, in an eye with pigmentary abnormalities and soft or reticular drusen.¹⁷ Patients were not included if they had any signs of active or former CNV in any eye or other retinal disease.

Healthy controls had <10 small drusen (<63 μ m in size), which are regarded as normal aging changes, and no RPE abnormalities in either eye.¹⁷

Patients with neovascular AMD had fibro-vascular detachments of the RPE and choroidal neovascular membranes with subretinal or sub-RPE hemorrhages or fibrosis, in one or both eyes. Patients with neovascular AMD were included regardless of any co-existence of atrophic regions in either eye.

Image Processing and Grading

Each image was evaluated by two individual investigators (MKN and MKF) blinded from any demographic or clinical information. Delineation of the atrophic area was performed using RegionFinder software version 2.5.7.0 (Heidelberg Engineering, Heidelberg, Germany). The readers manually selected the darkest area of the atrophic lesion (pixels with the lowest signal), and increased the threshold to include adjacent pixels, until the area marked corresponded to the lesion boundaries. In cases of multifocal lesions, all lesions ≥ 0.05 mm² were measured and included in the total lesion size. Manually placed constraints were used to exclude vessels or macula pigment from the GA delineation.¹⁸ Examples of GA progression and delineation are demonstrated in Figure 1.

Blood Sampling, Genotyping, and Cytokine Assays

Venous blood was sampled from the antecubital vein. Tubes coated with ethylenediamine-tetraacetic acid were posted to the Kennedy Center (Glostrup, Denmark) for extraction of genomic DNA using Chemagic Magnetic Separation Module 1 (Chemagen, Baesweiler, Germany). DNA samples were sent for genotyping at LGC Genomics Ltd (Herts, UK) where genotyping was performed using in-house KASP (kompetitive allele specific polymerase chain reaction) genotyping SNP-line system. The following SNPs were analyzed: CFH rs1061170 and ARMS2 rs10490924.

Two lithium-heparin coated blood filled tubes were used for cytokine assays. One tube was used for determining CRP using Dimension Vista 1500 (Siemens Healthineers, Erlangen, Germany). Another tube with lithium heparin stabilized blood was centrifuged for 15 minutes at 1500g, after which plasma was immediately isolated and stored at -80°C . Plasma concentration of inflammatory biomarkers were measured at initial visit. We quantified plasma levels of IL-1 β , IL-6, IL-8, IL-10, and TNF-receptor 2 (TNF-R2). Instead of measuring the labile TNF- α , we measured the soluble TNF-R2, which has a longer half-life, and therefore is a more stable indicator of the average TNF- α level.¹⁹ Cytokines were quantified using commercially available multiplex immunoassays (Meso Scale Discovery, Gaithersburg, MD, USA), and plates were prepared according to the manufacturer's instructions. Reading was done immediately after plate preparation on QuickPlex SQ120 (Meso Scale Discovery). All tests were run in duplicate and done randomly across plates. We included a standard on each plate to provide an eight-point standard curve, which was created using the manufacturer's software, by plotting the mean absorbance against the protein concentration. The concentration of target protein in each sample was automatically determined based on the standard curve. The coefficient of variation was calculated as the ratio of the standard deviation to the mean. We calculated the coefficient of variance (CV) in each sample, defined as the ratio of the standard deviation to the mean. Tests were included if the duplicates were within 20% of the mean, otherwise they were repeated. Quality of the cytokine assays were satisfactory (CV in % of mean \pm SD of the individual cytokine: IL-1 β : 6.5 ± 7.6 ; IL-6: 4.9 ± 4.1 ; IL-8: 2.9 ± 2.6 ; IL-10: 4.7 ± 4.1 ; TNF-R2: 8.9 ± 5.6).

Data Analysis and Statistics

For each patient we measured the atrophic area, and we repeated the measurement after 12 months. Interrater agreement between the two graders was assessed by calculating the interclass correlation coefficient. Due to the systemic measurements, and their supposed influence on both eyes, we only included one eye per patient to perform independent sampling.²⁰ In cases of bilateral GA, the right eye was included.

To reflect the general systemic inflammatory state, we adapted a summary score for low-grade inflammation to cluster conceptually related markers of low-grade inflammation. The index was developed to evaluate effect of lifestyle changes in chronic inflammation.²¹ Since the markers are expressed on different scale units, a z score for each marker was calculated. Subsequently these z scores were averaged to obtain a summary score for each participant:

$$\text{Summary score} = [z \text{ score}(\log_e \text{CRP}) + z \text{ score}(\log_e \text{IL} - 6) + z \text{ score}(\log_e \text{IL} - 8) + z \text{ score}(\log_e \text{TNF} - \text{R2})] / 4$$

To evaluate the size of the observed differences in this adapted score, we calculated Cohen's d , defined as the ratio

between the group difference and the SD. We interpreted the effect size as suggested by Cohen (0.2: small; 0.5: moderate; 0.8: large).²²

Statistical analyses were made using SPSS 24 (IBM Corporation, Armonk, NY, USA). Categorical data are presented with numbers and percentages, and compared using χ^2 test, unless sample size is small (expected count ≤ 5), in which case we used Fischer's exact test. Continuous data were tested for normal distribution visually by histograms and by using the one-sample Kolmogorov-Smirnov test. When normal distribution was present, data were presented as mean and SD, and comparisons were made using a 1-way ANOVA or independent samples t -test. When data were not normally distributed, it was presented with median and interquartile range (IQR) and compared using the nonparametrical Mann-Whitney U test or Kruskal-Wallis test.

For each patient we calculated the change in total GA lesion area in 1 year. To report progression rate normalized for baseline lesion size, we applied the square root transformation strategy. This mathematical method serves to eliminate the dependence on baseline lesion size for the growth rates.²³⁻²⁵ The evaluation of association between plasma markers and enlargement rate of GA was performed using a linear regression analysis.

RESULTS

Participants

A total of 118 participants were included, of which eight were excluded post hoc. Seven patients with GA were excluded due to following events during the follow-up period: Five patients were excluded due to development of CNV, one was excluded due to retinal vein occlusion, and two were excluded due to diagnosis of cancer in the follow-up period. One patient with neovascular AMD was excluded due to CRP of 18 mg/L. None of the 27 healthy controls were excluded. The three groups were compared on demographic and clinical parameters, and did not differ significantly, as presented in Table 1. Patients with GA were slightly elder than the others. Our impression is that more of the younger patients had a spouse, serving as healthy control, than the very old patients, since they were more frequently widowed. Patients with late stage AMD—both neovascular AMD and GA—had a higher occurrence of the AMD-associated genetic risk variants of CFH and ARMS2. None of the SNPs deviated from Hardy-Weinberg equilibrium (rs1061170, $\chi^2 = 1.0209$, $P = 0.5962$; rs10490924, $\chi^2 = 0.0297$, $P = 0.5962$).

Group Comparisons

We found that all AMD patients had significantly increased levels of IL-6, IL-10, TNF-R2, and CRP (Table 2). When comparing GA to neovascular AMD, we found a marked difference in levels of IL-8, which were solely increased in patients with GA. The calculated inflammation summary scores were significantly elevated in both groups of patients compared to healthy controls, but patients with GA had a significantly higher score than patients with neovascular AMD (Table 2). The difference in summary scores between patients with neovascular AMD and healthy controls had a moderate size (Cohen's d : 0.60), whereas the difference between patients with GA and healthy controls had a large size (Cohen's d : 1.14). The difference in between patients with GA and patients with neovascular AMD had a moderate size (Cohen's d : 0.50).²²

TABLE 1. Baseline Characteristics of Participants

	GA (n = 42)	Healthy (n = 27)	nAMD (n = 41)	P
Age, median (IQR)	80.5 (74.0–87.0)	76.0 (72.0–82.0)	77.0 (72.0–81.0)	0.060*
Female, n (%)	28 (66.7)	13 (48.1)	22 (53.7)	0.266†
Body mass index, mean (SD)	26.4 (5.6)	25.7 (3.6)	26.2 (4.1)	0.880‡
Hypertension, n (%)	25 (59.5)	9 (33.3)	21 (51.2)	0.103†
Hypercholesterolemia, n (%)	15 (35.7)	9 (33.3)	11 (26.8)	0.673†
Cardiovascular disease, n (%)	15 (35.7)	4 (14.8)	11 (26.8)	0.163†
Type 2 diabetes, n (%)	5 (11.9)	0 (0)	5 (12.2)	0.167†
Smoking habits, n (%)				0.239†
Current	9 (21.4)	2 (7.4)	12 (20.9)	
Former	17 (40.5)	13 (48.1)	18 (43.9)	
Never	16 (38.1)	18 (43.9)	11 (26.8)	
Alcohol consumption, median (IQR)	3.0 (1.0–7.0)	5.0 (2.5–7.0)	3.0 (0.5–8.0)	0.398*
Daily exercise, n (%)	27 (64.3)	18 (66.7)	21 (51.2)	0.343†
CFH genotype,§ n (%)				0.183†
C:C	11 (26.2)	3 (11.1)	13 (31.7)	
C:T	23 (54.8)	15 (55.6)	17 (41.5)	
T:T	7 (16.7)	8 (29.6)	5 (12.2)	
ARMS2 genotype,§ n (%)				0.003†
T:T	9 (21.4)	2 (7.4)	12 (20.9)	
T:G	17 (40.5)	13 (48.1)	18 (43.9)	
G:G	16 (38.1)	18 (43.9)	11 (26.8)	

nAMD, neovascular AMD.

* Kruskal-Wallis test.

† χ^2 test.

‡ One-way ANOVA.

§ Seven analyses failed in CFH genotyping and five analyses failed in ARMS2 genotyping.

Due to the tendency of patients with GA being slightly older than other study groups and composed of more females, we investigated if measured cytokine levels correlate with age or gender. We found that the relationship with age was weak and insignificant (all correlations had $\rho < 0.3$ and $P > 0.2$) and found no evidence of any differences between males and females ($P > 0.1$).

(range, 12–17 months). Interrater agreement of lesion area measurement between the two graders had an interclass correlation coefficient of 0.90, which indicates excellent agreement. The median enlargement rate of the atrophic lesion was 1.6 mm² per year (range, 0.1–4.3 mm² per year). Progression of GA in the study eye correlated significantly with progression rate in the fellow eye ($\rho: 0.64$; $P < 0.001$).

Progression of Atrophic Lesion Area

Thirty-six of the included GA patients completed follow-up. One patient died of cardiovascular event, one patient developed severe dementia, and three patients did not provide cause of absence. The mean follow-up time was 12.7 months

Do Markers of Inflammation Predict Progression Rate of GA?

We used linear regression analysis to test the predictive ability of the markers of inflammation and the progression rate of GA over 1 year. Plasma IL-6 moderately and significantly predicted

TABLE 2. Plasma Levels of Inflammatory Markers Differed Between Patient Groups

	GA (n = 42)	Healthy (n = 27)	nAMD (n = 41)	P		
				GA vs. Healthy	GA vs. nAMD	nAMD vs. Healthy
IL-1 β pg/mL, median (IQR; range)*	0.3 (0.2–0.4; 0.7)	0.3 (0.2–0.5; 1.2)	0.3 (0.2–0.5; 2.3)	0.519	0.670	0.755
IL-6 pg/mL, median (IQR; range)*	2.2 (1.7–3.1; 5.0)	1.5 (1.2–2.4; 5.6)	2.6 (1.5–3.9; 4.9)	0.009	0.600	0.024
IL-8 pg/mL, median (IQR; range)*	6.6 (4.1–11.7; 56.9)	4.7 (3.7–8.0; 20.7)	4.8 (3.6–7.0; 21.1)	0.085	0.013	0.535
IL-10 pg/mL, median (IQR; range)*	0.6 (0.5–0.9; 1.6)	0.5 (0.4–0.7; 0.9)	0.8 (0.6–1.2; 1.8)	0.052	0.087	0.002
TNF-R2 ng/mL, median (IQR; range)*	6.6 (5.3–8.7; 19.9)	5.4 (3.9–6.8; 8.0)	5.7 (4.0–7.5; 9.7)	0.013	0.096	0.370
CRP mg/L, n (%)†				0.017	0.814	0.058
0–2.9	24 (57.1)	21 (88.9)	26 (73.5)			
3.0–9.9	15 (35.7)	3 (11.1)	13 (31.7)			
10–15	3 (7.1)	0 (0)	2 (4.9)			
Inflammation summary score,‡ mean (SD)§	0.27 (0.64)	–0.34 (0.40)	–0.04 (0.59)	<0.001	0.024	0.016

nAMD, neovascular AMD.

* Mann-Whitney U test.

† χ^2 test.

‡ Inflammation summary score = [z score (log_eCRP) + z score (log_eIL-6) + z score(log_eIL-8) + z score(Log_eTNF-R2)] / 4.

§ Unpaired t-test.

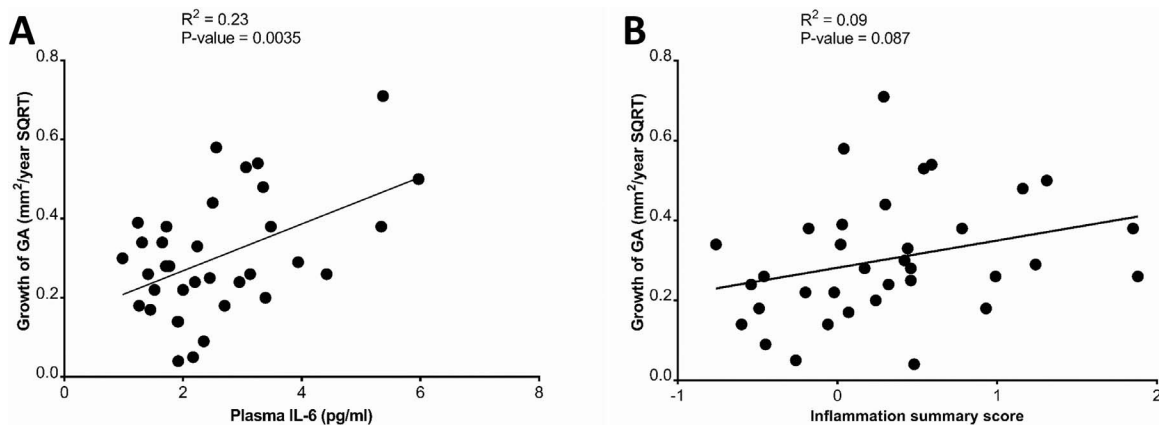


FIGURE 2. (A) Plasma IL-6 positively predicts future progression rate of the atrophic lesion in patients with GA. The progression rate is normalized for baseline area using square root transformation (SQRT). (B) The predictive ability of IL-6 is superior to the inflammation summary score. This score is calculated based on the proinflammatory markers (IL-6, IL-8, TNF-receptor 2, CRP).

the progression rate of GA ($R^2 = 0.23$, $P = 0.0035$) (Fig. 2), whereas the other markers did not possess any predictive ability (all $P > 0.05$). The inflammation summary score possessed a weak trend of predictive ability of the progression rate ($R^2 = 0.09$, $P = 0.087$) (Fig. 2).

DISCUSSION

In this study, patients with GA had distinctly elevated levels of plasma IL-6, IL-8, TNF-R2, and CRP. When comparing the adapted inflammation summary score, we found this increased in patients with GA compared to patients with neovascular AMD. The increase in IL-8 differs from patients with neovascular AMD, who displayed levels similar to that of healthy controls. GA enlargement rates were associated significantly with patient plasma level of IL-6.

We find a median enlargement rate of 1.60 mm^2 per year in the study eye, and very similar rate in fellow eyes. This is in line with previous observational studies on GA enlargement in which progression rates range from a median of 0.53 to $2.6 \text{ mm}^2/\text{year}$. A recent review by Fleckenstein et al.⁵ synthesized the literature on GA natural history and found a median enlargement rate of $1.78 \text{ mm}^2/\text{year}$. In line with previous observation studies, we also found a strong association between intereye progression rates in patients with bilateral GA.⁵

The role of systemic inflammation in brain and retinal aging has received increasing attention, since prolonged systemic inflammation can induce neuroinflammatory changes, and subsequently neurodegeneration. The effect of systemic inflammation to exacerbate or even drive neuronal dysfunction is described in Alzheimer's disease, but also in nonsymptomatic elderly individuals.^{26,27} Plasma levels of inflammatory markers, such as CRP, is associated with risk of AMD, but if it serves as a biomarker, or if there is a causal association is unknown. The latter is indicated by research demonstrating that CRP, IL-6, IL-8, and TNF- α have direct impact on RPE cells and choroidal endothelial cells *in vivo*.²⁸⁻³⁰

The cellular effect of IL-6 works through two distinct pathways. The classical, anti-inflammatory pathway works through stimulation of membrane-bound IL-6-receptor (IL-6R). The IL-6R initiates dimerization of gp130 and subsequent downstream signaling, leading to activation of selective cells, among these microglia cells, which is appropriate in pathogen-defense response.³¹ The alternative activation pathway is through formation of a complex with the soluble IL6-receptor

(sIL-6R), which is released from naïve T cells as they differentiate. This complex stimulates cells that express gp130 but not surface-bound IL-6R, and therefore are not sensitive to IL-6 in itself. Gp130 is expressed on numerous cells, including glia cells and neurons, explaining the widespread effect of chronic IL-6 elevation. The IL-6-sIL6R complex formation and stimulation is termed trans-signaling.³²

The special relevance of IL-6 in neuroinflammation is due to the fact that increased levels of IL-6 mediates the increased surface expression of the cell adhesion molecule vascular cell adhesion protein-1. This process disrupts the integrity of the blood-brain-barrier, and allows IL-6, along with other immune cells, to traverse the endothelial layer.³³ Elevated levels of IL-6 in the brain and periphery, can form a feed-back activation loop, as trans-signaling promotes differentiation of naïve T cells into the pathogenic Th17 cell, and in this differentiation gives rise to more IL-6 and sIL-6R.^{33,34}

Mononuclear phagocytes (microglia and blood-derived macrophages) are thought to play a central role in GA as they are found accumulated within the atrophic area of donor eyes.^{35,36} These cells change in phenotype according to the surrounding microenvironment. A proinflammatory environment promotes differentiation into the inflammatory M1 phenotype, contributing further to inflammation, and initiation of an adaptive immune response.³⁷ An individual's capacity to generate and maintain an inflammatory response varies greatly, and the difference is, to a large extent, determined by genetic factors. In AMD, there is a strong genetic component, and a number of studies have highlighted *ARMS2* and *CFH* as the major susceptibility loci of AMD.^{38,39}

In particular, the *CFH* at-risk CC variant results in an increased activation of the complement cascade and has been associated with a higher risk of AMD development and progression to late-stage AMD.^{40,41} The *ARMS2* gene codes for the age-related maculopathy susceptibility protein, whose functions has to be yet clarified. The *ARMS2* at-risk TT variant increases the risk of developing AMD by 7.6-fold compared to heterozygotes. The presence of risk variants has been further linked to increased levels of CRP in the at-risk TT variants in subjects with no evidence of AMD.⁴² This relationship between CRP and *ARMS2* risk variants suggests the potential role of gene polymorphisms in inflammation and AMD susceptibility. In the present study, we find that AMD patients have a higher occurrence of the AMD-associated genetic risk variants. This is in line with findings of large genotype studies of such patients,⁴⁰⁻⁴² which indicates that our study group can be

considered a representative sample of patients with late stage AMD.

Blockage of IL-6 has shown to alleviate NLRP3 inflammation,⁴³ presumably due to IL-6's ability to promote IL-17A.⁴⁴ IL17A has been shown to induce IL-1 β secretion from RPE cells via the NLRP inflammasome,⁴⁵ indicating a possible effect of IL-6 in a harmful inflammatory feedback circle. Therefore, we suggest a local feedback system generates a microenvironment of inflammation and cell death that is induced by persistent systemic IL-6 trans-signaling. This would explain why the association of systemic IL-6 and GA enlargement appear when the progression rate is normalized for the baseline lesion size, via the square root transformation.

In this study, we found a marked increase of plasma IL-8 in patients with GA, a finding that was not shared in patients with neovascular AMD. Besides serving as a marker of inflammation, IL-8 is part of the chemokine family. Chemokines are constitutively expressed in the organism and the brain. IL-8 is secreted by neutrophils, monocytes, macrophages, and endothelial cells. IL-8 function includes cell adhesion, recruitment of neutrophils and lymphocytes to sites of inflammation. In the CNS both neurons and glia cells produce IL-8.⁴⁶ Expression of IL-8 is increased in retinal microglia activation,⁴⁷ and in RPE cells when they are exposed to T cell-derived proinflammatory cytokine TNF- α .⁴⁸ IL-8 receptor CXCR2 has been shown to regulate T-cell migration and patients with Alzheimer's disease has increased expression of CXCR2, to enhance the trans-endothelial migration. In a blood-brain barrier model, T-cell migration was blocked through anti-CXCR2 antibody or IL-8 RNA interference.⁴⁹ In patients with Alzheimer's disease, plasma IL-8 is linked to presence and severity of disease. It is possible that GA holds similarities with patients with Alzheimer's, in terms of cell migration prior to neurodegeneration, but this theory needs further studies to explore.

The roles of IL-6 and IL-8 are extremely diverse in the human organism, as it is produced by various cell types and have many effector sites. Persistent low-level IL-6 is associated with many age-related degenerative diseases.⁵⁰ Therefore, the exact role of IL-6 in GA progression needs to be elucidated. In the case, that IL-6 holds a causal role in GA enlargement, this opens possibilities to intervene in a disease, that is common, disabling, and currently has no treatment option. Due to its many influences in the body, IL-6 interventions are thoroughly studied. One strategy to halt the harmful effect of trans-signaling is use of the physiological soluble form of gp130, which has been successful in blocking trans-signaling and reduce neuropathological changes in mice, without haltering the classical beneficial IL-6 signaling.^{51,52}

Important limitations should be kept in mind when interpreting these results. First, due to the observational nature of the study, we can only speculate on causality. Furthermore, the study sample size does not allow for subgroup analysis in GA patients. Previous studies have stratified eyes with GA into subtypes based on autofluorescence patterns, and knowledge on inflammatory levels in these subgroups might provide further insight into the pathogenesis of this poorly understood subtype of AMD.

In conclusion, we find that GA is associated with chronic inflammation. Patients with GA differs from patients with neovascular AMD in their vastly higher plasma levels of IL-8, suggesting a distinct inflammation profile. We demonstrate that a high level of plasma IL-6 is associated with a fast progression profile. Assessment of chronic inflammation may add significant information to the evaluation of the risk of GA and prediction of rates of disease progression over time. Future studies need to evaluate clinical efficacy of targeting chronic inflammation in GA.

Acknowledgments

Supported by The Velux Foundation, Øjenfonden, and the Region Zealand. None of the funding bodies had any role in design, execution, or interpretation of the research performed.

Disclosure: **M. Krogh Nielsen**, None; **Y. Subhi**, None; **C.R. Molbech**, Bayer (R); **M.K. Falk**, None; **M.H. Nissen**, None; **T.L. Sørensen**, None

References

1. Al-Zamil WM, Yassin SA. Recent developments in age-related macular degeneration: a review. *Clin Interv Aging*. 2017;12:1313-1330.
2. Curcio CA, Millican CL. Basal linear deposit and large drusen are specific for early age-related maculopathy. *Arch Ophthalmol*. 1999;117:329-339.
3. Sarks JP, Sarks SH, Killingsworth MC. Evolution of geographic atrophy of the retinal pigment epithelium. *Eye (Lond)*. 1988;2:552-577.
4. Jonasson F, Arnarsson A, Eiriksdottir G, et al. Prevalence of age-related macular degeneration in old persons: age, gene/environment susceptibility Reykjavik study. *Ophthalmology*. 2011;118:825-830.
5. Fleckenstein M, Mitchell P, Freund KB, et al. The progression of geographic atrophy secondary to age-related macular degeneration. *Ophthalmology*. 2018;125:369-390.
6. Čolak E, Ignjatović S, Radosavljević A, Žorić L. The association of enzymatic and non-enzymatic antioxidant defense in parameters with inflammatory markers in patients with exudative form of age-related macular degeneration. *J Clin Biochem Nutr*. 2017;60:100-107.
7. Haas P, Kubista KE, Krugluger W, Huber J, Binder S. Impact of visceral fat and pro-inflammatory factors on the pathogenesis of age-related macular degeneration. *Acta Ophthalmol*. 2015;93:533-538.
8. Klein R, Myers CE, Cruickshanks KJ, et al. Markers of inflammation, oxidative stress, and endothelial dysfunction and the 20-year cumulative incidence of early age-related macular degeneration: the Beaver Dam Eye Study. *JAMA Ophthalmol*. 2014;132:446-455.
9. Franceschi F, Bonafé M, Valensin S, et al. Inflamm-aging. An evolutionary perspective on immunosenescence. *Ann N Y Acad Sci*. 2000;908:244-254.
10. Frasca D, Blomberg BB. Inflammaging decreases adaptive and innate immune responses in mice and humans. *Biogerontology*. 2016;17:7-19.
11. Nikolich-Zugich J. Ageing and life-long maintenance of T-cell subsets in the face of latent persistent infections. *Nat Rev Immunol*. 2008;8:512-522.
12. Campisi J. Cellular senescence: putting the paradoxes in perspective. *Curr Opin Genet Dev*. 2011;21:107-112.
13. Freund A, Orjalo AV, Desprez PY, Campisi J. Inflammatory networks during cellular senescence: causes and consequences. *Trends Mol Med*. 2010;16:238-246.
14. Subhi Y, Singh A, Falk MK, Sørensen TL. In patients with neovascular age-related macular degeneration, physical activity may influence C-reactive protein levels. *Clin Ophthalmol*. 2014;8:15-21.
15. Subhi Y, Sørensen TL. Physical activity patterns in patients with early and late age-related macular degeneration. *Dan Med J*. 2016;63:A5303.
16. Rifai N, Ridker PM. Proposed cardiovascular risk assessment algorithm using high-sensitivity C-reactive protein and lipid screening. *Clin Chem*. 2001;47:28-30.
17. Ferris FL, Wilkinson CP, Bird A, et al. Clinical classification of age-related macular degeneration. *Ophthalmology*. 2013;120:844-851.

18. Schmitz-Valckenberg S, Brinkmann CK, Alten F, et al. Semi-automated image processing method for identification and quantification of geographic atrophy in age-related macular degeneration. *Invest Ophthalmol Vis Sci.* 2011;52:7640-7646.
19. Faber C, Jehs T, Juel HB, et al. Early and exudative age-related macular degeneration is associated with increased plasma levels of soluble TNF receptor II. *Acta Ophthalmol.* 2015;93:242-247.
20. Bunce C, Patel KV, Xing W, Freemantle N, Doré CJ; Ophthalmic Statistics Group. Ophthalmic statistics note 1: unit of analysis. *Br J Ophthalmol.* 2014;98:408-412.
21. Van Woudenberg GJ, Theofylaktopoulou D, Kujisten A, et al. Adapted dietary inflammatory index and its association with a summary score for low-grade inflammation and markers of glucose metabolism: the Cohort study on Diabetes and Atherosclerosis Maastricht (CODAM) and the Hoorn study. *Am J Clin Nutr.* 2013;98:1533-1542.
22. Cohen J. *Statistical Power Analysis for the Behavioral Sciences.* 2nd ed. Hillsdale: Lawrence Erlbaum Associates; 1988.
23. Gregori G, Wang F, Rosenfeld PJ, et al. Spectral domain optical coherence tomography imaging of drusen in nonexudative age-related macular degeneration. *Ophthalmology.* 2011;118:1373-1379.
24. Yehoshua Z, Wang F, Rosenfeld PJ, Penha FM, Feuer WJ, Gregori G. Natural history of drusen morphology in age-related macular degeneration using spectral domain optical coherence tomography. *Ophthalmology.* 2011;118:2434-2441.
25. Feuer WJ, Yehoshua Z, Gregori G, et al. Square root transformation of geographic atrophy area measurements to eliminate dependence of growth rates on baseline lesion measurements: a re-analysis of age-related eye disease study. *JAMA Ophthalmol.* 2013;131:110-111.
26. De Felice FG, Ferreira ST. Inflammation, defective insulin signaling, and mitochondrial dysfunction as common molecular denominators connecting type 2 diabetes to Alzheimer disease. *Diabetes.* 2014;63:2262-2272.
27. Corlier F, Hafzalla G, Faskowitz J, et al. Systemic inflammation as a predictor of brain aging: contributions of physical activity, metabolic risk, and genetic risk. *NeuroImage.* 2018;172:118-129.
28. Touhami S, Beguier F, Augustin S, et al. Chronic exposure to tumor necrosis factor alpha induces retinal pigment epithelium cell dedifferentiation. *J Neuroinflammation.* 2018;15:85.
29. Bhutto IA, Baba T, Merges C, Juriasinghani V, McLeods DS, Luttly GA. C-reactive protein and complement factor H in aged human eyes and eyes with age-related macular degeneration. *Br J Ophthalmol.* 2011;95:1323-1330.
30. Johnson PT, Betts KE, Radeke MJ, Hageman GS, Anderson DH, Johnson LV. Individuals homozygous for the age-related macular degeneration risk-conferring variant of complement factor H have elevated levels of CRP in the choroid. *Proc Natl Acad Sci U S A.* 2006;103:17456-17461.
31. Taga T, Hibi M, Hirata Y, et al. Interleukin-6 triggers the association of its receptor with a possible signal transducer, gp130. *Cell.* 1989;58:573-581.
32. Rose-John S, Heinrich PC. Soluble receptors for cytokines and growth factors: generation and biological function. *Biochem J.* 1994;300:281-290.
33. Heink S, Yogev N, Garbers C, et al. Trans-presentation of interleukin-6 by dendritic cells is required for priming pathogenic TH17 cells. *Nat Immunol.* 2017;18:74-85.
34. Betelli E, Carrier Y, Gao W, et al. Reciprocal developmental pathways for the generation of pathogenic effector TH17 and regulatory T cells. *Nature.* 2006;441:235-238.
35. Gupta N, Brown KE, Milam AH. Activated microglia in human retinitis pigmentosa, late-onset retinal degeneration, and age-related macular degeneration. *Exp Eye Res.* 2003;76:463-471.
36. Combadiere C, Feumi C, Raoul W, et al. CX3CR1-dependent subretinal microglia cell accumulation is associated with cardinal features of age-related macular degeneration. *J Clin Invest.* 2007;117:2920-2928.
37. Mosser DM, Edwards JP. Exploring the full spectrum of macrophage activation. *Nat Rev Immunol.* 2008;8:958-969.
38. Fritsche LG, Loenhardt T, Janssen A, et al. Age-related macular degeneration is associated with an unstable ARMS2 (LOC387715) mRNA. *Nature Gen.* 2008;40:892-896.
39. Klein RJ, Zeiss C, Chew EY, et al. Complement factor H polymorphism in age-related macular degeneration. *Science.* 2005;308:385-389.
40. Fritsche LG, Chen W, Schu M, et al. Seven new loci associated with age-related macular degeneration. *Nat Genet.* 2013;45:433-439.
41. Seddon JM, Francis PJ, George S, Schultz DW, Rosner B, Klein ML. Association of CFH Y402H and LOC387715 A69S with progression of age-related macular degeneration. *JAMA.* 2007;297:1793-1800.
42. Yasuma TR, Nakamura M, Nishiguchi KM, et al. Elevated C-reactive protein levels and ARMS2/HTRA1 gene variants in subjects without age-related macular degeneration. *Mol Vis.* 2010;16:2923-2930.
43. Wu R, Liu X, Yin J, et al. IL-6 blockade ameliorates diabetic nephropathy via inhibiting inflammasome in mice. *Metabolism.* 2018;83:18-24.
44. Powell N, Lo JW, Biancheri P, et al. Interleukin 6 increases production of cytokines by colonic innate lymphoid cells in mice and patients with chronic intestinal inflammation. *Gastroenterology.* 2015;149:456-467.
45. Zhang S, Yu N, Zhang R, Zhang S, Wu J. Interleukin-17A induces IL-1 β secretion from RPE cells via the NLRP3 inflammasome. *Invest Ophthalmol Vis Sci.* 2016;57:312-319.
46. Charo IF, Ransohoff RM. The many roles of chemokines and chemokine receptors in inflammation. *N Engl J Med.* 2006;354:610-621.
47. Goczalik I, Ulbricht E, Hollborn M, et al. Expression of CXCL8, CXCR1, and CXCR2 in neurons and glial cells of the human and rabbit retina. *Invest Ophthalmol Vis Sci.* 2008;49:4578-4589.
48. Juel HB, Faber C, Udsen MS, Folkersen L, Nissen MH. Chemokine expression in retinal pigment epithelial ARPE-19 cells in response to coculture with activated T cells. *Invest Ophthalmol Vis Sci.* 2012;53:8472-8480.
49. Liu YJ, Guo DW, Tian L, et al. Peripheral T cells derived from Alzheimer's disease patients overexpress CXCR2 contributing to its transendothelial migration, which is microglial TNF-alpha-dependent. *Neurobiol Aging.* 2010;31:175-188.
50. Ghanemi A, St-Amand J. Interleukin-6 as a "metabolic hormone". *Cytokine.* 2018;112:132-136.
51. Jostock T, Müllberg J, Ozbek S, et al. Soluble gp130 is the natural inhibitor of soluble interleukin-6 receptor transsignaling responses. *Eur J Biochem.* 2001;268:160-167.
52. Narazaki M, Yasukawa K, Saito T, et al. Soluble forms of the interleukin-6 signal-transducing receptor component gp130 in human serum possessing a potential to inhibit signals through membrane-anchored gp130. *Blood.* 1993;82:1120-1126.