

Cytokine Profiling in Patients With Exudative Age-Related Macular Degeneration and Polypoidal Choroidal Vasculopathy

Rupesh Agrawal,^{1,2} Praveen Kumar Balne,^{1,2} Xin Wei,³ Veonice Au Bijin,⁴ Bernett Lee,⁵ Arkasubhra Ghosh,⁶ Raja Narayanan,⁷ Mukesh Agrawal,⁸ and John Connolly⁴

¹National Healthcare Group Eye Institute, Tan Tock Seng Hospital, Singapore

²Singapore Eye Research Institute, Singapore

³Khoo Teck Puat Hospital, Department of Ophthalmology and Visual Sciences, Singapore

⁴Institute of Molecular and Cell Biology, Singapore

⁵Singapore Immunology Network, Singapore

⁶GROW Research Laboratory, Narayana Nethralaya Foundation, Bangalore, India

⁷L.V. Prasad Eye Institute, Hyderabad, Telangana, India

⁸Vimta Labs Limited, Hyderabad, Telangana, India

Correspondence: Rupesh Agrawal, National Healthcare Group Eye Institute, Tan Tock Seng Hospital, 11 Jalan, Tan Tock Seng 308433, Singapore; rupesh_agrawal@ttsh.com.sg.

RA and PKB are joint first authors.

Submitted: March 19, 2018

Accepted: December 12, 2018

Citation: Agrawal R, Balne PK, Wei X, et al. Cytokine profiling in patients with exudative age-related macular degeneration and polypoidal choroidal vasculopathy. *Invest Ophthalmol Vis Sci.* 2019;60:376-382. <https://doi.org/10.1167/iovs.18-24387>

PURPOSE. The purpose of this study was to investigate the cytokine profiles in plasma and aqueous humor of patients with choroidal neovascularization (CNV) due to exudative AMD and polypoidal choroidal vasculopathy (PCV).

METHODS. In this cross-sectional study, 16 patients clinically diagnosed with AMD, 18 patients with PCV, and 50 age- and sex-matched cataract patients without AMD/PCV (controls) were enrolled. Study subjects were treatment naïve, and 200 μ L undiluted aqueous humor and 5 mL peripheral venous blood were collected from the study subjects. Clinical samples were analyzed for 41 different cytokines by Luminex bead-based multiplex assay. Cytokines concentrations with detection rates of 50% or more were included for the analysis, and the differences in plasma and aqueous humor cytokines levels between each group were analyzed.

RESULTS. The age of the patients with AMD and PCV was 70.62 ± 10.15 (mean \pm SD) and 71.48 ± 9.08 years, respectively, and that in the control group was 62.8 ± 10.67 years. Aqueous humor cytokines growth-regulated oncogene (GRO), macrophage-derived chemokine (MDC), and macrophage inflammatory protein (MIP)-1 α were significantly higher in AMD patients than controls (all $P < 0.04$), and GRO, MDC, MIP-1 α , IL-8, IFN- γ -inducible protein 10, and monocyte chemoattractant protein levels were significantly higher in PCV patients than controls (all $P < 0.03$). Soluble CD40 ligand and platelet-derived growth factor-AA levels were higher in plasma of healthy controls compared with AMD subjects. No significant differences in cytokine levels were observed between AMD and PCV patients for both plasma and aqueous humor.

CONCLUSIONS. In AMD and PCV patients, our data suggest that the pathologic changes are primarily driven by dysregulation of local immune factors in the eye, whereas the plasma cytokine levels are not elevated.

Keywords: exudative age-related macular degeneration, choroidal neovascularization, polypoidal choroidal vasculopathy, aqueous humor cytokine profiles, plasma cytokine profiles, inflammation

AMD is one of the leading causes of blindness in elderly population with around 20 million cases reported so far worldwide.¹ AMD is classified into non-neovascular AMD (non-exudative/dry/atrophic AMD) and neovascular AMD (exudative/wet AMD).² In AMD, vision loss is due to degenerative changes in the macula (the central and posterior parts of the retina that are responsible for central vision³) loss of central vision is observed in most of the advanced or late stages of AMD patients.⁴ AMD is a multifactorial disease; although it is mainly associated with age, other factors such as metabolic interactions and functional, genetic, and environmental factors such as

race, heredity, obesity, diet, and smoking can play an important role in the development of the disease.⁵⁻¹⁰ The major known contributors of the AMD pathogenesis are accumulation of lipofuscin, formation of drusen, development of local inflammatory responses, and angiogenesis (in case of neovascular AMD).¹¹

Polypoidal choroidal vasculopathy (PCV) is a vascular disease of the choroid and is considered a common subtype of neovascular AMD due to similarities in clinical features (choroidal vasculopathy associated with subretinal hemorrhage, scars, and fibrosis), risk factors, and genetic determi-



nants.¹² However, recent literature suggests PCV has distinct features in its pathophysiology, epidemiology, clinical characteristics, and treatment responses compared with typical neovascular AMD with choroidal neovascularization (CNV).¹²⁻¹⁴

Inflammation is postulated to play a role in the pathogenesis of CNV in both AMD and PCV,^{14,15} and cytokines are mediators of various inflammatory responses in the human body.¹⁶ Studying cytokines in the aqueous humor and blood of patients with CNV due to AMD and PCV would help us to understand the disease mechanisms and the key differences between AMD and PCV, which will in turn help to identify disease-specific diagnostic markers for AMD and PCV. A number of research groups have compared cytokine profiles in CNV in AMD and PCV patients, but most of these studies focused on a few selected cytokines in either the aqueous humor or blood.¹⁷⁻²² With the recent advancement of a commercially available multiplex immunoassay, it is possible to evaluate a panel of cytokines in a small amount of clinical samples.²³ In this study, we aim to investigate both aqueous humor and plasma cytokine profiles using a multiplex immunoassay in patients with CNV due to either AMD and PCV in comparison with controls.

MATERIALS AND METHODS

This was a cross-sectional study comparing cytokine profiles of plasma and aqueous humor in patients with CNV due to AMD or PCV and healthy controls (age- and sex-matched cataract patients without any other ocular complication). A total number of 34 patients with CNV due to AMD or PCV and 50 cataract patients were recruited with prior informed consent. The study was approved by the institutional review board and adhered to the tenets of the Declaration of Helsinki.

Clinical Diagnosis of AMD and PCV

Clinical diagnosis of CNV was made by medical retina specialists in all the study subjects recruited under this study. Diagnosis of AMD or PCV was based on optical coherence tomography (OCT) and indocyanine green angiography (ICGA) features and was confirmed by medical retina specialists. Data on refractive error and IOP were collected for both the study group and control group to rule out myopia-associated CNV.

Inclusion Criteria

Subjects more than 50 years of age with PCV or exudative AMD as the only ocular pathology and requiring intravitreal injections were included as cases in the study. All the study patients were treatment naïve. Control subjects (>50 years of age) were patients undergoing cataract surgery with no retinal disease and having only senile cataracts. Cataract patients with AMD or any other ocular pathology were not included in the control group.

Exclusion Criteria

Subjects with previous intraocular surgery or procedures performed, systemic inflammatory medical conditions or malignancies diagnosed previously, surgeries performed within the last 6 months, and on systemic immunomodulators within the last 6 months were excluded from the study.

Collection of Blood and Aqueous Humor

Five milliliters peripheral venous blood were collected aseptically from cases and controls using blood vacutainer

tubes (BD Vacutainer; Beckton Dickinson, Franklin Lakes, NJ, USA). At the time of intravitreal injection, which is the standard of care in CNV in both AMD and PCV patients, approximately 200 μ L aqueous humor was collected aseptically from cases and controls under topical anesthesia and direct visualization with patients in an inclined position using an insulin syringe with attached 30-gauge needle. After the collection, clinical samples were immediately transferred into prelabelled sterile 1.5-mL microcentrifuge tubes and stored at -80°C freezer until final analysis.

Cytokine Profiling by Luminex Assay

Blood and aqueous humor samples were thawed on ice and centrifuged at 3000 rpm for 5 minutes. Plasma from blood and the supernatant from aqueous humor were separated and transferred onto ice, and 25 μ L of each sample was used for cytokine analysis in duplicate reactions. The Flex MAP 3D (Luminex) platform was applied for the analysis of 41 different cytokines (which include proinflammatory and inflammatory markers and growth factors) in the clinical samples using the Milliplex MAP human cytokine/chemokine magnetic bead panel-1 kit following the manufacturer's guidelines (Millipore, Burlington, MA, USA). Each sample was tested for the presence of 41 analytes including IL-1 α , IL-1 β , IL-R α , IL-2, IL-3, IL-4, IL-5, IL-6, IL-7, IL-8, IL-9, IL-10, IL-12 p40, IL-12 p70, IL-13, IL-15, IL-17A, IFN- α 2, IFN- γ , IFN- γ -inducible protein 10 (IP-10, CXCL10), TGF- α , TNF- α , TNF- β , epidermal growth factor (EGF), eotaxin, fibroblast growth factor (FGF)-2, Fms-like tyrosine kinase 3 ligand (Flt-3L), fractalkine, granulocyte colony-stimulating factor (G-CSF), granulocyte-macrophage colony-stimulating factor (GM-CSF), growth-regulated oncogene (GRO), monocyte chemotactic protein (MCP)-1, MCP-3, macrophage-derived chemokine (MDC), macrophage inflammatory protein (MIP)-1 α , MIP-1 β , platelet-derived growth factor (PDGF)-AA, PDGF-AB/BB, regulated upon activation, normal T-cell expressed, and secreted protein (RANTES), VEGF, and soluble CD40 ligand (sCD40L). The Luminex plates were read using Magpix system (Luminex Corp., Austin, TX, USA) following the manufacturer's instructions, and Bio-Plex manager 6.1 software (Bio-Rad Laboratories, Hercules, CA, USA) with a five-parameter curve-fitting algorithm was used to analyze the data (Supplementary Tables).

Statistical Analysis

Cytokine concentrations were median centered and logarithmically transformed to remove the plate effects and to ensure normality of the data between different runs, respectively. ANOVA analysis was carried out using the R statistical language (version 3.3.1; R Foundation for Statistical Computing, Vienna, Austria) on the logarithmically transformed concentration values in both aqueous humor and plasma (Supplementary Tables). Multiple testing correction for the ANOVA analysis was done using the method of Benjamini and Hochberg. This was followed by a post hoc *t*-test corrected for multiple testing using the method of Bonferroni to test for PCV and AMD versus controls in a pairwise fashion. Only post hoc *t*-tests for analytes having a significant corrected *P* value in the ANOVA was used in the interpretations. *P* < 0.05 was deemed to be statistically significant.

RESULTS

Of 34 cases with CNV, 16 cases had AMD and 18 cases had PCV (Table 1). The mean age of patients with AMD and PCV was 70.62 ± 10.15 (mean \pm SD) and 71.48 ± 9.08 years,

TABLE 1. Baseline Demographics of the Study Subjects and the Control Group

Demographic	Control Group	Study Group	
		CNV-AMD	PCV
Number of subjects	50	16	18
Age (y)	62.8 ± 10.67	70.62 ± 10.15	71.48 ± 9.08
Sex (male:female)	30:20	10:6	12:6
Refractive error (D) (spherical equivalent)	-1.50	-1.00	-1.25
Mean IOP (mm Hg)	17	16	18
Aqueous humor samples (number of subjects)	41	15	17
Plasma samples (numbers of subjects)	50	15	17

respectively, and the control group was 62.8 ± 10.67 years. The male and female ratios were 10:6 and 12:6 in AMD and PCV patients, respectively, and 30:20 in the control group. Of 34 cases, aqueous humor and plasma collected from 32 patients were subjected to cytokine profiling (in two aqueous humor samples, the quantity was inadequate, and two plasma samples were hemolyzed). Of 50 controls, 9 subjects denied permission to provide an aqueous humor sample for the study. Therefore, aqueous humor collected from 41 subjects and plasma collected from 50 subjects was subjected to cytokine profiling using the Luminex assay.

Of 41 cytokines tested in each sample, 23 cytokines (EGF, eotaxin, FGF-2, Flt-3L, fractalkine, GM-CSF, GRO, IFN-α2, IL-15, IL-1β, IL-1Rα, IL-6, IL-8, IP-10, MCP-1, MCP-3, MDC, MIP-1α, MIP-1β, PDGF-AA, sCD40L, TNF-α, and VEGF) had detection rates 50% or more in aqueous humor, and 31 cytokines (EGF, eotaxin, FGF-2, fractalkine, G-CSF, GM-CSF, GRO, IFN-α2, IFN-γ, IL-10, IL-12p70, IL-15, IL-17A, IL-1α, IL-1β, IL-1Rα, IL-5, IL-6, IL-8, IP-10, MCP-1, MCP-3, MDC, MIP-1α, MIP-1β, PDGF-AA, PDGF-AA/BB, RANTES, sCD40L, TNF-α, and VEGF) had detection rates 50% or more in plasma.

Table 2 shows the mean concentrations of cytokines that were significantly increased in aqueous humor of CNV-AMD and PCV patients versus controls. Concentrations of aqueous humor cytokines GRO, MDC, and MIP-1α were significantly higher in the AMD cohort than controls (all $P < 0.05$; Figs. 1–3). Of note, MIP-1α showed 2.3-fold increase in the AMD cohort than controls. Concentrations of aqueous humor cytokines GRO, MDC, MIP-1α, IL-8, IP-10, and MCP-1 levels were significantly higher in PCV subjects compared with controls (all $P < 0.05$; Figs. 1–6). IL-8 and IP-10 showed more than a threefold increase, and MCP-1 and MIP-1α showed more than a twofold increase than controls.

No significant differences were observed in these cytokines in plasma samples between the cases and controls, and no significant differences in both aqueous humor and plasma cytokine levels were observed between CNV-AMD and PCV

patients. However, there were two cytokines (sCD40L and PDGF-AA) that were downregulated in patients with CNV-AMD compared with healthy controls, but there was no difference between CNV-AMD and PCV plasma samples for both of these cytokines (Table 3).

DISCUSSION

In this study, a large panel of cytokine profiles was evaluated in both aqueous humor and blood samples from patients with CNV-AMD and PCV. It was demonstrated that significant differences existed in aqueous humor cytokine levels in patients with CNV-AMD (GRO, MDC, and MIP-1α) and PCV (GRO, MDC, MIP-1α, MCP-1, IP-10, and IL-8) compared with control subjects. Among patients with CNV-AMD and PCV, aqueous humor cytokine profiles did not show any significant differences. In terms of plasma cytokine levels, there was no significant difference among CNV-AMD, PCV, and control subjects. Our results support the theory that cytokine-mediated inflammation contributes to the pathogenesis of CNV-AMD and PCV. It also suggests that local rather than systemic deregulation of cytokines level is present in CNV-AMD and PCV.

GRO belongs to a subgroup of chemotactic cytokines (chemokine) that is characterized by the presence of the CXC motif. The total concentration of GRO measured in our study included three highly similar molecules (i.e., GROα/CXCL1, GROβ/CXCL2, and GROγ/CXCL3). Although GROα/CXCL1, the primary subtype of GRO, is known to be a potent neutrophil chemoattractant and mediator of inflammation and angiogenesis,²⁴ the functions of GROβ/CXCL2 and GROγ/CXCL3 remain poorly understood. In animal studies, GROα/CXCL1 is shown to be an essential mediator of neutrophil infiltration in a rabbit uveitis model.²⁵ It is secreted by RPE and Müller cells in a light-induced retinal degeneration model in rats²⁶ and is also upregulated in a model of laser-induced CNV in mice.²⁷ Deregulation of neutrophils plays a

TABLE 2. Mean Concentrations and Fold Change of Aqueous Humor Cytokines in Cases and Controls

Groups	Analytes	Mean Concentrations in Cases	Mean Concentrations in Controls	Fold Difference	P
AMD versus controls	GRO	41.12	26.59	1.55	0.0034
	MDC	30.10	15.63	1.92	0.0059
	MIP-1α	11.83	5.15	2.30	0.0032
PCV versus controls	GRO	45.70	26.60	1.72	0.0124
	IL-8	25.01	6.83	3.66	0.0250
	IP-10	583.72	193.60	3.01	0.0222
	MCP-1	2124.40	925.98	2.30	0.0175
	MDC	30.10	15.63	1.93	0.0001
	MIP-1α	11.00	5.15	2.14	0.0007

P values reported for post hoc *t*-tests corrected for multiple testing correction using the method of Bonferroni. Values are in pg/mL. This table only shows the specific cytokines with statistically significant difference in the post hoc *t*-tests after ensuring significance in the ANOVA results.

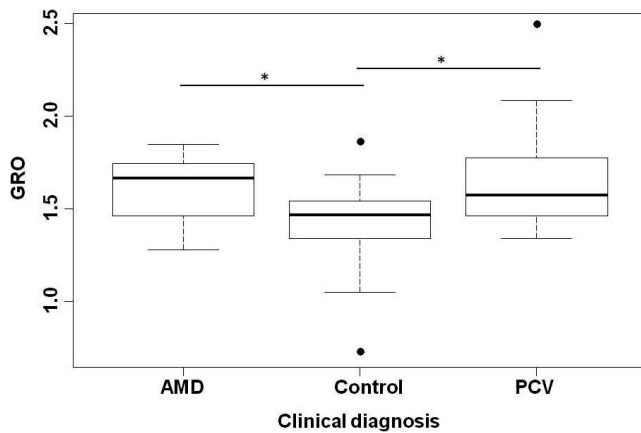


FIGURE 1. Box plot showing median centered and logarithmically transformed aqueous humor cytokines GRO levels in patients with exudative AMD, PCV, and control subjects. * $P < 0.04$; ** $P \leq 0.003$.

key role in the pathogenesis of in CNV-AMD, which is characterized by inflammation and angiogenesis.²⁸ Direct comparisons of aqueous humor GRO levels between CNV-AMD/PCV patients and controls were reported previously, but the results are inconsistent among datasets. A recent Japanese study did not show a difference in GRO α /CXCL1 levels in the aqueous sample between CNV-AMD/PCV patients and control subjects. However, there was a significant reduction in the aqueous humor GRO α /CXCL1 level after intravitreal anti-VEGF treatment.²⁹ A lower aqueous GRO level was noted in Chinese patients with wet AMD.²² This study, however, did not specify whether PCV was included. In our study, aqueous GRO level was measured to be 1.5 and 1.7 times higher in CNV-AMD and PCV patients, respectively. This observation suggests a possible association of GRO-mediated inflammation in the pathogenesis of CNV-AMD and PCV, which is in keeping with evidence from animal studies.

MDC, also known as CCL22, is a member of the subgroup of chemokines with a conserved CC motif. It is secreted by the proangiogenic M2 macrophages,³⁰ which differs functionally from the proinflammatory M1 macrophages.³¹ In histopathologic analysis, increased expression of MDC/CCL22 was found in the macular choroidal trephine of human eyes with AMD.³² Evaluation of aqueous humor MDC/CCL22 level in exudative AMD was previously reported in a cohort of Chinese patients,

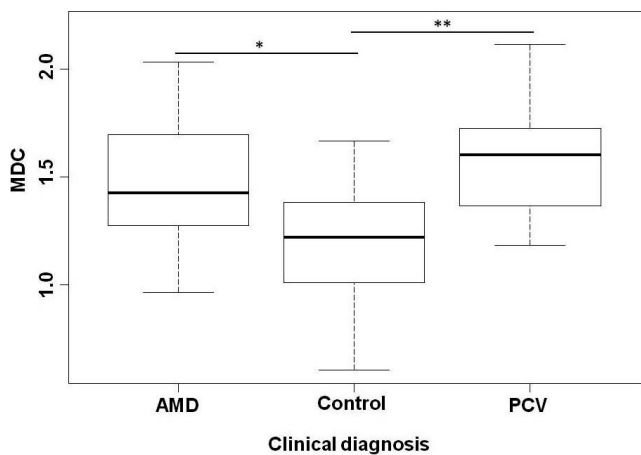


FIGURE 2. Box plots showing median centered and logarithmically transformed aqueous humor cytokines MDC levels in patients with exudative AMD, PCV, and control subjects. * $P < 0.04$; ** $P \leq 0.003$.

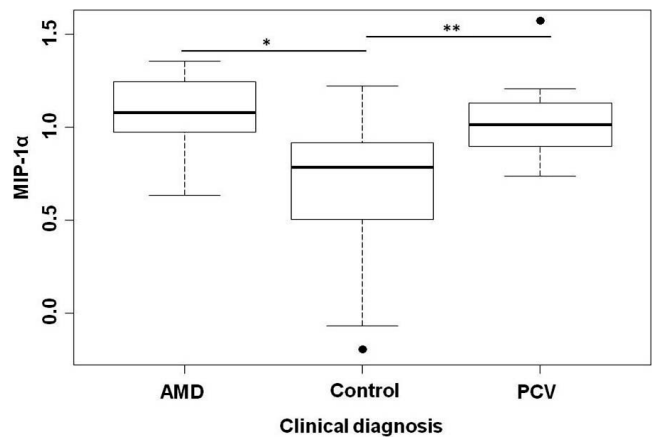


FIGURE 3. Box plots showing median centered and logarithmically transformed aqueous humor cytokines MIP-1 α levels in patients with exudative AMD, PCV, and control subjects. * $P < 0.04$; ** $P \leq 0.003$.

and it was significantly higher compared with controls.²² Our result showed a 1.9- and 2.5-fold increase in the aqueous humor MDC/CCL2 level in CNV-AMD and PCV patients, respectively. This is consistent with the previous wet AMD study. In addition, we demonstrated specifically that the aqueous humor MDC/CCL2 level was raised in PCV patients for the first time. This indicates the functional role of MDC/CCL2 and possibly M2 macrophages in the tissue remodeling and neovascularization process in both CNV-AMD and PCV.

The third chemokine that was shown to be raised in the aqueous humor of both CNV-AMD and PCV patients was MIP-1 α , also known as CCL3. It belongs to the same chemokine subgroup as MDC/CCL22 and shares the conserved CC motif. Systemically, it is shown to be a mediator of inflammation³³ and angiogenesis³⁴ in recurrent wheezing and osteosarcoma, respectively. MIP-1 α /CCL3 and its receptors (CCR1 and 5) are considered therapeutic targets for treatment of a few systemic inflammatory diseases including multiple sclerosis and rheumatoid arthritis.³⁵ In animal studies, MIP-1 α /CCL3 was noted to be upregulated in a rat model of light-induced retinal degeneration.³⁶ It was also shown to be an essential signaling molecule in microglia-mediated retinal inflammation in a mouse model of Stargardt disease and retinitis pigmentosa.³⁷ Thus far, there has been no report of change in the MIP-1 α /CCL3 level in aqueous humor from patients with CNV-AMD or

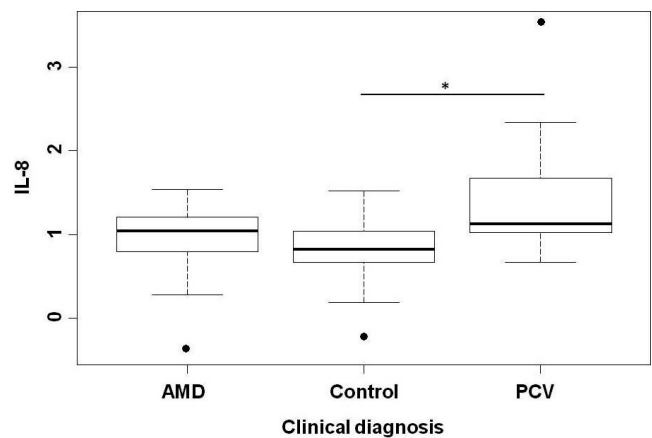


FIGURE 4. Box plots showing median centered and logarithmically transformed aqueous humor cytokines IL-8 levels in patients with exudative AMD, PCV, and control subjects. * $P < 0.04$.

TABLE 3. Mean Concentrations and Fold Change of Plasma Cytokines in Cases and Controls

Group	Analytes	Mean Concentrations in Cases	Mean Concentrations in Controls	Fold Difference	P
AMD versus controls	sCD40L	103.07	254.07	0.41	0.0067
	PDGF-AA	242.23	917.67	0.26	0.0261

P values reported for post hoc *t*-tests corrected for multiple testing correction using the method of Bonferroni. Values are in pg/mL. This table only shows the specific cytokines with statistically significant difference in the post hoc *t*-tests after ensuring significance in the ANOVA results.

PCV. The observation that more than a twofold increase in aqueous MIP-1 α /CCL3 levels in both CNV-AMD and PCV patients is a novel finding. If validated in future studies, MIP-1 α /CCL3 could be a potential therapeutic target in treating CNV-AMD and PCV.

MCP-1/CCL2, IP-10/CXCL10, and IL-8 are cytokines that were significantly higher in aqueous humor from PCV but not CNV-AMD patients in our study. Similar to the three chemokines that were discussed above, these three cytokines have also been demonstrated to be mediators of inflammation and angiogenesis in various ocular³⁸⁻⁴¹ and systemic diseases.⁴²⁻⁴⁵ IP-10/CXCL10 is also shown to be abundantly expressed in choroidal neovascularization membranes from postmortem eyes with AMD.⁴⁶ In previous studies of similar design, only MCP-1/CCL2 and IP-10/CXCL10 have been shown to be increased in aqueous humor from PCV patients specifically.^{21,47} Therefore, higher aqueous humor levels of IL-8 in PCV patients is a novel finding based on our study. Of note, aqueous humor concentrations of these three cytokines did show a nonsignificant higher trend in CNV-AMD patients compared with controls. This observation is in agreement with prior research on aqueous humor cytokine levels in neovascular AMD patients.^{20,21,48,49}

VEGF is the cytokine of special interest because intravitreal anti-VEGF injection is the mainstay treatment for CNV-AMD and PCV in current clinical practice. However, studies on aqueous humor VEGF levels have yielded inconsistent results. Increased VEGF levels were reported in a number of studies involving both CNV-AMD and PCV patients.^{18-20,47} Tong et al. also showed aqueous humor VEGF level was significantly lower in PCV compared with CNV-AMD patients.¹⁸ In contrary, there was another body of evidence in which no significant difference was found between CNV-AMD/PCV patients and controls.^{21,48,50,51} In our study, aqueous humor VEGF concentration did not differ significantly between study and control groups. Although a consensus has yet to be reached, one

plausible explanation for the discrepancy is that CNV-AMD/PCV has more localized pathology compared WITH generalized retinal disorders such as proliferative diabetic retinopathy, resulting in a limited rise in VEGF production.

Plasma cytokine levels has been investigated as potential biomarkers for AMD. Previous studies have shown AMD patients have elevated plasma levels of C-reactive protein,¹⁷ IP-10,⁴⁶ eotaxin,^{46,52} VEGF,⁵³ and interleukins (IL-1 α , IL-1 β , IL-4, IL-5, IL-10, IL-13, and IL-17).⁵⁴ However, it is noteworthy that most of these observations have not been replicated, and there are indeed studies that reported a similar plasma cytokine profile between neovascular AMD patients and controls.⁵⁵ Our study did not show a significant difference in plasma cytokine levels in CNV-AMD or PCV patients of the abovementioned or the specific cytokines that were upregulated in aqueous humor. However, plasma levels of sCD40L and PDGF-AA were downregulated in patients with CNV-AMD compared with healthy controls (on ANOVA and post hoc *t*-test). The role of the CD40 and sCD40L system in inflammatory response, vascular diseases, and atherosclerosis is widely accepted in the current literature.⁵⁶ PDGF-AA is one of the isoforms of PDGF. It is a proinflammatory and proangiogenic cytokine,⁵⁷ which has been showed to be expressed during angiogenesis in neovascular AMD.⁵⁸ Future studies are needed to validate whether deregulation of systemic inflammatory markers is present in AMD patients.

There are several limitations of our study. First, intraocular cytokine levels were measured with samples from aqueous humor instead of vitreous humor. Although vitreous cytokine concentration may better represent the actual value at the site of pathology in the retina and choroid,⁵⁹ it is more invasive to obtain vitreous samples and may not be ethically justified in research. Second, the sample size was relatively small. True difference in cytokine levels may not be fully appreciated, particularly in the comparison between CNV-AMD and PCV groups.

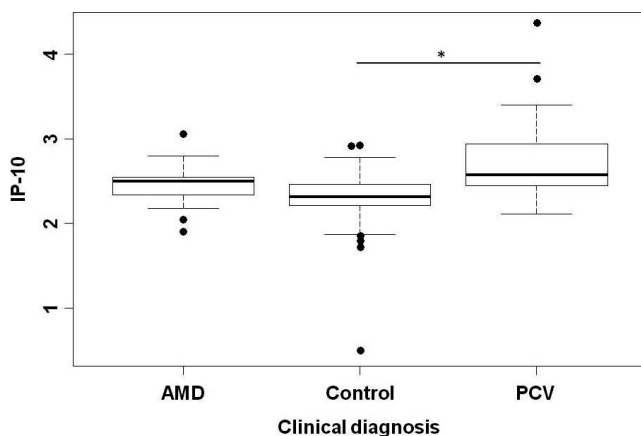


FIGURE 5. Box plots showing median centered and logarithmically transformed aqueous humor cytokines IP-10 levels in patients with exudative AMD, PCV, and control subjects. **P* < 0.04.

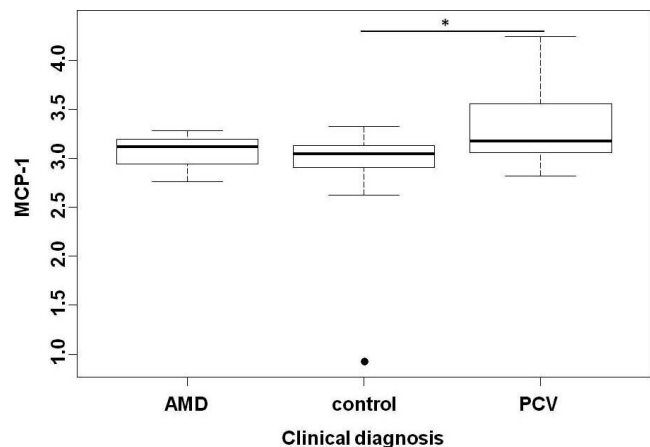


FIGURE 6. Box plots showing median centered and logarithmically transformed aqueous humor cytokines MCP-1 levels in patients with exudative AMD, PCV, and control subjects. **P* < 0.04.

In conclusion, increased cytokine levels in the aqueous humor from CNV-AMD and PCV suggests a role of inflammation in the pathogenesis of neovascular AMD and PCV. Understanding changes in cytokine profile may contribute to identification of new therapeutic targets in disease treatment. The lack of similar changes in plasma cytokine levels suggest that the pathologic changes in eyes with CNV-AMD/PCV are mainly due to dysregulation of local rather than systemic immune factors.

Acknowledgments

Supported by National Healthcare Group Thematic Grant NTG/13008.

Disclosure: **R. Agrawal**, None; **P.K. Balne**, None; **X. Wei**, None; **V.A. Bijin**, None; **B. Lee**, None; **A. Ghosh**, None; **R. Narayanan**, None; **M. Agrawal**, None; **J. Connolly**, None

References

- McConnell V, Silvestri G. Age-related macular degeneration. *Ulster Med J*. 2005;74:82-92.
- Age-Related Eye Disease Study Research Group. Risk factors associated with age-related macular degeneration. A case-control study in the age-related eye disease study: Age-Related Eye Disease Study Report Number 3. *Ophthalmology*. 2000;107:2224-2232.
- Alfaro V, Liggett P, Mieler W, Quiroz-Mercado H, Jager R, Tano Y. *Age Related Macular Degeneration: A Comprehensive Text*. Philadelphia: Lippincott Williams & Wilkins; 2006.
- Lim LS, Mitchell P, Seddon JM, Holz FG, Wong TY. Age-related macular degeneration. *Lancet*. 2012;379:1728-1738.
- Kuehn BM. Gene discovery provides clues to cause of age-related macular degeneration. *JAMA*. 2005;293:1841-1845.
- Bressler SB, Munoz B, Solomon SD, West SK. Racial differences in the prevalence of age-related macular degeneration: the Salisbury Eye Evaluation (SEE) Project. *Arch Ophthalmol*. 2008;126:241-245.
- Seddon JM, Cote J, Page WF, Aggen SH, Neale MC. The US twin study of age-related macular degeneration: relative roles of genetic and environmental influences. *Arch Ophthalmol*. 2005;123:321-327.
- Klein BE, Klein R, Lee KE, Jensen SC. Measures of obesity and age-related eye diseases. *Ophthalmic Epidemiol*. 2001;8:251-262.
- Zampatti S, Ricci F, Cusumano A, Marsella LT, Novelli G, Giardina E. Review of nutrient actions on age-related macular degeneration. *Nutr Res*. 2014;34:95-105.
- Khan JC, Thurlby DA, Shahid H, et al. Smoking and age related macular degeneration: the number of pack years of cigarette smoking is a major determinant of risk for both geographic atrophy and choroidal neovascularisation. *Br J Ophthalmol*. 2006;90:75-80.
- Nowak JZ. Age-related macular degeneration (AMD): pathogenesis and therapy. *Pharmacol Rep*. 2006;58:353-363.
- Laude A, Cackett PD, Vithana EN, et al. Polypoidal choroidal vasculopathy and neovascular age-related macular degeneration: same or different disease? *Progr Retinal Eye Res*. 2010;29:19-29.
- Wong CW, Yanagi Y, Lee WK, et al. Age-related macular degeneration and polypoidal choroidal vasculopathy in Asians. *Progr Retinal Eye Res*. 2016;53:107-139.
- Wong CW, Wong TY, Cheung CM. Polypoidal choroidal vasculopathy in Asians. *J Clin Med*. 2015;4:782-821.
- Kauppinen A, Paterno JJ, Blasiak J, Salminen A, Kaarniranta K. Inflammation and its role in age-related macular degeneration. *Cell Molec Life Sci*. 2016;73:1765-1786.
- Peter Delves J, Martin SJ, Burton DR, Roitt IM. *Roitt's Essential Immunology*. 12th edition. Hoboken, NJ: Wiley-Blackwell; 2011.
- Kikuchi M, Nakamura M, Ishikawa K, et al. Elevated C-reactive protein levels in patients with polypoidal choroidal vasculopathy and patients with neovascular age-related macular degeneration. *Ophthalmology*. 2007;114:1722-1727.
- Tong JP, Chan WM, Liu DT, et al. Aqueous humor levels of vascular endothelial growth factor and pigment epithelium-derived factor in polypoidal choroidal vasculopathy and choroidal neovascularization. *Am J Ophthalmol*. 2006;141:456-462.
- Funk M, Karl D, Georgopoulos M, et al. Neovascular age-related macular degeneration: intraocular cytokines and growth factors and the influence of therapy with ranibizumab. *Ophthalmology*. 2009;116:2393-2399.
- Agawa T, Usui Y, Wakabayashi Y, et al. Profile of intraocular immune mediators in patients with age-related macular degeneration and the effect of intravitreal bevacizumab injection. *Retina (Philadelphia, Pa)*. 2014;34:1811-1818.
- Sakurada Y, Nakamura Y, Yoneyama S, et al. Aqueous humor cytokine levels in patients with polypoidal choroidal vasculopathy and neovascular age-related macular degeneration. *Ophthalmic Res*. 2015;53:2-7.
- Liu F, Ding X, Yang Y, et al. Aqueous humor cytokine profiling in patients with wet AMD. *Molec Vision*. 2016;22:352-361.
- Kothur K, Wienholt L, Tantsis EM, et al. B Cell, Th17, and neutrophil related cerebrospinal fluid cytokine/chemokines are elevated in MOG antibody associated demyelination. *PLoS One*. 2016;11:e0149411.
- Schoenberger SD, Kim SJ, Sheng J, Rezaei KA, Lalezary M, Cherney E. Increased prostaglandin E2 (PGE2) levels in proliferative diabetic retinopathy, and correlation with VEGF and inflammatory cytokines. *Invest Ophthalmol Vis Sci*. 2012;53:5906-5911.
- Mo JS, Matsukawa A, Ohkawara S, Yoshinaga M. CXC chemokine GRO is essential for neutrophil infiltration in LPS-induced uveitis in rabbits. *Exp Eye Res*. 2000;70:221-226.
- Rutar M, Natoli R, Chia RX, Valter K, Provis JM. Chemokine-mediated inflammation in the degenerating retina is coordinated by Muller cells, activated microglia, and retinal pigment epithelium. *J Neuroinflammation*. 2015;12:8.
- Li L, Heiduschka P, Alex AF, Niekammer D, Eter N. Behaviour of CD11b-positive cells in an animal model of laser-induced choroidal neovascularisation. *Ophthalmologica*. 2017;237:29-41.
- Krogh Nielsen M, Hector SM, Allen K, Subhi Y, Sørensen TL. Altered activation state of circulating neutrophils in patients with neovascular age-related macular degeneration. *Immun Ageing*. 2017;14:18.
- Sakamoto S, Takahashi H, Tan X, et al. Changes in multiple cytokine concentrations in the aqueous humour of neovascular age-related macular degeneration after 2 months of ranibizumab therapy. *Br J Ophthalmol*. 2017;102:448-454.
- Yogo Y, Fujishima S, Inoue T, et al. Macrophage derived chemokine (CCL22), thymus and activation-regulated chemokine (CCL17), and CCR4 in idiopathic pulmonary fibrosis. *Respir Res*. 2009;10:80.
- Mantovani A, Sica A, Sozzani S, Allavena P, Vecchi A, Locati M. The chemokine system in diverse forms of macrophage activation and polarization. *Trends Immunol*. 2004;25:677-686.
- Cao X, Shen D, Patel MM, et al. Macrophage polarization in the maculae of age-related macular degeneration: a pilot study. *Pathol Int*. 2011;61:528-535.
- Sugai K, Kimura H, Miyaji Y, et al. MIP-1alpha level in nasopharyngeal aspirates at the first wheezing episode predicts recurrent wheezing. *J Allergy Clin Immunol*. 2016;137:774-781.

34. Liao YY, Tsai HC, Chou PY, et al. CCL3 promotes angiogenesis by dysregulation of miR-374b/ VEGF-A axis in human osteosarcoma cells. *Oncotarget*. 2016;7:4310–4325.
35. Ribeiro S, Horuk R. The clinical potential of chemokine receptor antagonists. *Pharmacol Therap*. 2005;107:44–58.
36. Jiao H, Natoli R, Valter K, Provis JM, Rutar M. Spatiotemporal cadence of macrophage polarisation in a model of light-induced retinal degeneration. *PLoS One* 2015;10:e0143952.
37. Kohno H, Maeda T, Perusek L, Pearlman E, Maeda A. CCL3 production by microglial cells modulates disease severity in murine models of retinal degeneration. *J Immunol*. 2014;192:3816–3827.
38. Kunikata H, Shimura M, Nakazawa T, et al. Chemokines in aqueous humour before and after intravitreal triamcinolone acetonide in eyes with macular oedema associated with branch retinal vein occlusion. *Acta Ophthalmol*. 2012;90:162–167.
39. Yamada K, Sakurai E, Itaya M, Yamasaki S, Ogura Y. Inhibition of laser-induced choroidal neovascularization by atorvastatin by downregulation of monocyte chemotactic protein-1 synthesis in mice. *Invest Ophthalmol Vis Sci*. 2007;48:1839–1843.
40. Abu El-Asrar AM, Struyf S, Kangave D, Geboes K, Van Damme J. Chemokines in proliferative diabetic retinopathy and proliferative vitreoretinopathy. *Eur Cytokine Netwk*. 2006;17:155–165.
41. Ghasemi H, Ghazanfari T, Yaraee R, Faghihzadeh S, Hassan ZM. Roles of IL-8 in ocular inflammations: a review. *Ocular Immunol Inflamm*. 2011;19:401–412.
42. Barczyk A, Pierzchala E, Caramori G, Sozanska E. Increased expression of CCL4/MIP-1beta in CD8+ cells and CD4+ cells in sarcoidosis. *Int J Immunopathol Pharmacol*. 2014;27:185–193.
43. Hasegawa M, Fujimoto M, Matsushita T, Hamaguchi Y, Takehara K, Sato S. Serum chemokine and cytokine levels as indicators of disease activity in patients with systemic sclerosis. *Clin Rheumatol*. 2011;30:231–237.
44. Liu M, Guo S, Hibbert JM, et al. CXCL10/IP-10 in infectious diseases pathogenesis and potential therapeutic implications. *Cytokine Growth Factor Rev*. 2011;22:121–130.
45. Remick DG. Interleukin-8. *Crit Care Med*. 2005;33:S466–S467.
46. Mo FM, Proia AD, Johnson WH, Cyr D, Lashkari K. Interferon gamma-inducible protein-10 (IP-10) and eotaxin as biomarkers in age-related macular degeneration. *Invest Ophthalmol Vis Sci*. 2010;51:4226–4236.
47. Hu J, Leng X, Hu Y, et al. The features of inflammation factors concentrations in aqueous humor of polypoidal choroidal vasculopathy. *PLoS One*. 2016;11:e0147346.
48. Jonas JB, Tao Y, Neumaier M, Findeisen P. Cytokine concentration in aqueous humour of eyes with exudative age-related macular degeneration. *Acta Ophthalmol*. 2012;90:e381–e388.
49. Jonas JB, Tao Y, Neumaier M, Findeisen P. Monocyte chemoattractant protein 1, intercellular adhesion molecule 1, and vascular cell adhesion molecule 1 in exudative age-related macular degeneration. *Arch Ophthalmol*. 2010;128:1281–1286.
50. Roh MI, Kim HS, Song JH, Lim JB, Koh HJ, Kwon OW. Concentration of cytokines in the aqueous humor of patients with naive, recurrent and regressed CNV associated with AMD after bevacizumab treatment. *Retina*. 2009;29:523–529.
51. Jonas JB, Neumaier M. Vascular endothelial growth factor and basic fibroblast growth factor in exudative age-related macular degeneration and diffuse diabetic macular edema. *Ophthalmic Res*. 2007;39:139–142.
52. Sharma NK, Prabhakar S, Gupta A, et al. New biomarker for neovascular age-related macular degeneration: eotaxin-2. *DNA Cell Biol*. 2012;31:1618–1627.
53. Grierson R, Meyer-Rusenberg B, Kunst F, Berna MJ, Richard G, Thill M. Endothelial progenitor cells and plasma vascular endothelial growth factor and stromal cell-derived factor-1 during ranibizumab treatment for neovascular age-related macular degeneration. *J Ocular Pharmacol Therap*. 2013;29:530–538.
54. Nassar K, Grisanti S, Elfar E, Luke J, Luke M, Grisanti S. Serum cytokines as biomarkers for age-related macular degeneration. *Graefes Arch Clin Exp Ophthalmol*. 2015;253:699–704.
55. Fauser S, Viebahn U, Muether PS. Intraocular and systemic inflammation-related cytokines during one year of ranibizumab treatment for neovascular age-related macular degeneration. *Acta Ophthalmol*. 2015;93:734–738.
56. Zhang B, Wu T, Chen M, Zhou Y, Yi D, Guo R. The CD40/CD40L system: a new therapeutic target for disease. *Immunol Lett*. 2013;153:58–61.
57. Shure D, Senior RM, Griffin GL, Deuel TF. PDGF AA homodimers are potent chemoattractants for fibroblasts and neutrophils, and for monocytes activated by lymphocytes or cytokines. *Biochem Biophys Res Commun*. 1992;186:1510–1514.
58. Kliffen M, Sharma HS, Mooy CM, Kerkvliet S, de Jong PT. Increased expression of angiogenic growth factors in age-related maculopathy. *Br J Ophthalmol*. 1997;81:154–162.
59. Kamppeeter BA, Cej A, Jonas JB. Intraocular concentration of triamcinolone acetonide after intravitreal injection in the rabbit eye. *Ophthalmology*. 2008;115:1372–1375.